

Baptist Health South Florida Scholarly Commons @ Baptist Health South Florida

All Publications

2018

The Significance of Thallium-201-Chloride SPECT Myocardial Perfusion Imaging in the Management of Patients With Stable Chronic Coronary Artery Disease

Anshul Saxena

Baptist Health Medical Group, AnshulS@baptisthealth.net

Follow this and additional works at: <https://scholarlycommons.baptisthealth.net/se-all-publications>

Citation


Clinical Medicine Insights: Cardiology (2018) 12:1179546818790562

This Article -- Open Access is brought to you for free and open access by Scholarly Commons @ Baptist Health South Florida. It has been accepted for inclusion in All Publications by an authorized administrator of Scholarly Commons @ Baptist Health South Florida. For more information, please contact Carrief@baptisthealth.net.

The Significance of Thallium-201-Chloride SPECT Myocardial Perfusion Imaging in the Management of Patients With Stable Chronic Coronary Artery Disease

Clinical Medicine Insights: Cardiology
Volume 12: 1–8
© The Author(s) 2018
Reprints and permissions:
sagepub.co.uk/journalsPermissions.nav
DOI: 10.1177/1179546818790562



Ivan Jurić¹, Emir Fazlibegović¹, Danijel Pravdić¹, Boris Starčević², Ante Punda³, Dražen Huić⁴, Mustafa Hadžomerović¹, Damir Rozić¹, Marko Martinac⁵, Darko Markota¹, Mirjana Vasilij¹, Ivan Vasilij⁶ and Anshul Saxena⁷ 

¹University Clinical Hospital Mostar, Mostar, Bosnia and Herzegovina. ²Clinical Hospital Dubrava, Zagreb, Croatia. ³Clinical Department for Nuclear Medicine, Split, Croatia. ⁴Clinical Department for Nuclear Medicine and Radiation Protection, Zagreb, Croatia. ⁵Health Center, Mostar, Bosnia and Herzegovina. ⁶Faculty of Health Studies, Mostar, Bosnia and Herzegovina. ⁷Baptist Health South Florida, Coral Gables, FL, USA.

ABSTRACT:

BACKGROUND: Patients with stable coronary artery disease (CAD) can be evaluated for myocardial viability by examining reverse redistribution of Thallium-201 (²⁰¹Tl) through cardiac scintigraphy. There is limited knowledge about association of a reverse redistribution with favorable cardiac outcomes. In this study, we hypothesized that higher left ventricular ejection fraction (LVEF), lower myocardial necrosis, fewer ischemic events, and less angina will be associated with reverse redistribution of ²⁰¹Tl imaging.

METHODS: Adult patients with stable CAD included in this study underwent exercise-redistribution Thallium single-photon emission computed tomography (SPECT) and were followed for one year. LVEF and regional wall motion abnormalities were evaluated with echocardiography, exercise duration by bicycle testing, and myocardial ischemia and viability by Thallium SPECT.

RESULTS: We studied 159 patients (87 men, 72 women, median age 60 years, range: 38-84) with well-developed collaterals. Those with reverse redistribution on SPECT ($n = 61$, 38.3%) had significantly better exercise tolerance ($\geq 85\%$; $P < .001$). Subjects with reverse redistribution had better LVEF ($P < .001$), wall motion parameters ($P < .001$), a lower degree of myocardial necrosis ($P < .05$), less angina during follow-up ($P = .02$), and fewer ischemic events whether treated with OMT or PCI ($P < .001$).

CONCLUSIONS: Reverse redistribution of ²⁰¹Tl on scintigraphic images is a predictor of myocardial viability. Evidence from our study suggests that optimally treated chronic CAD patients with reverse redistribution may have lower likelihood of future adverse cardiovascular events and better prognosis.

KEYWORDS: coronary artery disease, scintigraphy, angioplasty, collateral circulation, PCI

RECEIVED: December 20, 2017. **ACCEPTED:** June 28, 2018.

TYPE: Original Research

FUNDING: The author(s) received no financial support for the research, authorship, and/or publication of this article.

DECLARATION OF CONFLICTING INTERESTS: The author(s) declared no potential conflicts of interest with respect to the research, authorship, and/or publication of this article.

CORRESPONDING AUTHOR: Anshul Saxena, Center for Healthcare Advancement and Outcomes, Baptist Health South Florida, Coral Gables, FL 33146, USA. Email: AnshulS@Baptisthealth.net

Revascularization is the recommended optimal approach for managing coronary artery disease (CAD) presenting with an acute coronary syndrome.¹ Optimal management of patients with stable CAD is, however, still controversial.^{2,3} Guidelines from the European Society of Cardiology (ESC) recommend a non-invasive assessment of myocardial viability in stable CAD, and decision making by a multi-disciplinary team.^{1,4} Some studies have suggested that medical therapy may be an optimal approach in management of specific patients with stable CAD who have viable myocardium and a well-developed collateral circulation, a condition that is often associated with a reverse redistribution pattern during Thallium-201 (²⁰¹Tl) myocardial perfusion imaging (MPI).^{3,5} Findings from functional tests that detect viable myocardium, such as reverse redistribution of ²⁰¹Tl during MPI will be helpful in determining management of coronary stenosis.

Stress-MPI is often employed to assess the functional significance of obstructive CAD. It is very useful in cases with a moderate pre-test probability of CAD and in accurately predicting presence of epicardial CAD.¹ Moreover, the left ventricular function may be preserved despite severe coronary stenosis or occlusions in the presence of an abundant collateral circulation.⁶ It is unclear whether optimal medical therapy or coronary revascularization is appropriate in the management of these patients. The aim of our study was to evaluate the outcomes in patients with stable CAD and well-developed collateral circulation at angiography and reverse redistribution of ²⁰¹Tl in the territory of the culprit coronary artery.

Our hypothesis was that there will be greater preservation of left ventricular function, exercise tolerance and symptoms, and better long-term outcomes, regardless of assignment to PCI or OMT in patients with reverse redistribution.



Creative Commons Non Commercial CC BY-NC: This article is distributed under the terms of the Creative Commons Attribution-NonCommercial 4.0 License (<http://www.creativecommons.org/licenses/by-nc/4.0/>) which permits non-commercial use, reproduction and distribution of the work without further permission provided the original work is attributed as specified on the SAGE and Open Access pages (<https://us.sagepub.com/en-us/nam/open-access-at-sage>).

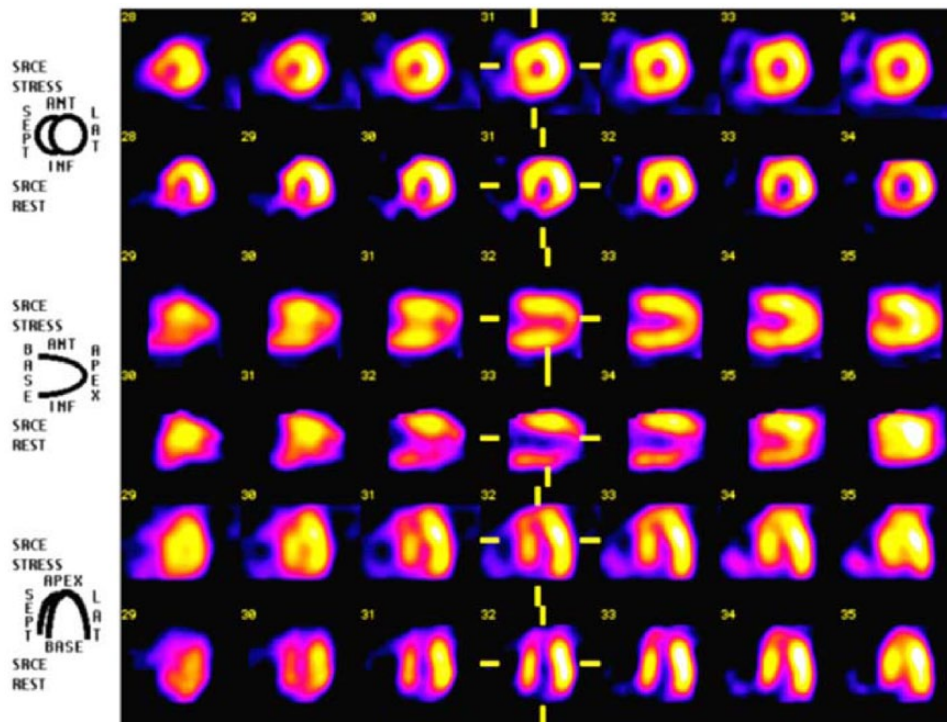


Figure 1. SPECT heart with ^{201}Tl /scintigraphic images of reverse redistribution: second, fourth and sixth order (redistribution): visible perfusion defect infero-apical segment 3 hours after the load. The first, third and fifth row (immediately after the load): no perfusion defect.

Methods

Patients

Adult patients undergoing coronary angiography between January 2011 and December 2013 in the Department of Cardiology at the University Clinical Hospital in Mostar, Bosnia and Herzegovina were enrolled. A complete physical examination, routine laboratory tests, electrocardiogram (ECG), stress ECG and echocardiography, and ^{201}Tl SPECT were performed. Informed consent was explained and obtained from each patient. This study was approved by the University Clinical Hospital Institutional Review Board

Study Protocol

Echocardiography. Two-dimensional echocardiography was performed with a 2.5-MHz transducer (GE, Vivid 4). Four standard views of the left ventricle were obtained for each acquisition: parasternal long axis, short axis at mitral and papillary muscle levels, and apical four- and two-chamber views. Undigitized images were analyzed by two independent operators. Regional wall motion was evaluated at the chordal, papillary muscle, and apical levels. Wall motion and systolic thickening were graded semiquantitatively by use of a scoring system in which 1 = normal, 2 = hypokinesia, 3 = akinesia, and 4 = dyskinesia. Normal left ventricular ejection fraction (EF) was defined as $\geq 50\%$ estimated by 2-dimensional (2D) echocardiography. Left ventricular volumes at end diastole and end systole were computed using a standard Simpson's method from the apical 2- and 4-chamber views to estimate LVEF.

SPECT imaging. All patients had a symptom-limited, multistep, dynamic bicycle stress test ("Ergo-fit300"). The initial workload was set at 25 W, and the exercise intensity was increased by 25W-steps each minute until the onset of symptoms or until 85% of the age-adjusted heart rate target was reached. At peak exercise, 111 MBq (3 mCi) of Tl-201 -chloride was injected intravenously and the patient was encouraged to continue exercising for another minute. Within 10 minutes after completion of the exercise test SPECT imaging was performed using a large-field-of-view gamma camera (Anyscan S; Mediso Ltd. Hungary) equipped with a low-energy general purpose collimator centered on the 73- and 164-keV photopeaks each with a 20% window. Single-photon emission computed tomography (SPECT) was performed as a semi-circular 180° orbit starting from 45° right anterior oblique to 45° left posterior oblique at 6° steps (30 seconds duration of each step). Redistribution images were obtained 3 hours later with 40 seconds acquisition time per angle and tomographic images were stored in a $64 \times 64 \times 16$ matrix. From the raw scintigraphic data, tomograms oriented along the three standard orthogonal views (transaxial, sagittal, and short-axis) were reconstructed using identical filtering.⁷ Filtered backprojection with a Butterworth filter (order, 5; cutoff, 0.5 cm^{-1}) was used. No attenuation correction was applied. The pattern of redistribution was evaluated by both visual and quantitative analysis comparing the stress and redistribution images. Reverse redistribution was defined as $\geq 10\%$ decrease in relative thallium-201 activity between stress and redistribution images and included either the worsening of a perfusion defect apparent on stress images or the appearance of a new defect on the redistribution images, see Figure 1.

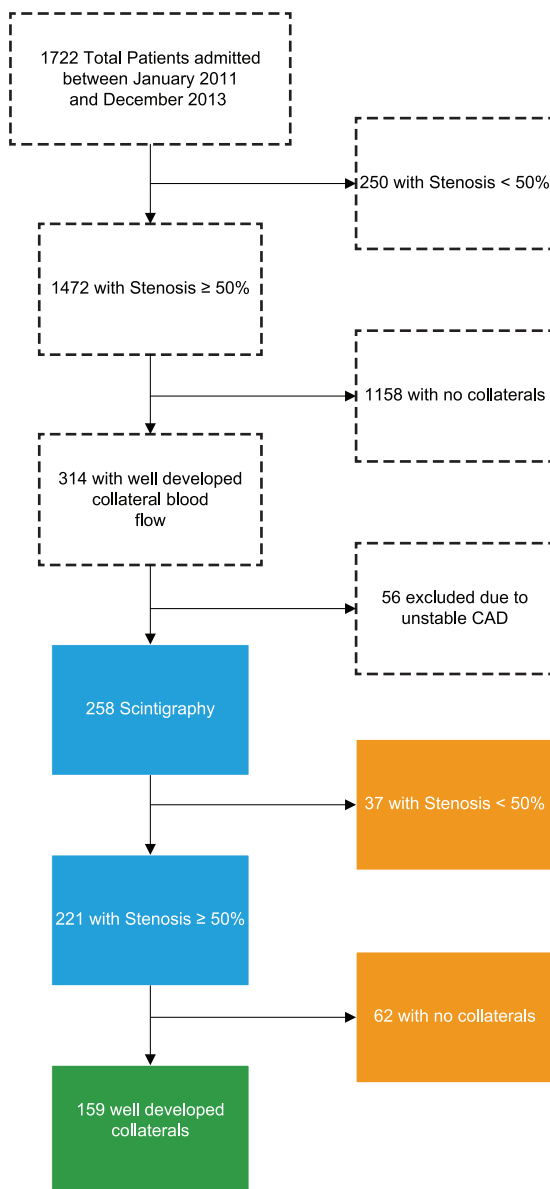


Figure 2. Flowchart of inclusion and exclusion of patients, and patient characteristics.

Quantitative ^{201}Tl Analysis. Three-pixel-thick slices were reconstructed along the short, horizontal, and vertical long axes of the heart. Flood, center of rotation, and decay correction were applied during reconstruction. ^{201}Tl images were visually interpreted (normal, moderate, frank, or complete defect) by an experienced observer, who was unaware of the clinical, echocardiographic, or angiographic characteristics of the patients. Regional ^{201}Tl activity was measured in each myocardial sector, and it was expressed in each patient as a percent of the maximal ^{201}Tl activity for each set of images. A ^{201}Tl defect was defined when ^{201}Tl activity measured $<80\%$ of maximal activity. Alignment and analysis of the two studies was visually made by two operators. Redistribution was defined when relative ^{201}Tl activity at 3 hours imaging increased $\geq 10\%$ above the initial value. Persistent defects at 3 hours imaging were classified as mild to moderate when ^{201}Tl activity was $\geq 50\%$ of maximal activity

and severe when ^{201}Tl activity was $<50\%$. Segments with persistent and severe reduction of ^{201}Tl activity were considered nonviable, whereas all other segments were considered viable.

Coronary angiography. Coronary angiography (transfemoral or transradial) was performed by the Judkin's method (Shimadzu digital flat panel detector).⁸ Collateral vessels were graded according to the Rentrop classification: 0, no filling of any collateral vessels; 1, filling of side branches of the artery to be perfused by collateral vessels without visualization of the epicardial segment; 2, partial filling of the epicardial artery by collateral vessels; and 3, complete filling of the epicardial artery by collateral vessels. All angiographies were evaluated by two cardiologists who were unaware of the other results. Patients in Rentrop grades 2 and 3 were classified as well-developed collateral circulation.⁹

Patient Follow-Up. Patients were followed up for the occurrence of major adverse cardiac events (MACE): angina, myocardial infarction (MI) or death. MI was defined using American College of Cardiology/ESC criteria and angina was using Canadian Cardiovascular Society Grading System for Stable Angina. Decisions about revascularization were made by the cardiologist based on the results of diagnostic angiography only.

Statistical Analysis

Results were stored in a MS Access database. SAS software version 9.4 was used for statistical analysis. Descriptive analyses included calculation of frequency and percentage for categorical variables, median and interquartile range or means for continuous variables, as appropriate. To test differences between groups, chi-square test, Fisher's exact test, and the independent t-test were used as appropriate. Multivariate survival analysis was conducted using Cox-Proportional hazards model accounting for demographic variables of age and sex. Adverse disease outcomes of angina, MI, death, and any or mixed adverse events were compared between patients with and without reverse redistribution. A P -value of $<.05$ was considered statistically significant.

Results

A total of 1722 patients underwent coronary angiography between January 2011 and December 2013. Of these, 1472 patients had significant CAD involving at least one major coronary artery, and 314 patients (21.3%) had well-developed collateral circulation to the culprit artery territory (Figure 2). In 258 of these patients with stable CAD, ^{201}Tl MPI was performed; 221 patients (128 men, median age 62 years) had significant stenosis during angiography and 159 (87 men, median age 60 years) had well-developed collateral circulation in the culprit vessel territory, whereas 62 patients (41 men, median age 58 years) had no angiographically visible collateral circulation. There was insignificant CAD ($<50\%$ stenosis) in the remaining 37 patients (16 men, median age 56) (Figure 2).

Table 1. Functionality of myocardial segments with reverse redistribution.

VARIABLES	N (%) PATIENTS ACCORDING TO SCINTIGRAPHIC FINDINGS				
	NORMAL	SCAR	ISCHEMIA	REVERSE REDISTRIBUTION	ISCHEMIA AND SCAR
Collaterals					
No	26 (72.2)	6 (24.0)	38 (48.1)	0	22 (38.6)
Yes	10 (27.8)	19 (76.0)	41 (51.9)	61 (100.0)	35 (61.4)
Stenosis (%)					
<50%	30 (83.3)	3 (12.0)	4 (5.1)	0	0
≥50%	6 (16.7)	22 (88.0)	75 (94.9)	61 (100.0)	57 (100.0)
Males	17 (48.6)	18 (72.0)	42 (54.5)	32 (52.5)	35 (62.5)
EF					
<50%	2 (5.9)	7 (28.0)	31 (39.2)	2 (3.3)	29 (50.9)
≥50%	32 (94.1)	18 (72.0)	48 (60.8)	59 (96.7)	28 (49.1)
Ergometry					
<85% maximum	10 (27.8)	15 (60.0)	46 (58.2)	15 (24.6)	41 (71.9)
≥85% maximum	26 (72.2)	10 (40.0)	33 (41.8)	46 (75.4)	16 (28.1)
Echocardiography					
Normokinesis	32 (97.0)	7 (28.0)	35 (44.3)	52 (85.2)	11 (19.3)
Hypokinesis inf.	0	10 (40.0)	20 (25.3)	5 (8.2)	30 (52.6)
Hypokinesis ant.	0	2 (8.0)	11 (13.9)	0	4 (7.0)
Hypokinesis sept.	1 (3.0)	3 (12.0)	4 (5.1)	1 (1.6)	2 (3.5)
Hypokinesis apx.	0	3 (12.0)	9 (11.4)	3 (4.9)	10 (17.5)

EF: ejection fraction.

Myocardial Scintigraphy

We investigated scintigraphic characteristics of myocardial segments with/without significantly narrowed epicardial arteries associated with/without well-developed collateral circulation in 258 patients. Patients with scintigraphic finding of reverse redistribution, as compared to patients with other positive scintigraphic findings were more likely to (a) have good collateralization ($P < .001$), (b) have >50% luminal occlusion ($P < .001$), (c) have EF ≥50% ($P < .001$), (d) achieved ≥85% of age-predicted heart rate during stress-testing ($P < .001$), and (e) had normal wall motion measured with echocardiography (Table 1).

Incident cardiovascular events—subgroup of 155 patients with significant stenosis, well-developed collateral circulation and positive scintigraphic findings (Table 2):

In the subgroup of patients who were event-free at 1-year follow-up and had scintigraphic finding of a reversible defects (ischemia) PCI was the most commonly employed treatment modality ($P < .001$). On the other hand, in the subgroup of event-free patients who had reverse redistribution pattern

during ^{201}Tl MPI, OMT was the most common treatment ($P = .02$).

A subset of 159 patients with good collaterals was found by invasive cardiologists in this study. The functional collaterals (collaterals able to nourish the corresponding myocardial segment) defined by pattern of reverse redistribution of ^{201}Tl in the corresponding myocardial segment were found on scintigraphy in 61 subjects (38.3%). The remaining myocardial segments in this category were scintigraphically presented as either ischemia or scarring indicating insufficient collaterals of the respective segments. Reverse redistribution pattern was associated with well-developed collateral circulation in all published papers.^{10–14} Of these 159 patients with significant narrowing of the coronary arteries and well-developed collaterals, 140 patients had viable myocardial segments (40 pts had scintigraphic ischemia, 61 reverse redistribution, 35 patients had mixed perfusion defects indicating ischemia with scarring and 4 patients had no scintigraphic visible perfusion defects). Twenty three out of 40 (46%) patients with angiographically proven significant stenosis and well-developed

Table 2. Cardiovascular events after 1 year follow-up according to scintigraphic findings.

SCINTIGRAPHIC FINDINGS	ONE YEAR FOLLOW-UP	N (%) PATIENTS ACCORDING TO APPLIED THERAPY	
		OMT	PCI
Scar (n = 19)	Number of patients	15	4
	No attacks	2 (13.3)	0
	Angina	11 (73.3)	3 (75.0)
	MI	1 (6.7)	1 (25.0)
	Death	1 (6.7)	0
Ischemia (n = 40)	Number of patients	10	30
	No attacks	0	18 (60.0)
	Angina	5 (50.0)	10 (33.3)
	MI	4 (40.0)	2 (6.7)
	Death	1 (10.0)	0
Reverse redistribution (n = 61)	Number of patients	43	18
	No attacks	37 (86.0)	10 (55.6)
	Angina	6 (14.0)	7 (38.9)
	MI	0	1 (5.6)
	Death	0	0
Ischemia and scar (n = 35)	Number of patients	14	21
	No attacks	2 (14.3)	3 (14.3)
	Angina	9 (64.3)	12 (57.1)
	MI	3 (21.4)	5 (23.8)
	Death	0	1 (4.8)

OMT: optimal medical therapy; PCI: percutaneous coronary intervention; MI: myocardial infarction.

collateral vessels had EF over 50%, 17/40 (42%) patients had normal wall motion and 15/40 (37.5%) patients achieved more than 85% of age-adjusted ergometric load. PCI was performed in 30 patients and of those 18 were event free during 1-year of follow-up, 10 patients had recurrent angina and 2 patients had MI. Optimal medical therapy was applied in 10 patients and of those 5 patients had recurrent angina, 4 patients had a MI and 1 patient died. Of 61 patients, 47 did not have ischemia during 1-year follow-up. Of these, 37 patients had OMT and 10 patients had PCI. In the group treated conservatively (OMT), 6 patients during the 1-year mark had frequent attacks of angina while 7 pts in the PCI group had angina attacks. Survival analysis showed significant benefit over time among patients with presence of reverse redistribution (Table 3 and Figure 3). In scintigraphic findings, reverse redistribution showed 87% (95% CI: 72%-90%) benefit when compared to patients with scarring over time.

Discussion

Percutaneous coronary intervention (PCI) is the most commonly performed medical procedure in acute coronary

syndrome.^{3,15,16} Currently, there is no consensus about providing optimal treatment for patients with chronic coronary heart disease. Our findings suggest that depending on clinical symptoms, patients' functional status, and the anatomical complexity, stable CAD can have better prognosis in presence of reverse redistribution. In patients with stable CAD, it is common to have discordant findings between anatomical imaging of coronary vessels and their functional ability to maintain viable myocytes. In this regard, the ESC recommended postponing invasive treatment in patients with discrepancies between anatomical and functional characteristics of the coronary vessels, and it has recommended the use of non-invasive procedures to assess myocardial functionality with respect to culprit vessels within multi-disciplinary "Heart Team."^{1,4} The "DEFER" and "FAME" studies have confirmed that the concept of avoiding unnecessary stent implantation using the above-mentioned functional method resulted in better outcomes.¹⁷⁻¹⁹ The "COURAGE" study showed that the OMT as initial form of treatment in patients with stable angina pectoris is equally effective in reducing the risk of death, MI or other major cardiovascular events as the combination of PCI

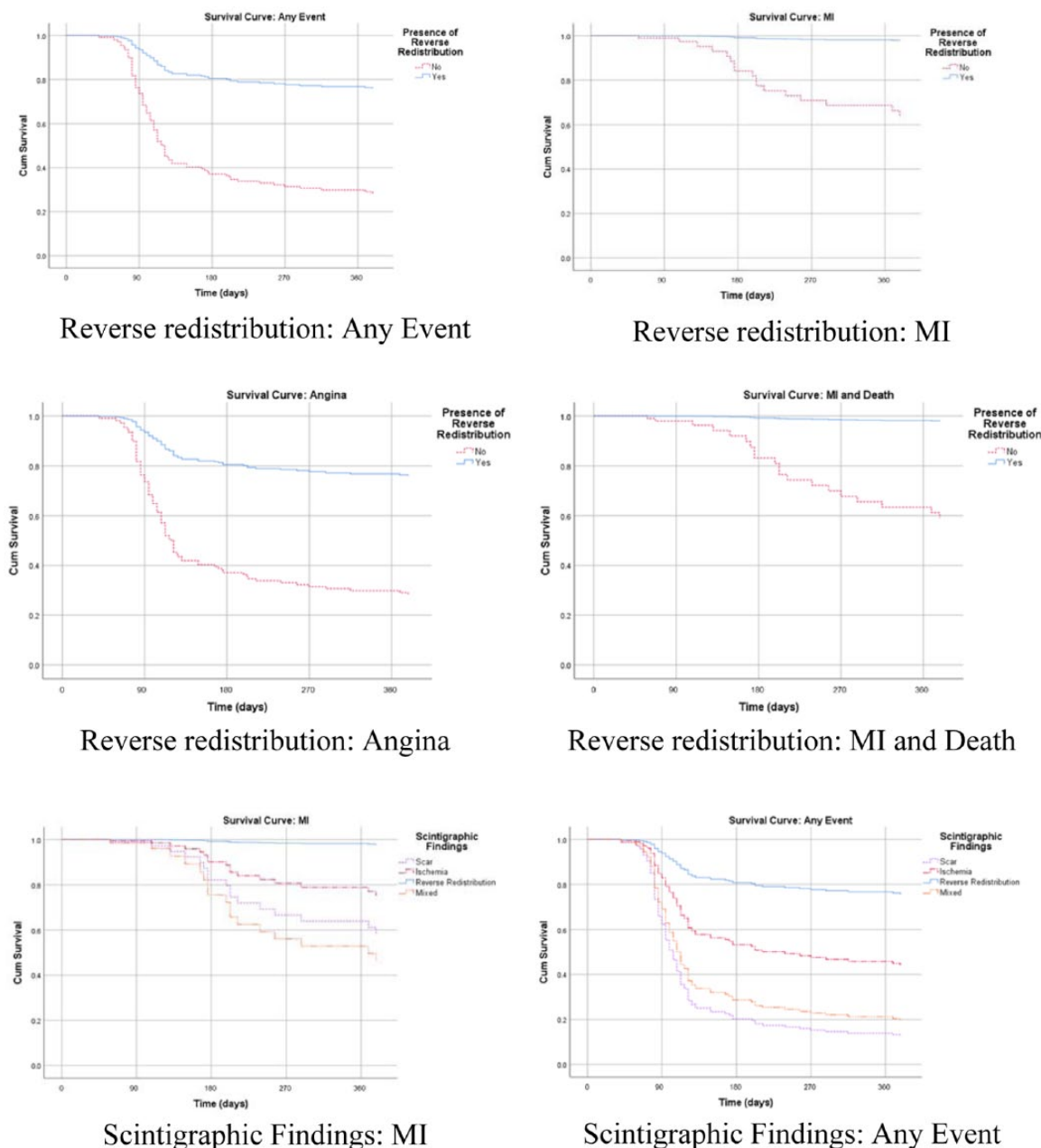


Figure 3. Survival curves showing survival probabilities over time (in days) among patients with the presence of reverse redistribution.

plus medical treatment.^{5,20} When exploring scintigraphic characteristics of myocardial segments in the supply area of significantly stenosed coronary arteries, we found almost identical angiographic findings for different scintigraphic findings (reversible defect, irreversible defect, partially reversible defect, and reverse redistribution). Opposite was also true, for various coronarographic findings, we found very similar scintigraphic patterns. This fact suggests key difference between anatomical (angiography) and functional (scintigraphic) imaging. This is a starting point and a source of ideas on the possible inclusion of specific findings observed among the tools in the decision to proceed with the treatment of patients with CAD.

Results of diagnostic coronary angiography are anatomical data that illustrate the degree of narrowing of the coronary

arteries, but it may not be precise since it is a visual assessment. On the other hand, functional scintigraphy images, the living cells regardless of the associated coronary anatomy and the goal of each method is to evaluate myocardial ischemia and not only the epicardial artery patency.²¹⁻²³ In support of scintigraphy as a functional method, there is the fact that ²⁰¹Tl is an analog of potassium which means that the mechanisms of movement and biodistribution in cells or tissues of both elements is identical and that the normal distribution of ²⁰¹Tl in myocardial cells reflects healthy tissue and conversely, abnormal biodistribution reflects scarring or myocardial ischemia.²⁴

Scintigraphic viability of ischemic and partially ischemic (reversible and partially reversible defects) myocardial segments becomes obvious after revascularization procedures.

Table 3. Hazard ratios for presence of reverse distribution.

	HR (95% CI)	P-VALUE
Any event	0.22 (0.12–0.39)	<.0001
MI	0.05 (0.01–0.36)	.003
Death	0.01 (0.0–153.56)	.36
MI and death	0.04 (0.005–0.30)	.002
Angina	0.22 (0.12–0.39)	<.0001
Scintigraphic findings		
Scar	Ref.	
Ischemia	0.40 (0.21–0.75)	.004
Reverse redistribution	0.13 (0.10–0.28)	<.0001
Mixed	0.78 (0.43–1.43)	.43

MI: myocardial infarction; HR: hazard ratio; CI: confidence interval. Models accounted for sex and age.

Myocardial segments presenting with reverse redistribution of ^{201}Tl exhibit good response to optimal medical therapy. Almost identically narrowed coronary epicardial arteries and well-developed collateral circulation that not only represent different scintigraphic characteristics related segments, but more importantly beyond the specific findings observed can expect better functional parameters. Results indicate better outcomes with PCI as compared to OMT in cases of scintigraphic findings of ischemia and angiographically proven significant stenosis despite well-developed collateral circulation. In the subgroup of patients with reverse redistribution on scintigraphic images, there was a significantly better exercise tolerance, EF, wall motion parameters, a lower degree of myocardial necrosis and a smaller number of ischemic attacks during one year follow-up. Results also suggest that OMT should be preferred over invasive therapeutic procedures in patients with scintigraphic finding of reverse redistribution regardless of coronary angiography. Research by Nudi et al also suggests that prognosis is better among patients with revascularization, but, they also emphasize the importance of focusing on necrosis, which is easier to define and irreversible, rather than viability, which is much more complex to define, and more prone to confusion. In addition, Nudi et al²⁵⁻²⁷ suggests that necrosis is much more stable, and obviously unlikely to benefit from revascularization.

In this case, the scintigraphic reverse redistribution pattern as an indicator of functional collaterals could serve as a new tool for making treatment decisions. Functional evaluation of myocardial segments by scintigraphic method describes functional significance as opposed to anatomical significance expressed in percent narrowing of the vascular lumen. Heart contractility and ejection ability can be preserved thanks to collateralized cardiac segments despite significant coronary artery stenosis. Results of our study indicate the need for scintigraphic evaluation of myocardial segments before making treatment

decisions which is in line with the recommendation of the ESC.^{1,4}

Conclusion

Scintigraphic pattern of reverse redistribution of ^{201}Tl as an indicator of successful natural bypasses (collaterals) may be used as an additional help in the choice of therapy in patients with chronic coronary heart disease. In such cases, functional collateral vessels should perhaps be kept patent by not performing revascularization procedure. If functional parameters and quality of life in terms of absence of new ischemic attacks during the one year-follow-up in patients with such scintigraphic pattern indicate stability of CAD then, clinicians may expect better prognosis in their patients.

Author Contributions

IJ conceptualized the study, supervised the project, and wrote the first draft of the manuscript. EF, DP, BS, AP, DH, MH, DR, DM, MV, and IV contributed to data collection, and revision of the manuscript. IJ, DM, MV, and IV contributed to further interpretation of the results. AS conducted the analysis and contributed to critical revision of the manuscript. All the authors have read and approved the final manuscript.

ORCID iD

Anshul Saxena  <https://orcid.org/0000-0002-2485-5017>

REFERENCES

- Windecker S, Kolh P, Alfonso F, et al. 2014 ESC/EACTS guidelines on myocardial revascularization: the Task Force on Myocardial Revascularization of the European Society of Cardiology (ESC) and the European Association for Cardio-Thoracic Surgery (EACTS) developed with the special contribution of the European Association of Percutaneous Cardiovascular Interventions (EAPCI). *EuroIntervention*. 2015;10:1024–1094.
- Morrow DA, Gersh BJ, Braunwald E. Coronary Revascularization. In: Lemos J, Omland T eds. *Chronic Coronary Artery Disease*. 1st ed. Philadelphia, PA: Elsevier Saunders; 2017:228–233.
- Katritsis DG, Ioannidis JPA. Percutaneous coronary intervention versus conservative therapy in nonacute coronary artery disease. *Circulation*. 2005;111:2906–2912.
- Linden B. Guidelines on the management of stable coronary artery disease. *Brit J Cardiac Nurs*. 2013;8:519–520.
- Boden WE, O'Rourke RA, Teo KK, et al. Optimal medical therapy with or without PCI for stable coronary disease. *N Engl J Med*. 2007;356:1503–1516.
- Antoniucci D, Valenti R, Moschi G, et al. Relation between preintervention angiographic evidence of coronary collateral circulation and clinical and angiographic outcomes after primary angioplasty or stenting for acute myocardial infarction. *Am J Cardiol*. 2002;89:121–125.
- Garcia EV, Van Train K, Maddahi J, et al. Quantification of rotational thallium-201 myocardial tomography. *J Nucl Med*. 1985;26:17–26.
- Stauffer Lehman J, Novack P, Kasparian H, Likoff W, Perlmutter HI. Selective coronary arteriography. *Radiology*. 1964;83:846–853.
- Rentrop KP, Cohen M, Blanke H, Phillips RA. Changes in collateral channel filling immediately after controlled coronary artery occlusion by an angioplasty balloon in human subjects. *J Am Coll Cardiol*. 1985;5:587–592.
- Taneseu D. Apparent worsening of thallium-201 myocardial defects during redistribution-what does it mean? *J Nucl Med*. 1979;20:688.
- van Royen N, Piek JJ, Schaper W, Fulton WF. A critical review of clinical arteriogenesis research. *J Am Coll Cardiol*. 2009;55:17–25.
- Pace L, Perrone-Filardi P, Mainenti PP, et al. Effects of myocardial revascularization on regional thallium-201 uptake and systolic function in regions with reverse redistribution on tomographic thallium-201 imaging at rest in patients with chronic coronary artery disease. *J Nucl Cardiol*. 1998;5:153–160.

13. Shi H, Zhang X, Huang R, Chen S, Liu W, Ge J. Evaluation of therapeutic responses after stem cell implanted using thallium-201 myocardial perfusion imaging: reverse redistribution is a sign of good response? *J Nucl Med.* 2007;48:3P.
14. Seiler C, Billinger M, Fleisch M, Meier B. Washout collaterometry: a new method of assessing collaterals using angiographic contrast clearance during coronary occlusion. *Heart.* 2001;86:540–546.
15. Mauri L, Deepak L and Bhatt DL. Percutaneous Coronary Intervention. In: Zipes DP, ed. *Braunwald's Heart Disease: A Textbook of Cardiovascular Medicine.* 11th ed. Philadelphia, PA: Elsevier Saunders; 2018:1271–1294.
16. Antman EM, Loscalzo J. Ischemic Heart Disease. In: Kasper DL, ed. *Harrison's Principles of Internal Medicine.* 19th ed. New York, NY: McGraw-Hill Education; 2015:1578–1592.
17. Pijls NH, de Bruyne B, Peels K, et al. Measurement of fractional flow reserve to assess the functional severity of coronary-artery stenoses. *New Engl J Med.* 1996;334:1703–1708.
18. Pijls NH, van Schaardenburgh P, Manoharan G, et al. Percutaneous coronary intervention of functionally nonsignificant stenosis: 5-year follow-up of the DEFER study. *J Am Coll Cardiol.* 2007;49:2105–2111.
19. Tonino PA, De Bruyne B, Pijls NH, et al. Fractional flow reserve versus angiography for guiding percutaneous coronary intervention. *N Engl J Med.* 2009;360:213–224.
20. Pfisterer M. Long-term outcome in elderly patients with chronic angina managed invasively versus by optimized medical therapy. *Circulation.* 2004;110:1213–1218.
21. Pace L, Cuocolo A, Marzullo P, et al. Reverse redistribution in resting thallium-201 myocardial scintigraphy in chronic coronary artery disease: an index of myocardial viability. *J Nucl Cardiol.* 1995;2:S76.
22. Soufer R, Dey HM, Lawson AJ, Frans JT, Zaret BL. Relationship between reverse redistribution on planar thallium scintigraphy and regional myocardial viability: a correlative PET study. *J Nucl Med.* 1995;36:180–187.
23. Weiss AT, Maddahi J, Lew AS, et al. Reverse redistribution of thallium-201: a sign of nontransmural myocardial infarction with patency of the infarct-related coronary artery. *J Am Coll Cardiol.* 1986;7:61–67.
24. Strauss HW, Harrison K, Langan JK, Lebowitz E, Pitt B. Thallium-201 for myocardial imaging. Relation of thallium-201 to regional myocardial perfusion. *Circulation.* 1975;51:641–645.
25. Nudi F, Iskandrian AE, Schillaci O, Peruzzi M, Frati G, Biondi-Zoccai G. Diagnostic accuracy of myocardial perfusion imaging with CZT technology: systemic review and meta-analysis of comparison with invasive coronary angiography. *JACC Cardiovasc Imaging.* 2017;10:787–794.
26. Nudi F, Procaccini E, Versaci F, et al. Impact of coronary revascularization on the clinical and scintigraphic outlook of patients with myocardial ischemia. *J Cardiovasc Med.* 2017;18:404–409.
27. Nudi F, Di Belardino N, Versaci F, et al. Impact of coronary revascularization vs medical therapy on ischemia among stable patients with or suspected coronary artery disease undergoing serial myocardial perfusion scintigraphy. *J Nucl Cardiol.* 2017;24:1690–1698.