

4-3-2018

Spontaneous Heterotopic Pregnancy in Natural Conception: A Case Report

Muhammad Aziz

West Kendall Baptist Hospital, muhammada@baptisthealth.net

Cristina Dou

West Kendall Baptist Hospital, CristinaDo@baptisthealth.net

Julio Arronte

West Kendall Baptist Hospital, julioe.arronte@baptisthealth.net

Follow this and additional works at: <https://scholarlycommons.baptisthealth.net/se-all-publications>

Citation

Aziz, Muhammad; Dou, Cristina; and Arronte, Julio, "Spontaneous Heterotopic Pregnancy in Natural Conception: A Case Report" (2018). *All Publications*. 2754.

<https://scholarlycommons.baptisthealth.net/se-all-publications/2754>

This Conference Poster -- Open Access is brought to you for free and open access by Scholarly Commons @ Baptist Health South Florida. It has been accepted for inclusion in All Publications by an authorized administrator of Scholarly Commons @ Baptist Health South Florida. For more information, please contact Carrie@baptisthealth.net.

Authors: Muhammad Aziz, MD, MPH; Cristina Dou, MD; Julio Arronte, MD

Affiliations: Family Medicine Center, West Kendall Baptist Hospital, Miami, FL; West Kendall OBGYN, West Kendall Baptist Hospital, Miami, FL

INTRODUCTION

- ❖ Heterotopic pregnancy (HP) is the concurrent development of an intrauterine pregnancy and an ectopic pregnancy (1).
- ❖ It is associated with significant risk of maternal and fetal morbidity and mortality, it can even increase the maternal mortality risk up to 90 times greater than that of a normal intrauterine pregnancy when the ectopic is implanted in the abdomen (2, 3).
- ❖ The incidence of HP is not uncommon and it ranges from 1 in 30,000 pregnancies in natural conception cycles and can go up to 1 in 3900 pregnancies because of invent of assisted reproduction techniques (ART).
- ❖ Other risk factors include family history of multiple gestations, tubal disease, history of pelvic inflammatory disease, elevated female hormones, high numbers of transferred embryos, and technique of embryo transfer (4, 5).
- ❖ Current case is relatively rare case of heterotopic pregnancy in a patient with natural conception, who also reported a strong family history of multiple gestation pregnancies. Patient was born as a product of twin pregnancy as well.

CASE PRESENTATION

- ❖ 28 years old Hispanic White nonsmoker female with PMH of liposuction of abdomen and tonsillectomy, presented to ER with complaint of severe abdominal pain, dyspnea, chest pressure, chills, sweats, and pelvic pain.
- ❖ At presentation, patient stated that she is 7 weeks pregnant.
- ❖ Family history later explored was significant for multiple gestation in her grandmother, mother and her sister.
- ❖ Stat EKG, cardiac troponin and pancreatic function tests were negative. Quantitative hCG was 111,360.0 MIU/ML. Transvaginal ultrasound (TV US) showed HP as first gestational sac as 6 weeks 0 days and second gestational sac as right adnexal ectopic pregnancy at 7 weeks 3 days along with a corpus luteum cyst in left ovary.
- ❖ Ultrasound was repeated to confirm findings of Heterotopic pregnancy.
- ❖ Since this was a desired pregnancy, patient opted to preserve IUP despite risks and to proceed with removal of ruptured ectopic.
- ❖ Laparoscopy with right partial salpingectomy, lysis of adhesions and evacuation of hemoperitoneum was performed successfully. Uterus was not explored in order to keep IUP alive. The pathology report showed right fallopian tube with products of conception containing chorionic villi admixed with focally organizing blood clot, proteinaceous debris, scant mucin and blood consistent with tubal ectopic pregnancy.
- ❖ Patient was discharged home stable on post op day 1 with recommendation for next couple of days follow up with OB outpatient for her IUP.
- ❖ Patient had to visit ER again in next couple of days with c/o vaginal bleeding.
- ❖ Stat TV US confirmed abortion with no intrauterine cardiac activity.
- ❖ Dilatation and Curettage was performed and pathology report showed partly necrotic decidua, part of endometrium and chorionic villi consistent with missed abortion.

FIGURES

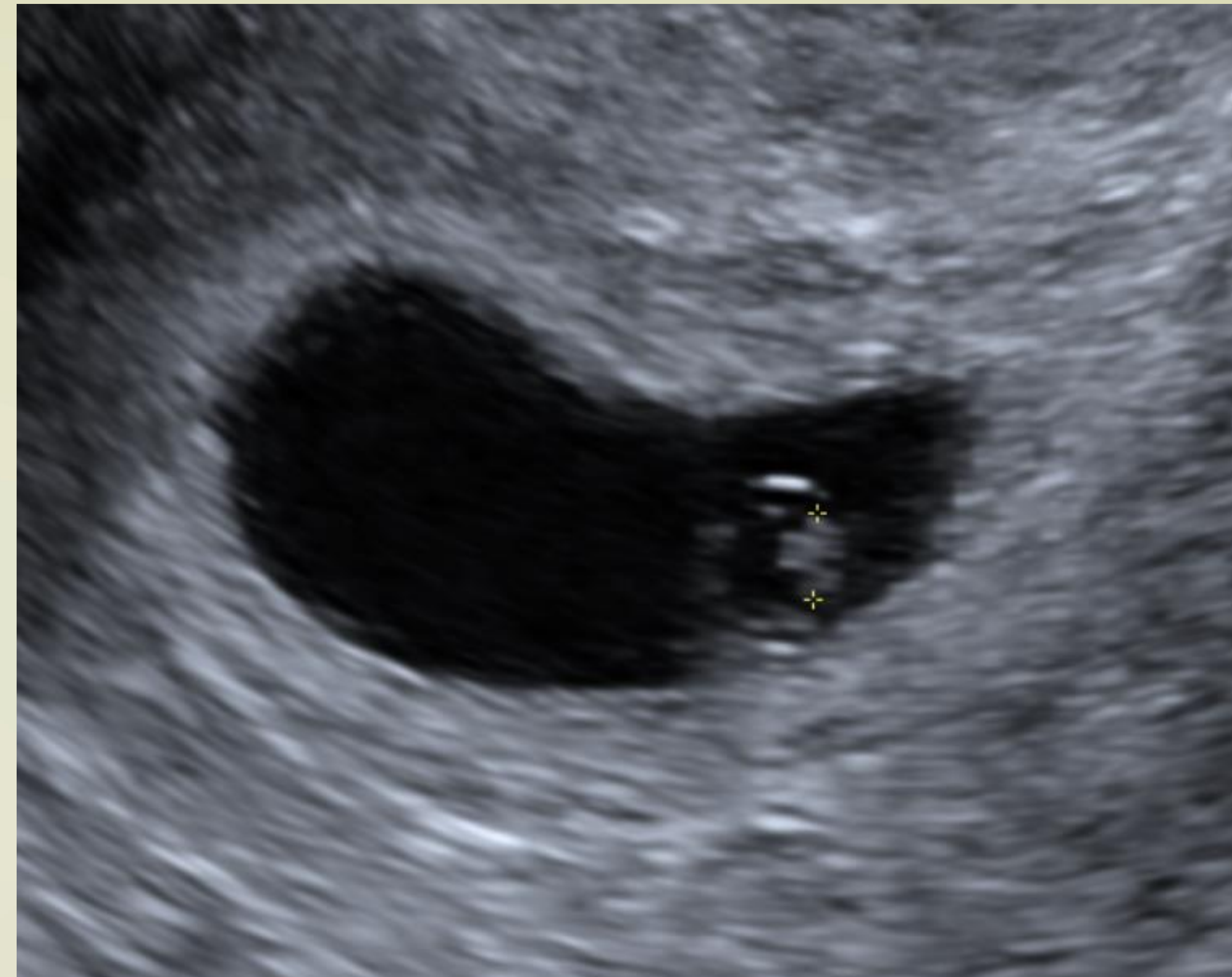

Fig 1. Uterus Trans

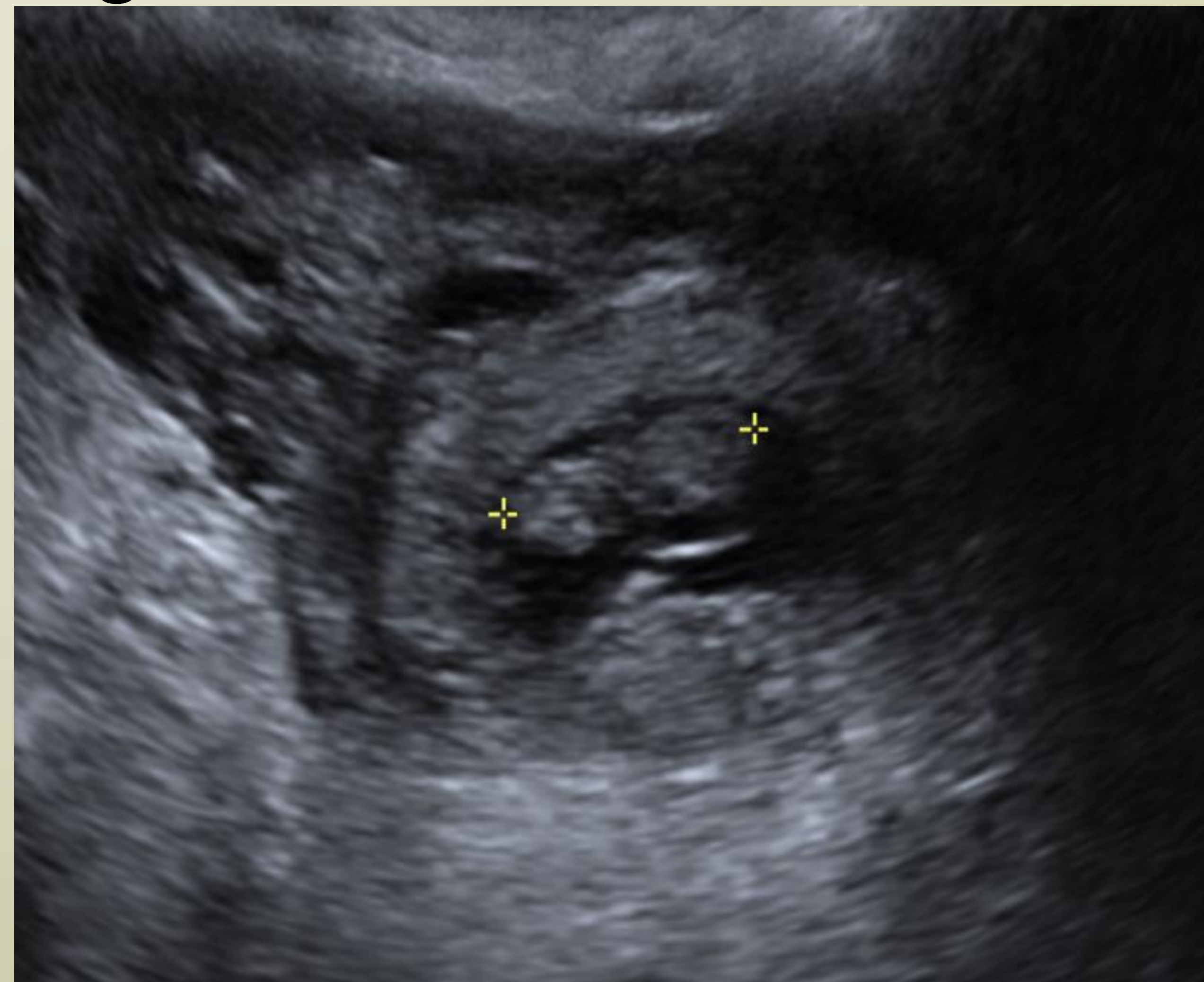


Fig. 2 Right Adnexa Trans

DISCUSSION

- ❖ HP poses unique therapeutic challenges, as its clinical presentation can easily be confused with other normal and abnormal pregnancy manifestations (2).
- ❖ A detailed history and physical examination is of crucial importance to explore all possible risk factors related to heterotopic pregnancy (4, 5).
- ❖ Management include least invasive therapy to remove tubal pregnancy and preserve the IUP as systemic medical therapy such as methotrexate is contraindicated in the presence of a viable IUP (7, 8).
- ❖ Although the incidence of HP has been increased tremendously over the last decade because of assisted reproduction techniques (ART), yet the other possible causes of HP should not be ignored in clinical practice (9, 10).
- ❖ Our case study patient did not seek any ART but patient reported a strong family history of multiple gestation pregnancies and also history of liposuction of abdomen.
- ❖ According to US statistics, about two-thirds of the increase in the twin birth rate in the last three decades is likely associated with assisted reproductive technology (ART) and non-ART infertility treatments and rest of one third could be related to other factors including family history of multiple gestation on father and mother side, use of hormones, diet, and race (11-12).
- ❖ Current study signifies the importance of collecting family history of multiple gestations in child bearing age women and counseling them accordingly regarding the potential benefits and risks of multiple gestations. The women with increased risk of multiple gestations need close monitoring and frequent prenatal visits for the pregnancy care.

IMPLICATIONS FOR PRACTICE

- ❖ Women with multiple gestations are at increased risk of complications and adverse pregnancy outcomes. This can have a significant psychosocial and economic impact on women and the families requiring emotional and psychological support.
- ❖ The role of a family physician can be crucial in alleviating such emotional burden and improving the quality of life in these women and families.

REFERENCES

1. Jeon JH, Hwang YI, Shin IH, Park CW, Yang KM, Kim HO. The Risk Factors and Pregnancy Outcomes of 48 Cases of Heterotopic Pregnancy from a Single Center. *J Korean Med Sci.* 2016;31(7):1094-9.
2. Siraj SHM, Wee-Stekly WW, Chern BSM. Heterotopic pregnancy in a natural conception cycle presenting as acute abdomen: A case report and literature review. *Gynecology and Minimally Invasive Therapy.* 2014;3(3):100-2.
3. Mihmanli V, Kilickaya A, Cetinkaya N, Karahisar G, Uctas H. Spontaneous Heterotopic Pregnancy Presenting with Hemoperitoneum. *J Emerg Med.* 2016;50(1):44-6.
4. Cheng PJ, Chueh HY, Qiu JT. Heterotopic pregnancy in a natural conception cycle presenting as hematometra. *Obstetrics and gynecology.* 2004;104(5 Pt 2):1195-8.
5. Farnaghi S, Kothari A. Heterotopic pregnancy: a report of two cases. *Australas J Ultrasound Med.* 162013. p. 30-6.
6. Clayton HB, Schieve LA, Peterson HB, Jamieson DJ, Reynolds MA, Wright VC. A comparison of heterotopic and intrauterine-only pregnancy outcomes after assisted reproductive technologies in the United States from 1999 to 2002. *Fertility and sterility.* 2007;87(2):303-9.
7. Louis-Sylvestre C, Morice P, Chapron C, Dubuisson JB. The role of laparoscopy in the diagnosis and management of heterotopic pregnancies. *Human reproduction (Oxford, England).* 1997;12(5):1100-2.
8. Sentilhes L, Bouet PE, Gromez A, Poilblanc M, Lefebvre-Lacoeuille C, Descamps P. Successful expectant management for a cornual heterotopic pregnancy. *Fertility and sterility.* 2009;91(3):934.e11-3.
9. Felekis T, Akrisis C, Tsirkas P, Korkontzelos I. Heterotopic Triplet Pregnancy after In Vitro Fertilization with Favorable Outcome of the Intrauterine Twin Pregnancy Subsequent to Surgical Treatment of the Tubal Pregnancy. *Case Reports in Obstetrics and Gynecology.* 2014;2014:356131.
10. Barrenetxea G, Barinaga-Rementeria L, Lopez de Larruzeta A, Agirregoikoa JA, Mandiola M, Carbonero K. Heterotopic pregnancy: two cases and a comparative review. *Fertility and sterility.* 2007;87(2):417.e9-15.
11. Martin JA, Hamilton BE, Osterman MJ. Three decades of twin births in the United States, 1980-2009. *NCHS data brief.* 2012(80):1-8.
12. Hoekstra C, Willemsen G, van Beijsterveldt TCEM, Montgomery GW, Boomsma DI. Familial Twinning and Fertility in Dutch Mothers of Twins. *American journal of medical genetics Part A.* 2008;146A(24):3147-56.