



PEDIATRIC UROLOGY CASE REPORTS

ISSN: 2148–2969

Journal homepage: <http://www.pediatricurologycasereports.com>

Holmium: yttrium-aluminum-garnet (Ho:YAG) laser for resection of bladder tumor in a pediatric patient

Suleyman Cakmakci, Necmettin Penbegul, Mehmet Mazhar Utangac, Mansur Daggulli, Onur Dede, Mehmet Nuri Bodakci, Ahmet Ali Sancaktutar, Yasar Bozkurt

Dicle University, School of Medicine, Department of Urology, Diyarbakir, Turkey

Abstract Bladder tumours are rare in children, with only 0.4% of cases occurring in the first 2 decades of life. Herein, a pediatric patient who underwent TUR-B with a holmium: yttrium-aluminum-garnet (Ho:YAG) laser is presented. Its histopathology was reported as urothelial papilloma.

Key Words Bladder tumor; pediatric; holmium laser; resection.

Copyright © 2015 [pediatricurologycasereports.com](http://www.pediatricurologycasereports.com).

Corresponding Author: Suleyman Cakmakci, M.D.

Medical Resident of Urology

Dicle University, School of Medicine

Department of Urology, Diyarbakir, Turkey

E-mail: suleymancakmakci@gmail.com

Accepted for publication: 28 Jun 2015

INTRODUCTION

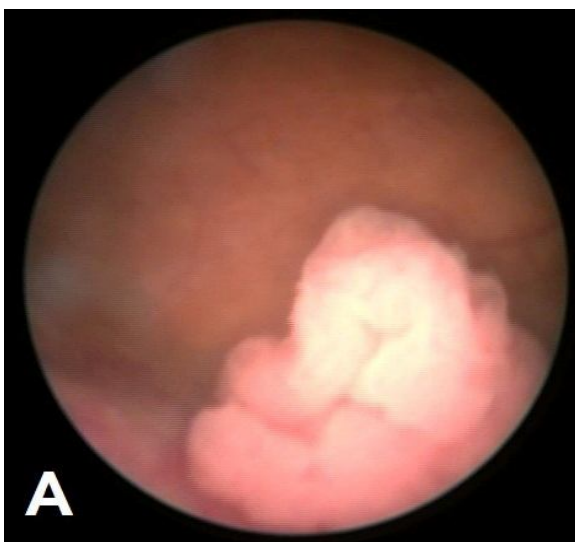
Bladder cancer is a disease that affects mostly the middle-aged or the elderly people, and is rarely encountered in the pediatric age group. In the first two decades

of life, its incidence has been reported as 0.1–0.4% [1-3]. For management of bladder cancer, transurethral resections of the bladder tumor (TUR-B) with a resectoscope loop or its various technical modifications are often used [4,5]. In recent years, various studies on effectiveness and safety of laser applications for the management of bladder tumors in adult patients have been published [6]. However, the use of laser for the resection of a bladder tumor in pediatric

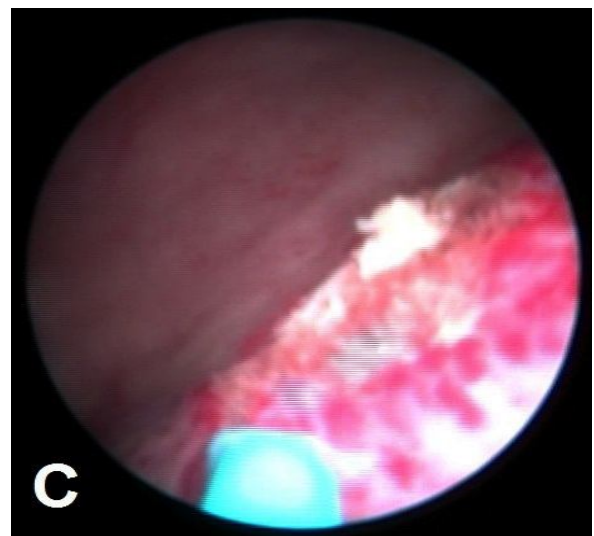
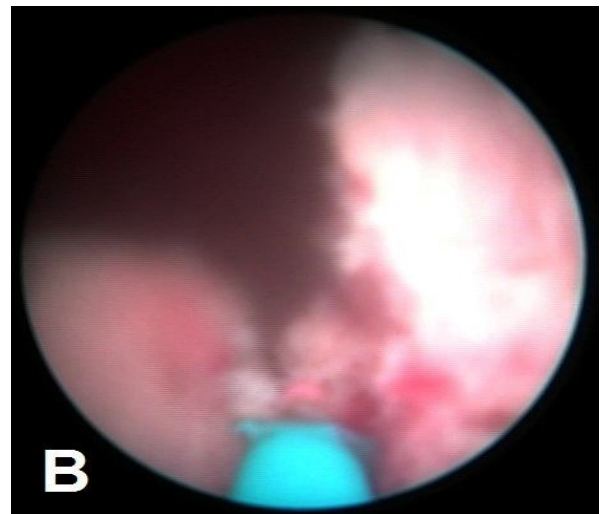
patients has not been cited in the medical literature until now. We report a pediatric patient with urothelial papilloma who underwent TUR-B with a holmium: yttrium-aluminum-garnet (Ho:YAG) laser.

CASE REPORT

A 12-year-old boy was admitted to our department because of painless gross hematuria for the last several days. His medical history did not reveal any evidence of exposure to a chemotherapeutic or chemical agent. As a result of physical examination and routine laboratory evaluations only an erythrocyturia was reported. There was absence of growth in the culture of urine specimens. An ultrasound (US) scan revealed a mass lesion on lateral wall of the bladder. A cystoscopy was performed under general anesthesia, and a pedunculated papillary lesion, 20x10x10 mm in diameter, was observed in the lateral localization of the left ureter (Fig. 1A).



During the operation, because of a sudden malfunction of the pediatric resectoscope, we had to proceed with laser resection. A 9.5 F pediatric cystoscope was inserted via a transurethral route into the bladder cavity, and the mass was completely resected from dome of the bladder, down to its base, using a 550 μ m Ho:YAG laser probe (Fig. 1B,C).



A cold punch biopsy was taken from the base of the mass. Its histopathology was reported as an urothelial papilloma, and the base of the lesion was tumor-negative. The

cystoscopic control examination was reported as normal 3 months after the operation (Fig. 1D).

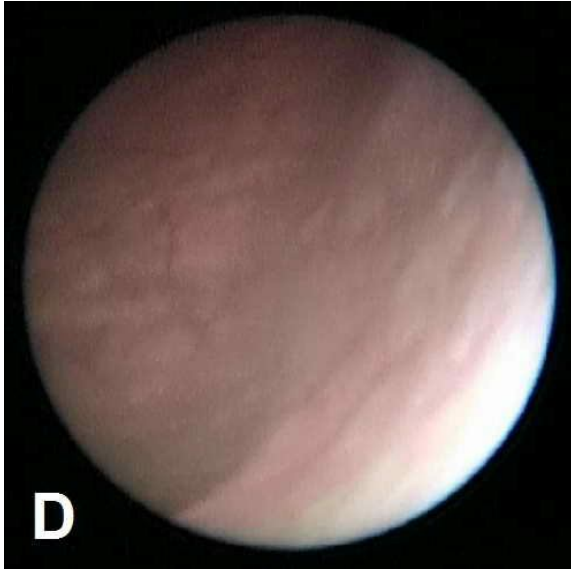


Fig. 1. (A) An endoscopic appearance of a papillary mass in the bladder. (B) A tumor resection with laser. (C) A fulguration of the base of the tumor. (D) Cystoscopic appearance of the intravesical cavity at the 3-month follow-up period.

DISCUSSION

Bladder cancer most commonly comes to medical attention in the 6th and 7th decades of life. [7,8]. The worldwide age standardized incidence rate is 10.1 per 100,000 for males and 2.5 per 100,000 for females [9]. Urothelial tumors in the first 2 decades of life are unusual, most of which have been described in case reports and small series [2,3]. Additionally, experience

with treatment of bladder tumor in childhood is limited because of its uncommon incidence [10].

As it is seen in adult patients, the admission complaint of gross hematuria is generally detected in the pediatric population [10]. This case was also seen with complaints of gross hematuria. In addition to the hematuria, according to the location of the mass, symptoms related to obstruction of the bladder outlet or ureteral orifice can be seen. Assessment of gross hematuria is included a urine culture, cytological evaluation of the urine, imaging of the kidneys, upper urinary tract and bladder and cystoscopy. Ultrasonography is generally the first examination to be performed in the clinical evaluation of gross hematuria for detection of bladder tumors because it is simple and safe for the cases. However, bladder tumors are usually diagnosed with cystoscopy. In cystoscopy, the gross appearance of the tumor can be evaluated (focal vs. multiple, flat vs. papillary and nodular), and a biopsy can be obtained from the tumor.

The most frequently used resection method is a TUR-B performed with a monopolar or bipolar resectoscope loop. Moreover, in current reports, especially in adult patients, potential use of the laser energy in TUR-B procedures has been stated [4-6]. Endoscopic holmium: yttrium-aluminum

garnet (Ho:YAG) laser incision is a new method, applied in pediatric urology in recent years. YAG laser irradiation has been preferred for treatment in the majority of pediatric patients with bladder hemangioma and it provides results superior to alternative therapy [11-14]. Takemoto et al [15] reported that a case of large bladder hemangioma, in an otherwise healthy 4-year-old boy, was successfully treated with serial endoscopic yttrium aluminium garnet laser irradiation. There was no recurrence, and normal bladder function was preserved. They suggested that serial yttrium aluminium garnet laser irradiation is thus a useful, less invasive method for cases with large tumors. In another pediatric study, Futao et al [16] have evaluated endoscopic holmium:yttrium-aluminum-garnet (Ho:YAG) laser's therapeutic effect on the treatment of pediatric patients with urethral strictures and urethral atresias. They suggested that with the advantages of safety, efficacy and minimal invasion; endoscopic Ho:YAG laser incision technique could be used as a primary treatment option in patients with urethral stricture. In this case, because of technical problems related to the resectoscope, a 550

µm laser probe was used. Endoscopic holmium: yttrium-aluminum-garnet (Ho:YAG) laser can be applied in-depth tissue resection, including safe surgical margins, which could allow a histopathologic evaluation.

In the pediatric population, hematuria can be a symptom of the bladder tumor. Therefore, in the relevant assessments, a mass lesion of the bladder should be kept in mind. For the selected pediatric cases, the use of laser energy for TUR-B can be an alternative to the standard procedures. Larger-scale studies should be conducted to be able to determine the effectiveness and safety of this method in detail.

Acknowledgements

The author(s) declare that they have no competing interests and financial support.

REFERENCES

1. Serrano-Durbá A, Domínguez-Hinarejos C, Reig-Ruiz C, Fernández-Córdoba M, García-Ibarra F. Transitional cell carcinoma of the bladder in children. *Scand J Urol Nephrol*. 1999;33(1):73-6.
2. Alanee S, Shukla AR. Bladder malignancies in children aged <18 years: results from the Surveillance, Epidemiology and End Results database. *BJU Int*. 2010;106(4):557-60.
3. Kutarski PW, Padwell A. Transitional cell carcinoma of the bladder in young adults. *Br J Urol*. 1993;72(5 Pt 2):749-55.
4. Muto G, Collura D, Giacobbe A, D'Urso L, Muto GL, Demarchi A, Coverlizza S, Castelli E. Thulium:yttrium-aluminum-garnet laser for en bloc resection of bladder cancer: clinical and histopathologic advantages. *Urology*. 2014;83(4):851-5.
5. Wilby D, Thomas K, Ray E, Chappell B, O'Brien T. Bladder cancer: new TUR techniques. *World J Urol*. 2009;27(3):309-12.
6. Kramer MW, Bach T, Wolters M, Imkamp F, Gross AJ, Kuczyk MA, Merseburger AS, Herrmann TR. Current evidence for transurethral laser therapy of non-muscle invasive bladder cancer. *World J Urol*. 2011;29(4):433-42.
7. Jemal A, Siegel R, Ward E, Hao Y, Xu J, Murray T, Thun MJ. Cancer statistics, 2008. *CA Cancer J Clin*. 2008;58(2):71-96.
8. Parkin DM. The global burden of urinary bladder cancer. *Scand J Urol Nephrol Suppl*. 2008;(218):12-20.
9. Ploeg M, Aben KK, Kiemeny LA. The present and future burden of urinary bladder cancer in the world. *World J Urol*. 2009;27(3):289-93.
10. Hoenig DM, McRae S, Chen SC, Diamond DA, Rabinowitz R, Caldamone AA. Transitional cell carcinoma of the bladder in the pediatric patient. *J Urol*. 1996;156(1):203-5.
11. Abdullaev FK, Nikolaev VV, Kulaev VD, Cherkashina EN. [Urinary bladder hemangiomas in children: experience with endoscopic treatment]. *Urologiia*. 2011;(1):46-9.
12. Kato M, Chiba Y, Sakai K, Orikasa S. Endoscopic neodymium:yttrium aluminium garnet (Nd:YAG) laser irradiation of a bladder hemangioma associated with Klippel-Weber syndrome. *Int J Urol*. 2000;7(4):145-8.
13. Vögeli TA, Peinemann F, Burdach S, Ackermann R. Urological treatment and clinical course of BK polyomavirus-associated hemorrhagic cystitis in children after bone marrow transplantation. *Eur Urol*. 1999;36(3):252-7.

14. Smith JA Jr. Laser treatment of bladder hemangioma. *J Urol.* 1990;143(2):282-4.
15. Takemoto J, Yamazaki Y, Sakai K. A case of large bladder hemangioma successfully treated with endoscopic yttrium aluminium garnet laser irradiation. *Int J Urol.* 2011;18(12):854-6.
16. Futao S, Wentong Z, Yan Z, Qingyu D, Aiwu L. Application of endoscopic Ho:YAG laser incision technique treating urethral strictures and urethral atresias in pediatric patients. *Pediatr Surg Int.* 2006;22(6):514-8.

Access this article online

<http://pediatricurologycasereports.com>

Quick Response Code

