



## Ectopic adrenal tissues at orchidopexy in children: A case series

Ibrahim Uygun, Erol Basuguy, Hikmet Zeytun, Serkan Arslan,  
Ugur Firat, Bahattin Aydogdu, Selcuk Otcu

**Abstract** Ectopic adrenal tissue is rare in children. Although its excision is recommended when found incidentally during inguinal surgical procedures, routine exploration is not indicated for the detection of its presence. Here, we present eight cases of ectopic adrenal tissue in pediatric patients who underwent orchidopexy.

**Key Words** Ectopic adrenal tissue; ectopic surrenal tissue; undescended testis; inguinal surgery.

© 2014 [pediatricurologycasereports.com](http://www.pediatricurologycasereports.com). All Rights Reserved

From the Department of Dicle University, Faculty of Medicine, Pediatric Surgery and Pediatric Urology and Pathology, Diyarbakir, Turkey. **Corresponding Author:** Ibrahim Uygun, MD, Associate Professor, Dicle University, Faculty of Medicine, Department of Pediatric Surgery and Pediatric Urology, 21280, Diyarbakir, Turkey.

E mail: [iuygun@hotmail.com](mailto:iuygun@hotmail.com)

This case series report is presented in 28<sup>th</sup> National Congress of Pediatric Surgery at 22-25 September 2010 in Antalya, Turkey.

Accepted for publication 22 October 2014

### INTRODUCTION

Ectopic adrenal tissue (EAT) is a rare pediatric abnormality that occurs when fragments of adrenal tissue separate and finally reside in locations other than their

origin. EAT can locate retroperitoneally from the diaphragm to the pelvis [1-8].

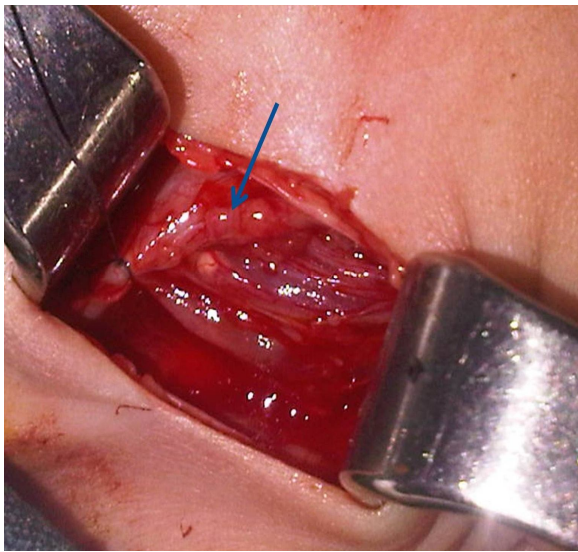
The aim of this study was to investigate the incidence of EAT in children who underwent inguinal surgical procedures.

### CASE REPORT

EAT were investigated in 1032 patients [867 males (84%) and 165 females (16%)] who underwent inguinal surgical procedures at Dumlupinar University Kutahya Evliya Celebi Training and Research Hospital,

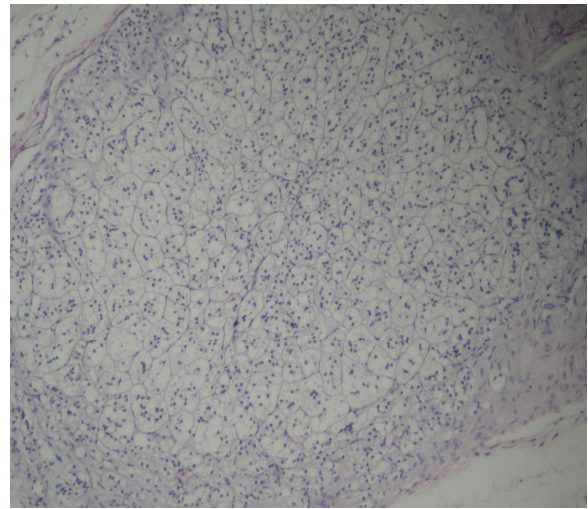
Kutahya, Turkey, and Dicle University Hospital, Diyarbakir, Turkey, between December 2004 and June 2010.

EAT was found in eight (0.7%) patients in 1170 inguinal surgical procedures [842 (72%) inguinal hernia or hydrocele, 328 (28%) undescended testes] (Fig. 1).



**Fig. 1.** A small, dark yellow nodule (arrow; ectopic adrenal tissue) found during orchidopexy.

All eight males were diagnosed as having undescended testes (%2.4). The mean age of these patients was 3.2 years (range 1–16 years). All of the small, dark yellow nodules (2–4 mm in size) were excised for histopathological confirmation of the diagnosis. Histological sections showed adrenal cortical tissue but no medullary tissue (Fig. 2).



**Fig. 2.** Histological sections of ectopic adrenal tissue showing adrenal cortical but not medullary tissue (H&E, ×100 magnification).

## DISCUSSION

EAT has been reported during inguinal exploration mainly for inguinal hernia and hydrocele or undescended testes. The incidence of EAT is 1–9.3% when it is detected incidentally in children, mostly among males. EAT has been found more often during orchidopexy than during the high ligation of an inguinal hernia, based on reported cases [1–8]. In our series, eight cases of EAT were detected during inguinal exploration. The eight males were undergoing orchidopexy, as typically reported in the literature.

EAT occurs mostly in males, and its occurrence rate is significantly higher in

those with undescended testes. The development of EAT may reflect the embryological events that take place during adrenal and gonadal growth, with its detection most often occurring during exploration of the inguinal canal and retroperitoneal region during orchidopexy rather than during a standard high ligation for inguinal hernia or hydrocele [1, 3, 6, 7]. Microscopically, inguinal EAT consists almost entirely of adrenal cortex and only

very rarely of medullary tissue [1–8]. Likewise, the EAT of our patients consisted only of adrenal cortex.

The excision of EAT is recommended when found incidentally during surgical procedures in the inguinal region in children, whereas routine exploration for the detection of EAT is not indicated.

#### **CONFLICT OF INTEREST**

**None declared.**

#### **REFERENCES**

1. Dobanovacki DS, Maric DM, Maric DL, Vuckovic N, Jokic RR, Slavkovic AR, et al. Ectopic adrenocortical tissue: an incidental finding during inguinal surgery in children. *Fetal Pediatr Pathol.* 2013;31 (1):32-7.
2. Iyengar V, Pittman DM. Ectopic adrenal gland tissue in inguinal hernia sac. *Ann Diagn Pathol.* 2007;11(4):291-2.
3. Ozel SK, Kazez A, Akpolat N. Presence of ectopic adrenocortical tissues in inguinoscrotal region suggests an association with undescended testis. *Pediatr Surg Int.* 2007;23(2):171-5.
4. Vaos G, Zavras N, Boukouvala I. Ectopic adrenocortical tissue along the inguinoscrotal path of children. *Int Surg.* 2006;91(3):125-8.
5. Mendez R, Tellado MG, Somoza I, Liras J, Sanchez-Abuin A, Pais E, Vela D. Ectopic adrenal tissue in the spermatic cord in pediatric patients: surgical implications. *Int Braz J Urol.* 2006;32(2):202-7.

6. Sullivan JG, Gohel M, Kinder RB. Ectopic adrenocortical tissue found at groin exploration in children: incidence in relation to diagnosis, age and sex. *BJU Int.* 2005;95(3):407-10.
7. Oguzkurt P, Oz S, Kayaselcuk F. Ectopic adrenal tissue: an incidental finding during inguinoscrotal operations in children. *Hernia.* 2002;6(2):62-3.
8. Okur H, Kucukaydin M, Kazez A, Kontas O. Ectopic adrenal tissue in the inguinal region in children. *Pediatr Pathol Lab Med.* 1995;15(5):763-7.