



## PEDIATRIC UROLOGY CASE REPORTS

ISSN:2148-2969

journal homepage: <http://www.pediatricurologycasereports.com>

## Ergonomic laparoscopic varicocele ligation: A case and technical report

Mete Kaya, Esra Ozcakir

**Abstract** The goal of surgical treatment of the varicocele is to occlude the refluxing venous drainage to the testis while maintaining normal testicular function. Many surgical techniques for treating varicoceles have been described. We aim to present an adolescent case with varicocele treated by simple laparoscopic ligation technique using intracorporeal knot-tying.

**Key Words** Laparoscopy; varicocele ligation; intracorporeal knot-tying.

© 2014 [pediatricurologycasereports.com](http://www.pediatricurologycasereports.com). All Rights Reserved

### Introduction

Many surgical and radiological techniques for treating varicoceles have been described, including open high or subinguinal ligation (microsurgical), laparoscopic methods and sclerotherapy [1,2,3].

There have many advantages of these methods to the others. Since 1988, when it was first described, high ligation of the spermatic veins by laparoscopy has become the preferred technique for surgical correction of varicocele in pediatric and adolescent patients [2,4].

We aimed to present our laparoscopic varicocele ligation technique using intra-corporeal knot-tying by available laparoscopic instruments.

*From the Department of Pediatric Surgery, Sevket Yilmaz Education and Research Hospital, Bursa, Turkey*

**Corresponding Author:**

*Mete Kaya, MD, Assoc. Prof.*

*Sevket Yilmaz Education and Research Hospital,*

*Department of Pediatric Surgery, Bursa, Turkey.*

*E-mail: [kayamete@yahoo.com](mailto:kayamete@yahoo.com)*

*Accepted for publication 25 February 2014*

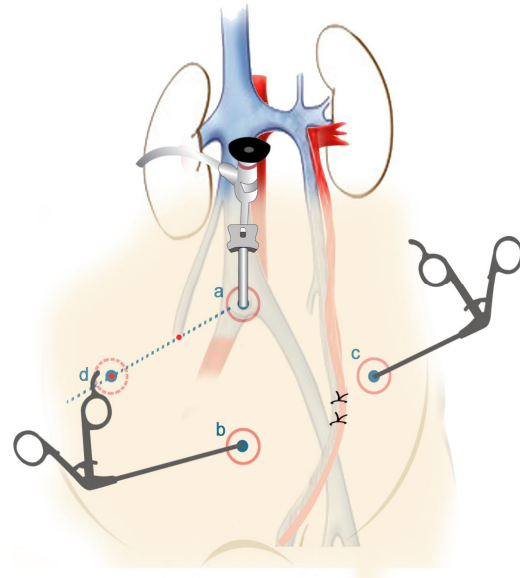
## Case Report

An 11 old boy admitted to our clinic with persistent left scrotal pain and swelling. On physical examination, varicose veins with valsalva meneuver were noted on left spermatic chord (grade 2). Color Doppler ultrasound examination revealed that spermatic vein is 3.9 mm in diameter, and retrograde reflux. Both testicular volumes were normal dimensions. Because of symptoms in the patient were persistent, we decided to treat varicocele surgically.

## Technique

Before the procedure, an antibiotic prophylaxis for patient with varicocele was made with single dose intravenous Cefazolin Sodium (25 mg/kg). After induction of general anesthesia, and a Verres needle was inserted into the peritoneum via infra-umbilical mini incision at the supine position. Then pneumoperitoneum was generated with CO<sub>2</sub> insufflations (10 – 12 mm Hg). A 5 –mm, trocar was inserted for 30<sup>0</sup> telescopes (Fig.1). Under direct vision, working trocars were placed at the midline suprapubic (3 mm) and left McBurney's point (3 mm) in the patients who have left varicocele. In cases with

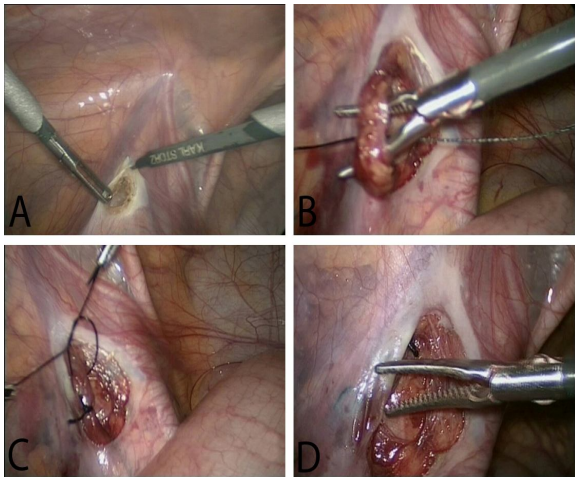
bilateral varicoceles, a 3mm trocar was placed at the right McBurney's point (Fig. 1).



**Fig. 1.** An illustration shows trocars. a. The 5 mm port inserted just below the umbilicus for direct vision with 30° camera. b. The first working trocar (3 mm) placed at the midline suprapubic area. c. The second one (3 mm) placed at left McBurney's (who have left varicocele). d. A 3 mm third trocar placed at the right McBurney's instead of b point in bilateral varicocele.

Subsequently, the patient was brought to a Trendelenburg position. After general inspection of the abdomen, a peritoneal window was made to expose the spermatic vascular bundle at 2 cm above the internal inguinal ring and on the median side of the spermatic vascular bundle (Fig. 2A). Blunt dissection was used to isolate

the whole spermatic bundle. No attempt was made to separate the testicular artery or adjacent lymphatics (Fig.2B). Then the spermatic bundle was elevated by dissectors and a free silk suture material about 8 – cm was inserted into the abdomen. Then the spermatic bundle was ligated at two points as a mass by silk sutures (Fig. 2C). At the end of the procedure, the veins were not divided. The nodes were hidden by pushing into the lateral retroperitoneal area (Fig. 2D).



**Fig. 2.** Figure shows the operation's steps. A. Creating a peritoneal window. B. Isolation of the spermatic vessels by blunt dissection without artery sparing. C. Double ligation of vascular bundle with intracorporeal knot-tying. D. Hiding the nodes into retroperitoneum.

Postoperative analgesics used by metamizole sodium of 8 – 16 mg / kg. Oral intake was started at third postoperative hour. Patient was discharged from hospital on same day.

Twenty patients were treated with this procedure. There were no intra-operative complication and the postoperative courses in all patients were uneventful. No recurrent varicocele or testicular atrophy was observed during follow-up period. Ethics approval was not needed because procedure was a part of standardized routine therapeutic workup, but informed consents were obtained from the parents.

### Discussion

Generally, treatment of varicocele is recommended for older patients only with proven infertility, clinical palpable varicocele, and abnormal semen parameters. In adolescents, however, some symptoms other than infertility such as testicular pain or scrotal mass could be an indication for varicocelectomy because these symptoms are frequently related to deterioration of testicular function [5].

Laparoscopic varicocele surgery was first performed Sanchez de Badajoz et al. [4] in 1988. The major advantage of the laparoscopic approach is that providing a direct and magnified view of the intra-abdominal structures, and allowing precise identification

and dissection [6]. Although, it was reported that laparoscopy is more expensive and of no proven benefit compared with open procedures, it is considered as a good alternative surgical procedure for the treatment of varicocele with reported benefits of convalescence, minimal invasive and less analgesic requirement [3,7,8]. In this presentation, we report a simple laparoscopic method and encouraging moderate-term clinical outcomes after treatment.

The advent of laparoscopic surgery has introduced various methods to ligate the varicose veins including electrocautery, endo clips, suture ligation and vessel sealing [1]. The surgeon preference, recurrence, complication rates and cost affects the most optimal technical approach [8]. In this present technique, the intracorporeal knot-tying with silk suture was used to ligate varicose veins in the boys with varicocele.

The main issue in laparoscopic varicocele surgery concerns the ligation of the artery and lymphatics. Several studies have found that mass ligation of the spermatic vessels (Palomo procedure) potentially carries the risk of testicular atrophy owing to artery ligation, and higher incidence of postoperative hydrocele due

to lymphatic ligation [9]. On the other hand, there has been reported that mass ligation of the spermatic vessels offers a safe method to achieve varicocelectomy without compromising the blood supply of the testis [1,3,7,10]. Additionally, the preservation of artery and lymphatic vessels of testis may help to avoid complications; attempts to preserve these vessels intimately attached to spermatic veins during laparoscopy may represent a large increase in surgical time, a high difficulty of the technique and a high risk of relapse due to small inadvertent preservation spermatic vessels that are left unknotted [2]. In the present method, the vascular mass was lifted and ligated without separating the arterial and lymphatic components from the veins. Our technique is not unique and several similar methods have been reported previously [11,12]. However, unlike others, we made no attempt to divide the vessels after ligation because of the risk of node slippage. In several studies, no transection after clipping or ligation was also reported [3,10].

The primary concern of the laparoscopic approach to varicocele has been the high associated cost and required expertise. The apparatus used for ligation, vessel sealing, endo

stapler and clips are expensive, and frequently require 10 mm working ports. In our technique, we performed varicocele ligation with silk suture using with 3 mm working trocar. One of the advantages of the intra-corporeal knot-tying with silk method does not require expensive materials or equipment for the ligation of varicous veins such as endoclips, ligasure, etc. The other is that procedure can be performed with available laparoscopic instruments [1]. Although, intra-corporeal knot-tying is difficult task in laparoscopic surgery, we thought that the tying could be performed when working ports placed appropriately.

Tissue reaction to silk suture is another critical issue in this method. In fact, the silk is non-absorbable, inexpensive and easy to handle as compared to other non-absorbable suture materials; the most marked tissue reaction is associated with this natural suture material. This problem was resolved by adjusting the position of nodes to the retroperitoneal area.

In conclusions, the most effective and least invasive method of varicocele treatment remains uncertain, but laparoscopic varicocele ligation using intracorporeal knot-tying is seen safe and effective with

good cosmetic outcomes, and it is a suitable procedure in pediatric and adolescent patients.

## CONFLICT OF INTEREST

**None declared.**

## References

1. Franco I. Laparoscopic varicolectomy in the adolescent male. *Curr Urol Rep.* 2004;5:132-136.
2. Mendez-Gallart R, Bautista Casasnovas A, Estevez Martinez E, Rodriquez-Barca P, Taboada Santomil P, Armas A. Reactive hydrocele after laparoscopic Palomo varicocele ligation in pediatrics. *Arch Esp Urol.* 2010;63:532-536.
3. Koyle MA, Oottamasathien S, Barqawi A, Rajimwale A, Furness PD 3rd. Laparoscopic palomo varicocele ligation in children and adolescents: Results of 103 cases. *J Urol.* 2004;172:1749-1752.
4. Sanchez de Badajoz E, Diaz Ramirez F, Marin Martin J. Endoscopic treatment of varicocele. *Arch Esp Urol.* 1988;41:15-16.
5. Choi WS, Kim SW. Current issues in varicocele management: A review. *World J Mens Health.* 2013;31:12-20.
6. Sihoe JD, Magsanoc N, Sreedhar B, Yeung CK. Laparoscopy in paediatric urology:

- Recent advances. *HKJ Pediatric (New Series)*. 2004;9:65-73.
7. Pini Prato A, MacKinlay GA. Is the laparoscopic Palomo procedure for pediatric varicocele safe and effective? Nine years of unicentric experience. *Surg Endosc*. 2006;20:660-664.
  8. Link BA, Kruska JD, Wong C, Kropp BP. Two trocar laparoscopic varicolectomy: Approache and outcomes. *JSLs*. 2006;10:151-154.
  9. Barroso U, Andrade DM, Novaes H, Netto JM, Andrade J. Surgical treatment of varicocele in children with open and laparoscopic palomo technique: A systematic review of the literature. *J Urol*. 2009;181:2724-2728.
  10. Barqawi A., Furness III P., Koyle M. Laparoscopic Palomo varicolectomy in the adolescent is safe after previous ipsilateral inguinal surgery. *BJU International*. 2002;89:269-272.
  11. Wu CC, Yang SS, Wang CC, Tsai YC. Mini-laparoscopic varicolectomy using a knot-tying technique: A preliminary report. *JTUA*. 2004;15:153-158.
  12. Chung SD, Wu CC, Lin VC, Ho CH, Yang SS, Tsai YC. Minilaparoscopic varicolectomy with preservation of testicular artery and lymphatic vessels by using intracorporeal knot-tying technique: Five-year experience. *World J Surg*. 2001;35:1785-1790.