




PEDIATRIC UROLOGY CASE REPORTS

ISSN 2148-2969

<http://www.pediatricurologycasereports.com>**Bladder dysfunction and urinary tract infection caused by abdominal pseudocyst with a ventriculoperitoneal shunt: A case report with literature review****Madoka Higuchi, Takeya Kitta, Yukiko Kanno, Masafumi Kon, Michiko Nakamura, Kimihiko Moriya, Nobuo Shinohara***Department of Renal and Genitourinary Surgery, Graduate School of Medical Science, Hokkaido University, Sapporo, Japan***ABSTRACT**

The lower urinary tract dysfunction of the neurogenic bladder often worsens owing to dysfunction of the bladder itself. We treated a patient with spina bifida who experienced bladder dysfunction that worsened owing to an abdominal pseudocyst that developed as a complication of a ventriculoperitoneal shunt. After removal of the pseudocyst, the urinary tract infection was controlled and bladder dysfunction was alleviated to a basal level.

Key Words: Hydrocephalus, spina bifida, ventriculoperitoneal shunt, abdominal pseudocyst, urinary tract infection.

Copyright © 2019 [pediatricurologycasereports.com](http://www.pediatricurologycasereports.com)

Correspondence: Dr. Takeya Kitta

*Department of Renal and Genitourinary Surgery,
Graduate School of Medical Science, Hokkaido
University, Sapporo, Japan.*

E mail: kitta@fb3.so-net.ne.jp

ORCID ID: <http://orcid.org/0000-0003-2870-9225>

Received 2019-06-05

Revisions 2019-07-14

Accepted 2019-07-23, Publication Date 2019-09-01

Introduction

Hydrocephalus is a common disorder in which insufficient drainage of cerebrospinal fluid (CSF) results in abnormal expansion of the cerebral ventricles, and its standard surgical treatment is CSF shunting. The common type of shunt is ventriculoperitoneal shunt (VPS). There are few abdominal complications with VPS. However, the abdominal pseudocyst is

observed infrequently [1-6]. Furthermore, there's no report that the bladder function had been worsened by the pseudocyst. We will report a case who suffered from urinary tract infection (UTI) caused by the abdominal pseudocyst, a complication of VPS.

Case report

A 12-year-old boy had a medical history of hydrocephalus and spina bifida. Soon after birth, he was implanted with a VPS and underwent spinal cord repair. At age 4 months, he was prescribed medication to treat a febrile UTI, after which the infection was controlled via intermittent catheterization administered by his mother. At age 12 years, he experienced a fever and hematuria and hence visited a pediatric clinic and was administered the

antibiotic cefditoren pivoxil orally. However, the high fever did not resolve, and he was admitted to the general hospital three days later and was diagnosed with a UTI. His hematological findings were as follows: WBC was $12,400/\mu\text{L}$, CRP was 19.2 mg/dL , and RBC was $492 \times 10^4/\mu\text{L}$. Urinalysis revealed leukocyturia with RBCs and bacteria even after administration of antibiotics. After admission, despite a change of antibiotic to sulbactam/ampicillin (intravenous administration for two days) later tazobactam/piperacillin (for four days), he suffered a fever spike over 38°C every evening. Therefore, he underwent a

computerized axial tomography (CAT) scan on the seventh hospital day. The CAT scan revealed a right hydronephrosis and an urinoma, and the bladder was compressed and its position within the abdomen shifted toward the right side as a complication of a pseudocyst that had formed around the ventriculoperitoneal shunt (Fig. 1a-d).

The fever subsided soon after the insertion of a urethral catheter, but the high fever relapsed after catheter removal. He was referred to our university hospital and was continued on intravenous antibiotics and a urethral catheter. He was subjected to a video-urodynamic study (UDS) every year routinely (Fig. 2-a).

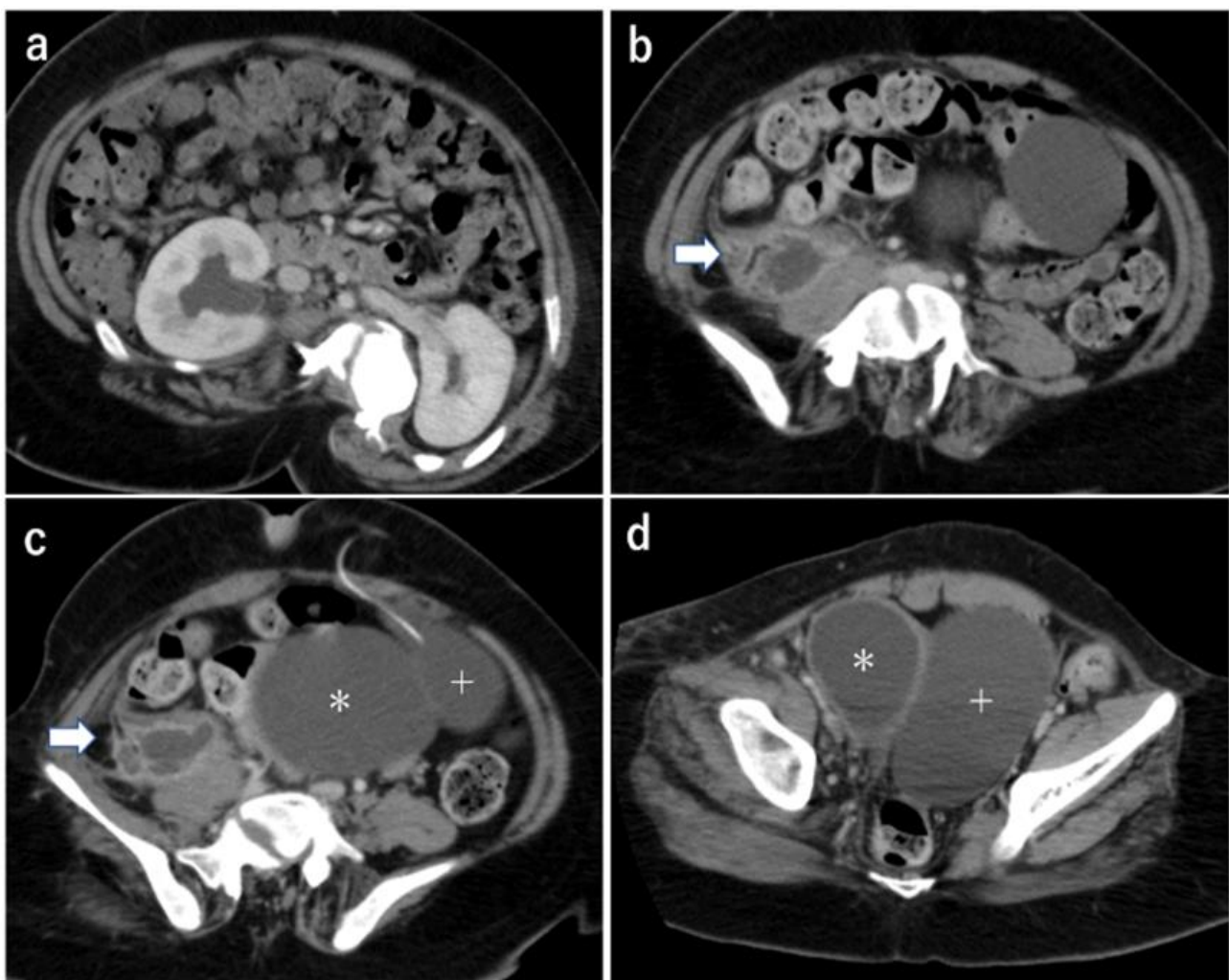


Fig. 1. CAT scan. **a:** CAT image showing a right hydronephrosis. **b:** Urinoma on the iliopsoas muscle (white arrow). **c, d:** Bladder (*) was compressed to the right side by a pseudocyst (+) that formed around the VPS.

Fortuitously, one month before the admission, as shown by the UDS, his bladder was shifted toward the right side, and the left vesicoureteral reflux newly emerged in 150 mL (Fig. 2-b), and Pdet (detrusor pressure) began to increase from 50 mL, which was worse than 1 year before (Fig. 3, 4).

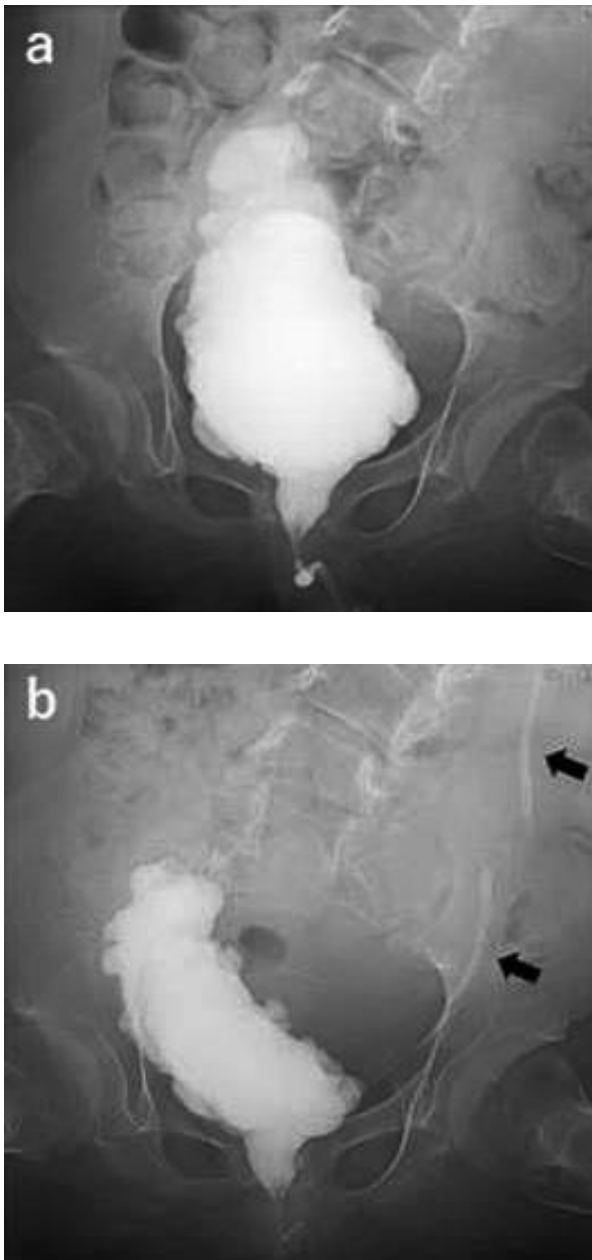


Fig. 2. View of the bladder deformity change. **a:** Image taken at 1 year before admission. **b:** Image taken at 1 month before admission. Bladder is shifted to the right, revealing a left vesicoureteral reflux (arrows).

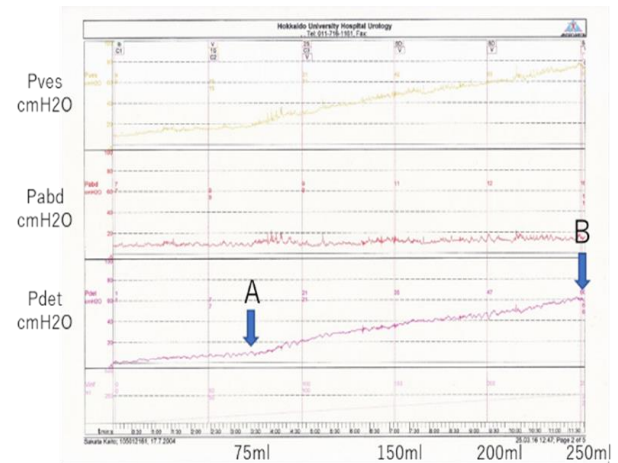


Fig. 3. Cystographic data acquired 1 year before admission. Pdet (detrusor pressure) increased from 75ml (arrow A). Bladder compliance was 47 cmH₂O at 200 mL, and there were no leakage or vesicoureteral reflux even at 250 mL insertion (Pdet, 61 cmH₂O, arrow B).

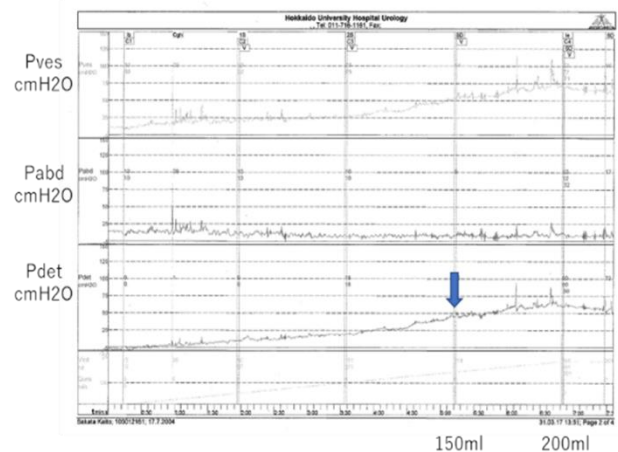


Fig. 4. Cystographic data acquired 1 month before admission; Pdet increased from 50 mL, and the left vesicoureteral reflux was revealed at 150 mL (arrow). Bladder compliance was 60 cmH₂O at 200 mL, and the abdominal leak point pressure was 70 cmH₂O at 200 mL.

Moreover, ALPP (abdominal leak point pressure) increased compared with the value determined by the previous UDS. At that time, no abnormality was detected in an abdominal ultrasonogram. We suspected that the pseudocyst had compressed the bladder and thereby compromised bladder compliance.

There seemed to be no obstruction of the shunt catheter because the hydrocephalus had not worsened.

We consulted a neurosurgeon concerning treatment of the pseudocyst. At first, they tried to relocate VPS on upper surface of the liver. However, the adhesion of peritoneum and intestinal tracts were so strong that they could not perform surgical procedure to the abdominal cavity by transabdominal approach. Therefore, the shunt was cut off at the level of precordia, and 600ml of CSF was absorbed from the pseudocyst. And then, new shunt tube was relocated to the left upper space of the abdominal cavity, but the space was not enough for drainage. Finally, the shunt was once located to an external position at the first operation, nine days after the first procedure, again relocated as a ventricular-arterial coupling.

Fourteen days after pseudocystectomy, the patient restarted the intermittent catheterization, and there was no recurrence of UTI. The UDS revealed that the bladder location was back to center position, and the vesicoureteral reflux disappeared (Fig. 5).

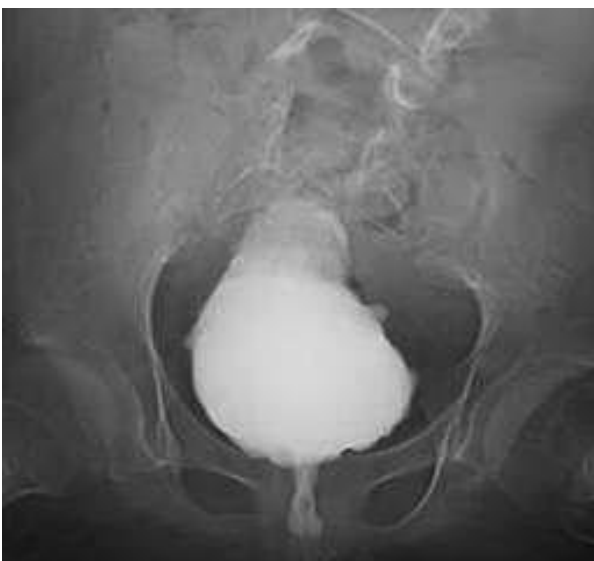

Fig. 5. After pseudocystectomy, the bladder relocated to the center position, and the vesicoureteral reflux disappeared.

The increase in Pdet was more gradual than pre-operation, and the ALPP decreased from 70 to 22 cmH₂O at 200 mL (Fig. 6).

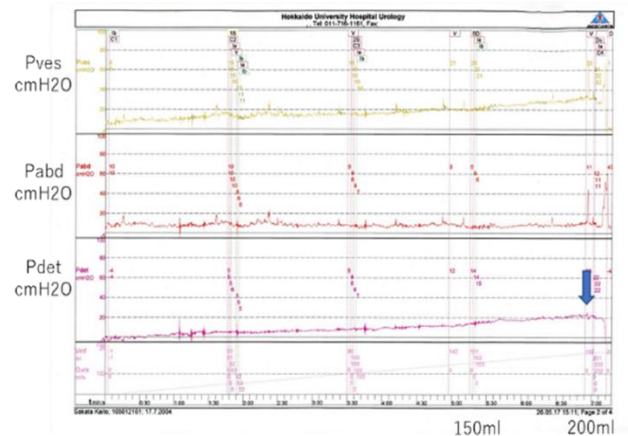


Fig. 6. After pseudocystectomy, Pdet increased more gradually than before the operation. Bladder compliance was 22 cmH₂O at 200 mL, and the detrusor leak point pressure was 22 cmH₂O at 200 mL (arrow).

One year after the admission, there was no recurrence of the pseudocyst or febrile UTI.

Discussion

Spina bifida is a consequence of incomplete neural-tube closure during the first trimester of embryonic development and manifests as a vertebral-column defect [1, 2]. Spina bifida subtypes, such as myelomeningocele, meningocele, myelocele, lipomeningocele and lipiomyelomeningocele, can be attributed to an extrusion. Most patients with spina bifida have a neurogenic bladder and require urinary management. A neurogenic bladder is a dysfunction of the constriction and extension of the bladder and leads to increased bladder pressure. Poor bladder compliance accounts for incontinence, secondary vesicoureteral reflux, and pyelonephritis, and it might lead to kidney dysfunction. The management of a neurogenic bladder involves keeping the bladder at low pressure and maintaining

urinary continence, which prevents febrile UTI and kidney dysfunction. Lower urinary tract management and history of urological surgery varied among age groups. However, regardless of the spina bifida subtype, the final goal of the management is the same, i.e., to prevent febrile UTI and kidney dysfunction. Conversely, a neurogenic bladder often worsens owing to dysfunction of the bladder itself, so most urologists do not confirm the external anatomical status.

On the other hand, hydrocephalus is a common disorder in which insufficient drainage of CSF results in abnormal expansion of the cerebral ventricles [3]. Treatment options include a shunt and endoscopic approaches based on the medical status of the individual child.

The standard surgical treatment for hydrocephalus is CSF shunting. The most common type of shunt is the VPS, which diverts CSF from the ventricles to the peritoneal cavity, although other distal sites such as the right atrium of the heart and the pleural cavity are occasionally used. Although there are few abdominal complications with VPS, complications associated with the distal part of the shunt include fracture of the device itself, shunt migration, disconnection or obstruction, ascites, abdominal pseudocyst (AP), and visceral perforation [4, 5, 6, 7]. AP is observed infrequently, with an incidence of 1–4.5% of shunt cases [8, 9, 10], and only a few cases have been reported. *Fisher EG et al.* reported that most cases of shunt-related AP develop within 6 months after installation of the VPS. AP is mostly diagnosed as a complication of neurologic symptoms owing to elevated intracranial pressure, i.e., mainly headache, nausea, and vomiting in children, whereas adults more often present with abdominal symptoms [11]. However, most cases are asymptomatic. There are reports of

VPS- or AP-associated infection, but there are no reports of an AP triggering a UTI or functional deterioration [12, 13]. The main risk factors for AP are peritoneal adhesion resulting from shunt-related infection, abdominal surgery, or shunt exchange, and chronic inflammation caused by the shunt tube or the accumulation of CSF-derived protein in the peritoneal cavity, among other factors. However, the cause is not readily apparent in most cases. Treatment of AP includes repositioning the distal catheter in a different abdominal quadrant, shunt removal, external ventricular drainage, and/or conversion to either a ventriculoatrial or ventriculopleural shunt [12]. In 1995, *Kim et al.* reported the laparoscopic management of AP [14].

The case we report here involved a VPS-related AP that compressed the bladder and deteriorated the bladder compliance, leading to a UTI. Notably, however, there have been no reports that an AP could trigger a UTI. In our case, the bladder neck was wide open as determined by cystography (Fig. 2-b), but Pdet gradually increased from the early phase, and there was an elevated ALPP and left vesicoureteral reflux. In the CAT scan, it seems that the AP not only compressed the bladder from the side but also enlarged so as to encompass the backside of the bladder and thereby compressed the urethra (Fig. 1-d). We speculate that the urethra was constricted and thus caused the bladder pressure increased.

Patients who suffer with both spina bifida and hydrocephalus is not so uncommon. There are many cases that urologists treat the bladder dysfunction in these patients. We should know the complication of VPS, especially of which might affect the bladder function.

Compliance with ethical statements

Conflicts of Interest: None.

Financial disclosure: None.

Consent: All photos were taken with parental consent.

References

- [1] Chan YY, Sandlin SK, Kurzrock EA. Urological outcomes of myelomeningocele and lipomeningocele. *Curr Urol Rep.* 2017;18(5):35.
- [2] Grau DC, Chiang G. Evaluation and lifetime management of the urinary tract in patients with myelomeningocele. *Urol Clin N Am.* 2017;44(3):391-401.
- [3] Kahle KT, Kulkarni AV, Limbrick DD, Warf BC. Hydrocephalus in children. *Lancet.* 2016;387(10020):788-99.
- [4] Martin K, Baird R, Farmer PJ, Emil S, Laberge JM, Shaw K, et al. The use of laparoscopy in ventriculoperitoneal shunt revisions. *J Pediatr Surg.* 2011;46(11):2146-50.
- [5] Browd SR, Ragel BT, Gottfried ON, Kestle JRW. Failure of cerebrospinal fluid shunts: part I: obstruction and mechanical failure. *Pediatr Neurol.* 2006;34(2):83-92.
- [6] Browd SR, Gottfried ON, Ragel BT, Kestle JRW. Failure of cerebrospinal fluid shunts: part II: overdrainage, loculation, and abdominal complications. *Pediatr Neurol.* 2006;34(3):171-76.
- [7] Sebastian M, Sebastian A, Sroczyński M, Rudnicki J. Laparoscopic management of abdominal pseudocyst following ventriculoperitoneal shunt implantation in hydrocephalus. *Wideochir Inne Tech Maloinwazyjne.* 2018; 13(2): 260–65.
- [8] Ayan E, Tanriverdi HI, Caliskan T, Senel U, Karaarslan N. Intraabdominal pseudocyst developed after ventriculoperitoneal shunt: a case report. *J Clin Diagn Res.* 2015; 9(6): PD05-06.
- [9] Yuh SJ, Vassilyadi M. Management of abdominal pseudocyst in shunt-dependent hydrocephalus. *Surg Neurol Int.* 2012;3:146.
- [10] Ohba S, Kinoshita Y, Tsutsui M, Nakagawa T, Shimizu K, Takahashi T, et al. Formation of abdominal cerebrospinal fluid pseudocyst. *Neurol Med Chir (Tokyo).* 2012;52(11):838-42.
- [11] Fischer EG, Shillito J Jr. Large abdominal cysts: a complication of peritoneal shunts. Report of three cases. *J Neurosurg.* 1969;31(4):441-44.
- [12] Hamid R, Baba AA, Bhat NA, Mufti G, Mir YA, Sajad W. Post ventriculoperitoneal shunt abdominal pseudocyst: challenges posed in management. *Asian J Neurosurg.* 2017;12(1):13-16.
- [13] Salomão JF, Leibinger RD. Abdominal pseudocysts complicating CSF shunting in infants and children. Report of 18 cases. *Pediatr Neurosurg.* 1999;31(5):274-78.
- [14] Kim HB, Raghavendran K, Kleinhaus S. Management of an abdominal cerebrospinal fluid pseudocyst using laparoscopic techniques. *Surg Laparosc Endosc.* 1995;5(2):151-54.

Access this article online

<http://pediatricurologycasereports.com>

Quick Response Code

