

Clinical report

Combined therapy of dexamethasone and indomethacin for patent ductus arteriosus in two premature infants

Hiroki ISHI, Takeshi TAKAMI, Satoshi SATO, Atsushi KONDO
Daisuke SUNOHARA, Akinori HOSHIKA

Department of Pediatrics, Tokyo Medical University

Abstract

In 2 premature infants with patent ductus arteriosus (PDA), indomethacin was discontinued because of renal failure in one and repeated re-opening of the ductus arteriosus in the other. Combined administration of low doses of dexamethasone and indomethacin resulted in complete closure of the PDA in both infants without serious side effects. This method of combined therapy may be an option in the medical management of PDA before considering surgical treatment, especially in premature infants when the PDA fails to close with indomethacin alone or when there are adverse side effects of indomethacin.

Introduction

Indomethacin has been widely used to close patent ductus arteriosus (PDA) in premature infants. The dose administered in Japan in general depends upon age : 0.1-0.2 mg/kg within the first 2 days of life ; 0.2-0.25 mg/kg from day 2 to day 7 ; 0.25 mg/kg after day 7. When these doses are administered at intervals from 12-24 hours, indomethacin is usually effective in closing the PDA ; however, there are some adverse side effects, such as renal failure, active bleeding and thrombocytopenia, but the PDA may fail to close in some cases (1). To find a better treatment for PDA, we tried combination therapy with low doses of both dexamethasone and indomethacin in two premature infants.

Case report

Case 1

A female infant was born at 34 weeks and 5 days of

gestation by emergency cesarean section with a birth weight of 1,520 g. The Apgar scores were 4 and 6 at 1 and 5 minutes, respectively. She received oxygen therapy with FiO_2 0.3 because of tachypnea. Her respiratory condition improved gradually, but the condition showed exacerbation again at the age of 3 days. She was transferred to the neonatal intensive care unit of our university hospital 2 days later. A grade 2/6 diastolic murmur was present and the chest X-ray showed a cardiothoracic ratio of 67% upon admission. A large PDA, mitral regurgitation and tricuspid regurgitation were diagnosed by echocardiography (Fig. 1-A,B). Fluids were restricted and diuretic therapy was given. She was treated with indomethacin at a dose of 0.2 mg/kg at 7 days of age and 0.25 mg/kg at 8 days. Slight constriction of the PDA was confirmed by echocardiography, but indomethacin was contraindicated because of occult blood in the urine and elevated serum creatinine to 2.5 mg/dl. The diastolic murmur and cardiomegaly on the

Received April 25, 2012, Accepted August 10, 2012

Key words : Patent ductus arteriosus (PDA), Indomethacin, Dexamethasone

Corresponding author : Hiroki Ishii, M.D., Department of Pediatrics, Tokyo Medical University, 6-7-1, Nishi-shinjuku, Shinjuku-ku, Tokyo, 160-0023, JAPAN

TEL : +81-3-3342-6111 FAX : +81-3-3344-0643 E-mail : h-ishii@tokyo-med.ac.jp

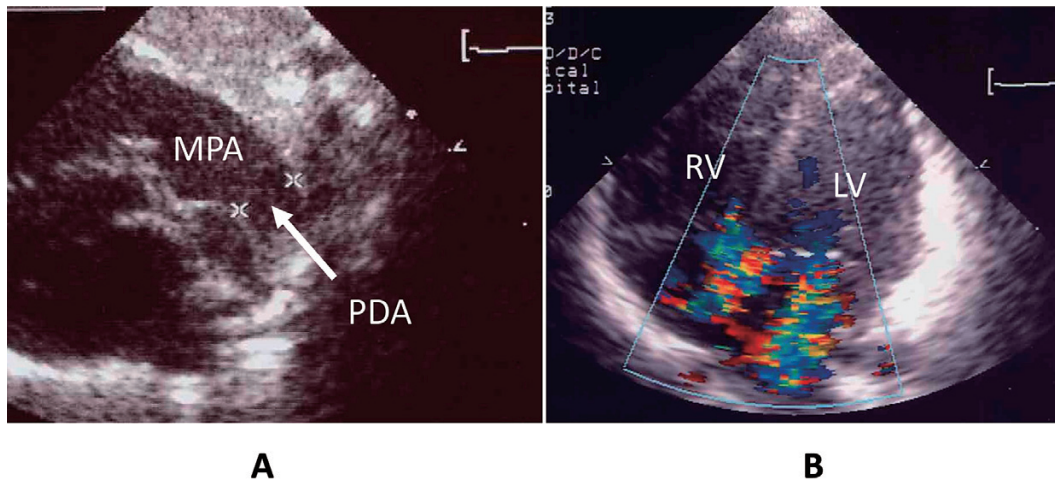


Figure 1 A large PDA (A), mitral regurgitation and tricuspid regurgitation (B) were diagnosed at 5 days of age by echocardiography

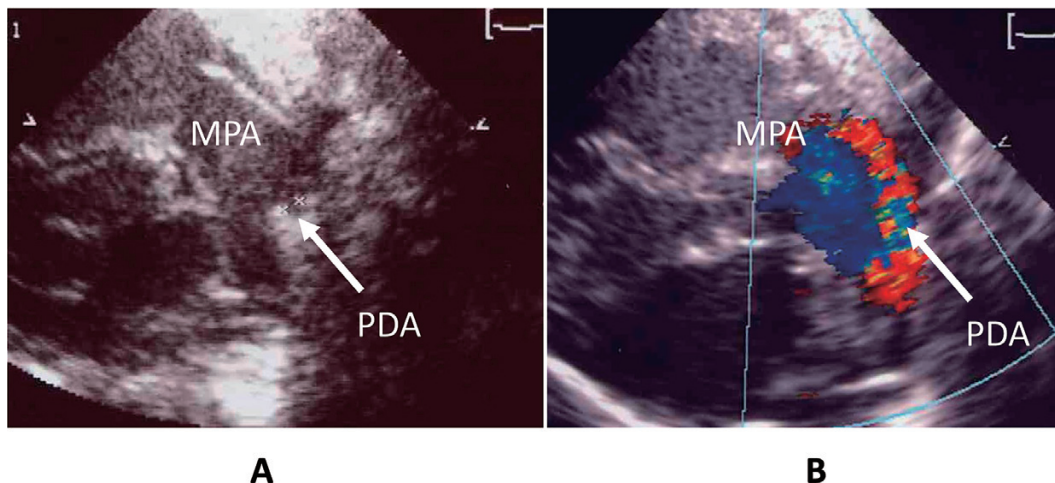


Figure 2 The constriction of PDA was observed at 12 days of age by echocardiography (A, B)

chest X-ray film persisted. After informed consent was obtained, administration of low doses of dexamethasone (0.3 mg/kg/day \times 3, 0.2 mg/kg/day \times 3, 0.1 mg/kg/day \times 3 ; divided into two daily doses) was given from 9 to 18 days of age. Since we confirmed the constriction of PDA at 12 days of age (Fig. 2-A,B), we decided to start the combined therapy. After the serum creatinine decreased to 1.05 mg/dl, low doses of indomethacin (0.1 mg/kg \times 5, at 12 hour intervals) were given from 12 to 15 days of age. During the course of therapy, serum creatinine did not exceed 1.0 mg/dl after administration of indomethacin (0.1 mg/kg) and no other severe side effects of indomethacin appeared.

Case 2

A female infant was born at 27 weeks and 2 days of gestation by emergency cesarean section because of premature rupture of membranes and threatened premature birth. Her birth weight was 1,163 g and the Apgar score was 6 at 1 minute. She received mechanical ventilation but no respiratory distress syndrome (RDS) was detected.

Chorioamnionitis was confirmed by histological examination. Laboratory examinations revealed plasma immunoglobulin M (IgM) of 59.0 mg/dl upon admission. The chest X-ray film showed diffuse and streaky infiltrate with a small cystic area from 2 days after birth. We suspected Wilson-Mikity syndrome from the clinical symptoms and laboratory findings. The PDA was closed as confirmed by echocardiography at 4 days. On day 20 of life, the chest X-ray showed atelectasis of the right upper lobe with infection sign, C-reactive protein 3.6 mg/dl, and a heart murmur appeared. PDA was diagnosed by echocardiography and she was treated successfully with indomethacin (0.25 mg/kg \times 1). At 24 days of age, the PDA re-opened and she was given indomethacin (0.25 mg/kg \times 2) and the PDA closed. At 28 days of age, the heart murmur was present again, PDA was diagnosed by echocardiography, and indomethacin (0.25 mg/kg \times 3) was given, followed by disappearance of the murmur. However, the PDA opened again at 35 days of age. After informed consent was obtained, combined administration of dexametha-

sone and indomethacin was given intravenously. Dexamethasone (0.3 mg/kg/day \times 3, 0.2 mg/kg/day \times 3, 0.1 mg/kg/day \times 3; divided into two daily doses) was started from 37 days of age and indomethacin (0.2 mg/kg \times 5) was given from 39 days of age. The PDA was closed, as confirmed by echocardiography, at 44 days and she was successfully extubated the following day. The PDA did not re-open after that time. Transient oliguria and hypertension were recognized during the course but there were no severe side effects of indomethacin such as active bleeding.

Discussion

Steroid hormones constricted the fetal PDA dose-dependently in fetal rats (2). Although the mechanism of steroid hormones in constricting the PDA is not completely clear, Clyman et al showed that transplacental hydrocortisone decreased the sensitivity of the ductal muscle to the dilative effects of prostaglandin (PG) E₂ in fetal lambs (3). Flower et al and Kuehl et al also reported that steroids could possibly have a direct effect on the PDA, leading to closure through interference with PG synthesis (4, 5). Clinically, Heyman et al reported 4 cases showing a temporal relationship between closure of the PDA and treatment with postnatal dexamethasone (0.4–0.5 mg/kg/day) given to preterm infants less than 1,000 g at birth (6). Furthermore, Morales et al demonstrated that in dexamethasone therapy the most common dosage regimen is 0.5 mg/kg/day divided into two daily doses tapered over a period of 12 days for surfactant-treated infants reduced the incidence of clinically detectable PDA and of bronchopulmonary dysplasia in premature infants as compared with infants treated with surfactant alone (7). They suggested that the clinical mechanism of PDA closure in dexamethasone-treated infants may in part have been related to diuresis. On the other hand, Watterberg et al showed that lower serum cortisol concentrations in very low birth weight infants correlated with the presence of PDA (8). This means that increased endogenous cortisol production in premature infant may promote ductal constriction, resulting in a decreased incidence of PDA.

We demonstrated greater constriction of the fetal PDA with the combined administration of dexamethasone and indomethacin than with dexamethasone or indomethacin alone in preterm and near-term fetal rats (9). In this clinical report, 2 cases showed the usefulness of combined therapy with dexamethasone and indomethacin. In case 1, the PDA was closed completely in combination with smaller doses of both dexamethasone and indomethacin without renal failure. In this infant, indomethacin was contraindicated after administration of two standard doses because of renal failure with occult blood in the urine and elevated serum creatinine. We tried to

administer a low dose of dexamethasone before having to consider surgical treatment, and the constriction of PDA was confirmed. We decided to start combined therapy. In case 2, combined administration of smaller doses of both dexamethasone and indomethacin showed greater constriction of the PDA in a premature infant in whom indomethacin therapy was discontinued because of repeated PDA re-opening. In these 2 premature infants, combined administration of smaller doses of both dexamethasone and indomethacin showed synergistic constriction of the PDA.

Recently, there is increasing concern that early and moderately-early postnatal corticosteroid therapy may have adverse effects on neurodevelopment (10). Stark et al showed that gastrointestinal perforations were increased in infants with extremely low birth weight < 1,000 g when dexamethasone was given with indomethacin within 24 hours of birth (11). Since prostaglandins play an important role in maintaining gastrointestinal integrity, inhibition of prostaglandin synthesis by corticosteroid and indomethacin may account for the gastrointestinal perforation. Therefore, administration of steroids under these conditions should be done carefully with reduced doses that are gradually tapered.

We suggest that combined therapy with smaller doses of both dexamethasone and indomethacin may be useful in constricting PDA when indomethacin alone is contraindicated due to side effects such as renal failure, active bleeding and thrombocytopenia. This combined therapy may also be useful when indomethacin alone fails to close the PDA, especially in premature infants weighing more than 1,000 g at birth, except in the early treatment of PDA in some cases before considering surgical treatment. Moreover, since hydrocortisone has less side effects than dexamethasone, it also might be useful for combined therapy with indomethacin. Further clinical studies are necessary to evaluate the long-term risks and benefits of combined therapy in neonates.

References

- 1) Papageorgiou A, Bardin CL. The extremely-low-birth weight infant. In: Avery GB, Fletcher MA, MacDonald MG. Neonatology 5th ed. Philadelphia, Lippincott Williams & Wilkins, Inc; 1999: 445–472
- 2) Momma K, Nishihara S, Ota Y. Constriction of the fetal ductus arteriosus by glucocorticoid hormones. *Pediatr Res* 1981; **15**: 19–21
- 3) Clyman RI, Mauray F, Roman C, Rudolph AM. Glucocorticoids after the sensitivity of the ductus arteriosus to prostaglandin E₂. *J Pediatr* 1981; **98**: 126–128
- 4) Flower DJ, Blackwell GJ. Anti-inflammatory steroid induce biosynthesis of a phospholipase A₂ inhibi-

- tor which prevents prostaglandin generation. *Nature* 1979 ; **278** : 456-459
- 5) Kuehl FA, Egan RW. Prostaglandins, arachidonic acid, and inflammation. *Science* 1980 ; **210** : 978-984
 - 6) Heyman E, Ohlsson A, Shennan AT, Heilbut M, Coceani F. Closure of patent ductus arteriosus after treatment with dexamethasone. *Acta Paediatr Scand* 1990 ; **79** : 698-700
 - 7) Morales P, Rastogi A, Bez ML, et al. Effect of dexamethasone therapy on the neonatal ductus arteriosus. *Pediatr Cardiol* 1998 ; **19** : 225-229
 - 8) Watterberg KL, Scott SM, Backstrom C, Gifford KL, Cook KL. Links between early adrenal function and respiratory outcome in preterm infants : airway inflammation and patent ductus arteriosus. *Pediatrics* 2000 ; **105** : 320-324
 - 9) Takami T, Momma K, Imamura S. Increased constriction of the ductus arteriosus by dexamethasone, indomethacin, and rofecoxib in fetal rats. *Circ J* 2005 ; **69** : 354-358
 - 10) American Academy of Pediatrics committee on fetus and newborn. Postnatal corticosteroids to treat or prevent chronic lung disease in preterm infants. *Pediatrics* 2002 ; **109** : 330-338
 - 11) Stark AR, Carlo WA, Tyson JE, et al. Adverse effects of early dexamethasone treatment in extremely-low-birth-weight infants. *N Engl J Med* 2001 ; **344** : 95-101

早産児動脈管開存症におけるデキサメタゾン、 インドメタシン併用療法の2症例

石井宏樹 高見剛 佐藤智
近藤敦 春原大介 星加明德

東京医科大学小児科学講座

腎障害と繰り返す再発により、動脈管開存症（PDA）に対するインドメタシン治療継続が困難になった早産児2症例に対して、低用量のデキサメタゾンとインドメタシンの併用療法を行い、2例とも重篤な合併症なくPDAの完全閉鎖が得られた。この併用療法は、特にインドメタシン単独投与で閉鎖が得られない症例や副作用により治療継続が困難となった早産児に対して、外科的手術を考慮する前の内科的治療としての選択肢の一つになると考えられた。

〈キーワード〉 動脈管開存症、インドメタシン、デキサメタゾン
