

Case reports

## Treatment for protruding keloids in the pubic area with everting suture and multiple Z-plasty

Akira SUGAMATA, Naoki YOSHIZAWA, Keiichi GOYA, Kazuki SHIMADA

Department of Plastic and Reconstructive Surgery, Tokyo Medical University Hachioji Medical Center, Tokyo, Japan

### Abstract

The pubic area has one of the highest rates of keloid scar formation in adults. Large protruding keloids in this area sometimes resist conservative therapies. We have resected primary keloids in the pubic area in 4 patients using our operative technique which included extremely everted wound suture with deep dermal stitches, and multiple Z-plasty. The associated postoperative therapies includes : regional steroid injection 5-6 times in 3 patients, and a meshed paper tape bandage was used continuously in all patients for 2-4 years until the surgical scars matured completely. None of the patients showed keloid recurrence following surgical correction.

### Introduction

Although the pubic area has one of the highest rates of keloid scar formation in adults, only a few studies have reported valid means of treating keloids affecting this area<sup>1-4)</sup>. Keloids formed on previous operative scars in the pubic area often form large protruding tumors that sometimes resist conservative therapies such as pressure tape bandages and intraregional steroid injections<sup>2-4)</sup>. Therefore it is appropriate to use treatments that include surgical excision and prevention of recurrence. We have resected primary large protruded keloids in the pubic area using the operative technique of Imai<sup>5)</sup>. These patients were followed up with postoperative therapeutic strategies such as steroid injection and meshed paper tape pressure bandages. This paper examines the clinical results of 4 adult patients who were followed for more than 2 years.

### Surgical technique

During surgery, keloid scarring and subcutaneous fat tissue were both resected to the superficial abdominal

fascia via a marginal skin incision of the stem of the keloid. Along the edges of the wounds, the skin and the subcutaneous fat tissue were formed into undermined flaps of about 3 cm in width. Dermal stitches with 4-0 nylon threads were inserted at 1-1.5 cm from both incisional margins and the suture threads were tied firmly to evert the flaps. Multiple Z-plasty was applied to the closed longitudinal wound ; each side of the triangular flaps had a length of approximately 7-10 mm. After each flap was put in place, dermis suturing was performed with 6-0 polydioxanone thread and the surface skin closed with 6-0 nylon thread (Fig. 1).

### Patients

#### Case 1

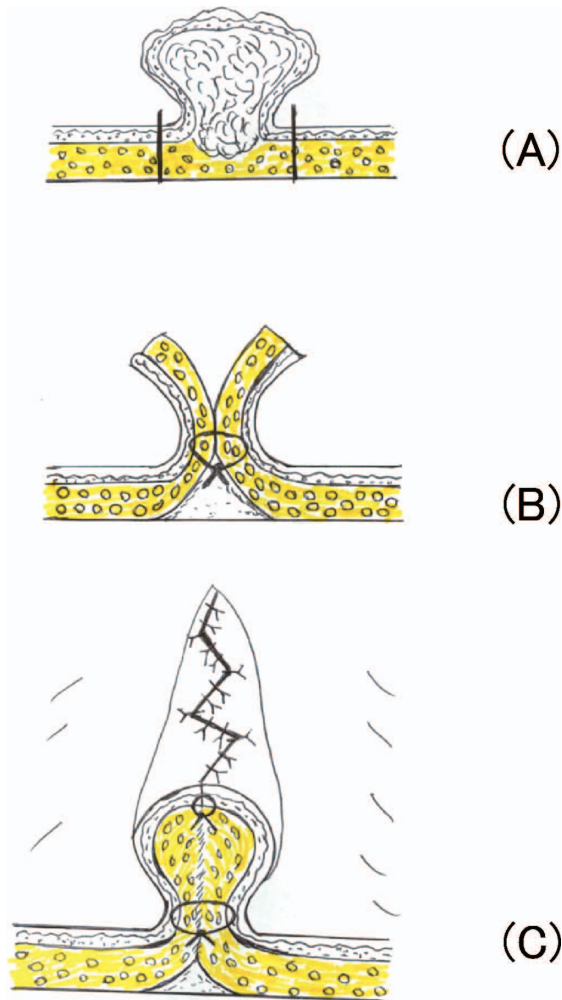
A 55-year-old woman, who had undergone an operation for a uterine myoma 3 years previously, showed development of a keloid in the lowest region of the incisional scar since after abscess formation caused by suture materials. The size of the keloid was 4×3×3 cm. The keloid was resected and the new wound was closed with everted margins with multiple Z-plasty. The everted

Received April 24, 2012, Accepted June 11, 2012

**Key words** : Keloid, Multiple Z-plasty, Pubic area, Meshed paper tape bandage

**Corresponding author** : Akira Sugamata MD, Department of Plastic and Reconstructive Surgery, Tokyo Medical University Hachioji Medical Center, 1163 Tatemachi, Hachioji City, Tokyo 193-0998, Japan

TEL : +81-426-65-5611 FAX : +81-426-65-1796 E-mail : sugamata@tokyo-med.ac.jp



**Fig. 1** Keloid scarring and subcutaneous fat tissue were both resected to the superficial abdominal fascia via a marginal skin incision of the stem of the keloid. (A) Along the edges of the wounds, the skin and the subcutaneous fat tissue were formed into undermined flaps of about 3 cm in width. Dermal stitches with 4-0 nylon threads were inserted at 1-1.5 cm from both incisional margins, and the suture threads were tied firmly to evert the flaps. (B) Multiple Z-plasty was applied to the closed longitudinal wound. (C)

suture wounds were maintained for about 2 months after the surgery and subsequently flattened. A meshed paper tape bandage was continued from 10 days after the surgery following removal of the suture materials to the last clinical examination 2 years later. There was no recurrence of the keloid (Fig. 2)

#### Case 2

A 42-year-old woman had undergone a cesarean section 8 years previously. She had experienced recurrent folliculitis on her operation scar and showed development of a large keloid in the lowest portion of the scar over a period of 1 year following surgery. The size of the keloid was 10×6×1 cm. The keloid was resected and the wound closed with crossed sutures with everted

margins and multiple Z-plasty. The everted suture wounds were maintained for about 1.5 months after the surgery. During the follow up period, when the surgical scars became hard and reddish, corticosteroid (0.1 ml triamcinolone acetate) was injected into the hard scar regionally at 3, 4, 7, 10, 12 and 15 months after the surgery. A meshed paper tape bandage was continued from 10 days after the surgery to the last clinical examination 2 years later. There was no recurrence of the keloid (Fig. 3).

#### Case 3

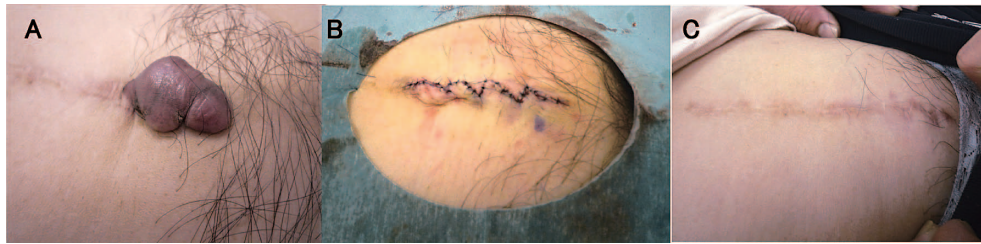
A 39-year-old man had undergone an operation for a left inguinal hernia when he was 1 year old. From 4 years prior to presenting at our clinic he had suffered several infections in the scar and a protruding keloid on the most infected inside region of the old scar gradually appeared. The size of the keloid was 5×4×3 cm. The keloid was resected and the wound was closed with everted margins with multiple Z-plasty. The everted suture wounds were maintained for about 1 month after the surgery. A meshed paper tape bandage was continued from 7 days after the surgery up to the last clinical examination 4 years later. When the surgical scars became hard, corticosteroid (0.1 ml triamcinolone acetate) was injected into the hard scar regionally at 1, 3, 4, 5 and 6 months after the surgery. Four years after the surgery for the keloid the scar had widened to 6 mm, however there was no recurrence of the keloid (Fig. 4).

#### Case 4

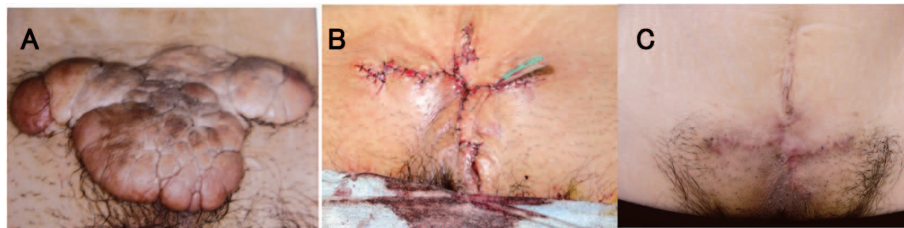A 34-year-old woman had undergone a cesarean section 8 years prior to consulting us. She had recurrent abscesses in the entire scar due to the original suture materials as well as epidermal cysts. She had gradually developed a large keloid on the scar from the cesarean section. The size of the keloid was 17×6×1 cm. The keloid was resected and the wound was closed with everted margins with multiple Z-plasty. The everted suture wounds were maintained for about 2 months after the surgery. A meshed paper tape bandage has been continued to the present time. When the surgical scars became hard, corticosteroid (0.1 ml triamcinolone acetate) was injected into the hard scar regionally at 3, 6, 10, 16, 20 and 24 months after the surgery. Four years after the surgery, the partial regions of the scar had widened to 3 mm, however there was no recurrence of the keloid (Fig. 5).

#### Discussion

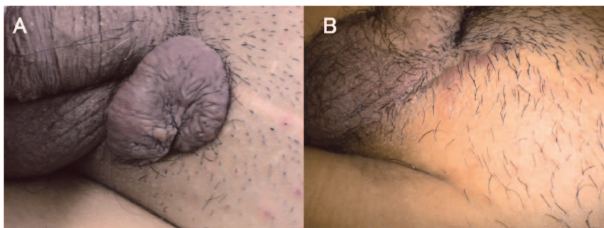
The tension of the skin in the pubic area is not as marked as the frontal chest area and around the shoulder region<sup>4)</sup>. Therefore, especially in adults, the greatest cause of pubic keloid formation in the primary scars is more likely due to recurrent inflammation from hair folliculitis, infected epidermal inclusion cysts and abscesses



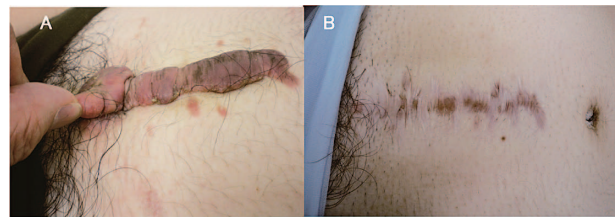**Fig. 2** A 55-year-old woman complained of a keloid in the lowest region of the incisional scar following an operation for a uterine myoma. (A) The keloid was resected and the new wound was closed with everted margins with multiple Z-plasty. (B) Two years after surgery, there was no recurrence of the keloid. (C)



**Fig. 3** A 42-year-old woman showed a large keloid in the surgical scar following a cesarean section. (A) The keloid was resected and the wound closed with crossed sutures with everted margins and multiple Z-plasty. (B) Two years after surgery, there was no recurrence of the keloid. (C)



**Fig. 4** A 39-year-old man complained of a keloid that had appeared on the old scar of an inguinal hernia correction. (A) Four years after the surgery for the keloid. The scar had widened however there was no recurrence of the keloid. (B)



**Fig. 5** A 34-year-old woman showed a keloid on the scar of a cesarean section carried out 1 year before. (A) Four years after the surgery. There was no recurrence of the keloid, and application of a meshed tape bandage is being continued. (B)

caused by suture materials, rather than anatomical tension of the skin. Our 4 patients also showed development of regional keloid formation subsequent to infections in the primary operation scars.

Our former co-worker, Imai<sup>5)</sup>, reported a unique surgical method for hypertrophic scars in the chest, shoulder and abdomen, which included everted wound sutures with extremely deep dermal stitches and multiple Z-plasty. Recently, Okuda<sup>6)</sup> reported this operation method was also useful for hypertrophic scars in the extremities. However, there have been no reports that describe application of this technique to true keloid scar formation. We had applied this technique to protruding keloids in the pubic area.

Imai<sup>5)</sup> described that deep dermal stitches reduced the skin tension in the wound for 1 month after surgery, and multiple Z-plasty of the suture wound also dispersed skin tension in the wound for a longer period. In the series of surgeries we reported here, the everted wounds were

maintained for about 1-2 months, which was slightly longer than in Imai's work. This is probably due to the tension of the skin in the pubic area being lower than in the chest or shoulder regions.

To prevent the recurrence of keloids, associated post-operative therapies were very important. A pressure bandage to the wound scar is the most basic associated therapy to prevent recurrence of keloids, and it eliminates skin tension to the wound scar and protects scars against external stimulation<sup>7-9)</sup>. We used a meshed paper tape bandage (Nichiban No. 50) that, according to our measurement, can produce a higher interface pressure (9 mmHg) than a general micropore tape (5 mmHg). When the wound scars became hard and reddish during the follow up period, we locally injected corticosteroid (0.1 ml triamcinolone acetate) into the scars<sup>10)</sup>. A course of 6 injections was used in 2 patients and 5 injections in 1 patient. After steroid injections, hard scars became soft and flat again. No serious complications (such as

hematoma or necrosis of the wound margins) were seen in any patient. There were no patients who experienced recurrence of keloids, even though in 2 cases the wound scars increased to 3-6 mm in widths ; however none of the patients were concerned with these outcomes.

Iida and Watanabe<sup>2)</sup> reported their operative method for hypertrophic scars in the pubic area, which involved using a rhomboid flap with multiple Z-plasty. However, in their technique, a flap without hair was inserted into the hair area and it seemed unnatural. The simple suture method described in this paper seems to have a more natural appearance. When keloids are removed from the pubic area, the underlying fat tissue should be preserved as much as possible to alleviate tension on the pubic bone, so our operative technique is also more useful for this purpose than skin grafts.

Positive results were observed with our treatment methods, however, more specific and sufficient follow up is necessary because infection of scar and keloids might recur several years after treatment.

**Conflict of interest statement :** The authors have no conflicts of interest.

#### References

- 1) Bayat A, Arscott G, Ollier WER, Ferguson MWJ, McGrouther DA : Description of site-specific morphology of keloid phenotypes in an Afrocaribbean population. *Br J Plast Surg* **57** : 122-133, 2004
- 2) Iida N, Watanabe A : Rhomboid flap with multiple Z-plasty for treatment of hypertrophic scar on the pubic area. *J Plastic Reconstr Aesthet Surg* **64** : 818-821, 2011
- 3) Hyakusoku H, Ogawa R : The small-wave incision for long keloids. *Plast Reconstr Surg* **111** : 964-965, 2003
- 4) Lin SD, Chou CK, Yang CC, Lai CS : Management of hypertrophic scars on the pubic area with an iliac flap. *Burns* **17** : 220-224, 1991
- 5) Imai S : Operation for hypertrophic scar and keloid. *Operation* **38** : 285-295, 1984 [Japanese]
- 6) Okuda R : Study of surgical treatment for hypertrophic scar/scar of limbs, cosmetic study and long-term follow up. *J Jap Plast Reconstr Surg* **31** : 789-795, 2011 [Japanese]
- 7) Reiffel RS : Prevention of hypertrophic scars by long term paper tape application. *Plastic Reconstr Surg* **96** : 1715-1718, 1995
- 8) Daya M : Abnormal scar modulation with the use of micropore tape. *Eur J Plast Surg* **34** : 45-51, 2011
- 9) Atkinson JA, McKenna KT, Barnett AG, McGrath DJ, Rudd M : A randomized, controlled trial to determine the efficacy of paper tape in preventing hypertrophic scar formation in surgical incision that traverses Langer's skin tension lines. *Plast Reconstr Surg* **116** : 1648-1656, 2005
- 10) Al-Attar A, Mess S, Thomassen JM, Kauffman CL, Davison SP : Keloid pathogenesis and treatment. *Plast Reconstr Surg* **117** : 286-300, 2006

## 外反縫合と Z 形成術による陰部ケロイドの治療

菅 又 章      吉 沢 直 樹      呉 屋 圭 一  
   島 田 和 樹

東京医科大学八王子医療センター形成外科

陰部に生じるケロイドは、皮膚の緊張などの解剖学的な要因よりも毛囊炎やアテローム感染、縫合糸膿瘍などの反復する炎症に起因することが多い。この部位のケロイドは、歩行による反復刺激を受けやすく、しばしば腫瘤型の形態をとり、圧迫やステロイド注射などの保存的治療に抵抗する。われわれは、陰部の腫瘤型ケロイドに対しては、ピアスケロイドの治療と同様に、腫瘤を一期的に切除して、再発を防止するという治療法を選択してきた。手術に当たっては、深い真皮縫合による皮膚縁の eversion と Z-plasty を組み合わせ、術後はメッシュテープによる長期にわたる創縁への張力の減退と刺激防止を行っている。また、瘢痕の発赤、硬化が生じた場合は、ステロイドの反復注入を行う。この手術法の結果は、極めて良好であり、この論文では 4 症例の臨床経過を提示してわれわれの手技を解説する。

---

〈キーワード〉 ケロイド、陰部ケロイド、Z-plasty、真皮縫合、メッシュテープ

---