



# QANUN MEDIKA

## JURNAL KEDOKTERAN FK UM SURABAYA

<http://journal.um-surabaya.ac.id/index.php/qanunmedika>



### Research Article

## Magnetic resonance cholangiopancreatography as a diagnostic tool in diagnosing biliary atresia at Dr. Soetomo Hospital

Gina Noor Djalilah<sup>1</sup>, Reny Widayanti<sup>2</sup>, Bagus Setyoboedi<sup>3</sup>, Sjamsul Arief<sup>4</sup>

1) Faculty of Medicine, University of Muhammadiyah Surabaya

2,3,4) Department of Child Health, Medical School, Airlangga University, Dr. Soetomo Hospital, Surabaya

### ARTICLE INFO

*Submitted* : November 2018

*Accepted* : February 2019

*Published* : July 2019

#### **Keywords:**

biliary atresia, magnetic resonance cholangiopancreatography, liver biopsy, diagnostic test.

#### **Correspondence:**

geendjk@gmail.com

### ABSTRACT

Cholestasis jaundice results from diminished bile flow and/or excretion, and caused by a number of disorders such as biliary atresia (BA). Magnetic resonance cholangiopancreatography (MRCP) is widely accepted as one of the modalities for biliary system imaging; however, liver biopsy still generally used for BA diagnosis, especially in developing countries. This aim study was to evaluate the diagnostic value of biliary atresia from MRCP compared to the result of a liver biopsy. A cross-sectional for diagnostic study documented of hospitalized patients from June 2014 to June 2015. All patients had MRCP and liver biopsy examination. The collection of data including age, gender, clinical manifestation and the result of MRCP and liver biopsy with ROC to evaluate the sensitivity and specificity was done. Liver biopsy revealed of biliary atresia was made based on proliferation, degeneration, and fibrosis of bile ducts. ROC to evaluate the sensitivity and specificity was done. The sensitivity, specificity, negative predictive value, positive predictive value of MRCP in diagnosing BA were calculated. There were 16 patients enrolled in this study with a median age of diagnosis was 6 months old (range 3-11). There were nine female patients out of the 16 patient. The median age of jaundice onset was 5 days (range 2-14 days). All patients had hepatomegaly and splenomegaly. Histopathology from liver biopsy revealed biliary atresia in 12 patients. From the ROC curve, the sensitivity of MRCP was 87.5% and specificity 62.5% with PPV 70% and NPV 80%. Five patients underwent a Kasai procedure and revealed biliary atresia. MRCP is sensitive but not specific for diagnosing BA, and MRCP has moderate sensitivity and specificity for BA diagnosis.



# QANUN MEDIKA

## JURNAL KEDOKTERAN FK UM SURABAYA

<http://journal.um-surabaya.ac.id/index.php/qanunmedika>



### ABSTRAK

Ikterus dikarenakan kolestasis terjadi akibat berkurangnya aliran empedu dan/ atau ekskresi, dan dapat disebabkan oleh sejumlah gangguan seperti atresia biliaris (BA). Magnetic resonance cholangiopancreatography (MRCP) secara luas diterima sebagai salah satu modalitas untuk pencitraan sistem empedu, namun biopsi hati masih secara umum digunakan untuk diagnosis BA, terutama di negara berkembang. Studi ini bertujuan untuk mengevaluasi nilai diagnostik atresia biliaris dari MRCP ke hasil biopsi hati. Sebuah cross sectional untuk studi diagnostik didokumentasikan pasien rawat inap dari Juni 2014 hingga Juni 2015. Semua pasien menjalani MRCP dan pemeriksaan biopsi hati. Data usia, jenis kelamin, manifestasi klinis dan hasil MRCP dan biopsi hati dengan ROC untuk mengevaluasi sensitivitas dan spesifisitas dilakukan. Biopsi hati mengungkapkan atresia bilier dibuat berdasarkan proliferasi, degenerasi dan fibrosis saluran empedu. ROC untuk mengevaluasi sensitivitas dan spesifisitas yang dilakukan. Dilakukan perhitungan sensitivitas, spesifisitas, nilai prediktif negatif, nilai prediksi positif MRCP dalam mendiagnosis BA. Terdapat 16 pasien yang terdaftar dalam penelitian ini dengan median usia diagnosis adalah 6 (kisaran 3-11) bulan. Terdapat 9 perempuan dari 16 pasien tersebut. Usia rata-rata onset penyakit kuning adalah 5 (kisaran 2-14) hari. Semua pasien mengalami hepatomegali dan splenomegali. Histopatologi dari biopsi hati mengungkapkan atresia bilier pada 12 dari 16 pasien. Dari kurva ROC, sensitivitas MRCP adalah 87,5% dan spesifisitas 62,5% dengan PPV 70% dan NPV 80%. Lima pasien menjalani prosedur Kasai dan mengungkapkan atresia bilier. MRCP sensitif namun tidak spesifik untuk mendiagnosis BA dan MRCP memiliki sensitivitas dan spesifisitas sedang untuk diagnosis BA.

**Kata kunci:** biliary atresia, magnetic resonance cholangiopancreatography, liver biopsy, diagnostic test.

### INTRODUCTION

Cholestasis jaundice results from diminished bile flow and/or excretion and caused by a number of disorders such as biliary atresia (BA) (Moyer V et al, 2014). BA is a devastating disease of infancy where the bile ducts are occluded and destroyed by a fibroinflammatory process. BA is rare but still the most common indication for childhood liver transplantation (LT). BA treatment is started with a Kasai Procedure or portoenterostomy (PE) operation, adjuvant medical therapy, and continued with LT if the PE fails (Liu Bo et al, 2014). Magnetic resonance cholangiopancreatography (MRCP) is widely accepted as one of the modalities for biliary system imaging; however, liver biopsy still generally used for BA diagnosis, especially in developing countries. This present study was

to evaluate the diagnostic value of biliary atresia from MRCP compared to the result of the liver biopsy.

### METHODS

This cross-sectional study included children admitted in the pediatric wards of Dr. Soetomo Hospital with suspected BA from June 2014 to June 2015. Inclusion criteria were 16 patients with consecutive cholestatic infants (9 female and 7 male) with a final diagnosis of INH or BA were included in this study as a clinical condition characterized by jaundice and all patients had MRCP and liver biopsy examination. The data collected includes age, gender, clinical manifestation and the result of MRCP and liver biopsy. Liver biopsy revealed of biliary atresia was made based on proliferation, degeneration, and fibrosis of bile ducts. The sensitivity,



# QANUN MEDIKA

## JURNAL KEDOKTERAN FK UM SURABAYA

<http://journal.um-surabaya.ac.id/index.php/qanunmedika>



specificity, negative predictive value, positive predictive value of MRCP in diagnosing BA were calculated.

### RESULTS

The clinical characteristics of patients are summarized in Table 1. There were 16 patients enrolled in this study with a median age of diagnosis was 6 months old (range 3-11). There were nine female patients. The median age of

onset of jaundice was 5 days (range 2-14). All patients had hepatomegaly and splenomegaly. Histopathology from liver biopsy revealed biliary atresia in 12 patients.

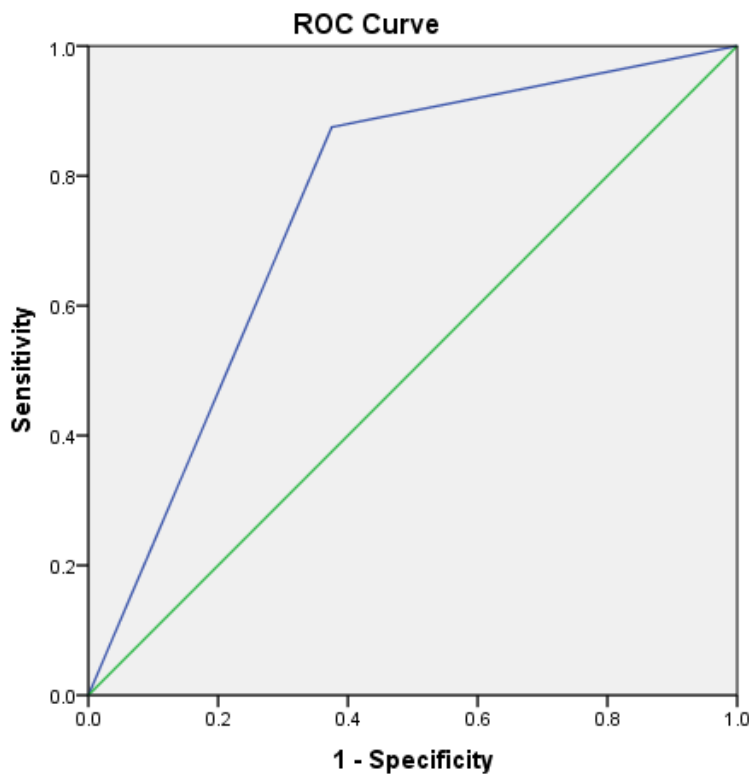
From table 2x2 (Table 2), the sensitivity of MRCP was 87.5% and specificity 62.5% with positive predictive value (PPV) 70% and negative predictive value (NPV) 80%. Five from 16 patients underwent Kasai Procedure and revealed biliary atresia

**Table 1.** Patient characteristic with suspected Biliary Atresia admitted in pediatric ward 2014-2015.

Characteristics	Value
Sex	
• Male	7 (43.8)
• Female	9 (56.2)
Age	
• < 3 month	2 (12.5)
• > 3 month	14 (87.5)
Dark Urine	
• Yes	13 (81.2)
• No	3(18.8)
Acholis Stool	
• Yes	14 (87.5)
• No	2(12.5)
Splenomegaly	
• Yes	15 (93.8)
• No	1 (6.2)
Hepatomegaly	16(100.0)

**Table 2.** Analysis MRCP compare with liver biopsy in BA patients.

MRCP	Liver Biopsy +/-		Total
	+	-	
+	7	3	10
-	1	5	6
	8	8	16



Diagonal segments are produced by ties.

**Figure 1.** ROC MRCP compare with liver biopsy in BA patient

## DISCUSSION

The North American Society for Pediatric Gastroenterology, Hepatology, and Nutrition (NASPGHAN) guideline for the evaluation of cholestatic jaundice in infants recommend that any infant noted to be jaundiced at the 2-week well-child visit should be evaluated for cholestasis (Moyer V, et al, 2014). Evaluation of breast-fed infants may be delayed until 3 weeks of age if they have a normal physical examination, no history of dark urine or light stools, and can be reliably monitored (Liu Bo, et al, 2011). Neonatal hepatitis and BA, which typically occur in term infants, account for 70-80% of cases (Hartley, 2009).

The feasibility of MR cholangiography in children has been described from the previous study. The BA could be ruled out if the extrahepatic bile duct is completely identified

at MRCP (Guibaud et al, 2009) reported that because of the small bile duct and the low rate of bile excretion in neonates and young infants with cholestatic jaundice, MRCP should not be relied on for the demonstration of the bile duct. The previous study reported that MRCP showed both the first branch of the intrahepatic bile duct and the common bile duct in most children without structural abnormalities (Lien TH et al, 2011).

In this present study, the liver biopsy revealed of biliary atresia was made based on proliferation, degeneration, and fibrosis of bile ducts. Most centers used percutaneous liver biopsy in the differential diagnostic path of a cholestatic infant. The liver histological assessment has approximately 90-100% sensitivity and 80-98% specificity for biliary obstruction (Takaya, 2007). The previous study revealed liver biopsy



# QANUN MEDIKA

## JURNAL KEDOKTERAN FK UM SURABAYA

<http://journal.um-surabaya.ac.id/index.php/qanunmedika>



of cholestasis infants, the features indicating BA were bile plugs in bile ducts and canaliculi, portal tract edema, severe portal fibrosis, and bile duct proliferation, whereas sinusoidal fibrosis ruled against BA (Yang Ji, 2009). Considerable interobserver variability observed was the percentage of agreement in the different features assessed varied from 43% to 93% (Khalil BA, 2010). Percutaneous liver biopsy is generally employed in the evaluation of neonatal cholestasis, particularly when biliary tract obstruction is high on the differential diagnosis (Humphrey TM, 2007). A pathologist with expertise in pediatric liver disease should interpret the biopsy. The experts recommend biopsy before performing a surgical procedure to diagnose BA (Norton KI et al, 2012).

A promising new option for imaging infants suspected with biliary atresia is by using MRCP. It can provide clear images of intrahepatic ducts and the common bile duct. The delineation of an incomplete extrahepatic bile duct and atrophic gall bladder on MR cholangiography suggests biliary atresia. A liver biopsy may also help in the diagnosis of biliary atresia (Metreweli, 2004).

In this present study, MRCP had a sensitivity and a specificity of 87.5 % and 62.5%, PPV 70% and NPV 80% for BA. This study shows that MRCP had higher sensitivity and NPV in the identification of BA; however, the specificity and PPV were lower. This lower accuracy may be due to the lower experience of the sonographer for detection of triangular cord sign. Accuracy not dependent by sonographer only, but also clinical manifestation from the patients. The sonographer who contributed to the research should only be one sonographer to avoid other bias and expertise on it. Contrary to previous reports, false-positive and false-negative findings occur at MRCP (Liu Bo et al, 2012).

The weakness in this study was the age of patients was more than 3 months which prognosis for BA was not good and gradually observed so for the next study should be earlier for good prognosis of BA.

### CONCLUSION

MRCP has moderate sensitivity and specificity for BA diagnosis.

### REFERENCES

- Han SJ, Kim MJ, Han A, Chung KS, Yoon CS, et al. (2002). Magnetic resonance cholangiography for the diagnosis of biliary atresia. *Journal of Pediatric Surgery* 37, 599–604.
- Hartley JL, Davenport M, Kelly DA (2009). Biliary atresia. *Lancet* 374, 1704-13.
- Humphrey TM, Stringer MD (2007). Biliary atresia: US diagnosis. *Radiology* 244: 845-51.
- Khalil BA, Perera MT, Mirza DF (2010). Clinical practice: management of biliary atresia. *European Journal of Pediatric* 169: 395–402.
- Lien TH, Chang MH, Wu JF, Chen HL, Lee HC, et al. (2011). Effects of the infant stool color card screening program on 5-year outcome of biliary atresia in Taiwan. *Hepatology* 53: 202-8.
- Liu Bo, Cai J, Xu Y, Peng X, Zeng H, Huang K, et al. (2014). Three-Dimensional Magnetic Resonance Cholangiopancreatography for the Diagnosis of Biliary Atresia in Infants and Neonates. *PLoS ONE* 9, e88268.
- Metreweli C, So NM, Chu WC, and Lam WW. (2004). Magnetic resonance cholangiography in children. *Br Journal of Radiology* 77: 1059-64.



**QANUN MEDIKA**  
**JURNAL KEDOKTERAN FK UM SURABAYA**  
<http://journal.um-surabaya.ac.id/index.php/qanunmedika>



- Mieli-Vergani G and Vergani D. (2009). Biliary atresia. *Semin Immunopathology* 31: 371-381.
- Moyer V, Freese DK, Whittington PF, Olson AD, Brewer F, Colletti RB, et al. (2014). Guideline for the evaluation of cholestatic jaundice in infants: recommendations of the North American Society for Pediatric Gastroenterology, Hepatology, and Nutrition. *Journal of Pediatric Gastroenterology and Nutrition* 39,115-28.
- Norton KI, Glass RB, Kogan D, Lee JS, Emre S, et al. (2012). MR Cholangiography in the evaluation of neonatal cholestasis: initial results. *Radiology* 222: 687-91.
- Takaya J, Nakano S, Imai Y, Fujii Y, and Kaneko K. (2007). Usefulness of magnetic resonance cholangiopancreatography in biliary structures in infants: a four-case report. *European Journal of Pediatric* 166: 211-4.
- Yang Ji, Ma Da, Peng Y, Song L, Lin L. (2009). Comparison of different diagnostic