

# Reportes de caso

## Chronic gastritis in a dog associated with *Spirocerca lupi* infection

### Gastritis crónica en un canino asociada a la infección de *Spirocerca lupi*

Rafael R. Santisteban-Arenas<sup>1\*</sup> MVZ; Carlos E. Piedrahita<sup>2</sup> MV, Esp

#### Resumen

*Spirocerca lupi* es un parásito de distribución mundial que infecta naturalmente el esófago de caninos domésticos y salvajes, este organismo puede migrar a otros órganos, incluyendo la aorta torácica y el estómago. La gastritis crónica canina es una enfermedad que se caracteriza por episodios de vómito asociada a diferentes causas inmunológicas e infecciosas. En este reporte de caso se evaluó una hembra canina con historia de vómitos crónicos y emaciación, la cual fue posteriormente sometida a laparoscopia exploratoria abdominal, durante la cual se extrajo un nódulo gástrico intramural. En la evaluación histopatológica del nódulo se observaron organismos compatibles con *Spirocerca lupi* en el interior. El paciente fue tratado con ivermectina y antiácidos, pero la resolución clínica completa de los vómitos se logró solo mediante la adición de prednisolona. La inmunosupresión se instituyó debido a la fuerte infiltración linfoplasmocítica observada en tejido gástrico debido a la infiltración parasitaria gástrica. *Spirocerca lupi* es un patógeno gastrointestinal de caninos, pero no existen reportes de su prevalencia en Colombia. Aquí describimos los hallazgos clínicos de la spirocercosis canina y sugerimos la infiltración parasitaria gástrica como una causa de gastritis crónica en perros.

**Palabras clave:** *Spirocerca lupi*, Canino, Gastritis, Histopatología

#### Abstract

*Spirocerca lupi* is a worldwide distributed parasite that naturally infects the esophagus of dogs and wild canids, parasitic larvae occasionally migrate to other organs, including thoracic aorta and stomach. Canine chronic gastritis is a condition characterized by episodes of vomiting associated with different immune and infectious causes. In this case report a female dog with history of chronic vomiting and emaciation was evaluated and latter scheduled for exploratory abdominal surgery, during surgery an intramural gastric nodule was found and removed. Histopathology evaluation of the nodule revealed *Spirocerca lupi* organisms coiled inside possibly due to aberrant migration in stomach wall. Patient was treated with ivermectin and antiacids, but complete clinical resolution of vomiting was achieved only by adding prednisolone. Immunosuppression was instituted to treat the strong lymphoplasmacytic infiltration observed on gastric tissue due to gastric parasitic infiltration. *Spirocerca lupi* is a gastrointestinal pathogen of dogs but no prevalence reports of this organism exist in Colombia. Here we described the clinical findings of canine spirocercosis and suggest the gastric parasitic infiltration as a cause of chronic gastritis in dogs.

**Keywords:** *Spirocerca lupi*, Canine, Gastritis, Histopathology

<sup>1</sup> Laboratorio de Patología Animal, Departamento de Salud Animal, Programa de Medicina Veterinaria y Zootecnia, Universidad de Caldas, Manizales, Colombia.

<sup>2</sup> Centro Veterinario Can & Kat, Armenia, Quindío

\*Autor de correspondencia Rafael Santisteban-Arenas, santistebandvm@gmail.com  
Laboratorio de Patología Animal, Departamento de Salud Animal, Programa de Medicina Veterinaria y Zootecnia, Universidad de Caldas, Manizales, Colombia. Teléfono 8781500 Ext 16645

## Introducción

Chronic gastritis in dogs is defined clinically as a persistent vomiting for more than one or two weeks (Amorim et al., 2016). The diagnosis of chronic gastritis is currently based on the histologic examination of gastric biopsies and is sub classified

according to the nature of the predominant cellular infiltrate, the presence of architectural abnormalities, and their severity, being the lymphoplasmacytic type the most common form of chronic gastritis in dogs (Simpson, 2013). The cellular infiltrate present in gastric tissue usually is the result of a response to a distinct pathologic disturbance, such as neoplastic transformation, bacterial infection or parasite infestation (Webb and Twedt, 2003). *Spirocerca lupi* (*S. lupi*) infection in dogs is a worldwide distributed disease in tropical and subtropical areas (Mazaki-Tovi et al., 2002;

van der Merwe et al., 2008). *S. lupi* is a nematode of carnivores, particularly dogs, that become infected by ingesting species of coprophagous beetles that act as intermediate hosts, although *S. lupi* can also utilize a variety of paratenic hosts such as poultry, rodents, wild birds and lizards (Mylonakis et al., 2008). Once ingested, larvae penetrate the gastric mucosa and migrate to thoracic aorta via coeliac artery, where they moult to immature adults, and then migrate to the caudal esophagus, developing the formation of granulomas, although erratic migration has been reported (Mazaki-Tovi et al., 2002). Clinical signs of canine spirocercosis include persistent vomiting and/or regurgitation, weakness, weight loss, dysphagia and dyspnea, depending on location, severity of the lesions and migration changes (Aroch et al., 2015). Complicated cases may present with acute death due to rupture of major blood vessels, secondary hemothorax and pneumomediastinum, pleuritis or pyothorax, due to parasitic migration through the aortic wall (Klainbart et al., 2007; Mazaki-Tovi et al., 2002), additionally, neoplastic transformation to sarcomas is well known in patients with *S. lupi* infection (van der Merwe et al., 2008).

Diagnostic techniques for spirocercosis include fecal flotation tests to find parasite eggs, direct endoscopic visualization of esophageal granulomas and radiographic visualization of mediastinal mass, especially when thoracic spondylitis is reported (van der Merwe et al., 2008). The authors of this report describe the clinical case of a patient with chronic gastritis diagnosed with *S. lupi* gastric nodule due to aberrant migration and associated with mucosal lymphoplasmatic infiltration responsive to ivermectin and immunosuppressive therapy.

## Materials and methods

### Patient assessment

A three-year-old, intact female mix-breed dog from peri-urban area was presented to the Small Animal Clinic of FUSM-Universidad del Tolima (Armenia, Colombia) with a history of chronic vomiting, several times a day during the last three months, significant weight loss and sialorrhea. During the first days of symptoms the patient was treated with antibiotics and prednisone prescribed by other veterinarian, the patient always kept a good appetite but the vomit persisted.

## Clinical and laboratory findings

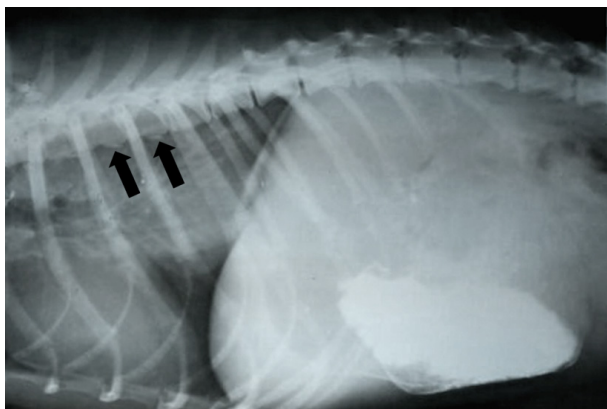
Upon presentation, the dog was anxious, with a body condition score of 2/5, 8 kg of body weight; pale mucus membranes, normothermic with a mild dehydration (7%), hypersalivation with repeated attempts to swallow, apparent bilateral sialoadenomegaly and no pain on abdominal palpation. No other abnormality was found on initial examination. A complete blood cell count (CBC) was performed, abnormal findings included a mild hypochromic anemia (packed cell volume 36%, reference range 37%-55% and HCM 16,8 pg, reference range 21 - 27 pg) and moderate thrombocytosis (751,000/ $\mu$ L, reference range 200,000-500,000), other values of the CBC were within reference intervals. On biochemistry profile total protein concentration was increased (9.0 g/dL, reference range 6-8 g/dL), ALT: 250 UI/L (reference range 10-70 UI/L), Albumin 1,8 mg/dL (reference range 2.8-4.0 g/dL), Alkaline Phosphatase 40 UI/L (12 - 121 UI/L) and Fibrinogen 600 mg/dl (reference range 200 - 400 mg/dL), Creatinine concentration was in reference ranges. Fecal examination by sugar flotation technique was performed and *Dipylidium spp* eggs were found.

### Initial clinical management

The initial treatment plan included daily ambulatory intravenous infusion with lactated ringer solution (LRS), famotidine (Gastrum®) 10 mg/kg/PO/BID, Sucralfate 1 g/PO/BID and a single administration of a broad spectrum anthelmintic (Canisan® Tablets). The first two days the patient reduce the vomiting frequency and an antiemetic (Maropitant 1 mL/SC/SID) was added to the treatment. The patient responded well to antiemetic treatment and no vomiting was detected for another four days, but relapse occurred on the sixth day of treatment, and the vomiting returned.

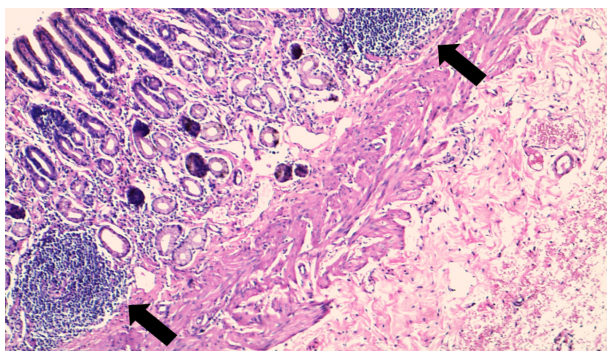
### Diagnostic aids used

A simple contrast radiographic study of lateral cervical and thoracic radiographs was performed with administration of oral barium sulfate, observing only a mild enlargement of stomach and thoracic spondylitis (Figure 1).



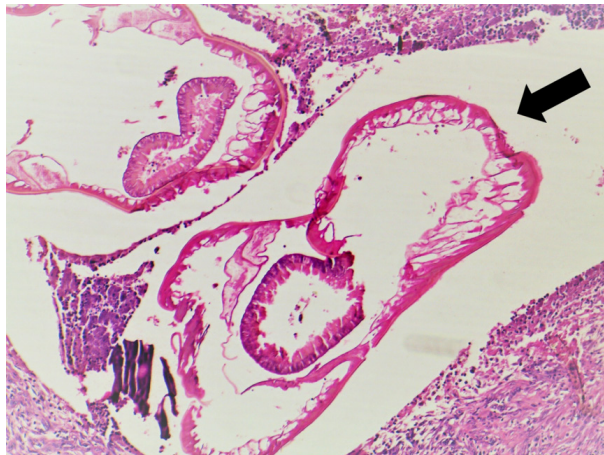
**Figure 1.** Barium contrasted left thoracic latero-lateral radiography showing mild gastric dilatation in cranial abdomen and thoracic vertebra with periosteal reaction in the ventral surface (arrows).

Ultrasound study findings included mild gastric overall mucosal thickening and moderate gastric dilatation. No neoplastic or inflammatory response was found on a fine needle aspiration and cytology of the enlarged salivary glands. At this point the owner agreed to perform a diagnostic abdominal laparotomy. For this surgery the patient was maintained with inhaled anesthesia and under continuous vital signs monitoring, on abdominal exploration a small (5 cm) intramural nodule in the stomach was founded and removed completely for biopsy studies, also a full thickness duodenal biopsy was obtained. No gross abnormalities were found in other intestinal portions of gastrointestinal tract, liver or pancreas. All tissue samples were fixed in 10% formalin and sent to histopathology analysis. The patient recovered well after surgery and no complications were reported. Histopathology examination of duodenal samples showed no abnormalities. In the gastric biopsy, the mucosa presented a moderate epithelial surface injury, mild glandular fibrosis and mild to moderate infiltration lymphocytes with several lymphoid aggregates observed (Figure 2).



**Figure 2.** Gastric mucosa and submucosa with moderate lymphocytic infiltration and lymphoid aggregates (arrows). H&E 10x.

The muscular layer had sparse areas of granulomatous formations with a fibrous reaction, lymphocyte infiltration and tissue necrosis; inside the granuloma formation were found parasitic forms with characteristic features of spiridid nematodes (Figure 3).



**Figure 3.** Tissue section showing parasitic forms of *Spirocerca lupi* inside the granuloma (arrow). H&E 10x.

Coiled worms inside the granuloma presented remains of lateral chords and a visible gut, with this finding the animal was diagnosed with *Spirocerca lupi* infection. The patient was scheduled for an esophagogastroscopy study to verify the presence of others granuloma lesions but no abnormalities were found on esophagus and gastric mucosa, and mild cardiac sphincter dilatation was reported.

### Treatment plan

The initial treatment plan was established with ivermectin 600 µg/kg/SC, two doses, two weeks apart, Fenbendazole 50 mg/kg PO for three days. Antacid medication composed of Famotidine (Gastrum®) 10 mg/kg/PO/BID, Sucralfate 1 g/PO/BID for 10 days was also prescribed. After the initial dose of ivermectin, the patient experienced mild improvement of clinical signs and vomiting frequency was reduced and with three weeks of treatment the patient was vomiting once a day and mostly at night, had a good appetite and it was more active. Due to the lymphocyte infiltration reported in the gastric histopathology, the chronic gastritis and lack of resolution of vomiting, the owner agreed to initiate a prednisolone treatment for a suspected secondary lymphocytic-plasmacytic gastritis. The patient initiated with a prednisolone dose of 1 mg/kg/PO/SID for two weeks without

change in diet or medication. After one week, the patient had a significant positive response and no vomiting episodes were reported by the owner. After the second week the patient gained 3 kg of body weight. The next two weeks the prednisolone was tapered to 0,5 mg/kg and other two weeks to 0,25 mg/kg/SID. The patient was on prednisolone 0,25 mg/kg every other day and no other vomiting or regurgitation was reported, there were two attempts to remove the prednisolone and after three months of initiate treatment, the dose of prednisolone was completely removed. The patient was in good physical conditions and no vomiting was reported after five months after treatment.

## Discussion

Spirocerosis, the disease caused by the infection with *S. lupi*, is prevalent in tropical and subtropical areas (Aroch *et al.*, 2015). Distribution is reported in several studies around the world including Greece, Turkey, Pakistan, India, USA, Brazil, Kenya and South Africa (van der Merwe, 2008). Prevalence is variable, ranging from 5% to 86% (van der Merwe, 2008), however limited information about prevalence of *S. lupi* exist in Colombia, to the authors knowledge only 2 clinical cases has been reported in literature, being this case report the second living patient described and treated (Acevedo-Naranjo *et al.*, 2014; Londoño *et al.*, 2003). The high prevalence variability reported for spirocerosis has been associated with many factors such as proximity to paratenic host, degree of rural development, accuracy of diagnosis methods, among others (van der Merwe *et al.*, 2008). The patient reported in this study lived in a peri-urban area bordering a small river, which probably contributed to the exposure to an intermediate or paratenic host.

The majority of parasitic nodules of *S. lupi* are located in the caudal esophagus, and contain adult stage worms coiled inside. However aberrant migration can occur stomach, intestine, mediastinum, kidney, urinary bladder, among others (van der Merwe *et al.*, 2008). Furthermore, between 3% and 5% of dogs infected had an intramural gastric nodule at necropsy (van der Merwe *et al.*, 2008). In the present report, the spirocerosis was the result of a solitary nodule caused by an erratic migration of the parasite. Solitary nodules of *S. lupi* in the stomach of dogs and wild canids have been reported. Recently, Giannelli *et al.* (2014) reported a similar parasitic nodule located near gastro esophageal junction in

a two year old dog from. In case of wild animals, a red fox, *Vulpes vulpes*, was reported with a solitary gastric nodule (Diakou *et al.*, 2012)

Clinical signs of spirocerosis depend on disease state, aberrant worm migration and malignant transformation of nodules to sarcomas (Aroch *et al.*, 2015). The most common signs include vomiting, regurgitation, weight loss, sialorrhea and sialoadenomegaly (van der Merwe *et al.*, 2008). In this case report the predominant clinical sign of the patient was vomiting and no esophageal involvement was found by esophagoscopy. Regurgitation was ruled out by anamnesis and visualization of emetic events accompanied by active abdominal contractions and prodromal signs. The sialoadenosis of the patient maybe due to the chronic gastric inflammation, generating a hyperplasia of the mandibular salivary glands due to continuous prodromal stimulation, which have been reported between *S. lupi* nodules and sialoadenosis (Schroeder & Berry, 1998)

The diagnosis of spirocerosis in early stages of disease is often challenging (van der Merwe, 2007). *S. lupi* eggs are difficult to find by flotation methods of fecal examination and formol-ether concentration techniques could improve egg detection (Okanishi *et al.*, 2013). In this case report no *S. lupi* eggs were not found on fecal evaluation and only *Dipylidium spp* eggs were reported in one fecal sample. Mazakitovi *et al.* in 2002 reported that 72% of dogs infected with *S. lupi* showed egg shedding in the first fecal examination. More recently in 2015, Aroch *et al.* reported that coproscopy studies positive to *S. lupi* eggs were found in 55% of dogs suffering from spirocerosis. Additionally, in the histopathology sections of the gastric nodules extracted from the patient, the *S. lupi* organisms did not have classic uterine tubes filled with eggs, so the authors presume that no female worm was present in the nodule, possibly explaining the lacking of egg shedding.

Endoscopy is a useful diagnostic tool used in cases of *S. lupi* infection since is considered 100% sensitive for diagnosis of esophageal masses (Mazaki-Tovi *et al.*, 2002), however in this case the procedure was not considered initially and the abdominal exploratory surgery was performed. However an esophagoscopy evaluation was conducted after confirmation of spirocerosis from biopsy analysis, revealing no additional granulomas in esophagus or stomach. Previous studies have reported that some

dogs infected with *S. lupi* may present in endoscopy only gastric granulomas but no esophageal lesions (Mazaki-Tovi *et al.*, 2002). The full thickness biopsy obtained by surgery in this case report proved to be suitable for diagnosis since endoscopy methods can only obtain a small portion of gastric mucosa and collection technique affects the sensitivity for certain lesions (Willard *et al.*, 2008). For this case the gastric granuloma would not have been properly evaluated with an endoscopically obtained biopsy, since diagnostic gastric lesions located in sub mucosal and muscle are not recovered by this method.

Radiography studies are also considered essential in the diagnosis of spirocercosis, especially when esophageal masses are present (van der Merwe *et al.*, 2008). However no esophageal masses were reported on lateral radiographies but authors observed few small periosteal reactions in the ventral aspects of thoracic vertebra T7, T8 and T9 consistent with mild spondylitis (Fig. 1). Spondylitis is found in up to 25% of dogs affected with *S. lupi* infection, and this lesions affects specially the vertebral bodies near the caudal esophagus, most commonly found between T5 and T12 (van der Merwe *et al.*, 2008). Spondylitis in dogs with spirocercosis is presumed to be caused by aberrant larval migration or inflammatory changes associated with aortic migration (Dvir *et al.*, 2001). However recent evidence suggest that the inflammatory changes in vertebral bodies of patients with *S. lupi* infection are mild and their association with larval or aortic migration was considered inconsistent, so inflammatory explanations for vertebral spondylitis in dogs need to be further evaluated (Kirberger *et al.*, 2013) which were necropsied, had the affected vertebrae removed and prepared for light and transmission electron microscopy examination. Transverse and sagittal sections of the ventral vertebrae were taken from 27 spondylitis and 8 spondylosis deformans lesions as well as from 8 normal vertebrae. Early spondylitis changes were characterized by periosteal woven new bone covered by hyperplastic periosteum with some involvement of the ventral longitudinal ligament. More mature lesions were characterized by nodules of denser trabecular bone and cartilage, also covered by hyperplastic periosteum and involved the ventral longitudinal ligament. It was difficult to distinguish the spondylitis and spondylosis deformans new bone. Inflammation was seen in five spondylitis cases (edema, lymphocytes, plasma cells, eosinophils and fibrin fibers.

Gastric pathology like granulomas are commonly reported in canine spirocercosis, being reported in up to 24% of dogs infected with *S. lupi* at necropsy examination (Sasani *et al.*, 2014). Gastric granulomas in dogs may be present due to foreign bodies or infectious diseases, but parasites infecting the canine stomach wall are considered uncommon (Amorim *et al.*, 2016). However, several parasitic gastric nodules or granulomas have been reported in domestic dogs (Giannelli *et al.*, 2014; Sasani *et al.*, 2014; van der Merwe *et al.*, 2008) and wild foxes (Diakou *et al.*, 2012). This gastric lesions are characterized by centrally located worms and surrounded by inflammatory infiltrates including degenerated neutrophils, macrophages and lymphocytes mixed with necrotic material and fibroblasts (Diakou *et al.*, 2012; Giannelli *et al.*, 2014). In the histopathology evaluation of the cellular infiltrates of the gastric granuloma of the patient, the predominant inflammatory cells were lymphocytes and macrophages. The parasitic infection was actively producing an increase inflammatory reaction in all layers of the stomach, including the mucosa.

Chronic gastritis is a disease characterized by a persistent vomiting for more than two weeks (Amorim *et al.*, 2016). Common causes of chronic gastritis in dogs include dietary intolerance, allergic reactions, occult parasitism and *Helicobacter sp.* infection, these disease conditions are diagnosed in absence of systemic disease which often can be identified in routine laboratory diagnostic tests (Amorim *et al.*, 2016; Berghoff & Steiner, 2011). Chronic gastritis in dogs is further classified according to the type of cellular infiltrate and severity of architectural abnormalities, being the lymphocytic plasmacytic form the most commonly reported (Amorim *et al.*, 2016). Histologically, the diagnosis of gastritis must include an increase number of mucosal lymphocytes or evidence of inflammatory changes like hyperemia, mucosal edema or epithelial injury (Amorim *et al.*, 2016; Day *et al.*, 2008). Although the granuloma of the patient was located in the muscular layer of the gastric wall, mild to moderate epithelial injury was evident in gastric mucosa, possibly due to chronic inflammatory reactions associated with the *S. lupi* granuloma. Aberrant parasitic migration is probably another cause of canine chronic gastritis and although is considered rare, specific anthelmintic drugs could be recommended in the course of diagnostic and therapeutic management of canine patients with chronic vomiting.

Several macrocyclic lactones are suggested for the treatment of canine spirocercosis, including doramectin, milbemycin oxime and ivermectin (Giannelli *et al.*, 2014) from where only few reports have been published in local journals at the beginning of the XXI century. In the present study, an autochthonous case of canine spirocercosis in a 2-year-old dog from southern Italy is described. The animal was admitted to a private veterinary clinic in the municipality of Potenza (Basilicata region). Doramectin is a broad spectrum antihelminthic commonly used in cattle and pigs, with good efficacy for treating dogs with *S. lupi* infection (van der Merwe *et al.*, 2008). Doramectin has been effective in reducing the size of the granulomas and decrease the egg shedding in dogs experimentally infected (Lavy *et al.*, 2002). Milbemycin oxime is an orally administered anthelmintic with similar efficacy in reducing *S. lupi* granulomas and egg shedding (Kok *et al.*, 2011). Ivermectin is another drug with efficacy against spirocercosis in dogs, this drug in combination with prednisolone has been proved to promote nodular regression, clinical signs and faecal shedding in 40 dogs naturally infected with spirocercosis (Mylonakis *et al.*, 2004). In this report, Ivermectin was administered at 600 µg/kg/SC two doses, two weeks interval, and the clinical signs of the patient improved with therapy but daily vomiting episodes persisted. Prednisolone administration was not considered early in this case report since the surgical wound of the laparotomy was prioritized, however due to lack of resolution of vomiting in the following weeks and the lymphocytic infiltrates in gastric tissue, a prednisolone treatment was suggested. The therapeutic response of this patient when prednisolone was added increased the suspicion of an exacerbated inflammatory response secondary to *S. lupi* granuloma formation, vomiting resolved in 48 hours and no emetic episodes were reported after prednisolone.

## Conclusions

Chronic gastritis is caused by many immunologic and infectious conditions in dogs. In this report, a canine patient suffering gastritis was described with an aberrant migration of parasitic forms of *S. lupi* in stomach without esophagus compromise. The inflammatory response associated with granuloma formation in gastric tissue may have contributed to development of conditions such as vomiting and

weight loss, however the antihelminthic and anti-inflammatory therapy were successful. The current distribution and prevalence of *Spirocerca lupi* in Colombia is unknown and the report of the clinical cases as the patient reported in this study encourage clinicians to include this pathogen as a potential cause of gastrointestinal disease not limited to esophagus.

## References

- Acevedo, C.M., Rendón, L., Martínez, M.M., 2015. Osteopatía pulmonar hipertrófica secundaria a una infestación mixta por *Dirofilaria immitis* y *Spirocerca lupi* en una hembra canina: reporte de caso. *Rev Colomb Cienc Pec* 2015; 28:Suplemento 69 264-272.
- Amorim, I., Taulescu, M.A., Day, M.J., Catoi, C., Reis, C.A., Carneiro, F., Gärtner, F., 2016. Canine gastric pathology: A review. *J. Comp. Pathol.* 154, 9-37. doi:10.1016/j.jcpa.2015.10.181
- Aroch, I., Markovics, A., Mazaki-Tovi, M., Kuzi, S., Harrus, S., Yas, E., Baneth, G., Bar-El, M., Bdoiah-Abram, T., Segev, G., Lavy, E., 2015. Spirocercosis in dogs in Israel: A retrospective case-control study (2004-2009). *Vet. Parasitol.* doi:10.1016/j.vetpar.2015.05.011
- Berghoff, N., Steiner, J.M., 2011. Laboratory tests for the diagnosis and management of chronic canine and feline enteropathies. *Vet. Clin. North Am. - Small Anim. Pract.* 41, 311-328. doi:10.1016/j.cvsm.2011.01.001
- Day, M.J., Bilzer, T., Mansell, J., Wilcock, B., Hall, E.J., Jergens, a., Minami, T., Willard, M., Washabau, R., 2008. Histopathological standards for the diagnosis of gastrointestinal inflammation in endoscopic biopsy samples from the dog and cat: A report from the World Small Animal Veterinary Association Gastrointestinal Standardization Group. *J. Comp. Pathol.* 138, 1-43. doi:10.1016/j.jcpa.2008.01.001
- Diakou, A., Karamanavi, E., Eberhard, M., Kaldrimidou, E., 2012. First report of *Spirocerca lupi* infection in red fox *Vulpes vulpes* in Greece. *Wildlife Biol.* 18, 333-336. doi:10.2981/11-094
- Dvir, E., Kirberger, R.M., Malleczek, D., 2001. Radiographic and computed tomographic changes and clinical presentation of spirocercosis in the dog. *Vet. Radiol. Ultrasound* 42, 119-129. doi:10.1111/j.1740-8261.2001.tb00914.x
- Giannelli, A., Baldassarre, V., Ramos, R. a N., Lia, R.P., Furlanello, T., Trotta, M., Dantas-Torres, F., Baneth, G., Otranto, D., 2014. *Spirocerca lupi* infection in a dog from southern Italy: An "old fashioned" disease? *Parasitol. Res.* 113, 2391-2394. doi:10.1007/s00436-014-3912-y
- Kirberger, R.M., Clift, S.J., van Wilpe, E., Dvir, E., 2013. *Spirocerca lupi*-associated vertebral changes: A radiologic-pathologic study. *Vet. Parasitol.* 195, 87-94. doi:10.1016/j.vetpar.2012.12.039
- Klainbart, S., Mazaki-Tovi, M., Auerbach, N., Aizenberg, I., Bruchim, Y., Dank, G., Lavy, E., Aroch, I., Harrus, S., 2007. Spirocercosis-associated pyothorax in dogs. *Vet. J.* 173, 209-214. doi:10.1016/j.tvjl.2005.08.019

- Kok, D.J., Schenker, R., Archer, N.J., Horak, I.G., Swart, P., 2011. The efficacy of milbemycin oxime against pre-adult *Spirocerca lupi* in experimentally infected dogs. *Vet. Parasitol.* 177, 111-118. doi:10.1016/j.vetpar.2010.11.031
- Lavy, E., Aroch, I., Bark, H., Markovics, A., Aizenberg, I., Mazaki-Tovi, M., Hagag, A., Harrus, S., 2002. Evaluation of doramectin for the treatment of experimental canine spirocercosis. *Vet. Parasitol.* 109, 65-73. doi:10.1016/S0304-4017(02)00250-9
- Londoño, Y., Carmona, J.U., Giraldo, C.E., 2003. Osteosarcoma generalizado y megaesófago secundario, ocasionados por infección de *Spirocerca lupi* en un canino. *Rev. Colomb. Ciencias Pecu.* 16, 63-69.
- Mazaki-Tovi, M., Baneth, G., Aroch, I., Harrus, S., Kass, P.H., Ben-Ari, T., Zur, G., Aizenberg, I., Bark, H., Lavy, E., 2002. Canine spirocercosis: Clinical, diagnostic, pathologic, and epidemiologic characteristics. *Vet. Parasitol.* 107, 235-250. doi:10.1016/S0304-4017(02)00118-8
- Mylonakis, M.E., Rallis, T., Koutinas, A.F., 2008. Canine spirocercosis. *Compend. Contin. Educ. Vet.* 30, 111-116.
- Mylonakis, M.E., Rallis, T.S., Koutinas, A.F., Ververidis, H.N., Fytianou, A., 2004. A comparison between ethanol-induced chemical ablation and ivermectin plus prednisolone in the treatment of symptomatic esophageal spirocercosis in the dog: A prospective study on 14 natural cases. *Vet. Parasitol.* 120, 131-138. doi:10.1016/j.vetpar.2003.12.008
- Okanishi, H., Matsumoto, J., Aoki, H., Kagawa, Y., Asano, K., Nogami, S., Watari, T., 2013. Successful resolution of esophageal granulomas in a dog infected with *Spirocerca lupi*. *J. Vet. Med. Sci.* 75, 1629-1632. doi:10.1292/jvms.13-0116
- Sasani, F., Javanbakht, J., Javaheri, a., Hassan, M. a M., Bashiri, S., 2014. The evaluation of retrospective pathological lesions on spirocercosis (*Spirocerca lupi*) in dogs. *J. Parasit. Dis.* 38, 170-173. doi:10.1007/s12639-012-0216-y
- Schroeder, H., Berry, W.L., 1998. Salivary gland necrosis in dogs: a retrospective study of 19 cases. *J. Small Anim. Pract.* 39, 121-5.
- Simpson, K.W., 2013. Stomach, in: Washabau, R.J., Day, M.D. (Eds.), *Canine and feline gastroenterology*. Elsevier, Saunders, p. 1017.
- van der Merwe, L.L., Kirberger, R.M., Clift, S., Williams, M., Keller, N., Naidoo, V., 2008. *Spirocerca lupi* infection in the dog: A review. *Vet. J.* 176, 294-309. doi:10.1016/j.tvjl.2007.02.032
- Webb, C., Twedt, D.C., 2003. Canine gastritis. *Vet. Clin. North Am. - Small Anim. Pract.* 33, 969-985. doi:10.1016/S0195-5616(03)00052-4
- Willard, M.D., Mansell, J., Fosgate, G.T., Gualtieri, M., Olivero, D., Lecoinde, P., Twedt, D.C., Collett, M.G., Day, M.J., Hall, E.J., Jergens, a. E., Simpson, J.W., Else, R.W., Washabau, R.J., 2008. Effect of sample quality on the sensitivity of endoscopic biopsy for detecting gastric and duodenal lesions in dogs and cats. *J. Vet. Intern. Med.* 22, 1084-1089. doi:10.1111/j.1939-1676.2008.0149.x