

DEVELOPMENT OF A MOBILE BASED DIABETES RETINOPATHY DETECTION SYSTEM

¹FENWA, O.D., ²AJALA, F.A. AND ³ALO, O.O.

^{1,2,3}Dept. of Computer Sc. & Eng, LAUTECH P.M.B 4000, Ogbomoso, Oyo State, Nigeria
Corresponding Authors email: {odfenwa/ faajala/ oalo}@lautech.edu.ng

ABSTRACT

Diabetes Retinopathy is a common retinal complication associated with diabetes. It is a major cause of blindness in the world most especially developing countries like Nigeria, which shares the largest percentage in Africa. Therefore early detection will be highly beneficial in effectively controlling the progress of the disease. The focus of this paper is to solve the problems of inadequate number of specialist who can handle growing number of people afflicted with the disease; and unavailability of mobile device that can aid early detection of diabetes retinopathy disease. Hence, in this paper a Mobile based Diabetes Retinopathy Detection System was developed to make it available for the masses for early detection of the disease.

Keywords: Diabetic Retinopathy (DR), Fundus, Diabetes Retinopathy Detector, Exudates, Retinal Images.

1. INTRODUCTION

Diabetic Retinopathy (DR) is the result of micro vascular retinal changes triggered by diabetes that can lead to a complete loss of sight if not treated in a timely manner. Recent reports have shown that approximately 25 000 people with diabetes go blind every year in the U.S. due to DR (Abr'amoff, et. al., 2008). The situation is made worse by the fact that only one half of the patients are aware of the disease. In the medical perspective, diabetes leads to severe late complications. These complications include macro and micro vascular changes which result in heart disease, renal problems and retinopathy. Early diagnosis of DR and treatment can prevent blindness (Mohamed, Gillies, and Wong, 2007) and therefore, systematic screening (by specialists) of diabetic patients is a cost-effective health care practice (James, et. al., 2000). However, due to the large number of people that require screening and annual reviews, an automated and accurate screening tool is a useful adjunct in diabetes clinics. Currently, several highly accurate programs exist for automated detection of specific DR related lesions (Giancardo et.al.,2011; Antal et.al., 2011; Fleming, et. al., 2006). These programs require different pre and post processing steps of retinal images depending on the lesion of interest as well as corrections for resolution and colour normalization to account for images with

different fields of view and ethnicity (Cree, Gamble and Cornforth, 2005).

The rate of diabetes is increasing, not only in developed countries, but in underdeveloped countries as well. Unfortunately, most developing countries lack basic recoding of DR cases (Kumar, 1998). It is estimated that 75% of people with diabetic retinopathy live in developing countries. The situation in developing countries is especially bad, because there is inadequate treatment. Many research works have been proposed in literature to make the detection of Diabetes Retinopathy an easier one, but unfortunately, African countries are lagging behind on the implementation aspect as a result of cost implication of the available technologies. The available fundus machine cost around 85,000 Euro in which most hospitals in the developing countries cannot afford to get. Hence, there is need to develop a cost effective and easily accessible system that can assist the Ophthalmologist in handling growing number of people afflicted with Diabetes Retinopathy. In this paper, a Mobile Based Diabetes Retinopathy Detection System was developed to make it available for the masses for early detection of the disease.

2. RELATED WORKS

Sánchez, et, al. (2004), Retinal Image Analysis to Detect and Quantify Lesions Associated with

Diabetic Retinopathy, An automatic method to detect hard exudates, lesion associated with diabetic retinopathy, was proposed in this paper. The algorithm determined on their color with the help of a statistical classification, and their sharp edges, an edge detector was applied to localize them. This system achieved a sensitivity of 79.62% with a mean number of 3 false positives per image in a database of 20 retinal images with variable color, brightness and quality.

Ahmed et, al. (2008) developed a system on automatic tracing of optic disc and exudates from color fundus images using fixed and variable thresholds. His proposed algorithm made use of the green component of the image and preprocessing steps such as average filtering, contrast adjustment, and thresholding. Morphological opening, extended maxima operator, minima imposition, and watershed transformation were other pre-processing steps. This algorithm was evaluated using the test images of STARE and DRIVE databases with fixed and variable thresholds and sensitivity of 96.7% was achieved.

Vijayakumari and Suriyanarayanan (2010) presented a method of detection of exudates in retinal images using image processing techniques. In their paper, the major goal was to detect the exudates in the retina. Pires et al.(2012) presented an algorithm to detect the presence of diabetic retinopathy (DR)-related lesions from fundus images based on a common analytical approach that is capable of identifying both red and bright lesions without requiring specific pre- or post-processing. Kullayamma(2013), developed a system on Retinal Image Analysis for Exudates Detection in which classification of a glaucomatous image was done using texture features within images and was effectively classified based on feature ranking and neural network. Efficient detection of exudates for retinal vasculature disorder analysis was performed.

Many other works have been proposed in literature to make the detection of Diabetes Retinopathy an easier one, but unfortunately, African countries are lagging behind on the implementation aspect as a result of cost implication of the available technologies. The available fundus machine cost around 85,000 Euro in which most hospitals in the developing countries cannot afford to get. Hence, this work has focused on making an alternative way of carrying out an eye test using smart device with the help of Fundus lens (which helps in getting the back of the eye) which will make the test available with the minimum cost by building a mobile application on mobile phone devices.

3. METHODOLOGY

An automated approach for classification of an eye defect Diabetes retinopathy using fundus images acquired is adopted. In order to diagnose diabetic retinopathy, a number of features such as area, mean and standard deviation of the pre-processed images are extracted to characterize the image content. Object oriented approach of software development was used to build a mobile application, which provides an interface to communicate with the user. Microsoft visual studio IDE is used to develop the application and SQL Server database was used to manage the data involved within the program. The Decision Tree Classifier (DTC) classifier is first trained using the histograms of the images and then they are employed to classify whether a retinal image is normal or not using a well-known database RetIDB and Messidor, which contains number of clearly labeled sample images for each anomaly.

The proposed model for the Mobile Based Diabetics Retinopathy Detector is as shown in figure 3.1 below:

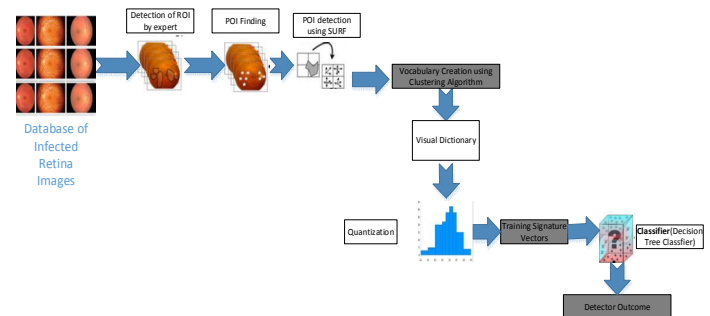


Fig. 3.1: Model of the Proposed Diabetes Retinopathy Detector

The stages of the system development is as discussed in section 3.1 to 3.6

3.1 Data Acquisition

Online database is used which contains the images affected by Diabetes Retinopathy and the ones that are not affected.

3.2 Pre-processing of Images

The pre-processing of image involve formation of Bag-of-Word, Bag-of-Word is basically an adaptation of document retrieval method for image retrieval application.

3.3 Extraction of Region of Interest

To detect bright or red lesions, the specialists marked ROIs within the retinal images are considered as good representatives of bright or red lesions. For

normal/control images, the entire retinal region represented in the image can be considered a ROI. The images with Diabetes Retinopathy-related lesion are marked by the specialists.

3.4 Point of Interest (PIO) Detection/Feature Extraction

The POI algorithm makes use of the concept of repeatability. We adopted “Speeded-Up Robust Features (SURF)” algorithm proposed in the year 2006 by Bay et, al. as POI detector.. Features are extracted from the images using the result of point of interest (POI) acquired and they are then quantized and was later used to generate histogram.

3.4.1 Vector Quantization

Vector quantization creates visual dictionaries from the extracted features (POI). It first splits the high dimensional descriptors into regions using a clustering algorithm to determine the groups or regions of most important points. Each cluster is considered as a visual word of a dictionary. K-means algorithm is chosen as the clustering algorithm for this work.

3.4.2 Histogram Generation/Image Segmentation

After the creation of the “dictionary”, the POIs of each image are assigned to the nearest visual word. The POIs are assigned by calculating the distance between each POI and each visual word. Once the POI obtained the distances to all available visual words, it will be assigned to the visual word with the smallest distance. By determining how much POI are assigned to each of the “visual words”, we could create a histogram for each image by plotting the number of occurrences of POIs in each visual word.

3.5 Image Classification

The retinal pathology images that have been represented with histograms are then classified into two groups, normal or abnormal (containing signs of Diabetic Retinopathy) using Decision Tree Classifier.

3.6 Software Requirement Specification

When the user of the system (Ophthalmologist) gets to the system, he or she provides the username and the password, if successfully logs in the user will be able to perform the following set of operations:

- Do eye test
- Set medication for the patient
- Set appointment for the patient
- View medication history of a patient

- Make subscription

The class diagram and the architecture diagram of the proposed system are as shown in figure 3.2 and 3.3 below.

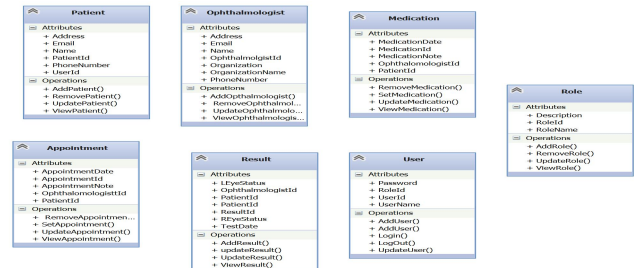


Fig. 3.2: The Class Diagram

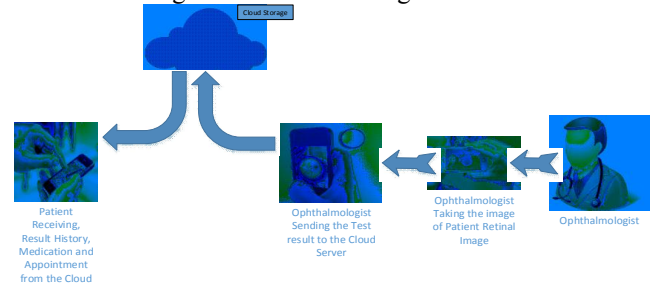


Figure: 3.3 Architecture Diagram of the Proposed System

4. RESULTS AND DISCUSSION

4.1 Overview of Results and Discussion

In this work, two well-known databases: RetiDB and Messidor(Xu, 2012) were adopted. Messidor database was chosen for training because it contains large number of clearly labelled sample images for each anomaly. It contains a total of 1200 images. The database RetiDB that we used for testing contains a total of 130 images with 22 normal images and 108 abnormal images (containing 1 or more anomalies). The results of the developed system as shown in figures 4.1 to 4.4 which include; the application login page; Ophthalmologist home page; patient home page and results history page of the developed mobile application respectively. The program is written in MATLAB on machine specifications: Intel i7 3630QM 2.4GHz, 8GB RAM, GeForce GT650M 4GB graphics card.

Having tested the algorithm, the solution is deployed on web service to be used on mobile devices. When the image is been captured on the phone, it is sent to the cloud for the processing, the image is then analyzed on the cloud and the result is sent back to the user of the application. On the user's phone, the result of previous test could be seen as a test history.

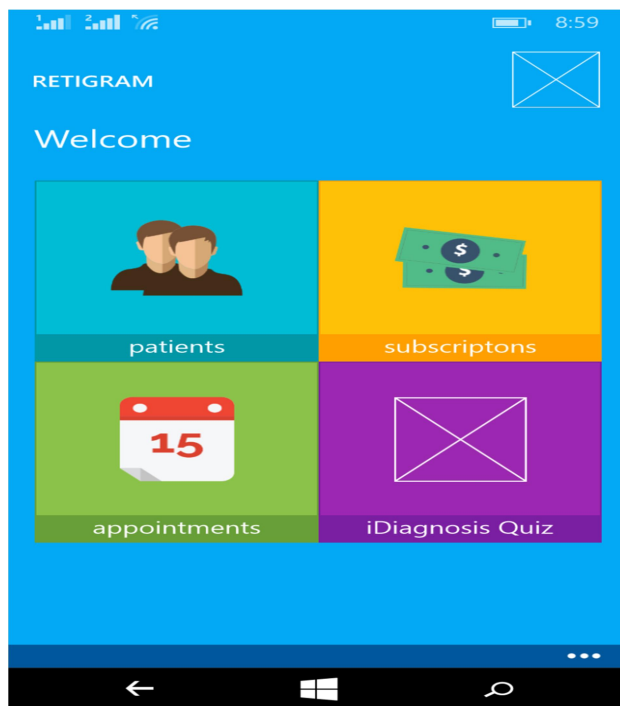
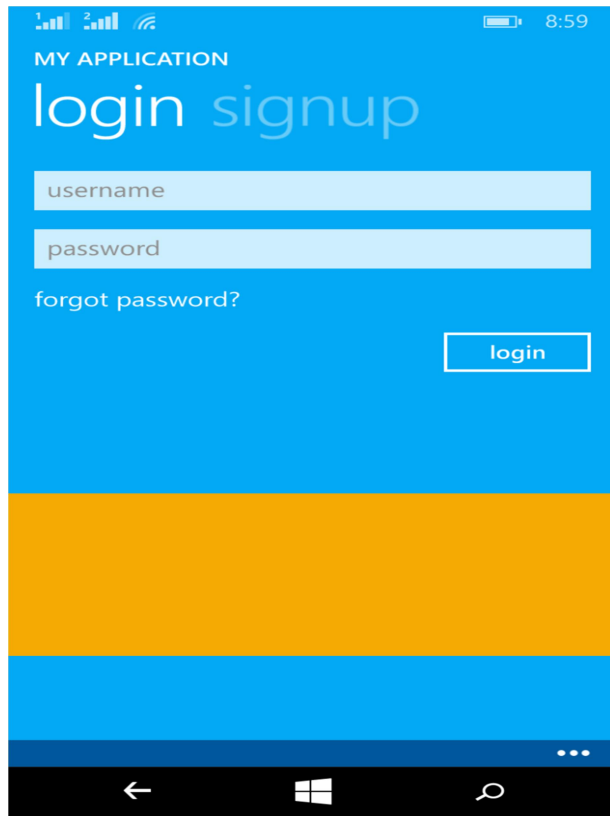


Figure 4.1: The Login page

Fig. 4.2 Ophthalmologist Home page

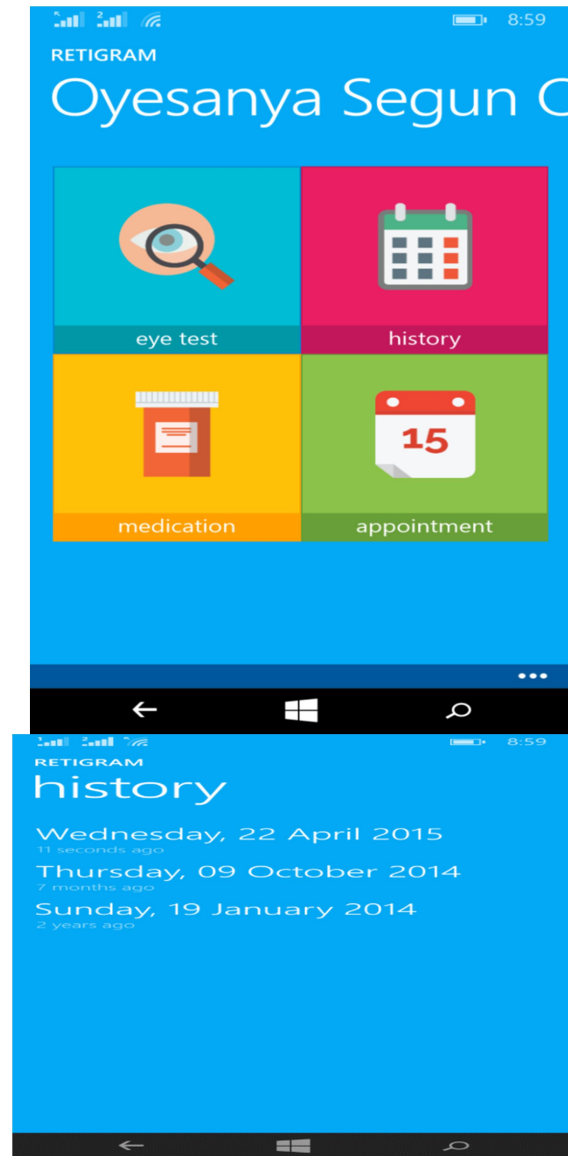


Figure 4.3: Patient Home page

Figure 4.8 Result history page

5. CONCLUSION, RECOMMENDATION AND FUTURE WORK

This paper focuses on detection of diabetic retinopathy using digital retinal images. The system intends to help the ophthalmologists in the diabetic retinopathy screening process to detect symptoms faster and more easily. Speed Up Robust Feature (SURF) algorithm is adopted for detection of the Diabetes Retinopathy. To make the system available to the mass, we develop a mobile phone application using object oriented programming methodology; the application provides the interface needed for an

ophthalmologist to implement the algorithm adopted in detecting Diabetes Retinopathy. The mobile phone based detection of Diabetes Retinopathy will however make the carrying out of the Diabetes Retinopathy test available to the masses, most especially in the developing countries.

This project is recommended to the health care centers, Pharmaceutical shops, Driver licensing centers, local community and individual families. Future work can be targeted towards using other classifiers to evaluate the performance of the proposed system.

References

M. D. Abramoff, M. Niemeijer, M. S. Suttorp-Schulten, M. A. Viergever, S. R. Russell, and B. van Ginneken, "Evaluation of a system for automatic detection of diabetic retinopathy from color fundus photographs in a large population of patients with diabetes," *Diabetes Care*, vol. 31, no. 2, pp. 193–198, 2008.

Q. Mohamed, M. C. Gillies, and T. Y. Wong, "Management of diabetic retinopathy: A systematic review," *J. Amer. Med. Assoc.*, vol. 298, no. 8, pp. 902–916, 2007.

M. James, D. A. Turner, D. M. Broadbent, J. Vora, and S. P. Harding, "Cost effectiveness analysis of screening for sight threatening diabetic eye disease," *Br. Med. J.*, vol. 320, pp. 1627–1631, 2000.].

L. Giancardo, F. Meriaudeau, T. Karnowski, Y. Li, K. Tobin, and E. Chaum, "Microaneurysm detection with radon transform-based classification on retina images," in *Proc. Intl. Conf. IEEE Eng. Med. Biol. Soc.*, 2011, pp. 5939–5942.

B. Antal, I. Lazar, A. Hajdu, Z. Torok, A. Csutak, and T. Peto, "Evaluation of the grading performance of an ensemble-based microaneurysm detector," in *Proc. Intl. Conf. IEEE Eng. Med. Biol. Soc.*, 2011, pp. 5943–5946.

A. D. Fleming, S. Philip, K. A. Goatman, J. A. Olson, and P. F. Sharp, "Automated microaneurysm detection using local contrast normalization and local vessel detection," *IEEE Trans. Med. Imag.*, vol. 25, no. 9, pp. 1223–1232, 2006.

M. J. Cree, E. Gamble, and D. J. Cornforth, "Colour normalisation to reduce inter-patient and intra-patient variability in microaneurysm detection in colour

retinal images," in *Proc. Workshop Digital Image Comput.*, 2005, pp. 163–168.

Kumar, A., Diabetic blindness in India: the emerging scenario. *Indian J. Ophthalmol.* 46(2):65–66, 1998.

Sanchez, R. Hornero, M.I. Lopez, J. Poza, Retinal Image Analysis to Detect and Quantify Lesions Associated with Diabetic Retinopathy, *Proc. 26 the IEEE Annual International Conf. on Engineering in Medicine and Biology Society (EMBC)*, 3, 2004, 1624–1627.

A. W. Reza, C. Eswaran and S. Hari, "Automatic Tracing of Optic Disc and Exudates from color Fundus Images Using Fixed and Variables Thresholds," *Journal of Medical Systems*, Vol. 33, pp. 73-80, April. 2008.

Vijayakumari V. and Suriyanarayanan N.(2010), Exudates Detection Methods in Retinal Images Using Image Processing Techniques, *International Journal of Scientific & Engineering Research*, Volume 1, Issue 2, ISSN pgs:2229-5518, IJSER © 2010, <http://www.ijser.org>

Pires R. H., F. Jelinek, J. Wainer, and A. Rocha, "Retinal Image Quality Analysis for Automatic Diabetic Retinopathy Detection," in *SIBGRAPI*, 2012, pp. 1-8.

Kullayamma, I. Madhavee Latha P., (2013), Retinal Image Analysis for Exudates Detection, *International Journal of Engineering Research and Applications (IJERA)* ISSN: 2248-9622 www.ijera.com, Vol. 3, Issue 1, January -February 2013, pp.1871-1875.

Bay H. T. Tuytelaars, and L. V. Gool, "SURF: Speeded up robust features," in *ECCV*, pp. 404-417, 2006.

Xu, M. Mandal, R. Long, I. Cheng, and A. Basu, "An Edge-Region Force Guided Active Shape Approach for Automatic Lung Field Detection in Chest Radiographs," *Comput. Med. Imaging Graph.*, vol. 36, no. 6, pp. 452–63, Sep. 2012.

