

CASE REPORT

## An Underexpanded Stent Does not Forgive

Konstantinos Triantafyllou, MD, Emmanouil Poulidakis, MD,  
Eleni Margioulas, MD, Konstantinos Kappos, MD

Department of Cardiology,  
Evangelismos Hospital, Athens, Greece

**KEY WORDS:** *stent underexpansion;  
stent thrombosis; resistant lesion*

**ABBREVIATIONS**

CAD = coronary artery disease  
DES = drug-eluting stent  
PCI = percutaneous coronary intervention  
RCA = right coronary artery  
STEMI = ST elevation myocardial  
infarction

Correspondence to:  
Konstantinos Triantafyllou, MD;  
E-mail: kontriad@gmail.com

ABSTRACT

Resistant coronary lesions regularly challenge physicians performing percutaneous coronary interventions (PCI) and specific techniques may be required to achieve procedural success. Underestimation of a resistant lesion may result in implanting an underexpanded stent due to insufficient plaque modification. Stent underexpansion is a risk factor for stent thrombosis and particularly difficult to treat. We present herein a case of a resistant right coronary artery lesion, insufficiently modified before stenting and finally treated with an underexpanded stent which could not be expanded by balloon post-dilatation at the initial intervention. Two inferior wall myocardial infarctions ensued one and three years later, both due to stent thrombosis despite intensive dual antiplatelet therapy and both treated by primary PCI. The stent could only be expanded by aggressive non-compliant balloon dilatation at the last procedure. The case presentation is followed by a brief discussion concerning techniques to successfully treat resistant coronary lesions and underexpanded stents.

INTRODUCTION

Interventional cardiologists are regularly challenged by resistant or non-dilatable coronary lesions that increase the complexity of several percutaneous coronary interventions (PCI). Such lesions demand the use of specific tools and techniques in an escalating stepwise approach in order to achieve procedural and clinical success. Sufficient lesion preparation before stenting is necessary, otherwise the stent will either not cross or not expand properly after crossing. Stent underexpansion is particularly difficult to treat and consists a well-known risk factor for stent restenosis and thrombosis.<sup>1</sup>

Below is presented the case example of very late stent thrombosis while on uninterrupted dual antiplatelet therapy occurring twice after the initial PCI, where a resistant right coronary artery (RCA) lesion was treated with an insufficiently expanded stent. The case presentation is followed by a brief discussion regarding tools and techniques that can be used to treat resistant coronary lesions and underexpanded stents.

---

**CASE PRESENTATION**

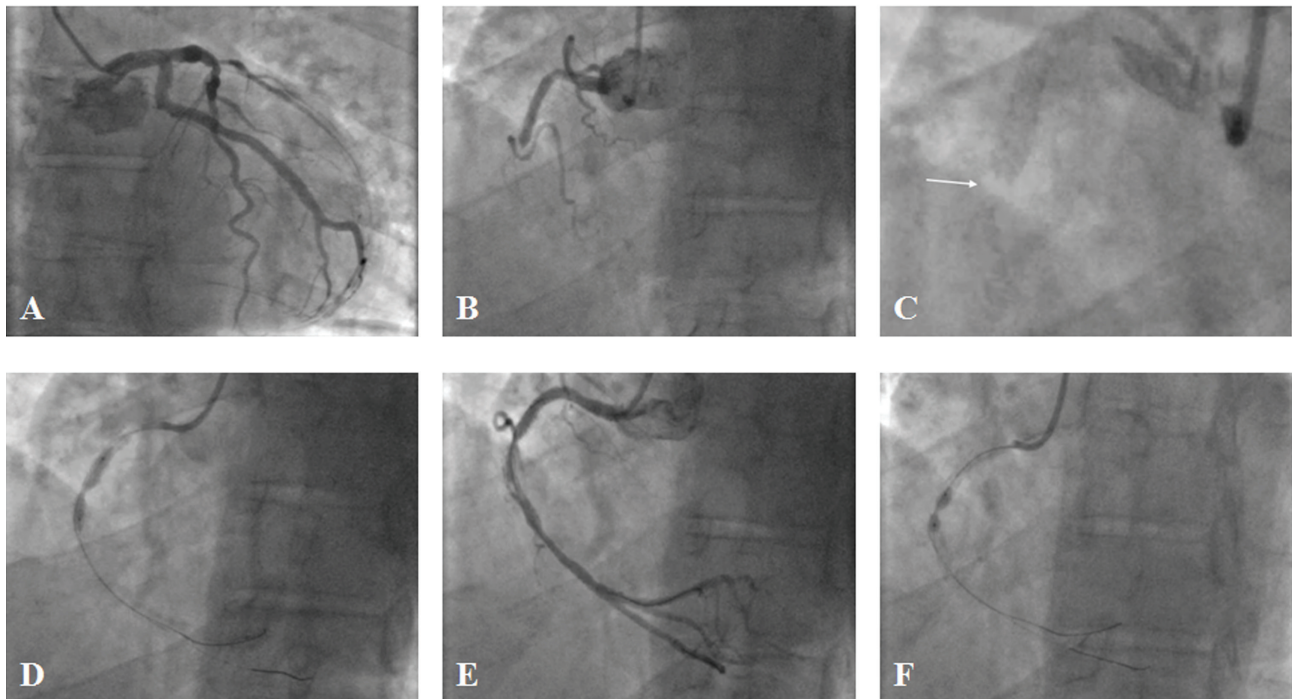

---

A 60 year-old male patient suffering from acute inferior STEMI was admitted to our hospital one hour after symptoms onset. He had known one-vessel coronary artery disease (CAD) having as initial manifestation a non STEMI 3 years earlier that was treated by PCI with implantation of a drug-eluting stent (DES) at the mid segment of the RCA. One year later he had suffered from an inferior STEMI treated by primary balloon angioplasty without stent implantation. Of note, we had no access to more detailed information concerning the techniques and materials used for these two initial PCIs (performed in another hospital) until after the completion of the primary PCI that followed. Otherwise the patient's history was remarkable for essential thrombocytosis diagnosed 10 years earlier, while his risk factors were active smoking and dyslipidemia. He was treated for his essential thrombocytosis with hydroxyurea 600 mg qd and anagrelide 0.5 mg bid, while he was still on dual antiplatelet therapy with aspirin 100 mg/d and prasugrel 10 mg/d two years after the last PCI. His medical

therapy otherwise consisted of metoprolol 25 mg bid, atorvastatin 20 mg qd, enalapril 5 mg bid and isosorbide dinitrate 60 mg qd. According to the information we had on admission the patient had been fully compliant with his prescribed treatment.

At presentation in the emergency department the patient had ongoing severe retrosternal chest pain and diaphoresis. He was hemodynamically stable (blood pressure: 110/70 mmHg, heart rate: 87 bpm), his physical examination was otherwise unremarkable, while his electrocardiogram was typical of acute inferior STEMI. A rapid echocardiographic assessment revealed a left ventricular ejection fraction of 50% with hypokinesis at the basal and middle inferior wall as well as at the basal posterior wall. His initial laboratory results were within normal limits, the first troponin was negative and the platelet count was 315000.

He was immediately transferred to the catheterization laboratory for emergency coronary angiography intending to perform primary PCI. The right radial approach was selected. There was no significant lesion at the left coronary artery (Fig. 1, A), while there was an acute thrombotic occlusion at the



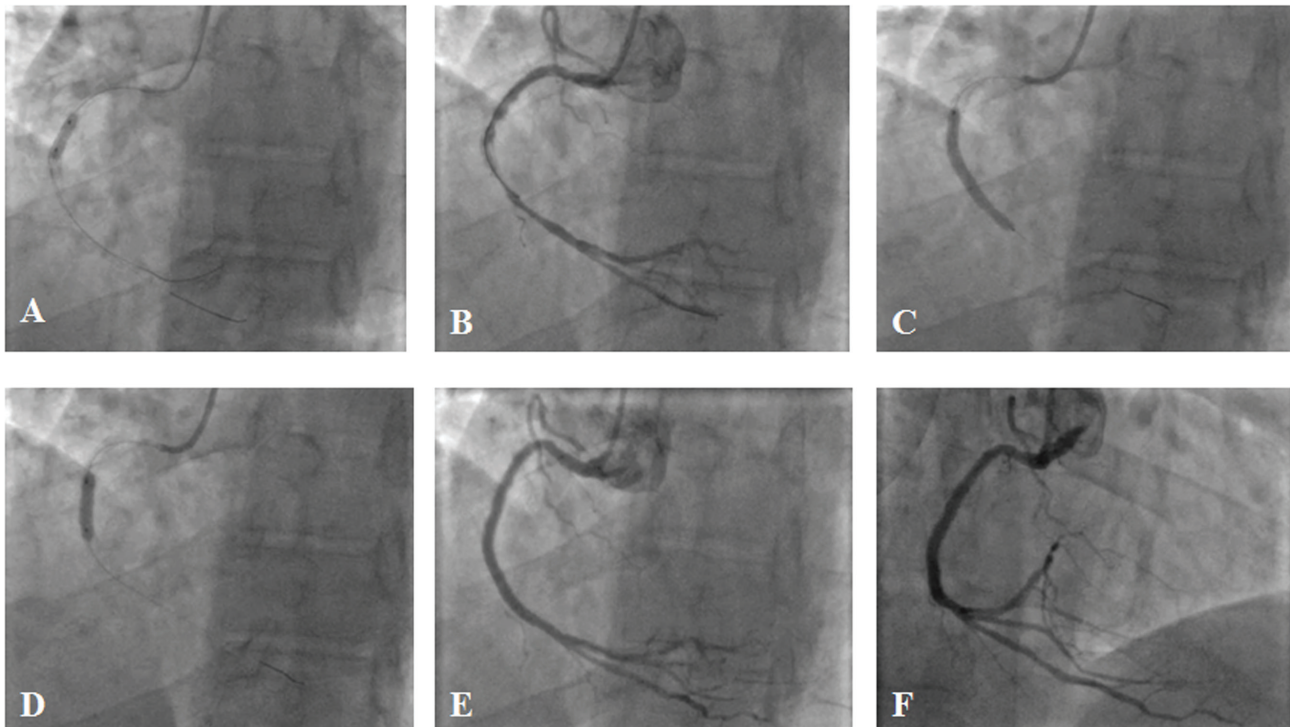
**FIGURE 1.** Primary PCI for acute inferior STEMI (7-9-2015). **A.** The left coronary artery had no significant disease, **B.** The middle segment of a dominant RCA had a thrombotic occlusion in a stented area, **C.** The occlusion point corresponded to a zone of probable stent underexpansion (white arrow: sufficiently expanded stent was visible before the injection proximally and distally, but not in that zone), **D.** After guidewire crossing a thrombus aspiration catheter could not advanced beyond the point of occlusion, resistance was felt and thrombectomy was unsuccessful. A dilatation attempt with a 2.5x20 mm semi-compliant balloon at 8 Atm is shown. It could not open properly at the middle of the stented area. **E.** TIMI III flow was restituted, while some thrombotic burden distally to the resistant underexpanded stent zone and significant disease beyond the stent were noticed, **F.** The underexpanded stent zone could not be expanded initially with a 3x9 mm non-compliant balloon inflated at 20Atm for 30 sec.

## UNDEREXPANDED STENT

second segment of the RCA, within a previously stented area at a zone of obvious stent underexpansion (Fig. 2, B & C). After guidewire crossing a thrombectomy attempt was unsuccessful since the thrombus aspiration catheter could not be advanced beyond that zone where resistance was felt. A balloon predilatation attempt with a 2.5x20 mm semi-compliant balloon resulted in failure to expand the zone of incomplete stent expansion (Fig. 1, D). However, TIMI III flow was restituted, giving evidence to some residual thrombotic burden distally to the resistance zone and significant disease just beyond the stent (Fig. 1, E). The underexpanded stent could not be expanded initially with a 3x9 mm non-compliant balloon inflated at 20Atm for 30 sec (Fig. 1, F). It finally yielded after insisting with the same balloon inflated differently: three rounds of increasing pressure from 12 Atm up to 26 Atm by steps of 2 Atm/sec resulted in significant lumen gain without balloon waist at the end of the inflation (Fig. 2, A & B). A long 3x38 mm DES was implanted (18 Atm, 30 sec) in order to cover from the stent underexpansion zone to the significant disease noted distally to the old stent and it was finally post-dilated with a 3.5x15mm non-compliant balloon throughout its length at

high pressure (20 Atm) (Fig. 2, C & D). The final angiographic result was optimal (Fig. 2, E & F). The patient was discharged five days later after an uncomplicated in-hospital course with a preserved left ventricular ejection fraction of 50%.

We had the opportunity to review the two previous coronary procedures only after the primary PCI. As mentioned above the patient had as initial manifestation a non STEMI three years ago that was treated by PCI with implantation of a DES at the second segment of the RCA. The left coronary artery had no significant lesions while the RCA had initially two consecutive severe stenoses within a long lesion at the second segment (Fig. 3, A). The distal stenosis did not yield at balloon predilatation (Fig. 3, B). Despite that fact a long stent was implanted to cover both stenoses, but unluckily a waist persisted at the distal stenosis resistant zone during stent deployment (Fig. 3, C). A significant residual stenosis remained there after implantation, as a consequence of the fact that the resistant lesion had not been properly prepared before (Fig. 3, D). An attempt to expand the stent with a short non-compliant balloon at high pressure was not successful (Fig. 3, E). The final result was thus suboptimal with a significant



**FIGURE 2.** Primary PCI for acute inferior STEMI (7-9-2015, continued). **A.** The resistant stent area finally yielded after inflating the same 3x9mm non-compliant balloon with three rounds of increasing pressure from 12 Atm up to 26 Atm by steps of 2Atm/sec. **B.** There was significant lumen gain at the previously underexpanded stent zone and TIMI III flow remained, **C.** A 3x38mm drug-eluting stent was implanted (18 Atm, 30sec) to cover the underexpanded stent zone and the significant disease noted distally to the old stent, **D.** Post-dilation with a 3.5x15mm non-compliant balloon was performed throughout the new stent at high pressure (20Atm). The post-dilation at the area of the previous underexpansion is shown, **E** and **F.** The final result was optimal (shown in two projections).



residual stenosis (about 60%) at the stent underexpansion zone. Of note, a long significant lesion at the third segment of the RCA, just distal to the stent, was also not treated (Fig. 3, F). The patient had been discharged with optimal medical therapy, plus aspirin and ticagrelor as dual antiplatelet therapy. Platelet function testing had shown satisfactory platelet inhibition at that time and a functional test was scheduled to be performed two months later, but the patient did not comply because he was asymptomatic and feeling well.

The second previous coronary procedure had been a primary PCI for acute inferior STEMI two years ago. The patient was compliant to his treatment plan and on aspirin plus ticagrelor at the time of the event. The left coronary artery had not significant disease. The middle segment of the RCA had a thrombotic occlusion in the stented area, similarly to our primary PCI procedure (Fig. 4, A). TIMI III flow had been restored by balloon angioplasty only, but attempts to expand the stent underexpansion zone were not successful (Fig. 4, B-E). At the end of the primary PCI the stent remained insufficiently expanded while significant disease beyond the stent could be noticed once more (Fig. 4, F). The

patient had been discharged on optimal medical therapy and dual antiplatelet therapy consisting of aspirin plus prasugrel (instead of ticagrelor).

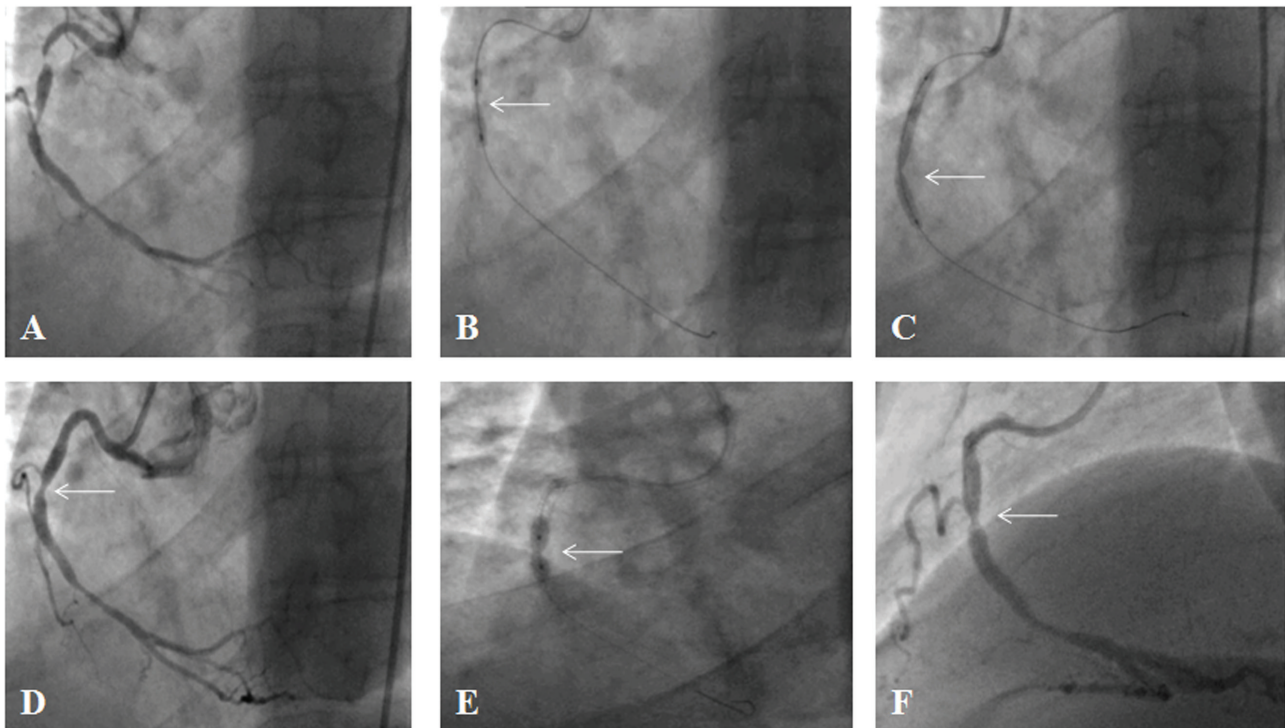
---

## DISCUSSION

---

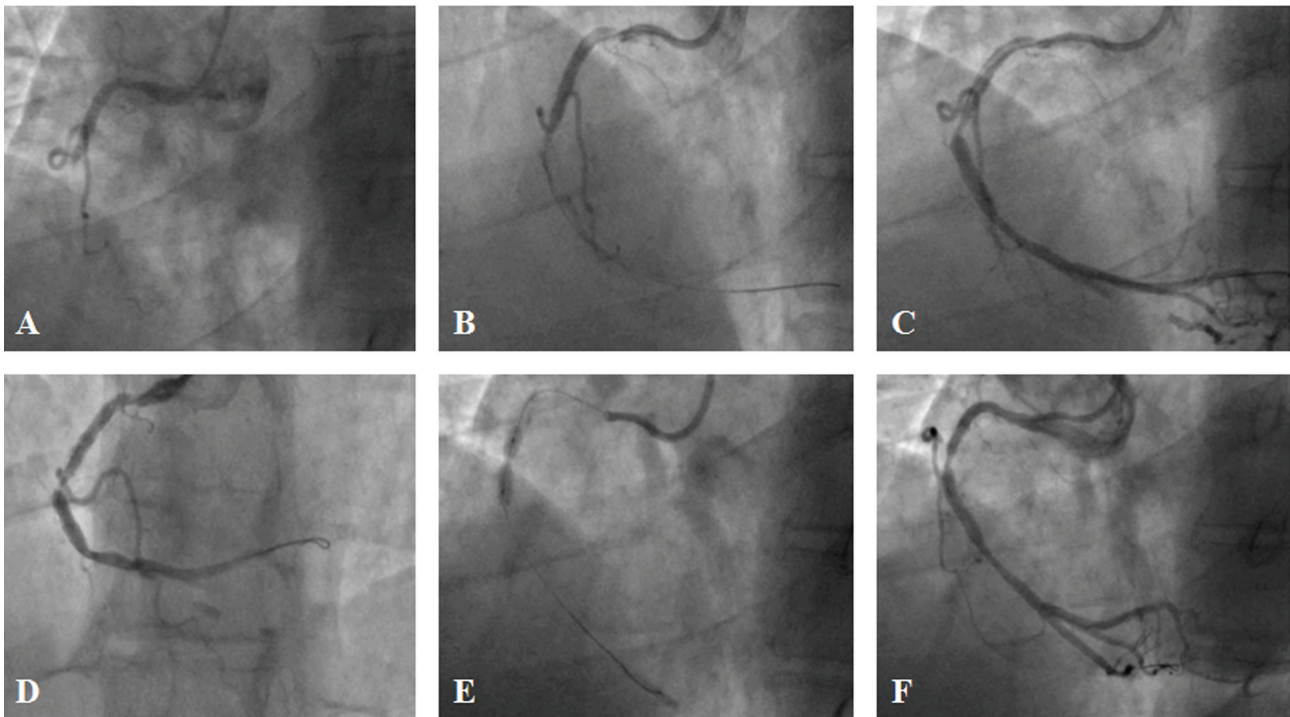
We presented a stent thrombosis case of an insufficiently expanded stent occurring twice very late after the initial implantation, despite the fact that the patient was on dual antiplatelet therapy with aspirin and a novel potent P<sub>2</sub>Y<sub>12</sub> inhibitor.

Stent thrombosis is a medical emergency often associated with death (20%-40%), MI (50%-70%) or the requirement for urgent repeat revascularization.<sup>2,3</sup> Stent thrombosis occurrence is categorized as early (either acute or subacute), if within 30 days of stent deployment, and either late (>30 days to 1 year) or very late (>1 year). The development of standardized definitions for both the time course and probabilistic likelihood of stent thrombosis by the Academic Research Consortium (ARC) has facilitated comparative analyses across clinical studies and other data sets.<sup>4</sup> Multiple risk factors may



**FIGURE 3.** Initial PCI after a non STEMI with inferior wall ischemia (19-10-2012). **A.** The left coronary artery had no significant disease (not shown). The dominant RCA had 2 consecutive severe stenoses within a long lesion at the second segment, **B.** The distal stenosis did not yield at balloon pre-dilatation, **C.** A long stent was implanted to cover both stenoses but it was not expanded enough at the distal stenosis level, **D.** A significant residual stenosis remained, which was evidence of a resistant lesion that was not properly prepared before stent implantation, **E.** An attempt to expand the stent with a short non-compliant balloon at high pressure was not successful, **F.** Final result: a significant residual stenosis (60%) with a stent under-expansion waist at the zone of lesion resistance remained at the end of PCI.

## UNDEREXPANDED STENT



**FIGURE 4.** Primary PCI for inferior STEMI about 1 year after the initial PCI (29-10-2013). **A.** The left coronary artery had no significant disease (not shown). The middle segment of a dominant RCA had a thrombotic occlusion in the stented area, **B.** Guidewire crossing restitutes some modest flow distally, **C & D.** After initial balloon dilatation, flow is improved, the underexpanded stent zone is appreciated and thrombotic material is embolized in the posterior descending branch, **E.** An attempt to expand the underexpanded stent zone with a non-compliant balloon did not succeed, **F.** At the end of PCI, TIMI III flow was restored, there was no more visible thrombotic material distally, but the significant residual stenosis due to stent underexpansion remained, as inherited from the initial PCI.

contribute to the genesis of stent thrombosis and may vary in importance as a function of time following stent deployment.<sup>5</sup>

Underexpansion and residual reference segment stenosis of a coronary stent due to undilatable, heavily calcified plaque has repeatedly been shown to significantly increase the rate of in-stent restenosis as well as predispose to stent thrombosis.<sup>1,6</sup> This phenomenon is a consequence of resistant non-dilatable coronary lesions that regularly challenge but can also be underestimated by interventional cardiologists. The ultimate PCI success in such cases depends on specific maneuvers and tools to be used in a stepwise approach in order to sufficiently prepare the lesion before stent deployment. Resistant lesions may yield by conventional balloon techniques, longitudinal focused force angioplasty, scoring balloons, cutting balloons or with even more aggressive approaches used for lesion debulking and modification, such as rotational and laser atherectomy. When pre-dilatation with appropriately sized non-compliant balloons fails plaque scoring techniques are the next in order. Longitudinal focused force angioplasty can be performed by placing a parallel buddy wire (or even more) outside the non-compliant balloon.<sup>7,8</sup> The theoretical basis of this technique is that by focusing the force of balloon inflation,

greater longitudinal and radial stress is exerted in order to create dissections in multiple planes on the lesion. The same action principle is the basis of cutting and scoring balloons, which however are bulkier and more difficult to deliver across tight stenoses, especially in calcified arteries. When all the above fail to prepare a resistant lesion, plaque modification and debulking with atherectomy devices becomes the final option. Rotational atherectomy is the most commonly used, while other options might be orbital or excimer laser atherectomy. Rotational atherectomy is an established technique to reduce calcium burden and modify heavily calcified plaques in order to facilitate stent crossing and correct deployment. In early studies two decades ago it had been already shown to be successful in ~90% of lesions that are either undilatable or uncrossable with balloons.<sup>9</sup>

When resistant calcified lesions are not sufficiently prepared, a stent could still cross and be deployed but remains underexpanded at the end of the procedure, even after aggressive post-dilatation with non-compliant balloons. Since an underexpanded stent significantly increases the risk for stent restenosis and thrombosis (as in our case), it should not be accepted as a PCI result. However, once the device has been

released, the problem of underexpansion is difficult to solve and the best treatment strategy in such a case remains elusive. In our case, simple dilatation with an appropriately sized non-compliant balloon at high pressure did not initially suffice but by inflating the same balloon differently (by pressure escalation 3 times from 12 to 26 Atm), the lesion finally yielded. The options are limited when high-pressure balloon inflations with short non-compliant balloons fail to expand the stents and include modalities such as cutting balloons, rotational atherectomy and excimer laser.<sup>10-12</sup> The most commonly used technique is the ablation of the stent and the calcified plaque protruding through the stent struts by means of high-speed rotational atherectomy that reduces wall thickness, facilitating balloon dilation. Stent ablation is not without potential risks and complications, such as distal embolization of metal particles, no-reflow and peri-procedural or late thrombotic events. Experience is limited and few cases are documented in the literature.<sup>10,11</sup> Thus, the treatment of underexpanded stents after failure of post-dilatation with high-pressure non-compliant balloons is mostly uncharted territory to be avoided by sufficient lesion modification before stenting.

---

#### CONCLUSION

---

Adequate lesion preparation before stent implantation is a principle that should be respected. High-pressure non-compliant balloons, scoring or cutting balloons and rotational atherectomy are the usual modalities that if used in an escalating stepwise approach can ensure sufficient modification of resistant lesions and appropriate stent expansion. Stents should not be deployed in resistant calcified lesions that are not adequately prepared, since incomplete stent expansion can lead to significant restenosis and thrombosis. An incompletely expanded stent consists a problem that should not be overlooked and usually proves particularly difficult to treat, since if post-dilatation with high-pressure non-compliant balloons fails one should most probably recur to stent ablation with rotational atherectomy, which has potential risks and is only scarcely reported in the literature.

#### REFERENCES

1. Uren NG, Schwarzscher SP, Metz JA, et al. Predictors and outcomes of stent thrombosis: an intravascular ultrasound registry. *Eur Heart J* 2002;23:124-132.
2. Holmes DR, Jr., Kereiakes DJ, Garg S, et al. Stent thrombosis. *J Am Coll Cardiol* 2010;56:1357-1365.
3. Daemen J, Wenaweser P, Tsuchida K, et al. Early and late coronary stent thrombosis of sirolimus-eluting and paclitaxel-eluting stents in routine clinical practice: data from a large two-institutional cohort study. *Lancet* 2007;369:667-678.
4. Cutlip DE, Windecker S, Mehran R, et al. Clinical end points in coronary stent trials: a case for standardized definitions. *Circulation* 2007;115:2344-2351.
5. van Werkum JW, Heestermans AA, Zomer AC, et al. Predictors of coronary stent thrombosis: the Dutch Stent Thrombosis Registry. *J Am Coll Cardiol* 2009;53:1399-1409.
6. Fujii K, Carlier SG, Mintz GS, et al. Stent underexpansion and residual reference segment stenosis are related to stent thrombosis after sirolimus-eluting stent implantation: an intravascular ultrasound study. *J Am Coll Cardiol* 2005;45:995-998.
7. Stillabower ME. Longitudinal force focused coronary angioplasty: a technique for resistant lesions. *Cathet Cardiovasc Diagn* 1994;32:196-198.
8. Yazdanfar S, Ledley GS, Alfieri A, Strauss C, Kotler MN. Parallel angioplasty dilatation catheter and guide wire: a new technique for the dilatation of calcified coronary arteries. *Cathet Cardiovasc Diagn* 1993;28:72-75.
9. Brogan WC, 3rd, Popma JJ, Pichard AD, et al. Rotational coronary atherectomy after unsuccessful coronary balloon angioplasty. *Am J Cardiol* 1993;71:794-798.
10. Kobayashi Y, Teirstein P, Linnemeier T, Stone G, Leon M, Moses J. Rotational atherectomy (stentablation) in a lesion with stent underexpansion due to heavily calcified plaque. *Catheter Cardiovasc Interv* 2001;52:208-211.
11. Medina A, de Lezo JS, Melian F, Hernandez E, Pan M, Romero M. Successful stent ablation with rotational atherectomy. *Catheter Cardiovasc Interv* 2003;60:501-504.
12. Sunew J, Chandwaney RH, Stein DW, Meyers S, Davidson CJ. Excimer laser facilitated percutaneous coronary intervention of a nondilatable coronary stent. *Catheter Cardiovasc Interv* 2001;53:513-517.