

## TECHNIQUES

# Insights into Catheter Ablation of Ventricular Tachycardias in Arrhythmogenic Right Ventricular Cardiomyopathy/Dysplasia\*

Sokratis Pastromas, MD, Emmanuel Koutalas, MD

Department of Electrophysiology,  
Heart Center, Leipzig, Germany

**KEY WORDS:** *sudden cardiac death; arrhythmogenic right ventricular cardiomyopathy/dysplasia; ventricular tachycardia/fibrillation; implantable cardioverter defibrillator; catheter ablation/mapping*

#### ABBREVIATIONS

AAA = antiarrhythmic agents;  
ARVC/D = arrhythmogenic right ventricular cardiomyopathy/dysplasia;  
EAM = electro-anatomical mapping;  
EPS = electrophysiology study;  
ICD = implantable cardioverter defibrillator;  
LV = left ventric-le(-ular);  
RFA = radiofrequency catheter ablation;  
RV = right ventric-le(-ular);  
SCD = sudden cardiac death;  
VAs = ventricular arrhythmias;  
VF = ventricular fibrillation;  
VT = ventricular tachycardia

#### Address for correspondence:

Sokratis Pastromas, MD, Department of Cardiology, Henry Dunant Hospital, Athens, Greece;  
e-mail: [spastromas@yahoo.gr](mailto:spastromas@yahoo.gr)

Conflict of Interest: none declared

\*Reproduced with permission from *Rhythmias* 2015;10(4): 80-86 ([www.rhythmias.gr](http://www.rhythmias.gr))

#### ABSTRACT

Arrhythmogenic right ventricular cardiomyopathy/ dysplasia (ARVC/D), mostly affecting young/middle-aged individuals, poses a significant risk of malignant ventricular arrhythmias (VAs) and subsequent sudden cardiac death (SCD). Antiarrhythmic agents (AAA) provide insufficient arrhythmia suppression and prevention and can be proarrhythmic. Thus, the implantable cardioverter defibrillator (ICD) is considered the first-line treatment, especially in patients with secondary prevention indication. Nevertheless, catheter ablation is an additional therapy to the ICD which has proved its efficacy in primary and secondary prevention of fatal arrhythmias and sudden cardiac death. The superiority of the combined endo- and epicardial VT ablation in this population is clear since the ARVC/D substrate has been shown to be mostly epicardial. Due to progressive nature of ARVC/D, ablation seems to be a useful tool for the patients who experience recurrent VT episodes or electrical storms.

#### INTRODUCTION

Arrhythmogenic right ventricular cardiomyopathy/ dysplasia (ARVC/D) poses a significant risk of malignant ventricular arrhythmias (VAs) and subsequent sudden cardiac death (SCD).<sup>1</sup> On top of the fact that young/ middle-aged individuals are mostly affected, imperative issues emerge regarding primary and secondary prevention of catastrophic ventricular arrhythmogenesis.<sup>1</sup> Antiarrhythmic agents (AAA) provide insufficient arrhythmia suppression and prevention and can be proarrhythmic.<sup>2</sup> In this context, implantable cardioverters-defibrillators (ICDs) are considered the first-line treatment, especially in patients with an indication for secondary prevention of SCD.<sup>3</sup> However, a substantial amount of discrepancy remains as to which patients without documented VAs are optimal candidates for ICD implantation, based on arrhythmic risk stratification schemes. Prospective studies in patients with implanted ICDs according to the arrhythmic risk factors let somebody see that only a minority of them receive appropriate ICD intervention, while significant proportions present with inappropriate ICD interventions and/or device-related complications.<sup>4</sup>

In all cases, what ICDs are incapable of is prevention of arrhythmias occurrence and, of more importance, modification or elimination of the arrhythmogenic substrate. Radiofrequency catheter ablation (RFA) effectively modifies and/or eliminates abnormal arrhythmogenic substrate. In post-infarction patients with mainly subendocardial scars and slow conduction areas, RFA is an established therapy for malignant ventricular arrhythmias.<sup>5</sup> Regarding ARVC/D, though, the abnormal substrate appears not to be confined to the subendocardium. In fact, recent research work has demonstrated the presence of scarring, creating re-entry circuits due to slow conduction and unidirectional block promoting thus arrhythmogenesis in the epicardium.<sup>6</sup> State-of-the-art ablation procedures include epicardial electroanatomical mapping (EAM) and ablation, not only after failure of endocardial ablation, but even as first-line approach.<sup>7</sup> The combined use of endocardial and epicardial ablation has given more than encouraging results in patients presenting with VAs and has raised significantly rates of arrhythmia-free survival.<sup>7,8</sup>

---

#### ELECTROANATOMIC AND ELECTROPHYSIOLOGIC SUBSTRATE

---

ARVC/D is a genetically determined cardiomyopathy which typically affects the right ventricle (RV); involvement of the left ventricle (LV) is now commonly recognized, especially in the late stages of the disease, while recent data suggests that it may in fact precede the onset of significant RV dysfunction.<sup>9-12</sup> It primarily results from defective desmosomal proteins with the subsequent myocardial degeneration and death causing replacement of right and/or ventricular myocardium by fibrofatty tissue.<sup>9,13,14</sup> Along with RV enlargement and dysfunction, RV aneurysms are typical of ARVC/D and are detected in the so-called “triangle of dysplasia”, i.e., RV outflow tract, apex, and outflow tract.<sup>15</sup> Sites of left ventricle (LV) involvement, demonstrated by late enhancement cardiac magnetic resonance (LECMR), include more often the inferolateral wall, inferior wall-septal junction, inferior wall and septum.<sup>12</sup> Through functional myocardial tissue degeneration and replacement, the two principal prerequisites for reentry are met. The intercellular coupling is deranged leading to slower impulse conduction and, secondly, areas of anatomic and/or functional unidirectional block are created.

High-density electroanatomic mapping (EAM) has been used to characterize the electrical correlates of arrhythmogenic substrate in ARVC/D. Bipolar RV endocardium signals are considered normal if they display up to 3 deflections from baseline, with amplitude of more than 1.5 mV, while dense scar is demonstrated by amplitudes less than 0.5 mV.<sup>16,17</sup> Regarding the epicardium, an amplitude in the bipolar setting of more than 1.0 mV is considered normal, which corresponds to 95% of the signals recorded at a distance at least 1 cm from

the defined large vessel coronary vasculature.<sup>18</sup> In patients with minimal or moderate endocardial disease involvement, the extent of epicardial scar can also be reliably evidenced with application of endocardial unipolar mapping, using a cutoff of <5.5 mV for normal endocardial unipolar voltage.<sup>19</sup> The areas of endocardial electroanatomic scar, as defined by studies conducted to seek endocardial ventricular tachycardia (VT) ablation efficacy, extend from the tricuspid or pulmonary valve to the RV free wall, while the RV apex seems to be excluded.<sup>20,21</sup> High-density EAM in the epicardium has revealed that low-voltage epicardial areas correspond well to endocardial anatomical ones but extend further over the surface of the RV.<sup>7,22</sup> In ARVC/D the RV epicardium activation is delayed and independent of the underlying endocardium activation. In particular, compartmentalization of the epicardium from the endocardium and VT circuits defined only to the epicardium are created, explaining the low rates of success and high rates of VT recurrence when an endocardial-only ablative strategy is applied.<sup>6</sup> Of importance, the existence of scarring and low voltage areas does not dogmatically predict arrhythmic events. As Santangeli et al<sup>23</sup> report, in primary prevention patients prospectively followed after ICD implantation, fragmented and late activation potentials recorded within the scar and not RV electroanatomic scar itself, were linked with subsequent malignant arrhythmogenesis.

---

#### RISK STRATIFICATION AND MANAGEMENT

---

The majority of affected individuals develop symptoms during the second to fourth decade of life. The latter, especially during the early “concealed” stage of the disease, where gross changes in the cardiac muscle architecture are difficult or impossible to define, include mainly malignant ventricular arrhythmias, syncope and in some cases SCD.<sup>10</sup> Survivors of cardiac arrest present mainly with sustained ventricular tachycardia (VT) or ventricular fibrillation (VF), receive an ICD in the context of secondary prevention and have rates of VT/VF incidence of up to 70% during follow up.<sup>24,25</sup>

The subgroup of patients without documented VAs is typically stratified according to arrhythmic risk factors. Such factors include induction of VT during an electrophysiology study (EPS), detection of non-sustained VT on noninvasive monitoring, male gender, severe RV dilation, extensive RV involvement, young age at presentation (less than 5 years), LV involvement, prior cardiac arrest, unexplained syncope and genotypes of ARVC/D associated with a high risk for SCD.<sup>3</sup> The John Hopkins registry reported 48% appropriate ICD interventions during follow-up. Inducibility at EPS, non-sustained VT and high burden of ventricular ectopy were independent strong predictors of appropriate ICD therapy.<sup>26</sup> On the other hand, Corrado et al report a lower, albeit signifi-

cant, percentage of 24%. They define syncope as an important predictor of life-saving ICD intervention, while programmed ventricular stimulation seems to have a low predictive accuracy for appropriate ICD intervention.<sup>4</sup>

CATHETER ABLATION

A significant proportion of appropriate ICD therapies is delivered due to episodes of electrical storm.<sup>27,28</sup> The aforementioned data sufficiently highlight the urge for therapies that move one step forward in the field of arrhythmogenic substrate modification/elimination rather than malignant VAs termination. General recommendations regarding catheter ablation indications in patients with structural heart disease are summarized in Table 1.<sup>29</sup>

In patients with ischemic cardiomyopathy (ICM), RFA has been shown to be more efficacious compared to individuals with non-ischemic cardiomyopathies. In the field of ARVC/D the results from the studies carried out in patients with VTs are controversial. Although there are no large clinical trials in this population, the results are not encouraging regarding RFA. As in ICM, two end-points have been proposed indicating acute success, either non-inducibility of the clinical VT or of any inducible VTs. The first clinical studies during late 90's enrolled only a few patients and the procedures were carried out conventionally, typically with pace- and entrainment mapping techniques, without using EAM systems. One of them was conducted by Harrada et al, who enrolled 7 patients using entrainment endocardial mapping to identify the reentrant circuit. They demonstrated that RFA was most successful at narrow isthmuses of the re-entry circuits, proving that in this population re-entry predominates as VT generating mechanism.<sup>30</sup> Although nowadays RFA is the commonly used technique, in the early 1990s direct current (DC) fulguration was also widely used. According to Fontaine et al, who compared the efficacy of these two techniques in patients with ARVC/D, the effectiveness/efficacy of RFA alone was about 40%, while DC fulguration was successful after RFA failure. In these 50 patients, the success rate during the follow up was 81% for DC ablation and 93% for combined DC and RFA.<sup>31</sup>

Moreover, in the past years a non-contact mapping technique with a balloon catheter was introduced in the clinical

practice of VT ablation. This technique using the far-field unipolar electrograms obtained from the endocardium allows the creation of an activation map, although sometimes it is not possible to detect the low voltage electrograms. In patients with ARVC/D, results seem to be promising, since in a group of 32 subjects acute success was achieved in 84.4% of them and at the end of follow up 81.3% were free of VT.<sup>32</sup>

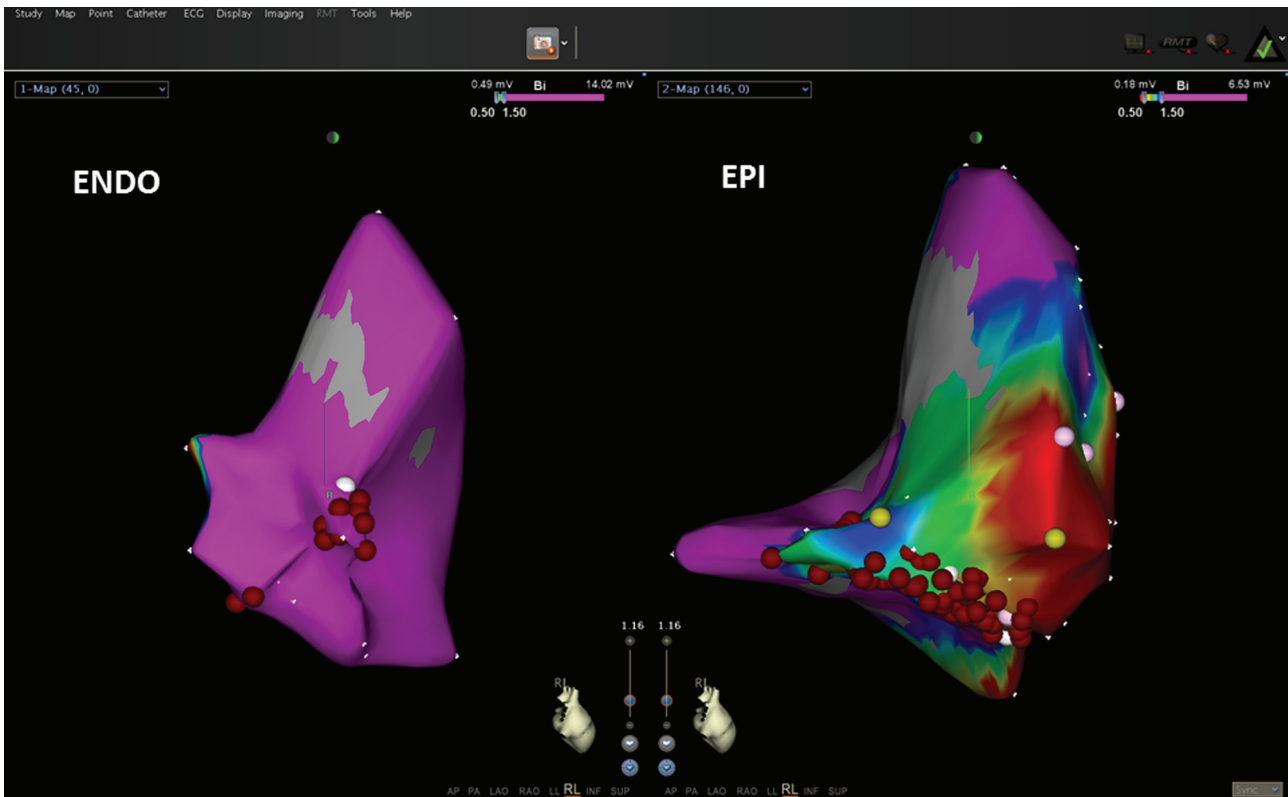
Table 2 summarizes the results from the most important published clinical trials for VT ablation in patients with ARVC/D. Due to different ablation techniques, endpoints used and the overall post ablation management of the patients, regarding the use of AAA, ICDs and follow up duration, there is an obvious variability among these results. Most of the studies published after 2000 included patients with implanted ICDs, either before inclusion or during the study, since its effectiveness is undeniable. A large observational study showed that about half of the patients with ARVC/D had at least one episode of ventricular tachyarrhythmia that required ICD therapy over a mean follow-up period of 3.3 years, and 24% experienced potentially fatal arrhythmias as ventricular fibrillation or flutter, suggesting thus the beneficial effect of the ICDs.<sup>33</sup> Ablation in these patients seems to reduce the number of VA episodes especially when it is performed both endocardially and epicardially. Recently published data showed that, in a population of 49 patients, 52.2% were free of VAs or ICD therapy during a 3-year follow up after endocardial ablation compared to 84.6% after combined endo- and epi-cardial ablation (P=0.029). Moreover, patients with frequent premature ventricular contractions after ablation were more likely to have VA recurrence or ICD therapy (P <0.001).<sup>7</sup>

Although the acute success rate after VT ablation seems to be satisfactory in patients using an endocardium-confined approach, late recurrence remains a principal drawback. Recent advances in EAM and catheter ablation technology have contributed to the better understanding of the VT substrate in ARVC/D. Electroanatomical mapping data were compared between patients with ARVC/D and patients without structural heart disease who both underwent endocardial and epicardial mapping (Fig. 1). The identified scar area was larger in the epicardium compared to the endocardium (P=0.04). Additionally, ARVC/D patients had longer epicardial and endocardial activation times compared to controls. Specifically, in these patients a more than four-fold greater delay between the last

TABLE 1. Indications for catheter ablation of ventricular tachycardia associated with structural heart disease<sup>29</sup>

1	Recurrent symptomatic sustained monomorphic VT (SMVT), including VT terminated by an ICD despite AAA or when AAA are not tolerated or not desired
2	Control of incessant SMVT or VT storm that is not due to a transient reversible cause
3	Recurrent sustained polymorphic VT and VF refractory to AAA when there is suspected trigger that can be targeted for ablation

AAA = antiarrhythmic agents; ICD = implantable cardioverter defibrillator; VF = ventricular fibrillation; VT = ventricular tachycardia



**FIGURE 1.** Endocardial (ENDO) and epicardial (EPI) voltage maps with the CARTO-3 system of a patient submitted for ventricular tachycardia ablation and diagnosis of ARVD in right lateral view. A low-voltage area is present in the epicardial surface. The epicardial scar is wider than the endocardial. Normal myocardium ( $>1.5$  mV) is coded in purple, scar ( $<0.5$  mV) is coded in red. Red dots: radiofrequency applications.

recorded endocardial activation and the latest epicardial right ventricular sites was demonstrated, simultaneously with the presence of late epicardial isolated potentials. On the contrary, the control patients had the latest epicardial activation within 20 ms after the latest RV endocardial activation.<sup>6</sup> The same activation template became clear after direct surgical mapping in 4 patients with ARVC/D, which showed the earliest activation points in the epicardium.<sup>34</sup> Garcia et al performed epicardial ablation in 12 out of 13 patients with failed endocardial ablation and after a mean follow up of  $18 \pm 13$  months, 77% of the patients were free of sustained VT. The authors noted that the epicardial VT origin site was in proximity to the tricuspid annulus at the acute angle of the RV and this epicardial successful ablation region was in some of the patients  $>1$  cm away from the previous failed endocardial ablation site.<sup>35</sup> More recently, Bai et al<sup>7</sup> compared the long-term results by using endocardium-confined ablation versus endo-epicardial substrate-based ablation in patients with ARVC/D, reporting a rate of freedom from any VT of 52.2% and 84.6%, respectively. The existence of more than 10 premature ventricular complexes per minute was associated with more high percent-

age of VT recurrence. Added to the latter, newer data confirm the superiority of epicardial ablation in this population. In 87 patients from 80 different centers, those who underwent epicardial ablation were free from VT recurrence by 64% and 45% at 1 and 5 years of follow up, respectively, which was significantly larger compared to endocardial RFA ( $P=0.021$ ).<sup>8</sup> The incidence of major complications during the pericardial procedures was about 7.7%, similar to those reported in the literature about all VT categories epicardial ablation. Epicardial ablation seems also to be efficient in pediatric patients with ARVC. Pokushalov et al<sup>36</sup> showed that in 17 pediatric patients with recurrent VTs due to failed prior endocardial ablation or AAA inefficacy, epicardial VT ablation resulted to non-inducibility of the VT in most of them (16 of 17 pts). After a follow-up period of  $26 \pm 15$  months without receiving AAA, 70.6% of them were free of arrhythmia episodes.

---

## CONCLUSION

---

In patients with ARVC/D, catheter ablation is an ad-

TABLE 2. Clinical Outcomes of Ventricular Tachycardia Ablation in Patients with ARVC/D.

Study	Patients characteristics	No of procedures/episodes	Ablation approach	Acute success rate	Complications	Recurrence rates	Additional comments
Harada et al <sup>30</sup>	7 pts, FU 19 ± 7 months	8 VTs	Entrainment endocardial mapping & RF	17% of exit sites, 67% of proximal sites & 8% of outer loop sites		1 pt (chemical ablation RCA)	RFA is most successful at narrow isthmuses of the reentry circuits
Fontaine G et al <sup>31</sup>	50 pts, 48±15 yrs old during 16 yrs, mean FU 5.8 yrs		Endocardial mapping, DC (27 pts) & RFA	Clinical success after 3 sessions RFA+DC: ~90%	Death rate 3% per year, 3 pts had tamponade		RFA plus DC ablation effective after failed RFA in the same session
Marchlinski et al <sup>37</sup>	21 pts mapping/19 pts abl, all had ICD, FU 27±22 months	66 VTs	21 pts endo (RV, 18 pts LV)	14/19 (74%) acute success	none	17/19 pts no VT, 2 pts (≤1 episode/3 months FU)	>1 Ablation required in 13 pts
Verma et al <sup>38</sup>	22 pts, aged 41±15 y, 18 pts ICD, median FU 37 months	3±2 VT/pt	Endocardial with CARTO	18/22 pts	1 pt had cardiac tamponade	8 pts, but with slower VTs	Scar areas: TA, proximal RVOT, anterior/inferior-apical walls
Satomi et al <sup>20</sup>	17 pts, 26 ± 15 months	13 stable VTs, 13 unstable VTs	Endocardial with CARTO	13/17 pts were free of symptoms, 2pts received ICD	No	2 pts had VT recurrence	Diastolic or fragmented potentials were recorded along TA or RVOT
Dalal et al <sup>40</sup>	24 pts, 36±9 yrs, 19 pts ICD, FU 32±36 months	48 RFA	10 with 3D mapping/38 conventional	22/48 successful procedures	1 procedure related death	8±10 months recurrence time after abl., 40/48 procedures (85%), 4 pts cl. storm	no difference in VT recurrence-free survival between patients with complete or partial procedural success and failure
Yao et al <sup>32</sup>	32 pts, 37±13 yrs, 2 pts had ICD, 28.6 ±16 months FU	67 induced VTs, CL: 210±32 ms	Non contact mapping, Ensite	27/32 pts	None	81.3% free of VTs without AAA	Non contact mapping is useful for fast VTs ablation
Reithmann et al <sup>40</sup>	11 pts, 53±13 y, 6 pts had ICD implanted at end of FU, 27±17 months	18 VTs	Entrainment mapping with CARTO	10 VTs (9 pts) successful ablated	No complications	6/11 pts had recurrence (FU every 3 months)	isolated diastolic potentials in SR were associated with successful RFA at reentry circuit isthmus sites
Garcia et al <sup>35</sup>	13 pts, 43±15 yrs, FU 18±13 months,	Recurrent VTs after endocardial ablation (mean 2 abl.)	Endo- & epicardial with CARTO	11/13 pts (85%) non inducible monomorphic VT, 12/13 pts (92%) elimination of all VTs	No complications	10/13 pts (77%) free of sustained VT	ARVC/D is associated with a more extensive epicardial area of electrogram abnormalities & frequently basal RV wall thickening

TABLE 2. (continued) Clinical Outcomes of Ventricular Tachycardia Ablation in Patients with ARVC/D.

Study	Patients characteristics	No of procedures/episodes	Ablation approach	Acute success rate	Complications	Recurrence rates	Additional comments
Pokushalov et al <sup>36</sup>	17 pediatric pts, 14 ±4 y, FU 26±15 mos, recurrent VTs failure AAD endo- prior ablation, 5 pts had ICD		Endo- & epi-cardial	16/17 pts (94.1%) had non-inducible VT	4 pts had pericardial effusion	12 pts (70.6%) free of arrhythmia	Failure of endocardial RFA due to: RV perianular thickness, 45% of pts had mismatch of endo- & epi-findings, in fibrotic areas endo-cardial ablation was ineffective
Komura et al <sup>41</sup>	35 pts (ICD & RFA), 5 pts ICD+RFA, 14 pts RFA, 45.6± 15.6 y, FU 54.5±48.2 mos					19/10 pts RFA (52.6%) 14.0±20.1 mos, 18/30 pts received ICD, recurrence 6/18 pts (33%) at 5.3±4.0 mos	ICD reduced recurrence of VTs compared to RFA
Nair et al <sup>42</sup>	15 pts, 44± 15 y, 5 pts had ICD, FU 25± 16 months	26 inducible VTs	Only endo-cardial VTs, (Ensite system)	23/26 VTs were successfully ablated	No complications	2 pts had recurrence of non-clinical VT	AAA discontinued after 6 months
Bai et al <sup>7</sup>	49 pts with ICD, FU 1224± 310 d endo-, 1175±112 days endo-epi-cardial	2 VTs/pt (median)	23 endo-, 26 endo-/epi-cardial with CARTO	End point: non-inducible suMVT	No major	52.2% group 1 and 84.6% in group 2 free of VA	Endo-epicardial RFA results in discontinuation of AAA; PVCs after RFA was associated with recurrence
Della Bella et al <sup>43</sup>	13 pts, 17.3± 18.2 months		Endo-/epi-cardial	9 (69.2%) non-inducible VT	1 pt minor complication	4 pts (3 with the same morphology)	
Philips et al 2012 <sup>8</sup>	87 pts, 38± 13 years, 95% had ICD, mean FU 88.3±66 months	175 procedures, average 2.3 procedures/pt	Endo- & epi-cardial	47% acute/38% partial success, & procedural failure in 15% of 160 procedures, 53% of pts had repeat ablations	2 major associated with epicardial	19% freedom from VT after a single endocardial RFA compared to 45% after a single epi-cardial RFA at 5 y (P=0.021)	VT-free survival was significantly longer after epicardial RFA than after endocardial (P=0.003)
Haqqani et al <sup>6</sup>	18 pts, 43± 15 years compared to 6 pts with normal heart, 15/18 pts had ICDs	28 VTs were induced, 9 were mappable	Endo- & epi-cardial with CARTO	20/22 VTs after epicardial ablation were non-inducible			Epicardial RV activation pattern is often independent of endocardial activation suggesting that the fibrosis may compartmentalize the endocardium from the epicardium

ditional therapy to the ICD which has proved its efficacy in primary and secondary prevention of fatal arrhythmias and sudden cardiac death. The superiority of the combined endo- and epicardial VT ablation in this population is clear, since the ARVC/D substrate has been shown to be mostly epicardial. Due to progressive nature of ARVC/D, ablation seems to be a useful tool for the patients who experience recurrent VT episodes or electrical storms. Using the new three-dimensional (3D) EAM mapping systems we are able to modify the arrhythmogenic endocardial and/or epicardial substrate and to abolish the re-entrant circuits which are responsible for the genesis of these macroreentry or focal tachycardias. Larger well organized multicenter trials are required to investigate the long-term effect favorable or not of the ablation therapy in these patients using the current endocardial and epicardial approach.

## REFERENCES

- Marcus FI, McKenna WJ, Sherrill D, et al. Diagnosis of arrhythmogenic right ventricular cardiomyopathy/ dysplasia: proposed modification of the Task Force Criteria. *Eur Heart J* 2010;31:806-814.
- Marcus GM, Glidden DV, Polonsky B, et al. Multi-disciplinary study of right ventricular dysplasia investigators. Efficacy of antiarrhythmic drugs in arrhythmogenic right ventricular cardiomyopathy: a report from the North American ARVC Registry. *J Am Coll Cardiol* 2009;54:609-615.
- Epstein AE, DiMarco JP, Ellenbogen KA, et al. ACC/AHA/HRS 2008 Guidelines for Device-Based Therapy of Cardiac Rhythm Abnormalities: a report of the ACC/AHA Task Force on Practice Guidelines developed in collaboration with the AATS & STS. *J Am Coll Cardiol* 2008;51:e1-62.
- Corrado D, Calkins H, Link MS, et al. Prophylactic implantable defibrillator in patients with arrhythmogenic right ventricular cardiomyopathy/dysplasia and no prior ventricular fibrillation or sustained ventricular tachycardia. *Circulation* 2010;122:1144-1152.
- Haqqani HM, Marchlinski FE. Electrophysiologic substrate underlying postinfarction ventricular tachycardia: characterization and role in catheter ablation. *Heart Rhythm* 2009;6(Suppl. 8):S70-76
- Haqqani HM, Tschabrunn CM, Betensky BP, et al. Layered Activation of Epicardial Scar in Arrhythmogenic Right Ventricular Dysplasia: Possible Substrate for Confined Epicardial Circuits. *Circ Arrhythm Electrophysiol* 2012;5:796-803.
- Bai R, Di Biase L, Shivkumar K, et al. Ablation of ventricular arrhythmias in arrhythmogenic right ventricular dysplasia/ cardiomyopathy: arrhythmia-free survival after endo-epicardial substrate based mapping and ablation. *Circ Arrhythm Electrophysiol* 2011;4:478-485.
- Philips B, Madhavan S, James C, et al. Outcomes of catheter ablation of ventricular tachycardia in arrhythmogenic right ventricular dysplasia/cardiomyopathy. *Circ Arrhythm Electrophysiol* 2012;5:499-505.
- Basso C, Corrado D, Marcus FI, Nava A, Thiene G. Arrhythmogenic right ventricular cardiomyopathy. *Lancet* 2009;373:1289-1300.
- Basso C, Thiene G, Corrado D, Angelini A, Nava A, Valente M. Arrhythmogenic ventricular cardiomyopathy: dysplasia, dystrophy or myocarditis? *Circulation* 1996;94:983-991.
- Corrado D, Basso C, Thiene G, et al. Spectrum of clinicopathologic manifestations of arrhythmogenic right ventricular cardiomyopathy/dysplasia: a multicenter study. *J Am Coll Cardiol* 1997;30:1512-1520.
- Sen-Chowdhry S, Syrris P, Ward D, Asimaki A, Sevdalis E, McKenna WJ. Clinical and genetic characterization of families with arrhythmogenic right ventricular dysplasia/cardiomyopathy provides novel insights into patterns of disease expression. *Circulation* 2007;115:1710-20.
- McKoy G, Protonotarios N, Crosby A, et al. Identification of a deletion in plakoglobin in arrhythmogenic right ventricular cardiomyopathy with palmoplantar keratoderma and wooly hair (Naxos disease). *Lancet* 2000;355:2119-2124
- Sen-Chowdhry S, Syrris P, McKenna WJ. Genetics of right ventricular cardiomyopathy. *J Cardiovasc Electrophysiol* 2005;16:927-935.
- Marcus FI, Fontaine GH, Guiraudon G, et al. Right ventricular dysplasia: a report of 24 adult cases. *Circulation* 1982;65:384-398.
- Marchlinski FE, Callans DJ, Gottlieb CD, Zado E. Linear ablation lesions for control of unmappable ventricular tachycardia in patients with ischemic and nonischemic cardiomyopathy. *Circulation* 2000;101:1288-1296.
- Hsia HH, Callans DJ, Marchlinski FE. Characterization of endocardial electrophysiological substrate in patients with nonischemic dilated cardiomyopathy and monomorphic ventricular tachycardia. *Circulation* 2003;108:704-710.
- Cano O, Hutchinson M Lin D, et al. Electroanatomic substrate and ablation outcome for suspected epicardial ventricular tachycardia in left ventricular nonischemic cardiomyopathy. *J Am Coll Cardiol* 2009;54:799-808.
- Polin GM, Haqqani H, Tzou W, et al. Endocardial unipolar voltage mapping to identify epicardial substrate in arrhythmogenic right ventricular cardiomyopathy/dysplasia. *Heart Rhythm* 2011;8:76-83.
- Satomi K, Kurita T, Suyama K, et al. Catheter ablation of stable and unstable ventricular tachycardias in patients with arrhythmogenic right ventricular dysplasia. *J Cardiovasc Electrophysiol* 2006;17:469-476.
- Nogami A, Sugiyasu A, Tada H, et al. Changes in the isolated delayed component as an endpoint of catheter ablation in arrhythmogenic right ventricular cardiomyopathy: predictor for long-term success. *J Cardiovasc Electrophysiol* 2008;19:681-688.
- Garcia FC, Bazan V, Zado ES, Ren JF, Marchlinski FE. Epicardial substrate and outcome with epicardial ablation of ventricular tachycardia in arrhythmogenic right ventricular cardiomyopathy/dysplasia. *Circulation* 2009;120:366-375.

23. Santangeli P, Russo AD, Pieroni M, et al. Fragmented and delayed electrograms within fibrofatty scar predict arrhythmic events in arrhythmogenic right ventricular cardiomyopathy: Results from a prospective risk stratification study. *Heart Rhythm* 2012; 9:1200-1206.
24. Tavernier R, Gevaert S, De SJ, et al. Long term results of cardioverter-defibrillator implantation in patients with right ventricular dysplasia and malignant ventricular tachyarrhythmias. *Heart* 2001; 85:53-56.
25. Wichter T, Paul M, Wollmann C, et al. Implantable cardioverter defibrillator therapy in arrhythmogenic right ventricular cardiomyopathy: single-center experience of long-term follow-up and complications in 60 patients. *Circulation* 2004; 109:1503-1508.
26. Bhonsale A, James CA, Tichnell C, et al. Incidence and predictors of implantable cardioverter-defibrillator therapy in patients with arrhythmogenic right ventricular dysplasia/cardiomyopathy undergoing implantable cardioverter-defibrillator implantation for primary prevention. *J Am Coll Cardiol* 2011; 58:1485-1496.
27. Li CH, Lin YJ, Huang JL, et al. Long-term follow-up in patients with arrhythmogenic right ventricular cardiomyopathy. *J Cardiovasc Electrophysiol* 2012; 23:750-756.
28. Kozeluhova M, Peichl P, Cihak R, et al. Catheter ablation of electrical storm in patients with structural heart disease. *Europace* 2011; 13:109-113.
29. Aliot EM, Stevenson WG, Almendral-Garrote JM, et al; European Heart Rhythm Association; European Society of Cardiology; Heart Rhythm Society. EHRA/HRS Expert Consensus on Catheter Ablation of Ventricular Arrhythmias: developed in a partnership with the European Heart Rhythm Association (EHRA), a Registered Branch of the European Society of Cardiology (ESC), and the Heart Rhythm Society (HRS); in collaboration with the American College of Cardiology (ACC) and the American Heart Association (AHA). *Europace* 2009; 11:771-817.
30. Harada T, Aonuma K, Yamauchi Y, et al. Catheter ablation of ventricular tachycardia in patients with right ventricular dysplasia: Identification of target sites by entrainment mapping techniques. *Pacing Clin Electrophysiol* 1998; 21:2547-2550.
31. Fontaine G, Tonet J, Gallais Y, et al. Ventricular tachycardia catheter ablation in arrhythmogenic right ventricular dysplasia: a 16-year experience. *Curr Cardiol Rep* 2000; 2:498-506.
32. Yao Y, Zhang S, He DS, et al. Radiofrequency ablation of the ventricular tachycardia with arrhythmogenic right ventricular cardiomyopathy using non-contact mapping. *Pacing Clin Electrophysiol* 2007; 30:526-533.
33. Corrado D, Leoni L, Link MS, et al. Implantable cardioverter-defibrillator therapy for prevention of sudden death in patients with arrhythmogenic right ventricular cardiomyopathy/dysplasia. *Circulation* 2003; 108:3084-3091.
34. Doig JC, Downar E, Saito J, Furniss SS, Bourke JP, Campbell RWF: Localised reentry in ventricular tachycardia of arrhythmogenic right ventricular disease. *Pacing Clin Electrophysiol* 1996; 19:590.
35. Garcia FC, Bazan V, Zado ES, Ren J-F, Marchlinski FE. Epicardial substrate and outcome with epicardial ablation of ventricular tachycardia in arrhythmogenic right ventricular cardiomyopathy/dysplasia. *Circulation* 2009; 120:366-375.
36. Pokushalov E, Romanov A, Turov A, Artyomenko S, Shirokova N, Karaskov A. Percutaneous epicardial ablation of ventricular tachycardia after failure of endocardial approach in the pediatric population with arrhythmogenic right ventricular dysplasia. *Heart Rhythm* 2010; 7:1406-1410.
37. Marchlinski FE, Zado E, Dixit S, et al. Electroanatomic substrate and outcome of catheter ablative therapy for ventricular tachycardia in setting of right ventricular cardiomyopathy. *Circulation* 2004; 110:2293-2298.
38. Verma A, Kilicaslan F, Schweikert RA, et al. Short- and long-term success of substrate-based mapping and ablation of ventricular tachycardia in arrhythmogenic right ventricular dysplasia. *Circulation* 2005; 111:3209-3216.
39. Dalal D, Jain R, Tandri H, et al. Long-term efficacy of catheter ablation of ventricular tachycardia in patients with arrhythmogenic right ventricular dysplasia/cardiomyopathy. *J Am Coll Cardiol* 2007; 50:432-440.
40. Reithmann C, Ulbrich M, Hahnefeld A, Huber A, Matis T, Steinbeck G. Analysis during sinus rhythm and ventricular pacing of reentry circuit isthmus sites in right ventricular cardiomyopathy. *Pacing Clin Electrophysiol* 2008; 31:1535-1545.
41. Komura M, Suzuki J, Adachi S, et al. Clinical course of arrhythmogenic right ventricular cardiomyopathy in the era of implantable cardioverter-defibrillators and radiofrequency catheter ablation. *Int Heart J* 2010; 51:34-40.
42. Nair M, Yaduvanshi A, Kataria V, Kumar M. Radiofrequency catheter ablation of ventricular tachycardia in arrhythmogenic right ventricular dysplasia/cardiomyopathy using non-contact electroanatomical mapping: single-center experience with follow-up up to median of 30 months. *J Interv Card Electrophysiol* 2011; 31:141-147.
43. Della Bella P, Brugada J, Zeppenfeld K, et al. Epicardial ablation for ventricular tachycardia: a European multicenter study. *Circ Arrhythm Electrophysiol* 2011; 4:653-659.