

## IMAGES IN MEDICINE

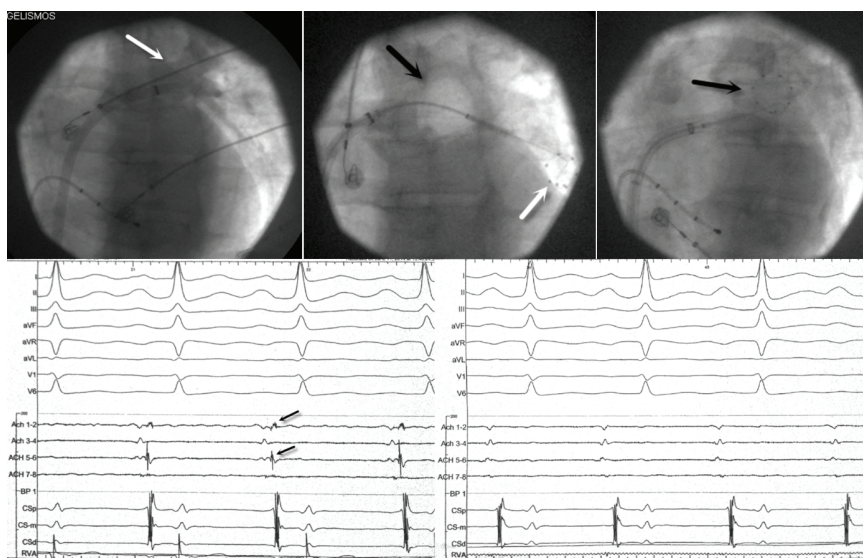
## CryoAblation of Atrial Fibrillation: New Technique / New Expectations

Antonis S. Manolis, MD, Dimosthenis Avramidis, MD,  
Prokopis Papadimitriou, MD, Emmanouil Poulidakis, MD,  
John Tzagarakis, MD, Kostas Kappos, MD

*Department of Cardiology,  
Evangelismos Hospital,  
Athens, Greece*

A 53-year-old gentleman with frequent episodes of idiopathic paroxysmal atrial fibrillation (AF) who had failed rhythm control with two antiarrhythmic drugs was initially submitted to an ablation procedure during which pulmonary vein (PV) isolation was performed with use of a cryothermic balloon in September 2012. After a 3-month blanking period, he remained free of symptoms for over a year. However, over the last one month he has had frequent arrhythmia recurrences with almost weekly episodes. He returned for a repeat ablation procedure.

During the procedure the left atrium was accessed via transeptal catheterization. With use of a circular mapping catheter, electrical activity was assessed within each pulmonary vein. No activity was recorded in the right pulmonary veins. The left pulmonary veins drained into the left atrium via a common trunk (left upper panel, white arrow). Pulmonary vein potentials indicating electrical reconnections were detected in the left pulmonary veins at several points around the perimeter of the veins (left lower panel, black arrows). Subsequently, the veins were successfully re-isolated with use of a second generation 28-mm cryoballoon (mid upper panel, black arrow) by applying 3 cryothermic lesions each of 200-240 seconds in duration at the antrum of the left



*Correspondence to:*  
Antonis Manolis, MD,  
Department of Cardiology,  
Evangelismos Hospital,  
Athens, Greece;  
E-mail: [asm@otenet.gr](mailto:asm@otenet.gr)

*Manuscript received and accepted  
June 29, 2014*

Conflict of Interest: none declared

pulmonary veins. Upon obtaining new local recordings with use of the circular catheter (mid upper panel, white arrow; right upper panel, black arrow), absence of PV potentials was confirmed (right lower panel; PV potentials indicated with black arrows in the left lower panel are absent in the right lower panel). Several spontaneous episodes of AF recorded during the procedure promptly ceased to recur after completion of the cryothermic lesions.



Pulmonary vein isolation with use of radiofrequency ablation is the most common ablation technique for paroxysmal and/or persistent atrial fibrillation (AF).<sup>1</sup> Using cryothermic ablation via a cryoballoon is an alternative, more recently developed, rapidly growing technique. The STOP AF trial has demonstrated that cryoballoon ablation is a safe and effective alternative to antiarrhythmic medication for the treatment of patients with symptomatic paroxysmal AF.<sup>2</sup> This technology has already advanced to a second generation cryoballoon considered to deliver more effective lesions.<sup>3</sup> Results of cryoablation appear at least to be similar with those of radiofrequency ablation, while some investigators have suggested that this may be a faster and possibly safer or even more effective technique.<sup>4</sup> A recent study indicated that use of second-generation 28-mm cryoballoon for pulmonary vein isolation resulted in an 80% 1-year success rate.<sup>5</sup> Another study showed that procedural times were significantly shorter in the cryoballoon approach compared with the radiofrequency method. The most frequent complication during cryoballoon procedures was phrenic nerve palsy, which may occur in up to ~10% of patients, but usually resolves during the follow-up period.<sup>4,6-8</sup>

Ablation techniques for AF are plagued by frequent early and late recurrences, reported to occur in around 30-50% of patients, requiring reablation, which is subsequently associated with better long-term freedom from recurrent AF.<sup>6</sup> The main reason for AF recurrences after an initial procedure is mostly related to reconnections (recovery of conduction between the PVs and the left atrium) at some segments of the perimeter of PVs, rather than extrapulmonary sources. This was the cause of AF recurrence in the present case, which was effectively remedied with re-ablation, which makes a repeat procedure worth performing in patients with a recurring arrhythmia.

Cryoablation with the cryoballoon is a rapidly emerging alternative and promising technique with a favorable safety

profile for AF ablation used to achieve circumferential PV isolation. Phrenic nerve palsy while ablating the right PVs is more common with cryoablation rather than radiofrequency ablation, albeit rarely a permanent complication. This new technique has raised expectations for a faster, safer (less thrombogenic and/or less traumatic to the esophagus) and perhaps more effective tool for PV isolation in patients with paroxysmal and/or persistent AF.<sup>8</sup> However, head-to-head comparisons with radiofrequency ablation are needed before this technique is more widely adopted.

## REFERENCES

1. Cappato R, Calkins H, Chen S, et al. Updated worldwide survey on the methods, efficacy, and safety of catheter ablation for human atrial fibrillation. *Circ Arrhythmia Electrophysiol* 2010;3:32-38.
2. Packer DL, Kowal RC, Wheelan KR, et al; STOP AF Cryoablation Investigators. Cryoballoon ablation of pulmonary veins for paroxysmal atrial fibrillation: first results of the North American Arctic Front (STOP AF) pivotal trial. *J Am Coll Cardiol* 2013;61:1713-1723.
3. Bordignon S, Fürnkranz A, Dugo D, et al. Improved lesion formation using the novel 28 mm cryoballoon in atrial fibrillation ablation: analysis of biomarker release. *Europace* 2014;16:987-993.
4. Mugnai G, Chierchia GB, de Asmundis C, et al. Comparison of pulmonary vein isolation using cryoballoon versus conventional radiofrequency for paroxysmal atrial fibrillation. *Am J Cardiol* 2014;113:1509-1513.
5. Metzner A, Reissmann B, Rausch P, et al. One-year clinical outcome after pulmonary vein isolation using the second-generation 28-mm cryoballoon. *Circ Arrhythm Electrophysiol* 2014; 7:288-292.
6. Andrade JG, Khairy P, Macle L, et al. Incidence and significance of early recurrences of atrial fibrillation after cryoballoon ablation: insights from the multicenter Sustained Treatment of Paroxysmal Atrial Fibrillation (STOP AF) Trial. *Circ Arrhythm Electrophysiol* 2014;7:69-75.
7. Metzner A, Rausch P, Lemes C, et al. The incidence of phrenic nerve injury during pulmonary vein isolation using the second-generation 28 mm cryoballoon. *J Cardiovasc Electrophysiol* 2014;25:466-470.
8. Martins RP, Hamon D, Cisari O, et al. Safety and efficacy of a second-generation cryoballoon in the ablation of paroxysmal atrial fibrillation. *Heart Rhythm* 2014;11:386-393.