

CASE REPORT

Catheter Ablation of Ventricular Extrasystoles Originating from the Left Coronary Cusp

Konstantinos P. Letsas, MD, FESC, Michalis Efremidis, MD,
Konstantinos Vlachos, MD, Dimitrios Asvestas, MD, Antonios Sideris, MD

ABSTRACT

We describe the case of a 55-year-old man with frequent ventricular premature beats displaying inferior axis and positive QRS concordance in precordial leads. The arrhythmia was successfully ablated from the left coronary cusp. The electrocardiographic and electrophysiological characteristics of this arrhythmia are discussed.

Invasive Cardiac Electrophysiology Laboratory, Second Department of Cardiology, Evangelismos General Hospital of Athens, Athens, Greece

KEY WORDS: *premature ventricular extrasystoles; ventricular tachycardia; cardiac arrhythmias; catheter ablation*

ABBREVIATIONS

ECG = electrocardiogram

LCC = left coronary cusp

LVOT = left ventricular outflow tract

VPBs = ventricular premature beats

INTRODUCTION

Idiopathic ventricular ectopy, defined as ventricular ectopy in the absence of structural heart disease, usually originates in the right ventricular outflow tract displaying a left bundle branch block morphology with an inferior axis and less commonly in the left ventricle typically exhibiting a right bundle branch block morphology. Left ventricular outflow tract (LVOT) ventricular premature beats (VPBs) are usually mapped to the region of aortic cusps.¹⁻⁵ Frequent VPBs, regardless of their origin, may be associated with a form of left ventricular cardiomyopathy that is reversed by catheter ablation of the VPBs. We herein present a case of a patient with symptomatic frequent LVOT VPBs, which were successfully ablated from the left coronary cusp.

CASE PRESENTATION

A 55-year-old man with a history of palpitations was referred to our hospital for further evaluation. Baseline electrocardiogram (ECG) showed frequent VPBs displaying inferior axis and positive QRS concordance in the precordial leads suggestive of a left ventricular outflow tract (LVOT) origin (Figure 1a). Ambulatory recordings demonstrated more than 10,000 VPBs per day. Echocardiography revealed normal left ventricular ejection fraction. The patient was symptomatic, while β -blockers and calcium channel blockers failed to control the arrhythmia. An electrophysiology study was then carried out, whereby a detailed activation mapping of the VPBs was performed using a 3-dimensional electroanatomical mapping system (CARTO 3, Biosense Webster, Inc., Diamond Bar, CA, USA). Endocardial left ventricular mapping, as well as

Correspondence to:

Konstantinos P. Letsas, MD,
Second Department of Cardiology,
Evangelismos General Hospital of
Athens, 10676, Athens, Greece;
Fax: +30-210-6513317;
e-mail: k.letsas@mail.gr

Manuscript received September 28, 2013;

Revised manuscript received December 19, 2013; Accepted December 27, 2013

Conflict of interest: none declared

epicardial mapping of all coronary cusps was performed using a 3.5-mm irrigated-tip catheter (NaviStar ThermoCool, Biosense Webster). The earliest endocardial activation site of the VPBs was identified at the LVOT beneath the left coronary cusp (LCC), while the earliest epicardial activation site was identified within the LCC (Figure 2). Both sites displayed a near perfect pace-mapping without significant differences (Figure 1b and 1c). The arrhythmia was partially suppressed following radiofrequency energy application at the endocardial site. Following aortography, energy delivery within the LCC (25 W, 50° C) where the earliest local ventricular activation preceded the QRS complex by 21 ms (Figure 1d) abolished all VPBs.

DISCUSSION

Idiopathic ventricular arrhythmias originating from the aortic cusps are not so rare. These tachycardias originate from extensions of ventricular myocardium that cross the aortic annulus.¹ The site of origin is usually the LCC (54.5%).² Several ECG characteristics have been proposed for the identification of LCC ventricular arrhythmias. Pacing within the LCC typically produces a multiphasic QRS morphology consistent with an

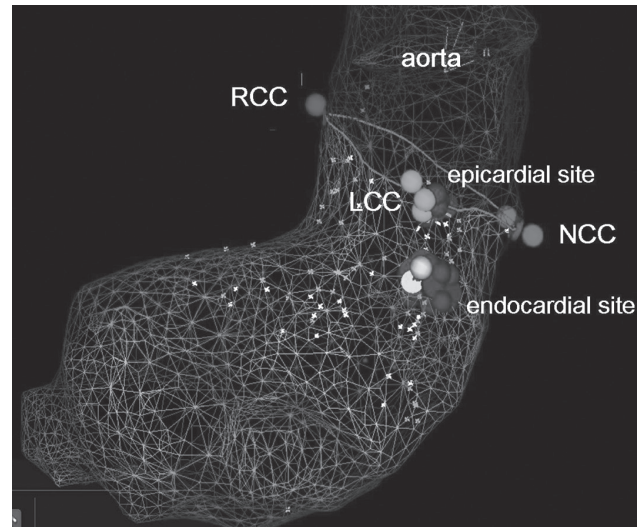


FIGURE 2. A left ventricular outflow tract (LVOT) mesh model showing the anatomic position of the left (LCC), right (RCC) and non-coronary cusps (NCC). The earliest endocardial activation site was identified at the LVOT beneath the LCC, while the earliest epicardial activation site was identified within the LCC. Radiofrequency energy delivery within the LCC abolished the arrhythmia.

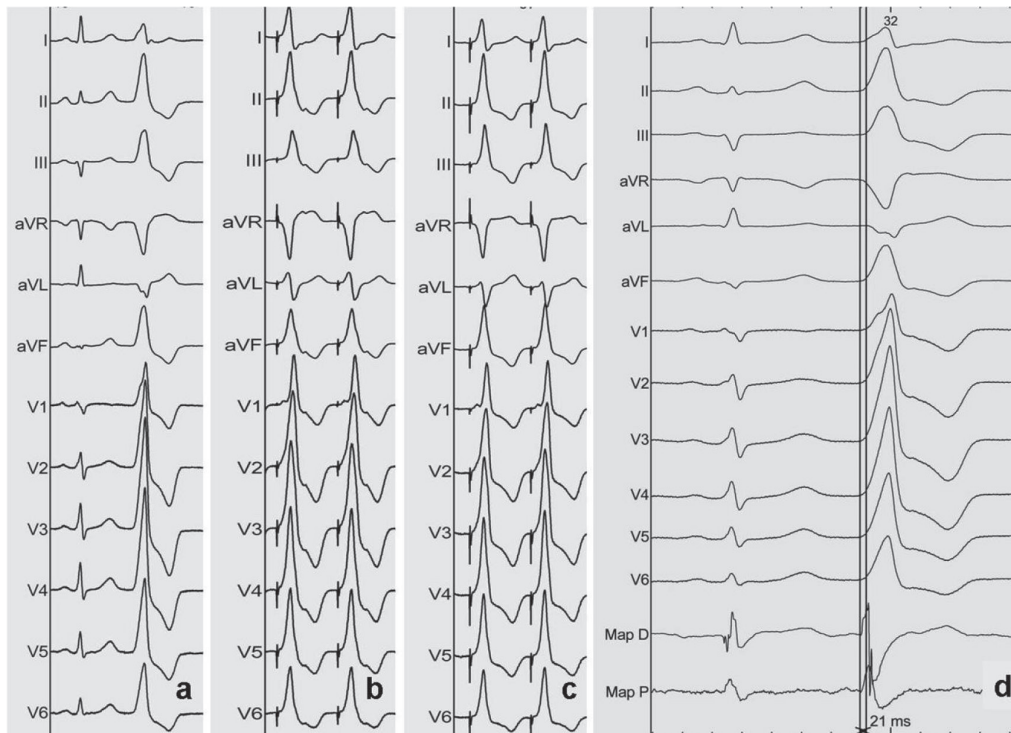


FIGURE 1. a. Baseline ECG showing the morphology of the VPBs; **b** and **c.** Pace-mapping from the left ventricular outflow tract beneath the left coronary cusp (LCC) (**b**) and within the LCC (**c**); **d.** The earliest local ventricular activation time (preceded the onset of the QRS complex by 21 msec) was identified within the LCC.

M- or W-pattern in lead V1 with a precordial transition (R>S) no later than V2.³ Apart from the early precordial transition, the surface ECG exhibits broad R waves in leads V1 or V2, tall R waves in inferior leads, an S wave in lead I, and absence of S waves in V5 and V6.⁴ Ouyang et al. have shown that an R-wave duration of >50% of the total QRS duration or an R/S ratio of more than 30% in leads V1 or V2 were strongly predictive of an aortic cusp origin, particularly of LCC.⁵

REFERENCES

1. Letsas KP, Charalampous C, Weber R, et al. Methods and indications for ablation of ventricular tachycardia. *Hellenic J Cardiol* 2011;52:427-436.
2. Yamada T, McElderry HT, Doppalapudi H, et al. Idiopathic ventricular arrhythmias originating from the aortic root prevalence, electrocardiographic and electrophysiologic characteristics, and results of radiofrequency catheter ablation. *J Am Coll Cardiol* 2008;52:139-147.
3. Lin D, Ilkhanoff L, Gerstenfeld E, et al. Twelve-lead electrocardiographic characteristics of the aortic cusp region guided by intracardiac echocardiography and electroanatomic mapping. *Heart Rhythm* 2008;6:663-669.
4. Hachiya H, Aonuma K, Yamauchi Y, Igawa M, Nogami A, Ie-saka Y. How to diagnose, locate, and ablate coronary cusp ventricular tachycardia. *J Cardiovasc Electrophysiol* 2002;13:551-556.
5. Ouyang F, Fotuhi P, Ho SY, et al. Repetitive monomorphic ventricular tachycardia originating from the aortic sinus cusp: Electrocardiographic characterization for guiding catheter ablation. *J Am Coll Cardiol* 2002;39:500-508.