

IMAGES IN MEDICINE

Transesophageal Overdrive Pacing: A Simple and Versatile Tool

Antonis S. Manolis, MD, Ioannis Dragazis, MD, Ioannis Kapelakis, MD,
Prokopis Papadimitriou, MD, Nikolaos Sakellaris, MD

ABSTRACT

In the present case, a patient with atrial flutter failed drug conversion with use of intravenous amiodarone and before resorting to electrical cardioversion, transesophageal atrial overdrive pacing was proposed and performed as a bedside procedure with successful conversion of atrial flutter into sinus rhythm.

*First Department of Cardiology,
Evangelismos Hospital, Athens, Greece*

KEY WORDS: *transesophageal pacing;
overdrive pacing; atrial flutter;
supraventricular tachycardia; electrical
cardioversion*

Abbreviation

ECG = ELECTROCARDIOGRAM

Correspondence to:

Antonis Manolis, MD, Evangelismos
Hospital, Athens, Greece; e-mail:
asm@otenet.gr

Manuscript received June 10, 2013;

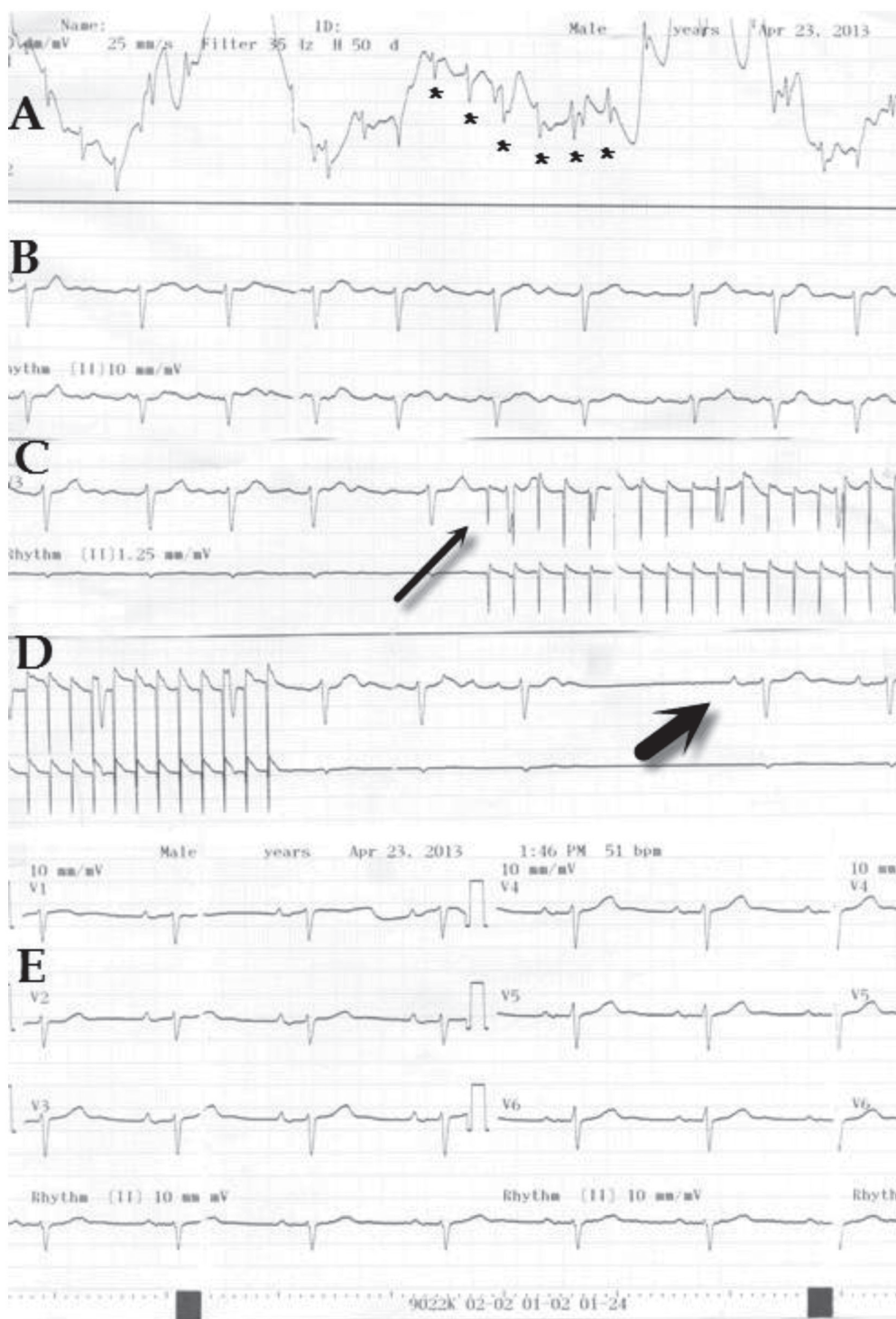
*Revised manuscript accepted June 25,
2013*

A temporary pacing electrode catheter inserted via the nares into the esophagus can be used to both record and pace the left atrium. It can thus be used both diagnostically and therapeutically for a variety of cardiac arrhythmias, obviating the need for invasive endocardial pacing in many circumstances. In the present case, a patient with atrial flutter failed drug conversion with use of intravenous amiodarone and before resorting to electrical cardioversion, transesophageal atrial overdrive pacing was proposed and performed as a bedside procedure with the patient's consent. A 6-French quadripolar electrode catheter was easily and swiftly inserted via the nares into the esophagus coordinated with the patient's deglutition with use of a sip of water. Then, the distal pole of the catheter was connected with use of an alligator clamp with the precordial V₁ lead to record the left atrial activity, ensuring a good position of the catheter (Figure, panel A, asterisks). Surface ECG recording of the atrial flutter is shown in panel B. Subsequently, the distal and the most proximal (fourth) poles of the catheter were connected with an external cardiac stimulator for pacing. Overdrive atrial pacing was effected at a pulse width of 9 ms and a pacing output of 12 mA at a rate progressively faster than the atrial rate of the atrial flutter (panel C, thin arrow). Each attempt of overdrive atrial pacing lasted for 15-30 seconds. When the pacing rate was increased to 300 bpm and upon interruption of the burst, successful conversion of atrial flutter into sinus rhythm was observed (panel D, thick arrow). Sinus rhythm was sustained (panel E) and the patient was further observed for 24 hours before being discharged home with instructions for medical therapy including antiarrhythmic drugs for rhythm and rate control plus anticoagulation therapy. An option for future radiofrequency ablation of the isthmus was also offered.

•••

Transesophageal cardiac recording and pacing can be used for both diagnosis and treatment of both bradyarrhythmias and tachyarrhythmias as a simple, effective and

Conflict of Interest: none declared



versatile tool.¹ Recording of left atrial activity via the esophagus can aid in the differential diagnosis of any tachyarrhythmia by demonstrating the relationship of the atrial electrograms being recorded simultaneously with a regular surface ECG recording. Subsequently for regular supraventricular tachycardias,

overdrive atrial pacing can be applied which can effectively terminate the arrhythmia, as illustrated in the present case with successful termination of atrial flutter. There is also the possibility with some extra effort and technique to even succeed in pacing the ventricle and apply either antibradycardia

pacing for bradyarrhythmias or overdrive ventricular pacing for ventricular tachycardia termination.^{2,3} One could even perform a mini electrophysiology study and evaluate usually children or young patients, e.g. with a preexcitation syndrome, and spare them the inconvenience of an invasive electrophysiology study.⁴

With regards to converting atrial flutter as in the case presented herein, this can be done either by electrical cardioversion, or overdrive atrial pacing effected either via a transvenous temporary pacing wire or with use of transesophageal atrial pacing.⁵ However, elective electrical cardioversion requires deep sedation and monitoring in a cardiac care unit, while the electrical shock delivered to the heart may sacrifice a few myocardial fibers. Transvenous cardiac pacing is an invasive procedure requiring central vein access (with its attendant possible complications of pneumothorax or hemothorax), demanding technical expertise and commonly access to fluoroscopy. Transesophageal pacing is a semi-invasive procedure, easily performed at the bedside with use of a monitor or a regular ECG machine. Although specially designed electrode catheters can be used for transesophageal pacing, a common bipolar or preferably a quadripolar catheter can be employed with use of the distal and most proximal poles for more appropriate distance needed (15-30 mm vs 5-10 mm for intracardiac pacing) to effect bipolar pacing via the esophagus. Insertion can be swiftly done via the nares by coordinating patient's swallowing with simultaneous gentle advancement of the catheter (others have used a pill electrode which can be simply swallowed by the patient⁶). Proper placement of the catheter can be easily guided with local unipolar recordings from the distal tip of the catheter by connecting it to the V₁ ECG lead. When large left atrial electrograms are recorded (see panel A), this site is usually the right spot to start bipolar pacing. Compared to intracardiac pacing, pacing from the esophagus requires

different, i.e. much higher, pacing current (10-20 mA vs 1-5 mA) and pulse width (5-15 ms vs 2 ms), which can be provided by either an external temporary pacing pulse generator or a programmed cardiac stimulator similar to or same as the one used for electrophysiology studies. Patient's discomfort from the whole procedure is usually minimal and relates to the initial placement of the catheter and some burning sensation during esophageal pacing depending on the current output needed to capture the left atrium. Finally, the procedure is simple and inexpensive, can be performed at the bedside, does not require sedation or anesthesia, and there is no need for fluoroscopy, special catheterization or electrophysiology laboratory or monitoring in a cardiac care unit.

REFERENCES

1. Santini M, Ansalone G, Cacciatori G, Turitto G. Transesophageal pacing. *Pacing Clin Electrophysiol* 1990; 13:1298-1323.
2. McEneaney DJ, Cochrane DJ, Anderson JA, Adgey AAJ. A gastroesophageal electrode for atrial and ventricular pacing. *Pacing Clin Electrophysiol* 1997;20:28-33.
3. Cochrane DJ, McEneaney DJ, Dempsey GJ, Anderson JM, Adgey AAJ. An esophageal and gastric approach to ventricular pacing. *Pacing Clin Electrophysiol* 1995;18(Pt. 1): 1815-1825.
4. Benson DW, Dunnigan A, Sterba R, et al.: Atrial pacing from the esophagus in the diagnosis and management of tachycardia and palpitations. *J Pediatr* 1983;102:40-46.
5. Kantharia BK, Mookherjee S. Clinical utility and the predictors of outcome of overdrive transesophageal atrial pacing in the treatment of atrial flutter. *Am J Cardiol* 1995; 76:144-147.
6. Tucker KJ, Wilson C. A comparison of transoesophageal atrial pacing and direct current cardioversion for the termination of atrial flutter: a prospective randomized clinical trial. *Br Heart J* 1993; 69:530-533.