

IMAGES IN MEDICINE

Transcatheter Aortic Valve Implantation in Severe Left Ventricular Dysfunction: A Viable Option in a Patient With Low-Flow, Low-Gradient Critical Aortic Stenosis

Antonis S. Manolis, MD, Antonios Polydorou, MD, Effie Rouska, MD, Spyros Bethanis, MD, Theofanis Minos, MD, Panagiotis Dedeilias, MD, John Kokotsakis, MD

Departments of Cardiology, Catheterization Laboratory, and Cardiothoracic Surgery, Evagelismos General Hospital of Athens, Athens, Greece

KEY WORDS: aortic stenosis; aortic valve replacement; transcatheter aortic valve implantation; left ventricular dysfunction; low-flow, low-gradient aortic stenosis

ABSTRACT

Images are provided from a successful procedure of transcatheter aortic valve implantation (TAVI) in an elderly patient with symptomatic low-flow, low-gradient critical aortic stenosis, and associated severe left ventricular dysfunction, who had a very high risk for surgery.

An 83-year old lady with symptomatic low-flow, low-gradient critical aortic stenosis, severe left ventricular dysfunction and high-risk for surgery was successfully submitted to transcatheter aortic valve implantation (TAVI). About 2 years earlier the patient had sustained an acute myocardial infarction which was managed with primary percutaneous coronary intervention and stenting. However, she was left with severely compromised left ventricular function (ejection fraction 35%). She continued having symptoms of angina and shortness of breath, mostly attributed to known underlying critical aortic stenosis (aortic valve area 0.6 cm²; mean aortic gradient 34 mmHg). Due to worsening symptomatology over the preceding 6 months, the patient was evaluated for aortic valve replacement. She was though deemed a high-risk surgical candidate due to her age and underlying comorbidities (diabetes, hypertension, chronic pulmonary disease and poor left ventricular function). The logistic Euroscore was calculated at 32.51%. Thus, the patient was scheduled for TAVI, per the “Heart Team” recommendation, despite her severely compromised systolic ventricular function.

Balloon valvuloplasty was initially performed as seen in panel A. A first attempt to place a number 26 CoreValve (Medtronic Inc., Minneapolis, MN, USA) via the right femoral artery with use of an 18F delivery system (panel B, arrow) was unsuccessful due to downward displacement of the valve during the release process (panel C, arrow). The valve was recaptured and a second attempt was finally successful in implanting the valve at the correct position (panel D, arrow). Aortography demonstrated no

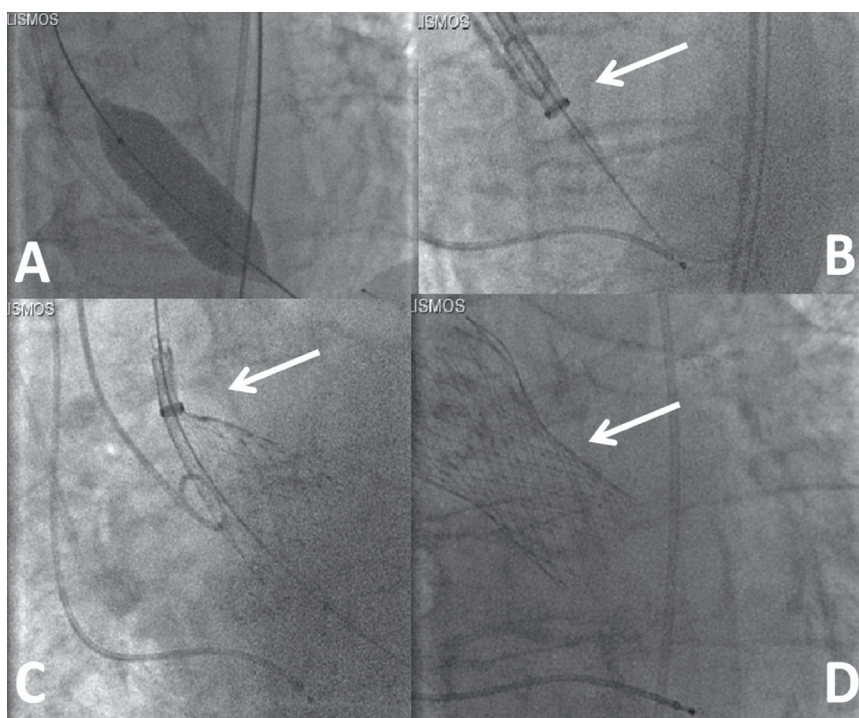
ABBREVIATION

TAVI = transcatheter aortic valve implantation

Correspondence to:

Antonis Manolis, MD; First Department of Cardiology, Evagelismos Hospital, Athens, Greece; e-mail: asm@otenet.gr
Manuscript received and accepted March 30, 2013

Conflict of Interest: none declared



paravalvular regurgitation and the procedure was successfully completed with surgical closure of the femoral artery insertion site. Due to development and persistence of complete heart block after the procedure, in the setting of a pre-existing left bundle branch block, a permanent pacemaker was implanted 5 days later. The patient's course was complicated by worsening anemia in the setting of a pre-existing low hematocrit due to thalassemia trait treated with transfusion and also recurrent bouts of cellulitis in both arms treated with antibiotics, but she was finally discharged home in stable medical condition about 2 weeks later.

•••

The availability of transcatheter aortic valve implantation (TAVI) represents a long-awaited and most important development in the management of valvular heart disease for patients deemed to have a prohibitive or high surgical risk.¹ Thus, an alternative to traditional surgical aortic valve replacement can now be offered to these patients.

However, very few studies have focused on outcomes of TAVI in patients with severe left ventricular dysfunction.²⁻⁵ Conservative treatment of severe aortic stenosis associated with severely reduced left ventricular function carries a dismal prognosis. Thus, after the widespread use of and experience obtained from the TAVI procedure in patients with adequate left ventricular performance, the procedure has also been proposed and offered selectively to patients with severely compromised left ventricular function. Indeed, from the few

data available, it appears that TAVI should not be withheld in selected patients with impaired left ventricular function.²⁻⁵

In the limited number of patient series available in the literature, a favorable periprocedural outcome, similar to our patient, has been reported, which was accompanied by a post-procedural recovery in left ventricular function translated into favorable long-term survival comparable to patients with normal or moderately reduced left ventricular function.^{2,3} Thus, it has been suggested that severely compromised left ventricular function should not deter providers from offering TAVI to these patients with severe aortic stenosis who are at high risk for surgery.

Some investigators have suggested that the improvement in ejection fraction obtained after TAVI seems even better than that observed after surgical aortic valve replacement.⁴ This may be possibly attributed to a superior hemodynamic performance of the transcatheter prosthesis affording a bigger effective orifice area and lower transvalvular gradient, or even better protection and improved recovery of myocardial function, by avoiding or minimizing ischemic and/or reperfusion injury and inflammation conferred by cardioplegia and the surgical injury.

Of course, due to the severely compromised ventricular function, this subgroup of TAVI patients are expected to have a higher complication rate and higher 30-day (e.g. 10% vs 3%)⁴ or 1-year mortality rates (31% vs 13%),⁴ associated with a greater logistic Euroscore in these patients, an increased incidence of periprosthetic leaks (>2+/4), and higher rates of

congestive heart failure after TAVI.^{4,5} An additional significant predictor of mortality in this very high-risk subgroup of patients relates to the *low-flow low-gradient aortic stenosis*,⁵ as indeed was the case in our patient, whereby the mean aortic gradient was calculated at 34 mmHg, instead of a classical >40 mmHg gradient measured in critical aortic stenosis. Nevertheless, in view of the grave prognosis incurred by medical therapy in patients with critical aortic stenosis and severe left ventricular dysfunction, TAVI appears to be a feasible and effective procedure, and a viable option, even in this group of patients, as it leads to satisfactory procedural success rates and clinical improvement with even partial recovery of their left ventricular function.²⁻⁵ Although these results are encouraging, data from randomized trials are needed to determine whether this therapeutic strategy will also improve long-term survival rates in this subgroup of aortic stenosis patients.

ACKNOWLEDGEMENT

The authors acknowledge the pivotal role of Dr. Ariel Finkelstein, and critical assistance of the Nursing and Medical staff of the Catheterization Laboratory and the Cardiology Ward and the staff of the Anesthesiology Department involved in

carrying out the TAVI procedure and delivering high-quality care to the patient.

REFERENCES

1. Holmes DR, Mack MJ, Kaul S, et al. 2012 ACCF/AATS/SCAI/STS Expert consensus document on transcatheter aortic valve replacement. *J Am Coll Cardiol* 2012;59:1200–1254.
2. Pilgrim T, Wenaweser P, Meuli F, et al. Clinical outcome of high-risk patients with severe aortic stenosis and reduced left ventricular ejection fraction undergoing medical treatment or TAVI. *PLoS One* 2011;6(11):e27556.
3. van der Boon RM, Nuis RJ, Van Mieghem NM, et al. Clinical outcome following transcatheter aortic valve implantation in patients with impaired left ventricular systolic function. *Catheter Cardiovasc Interv* 2012;79:702-710.
4. Fraccaro C, Al-Lamee R, Tarantini G, et al. Transcatheter aortic valve implantation in patients with severe left ventricular dysfunction: immediate and mid-term results, a multicenter study. *Circ Cardiovasc Interv* 2012;5:253-260.
5. Lauten A, Zahn R, Horack M, et al; German Transcatheter Aortic Valve Interventions Registry Investigators. Transcatheter aortic valve implantation in patients with low-flow, low-gradient aortic stenosis. *JACC Cardiovasc Interv* 2012;5:552-559.