

HOSPITAL CHRONICLES 2013, 8(1): 20–21

IMAGES IN MEDICINE

Coronary “Collateralization” or “De-Collateralization” by Percutaneous Coronary Intervention in the Collateral Flow Supplying or Receiving Vessel

Isidoros P. Gavaliatsis, MD, FESC

ABSTRACT

Director, Department of Interventional Cardiology, Evagelismos Hospital, Athens, Greece

KEY WORDS: percutaneous coronary intervention; coronary artery disease; coronary collaterals; myocardial infarction; coronary angiography

ABBREVIATIONS

CTO = chronic total occlusion

LAD = left anterior descending (coronary artery)

PCI = percutaneous coronary intervention

RCA = right coronary artery

Images of coronary angiography are being presented of two patients undergoing percutaneous coronary intervention (PCI). In the first patient with chronic total vessel occlusion, who also had a significant stenosis of the contralateral artery, there were no visible collaterals, which became fully functional and visible right after the successful PCI of the contralateral lesion (*collateralization by PCI*). In the second patient with acute myocardial infarction undergoing primary PCI of a total vessel occlusion, there was good collateral supply (provided by the contralateral vessel), which vanished upon restoration of antegrade flow to the totally occluded artery (*de-collateralization by PCI*).

The upper panel images concern a 73-year-old gentleman with an old anterior myocardial infarction, undergoing percutaneous coronary intervention (PCI) of a critical lesion in the mid-segment of the right coronary artery (RCA), as depicted in panel A (pre PCI). Note the absence of coronary collaterals to the totally occluded left anterior descending (LAD) coronary artery. Full collaterals emerge right after the successful dilation of the collateral flow supplying vessel (RCA), as illustrated in panel A (post PCI). The lower panels are images from a 71-year-old patient undergoing PCI at 24 hours after an anterior myocardial infarction. Panel B (pre PCI) shows collaterals to the totally occluded LAD. However, these collaterals disappear right after the successful PCI in the collateral flow receiving vessel (LAD), as shown in panel B (post PCI).

●●●

There is usually broad variation in collateral flow capabilities among patients with coronary artery disease.^{1,2} During PCI balloon occlusion, studies, using different methods to assess collateral flow, have shown that retrograde collateral flow velocity usually appears within seconds following the onset of balloon inflation, and the relative magnitude of flow velocity contributed by retrograde collateral flow to the recipient artery ranges between 20-30% of corresponding antegrade distal flow velocity after PCI. However, in two distinct groups of patients, in those with chronic total occlusion (CTO) encountered during coronary angiography and in patients undergoing primary PCI in acute myocardial infarction, collaterals are assessed with the occlusion model in

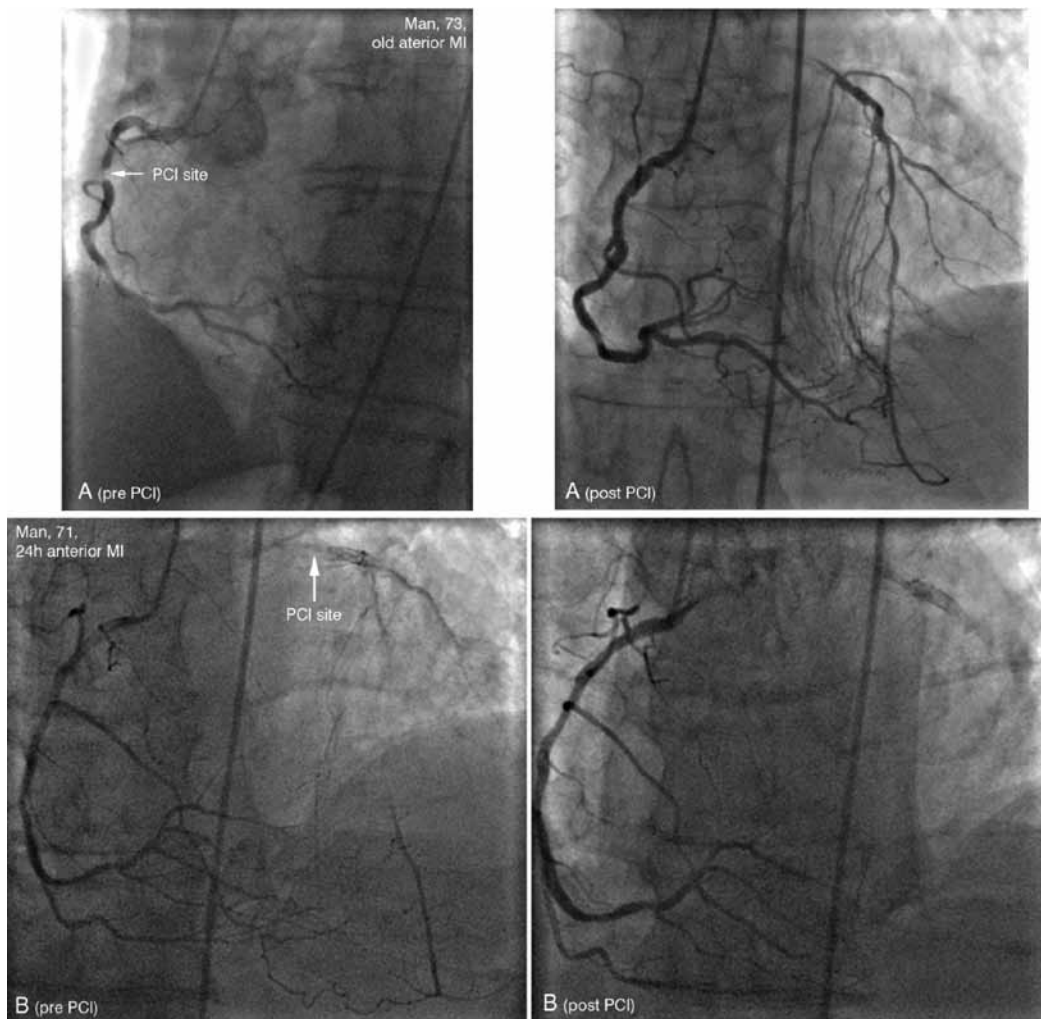
Correspondence to:

Isidoros Gavaliatsis, MD,

Cath Lab, Evagelismos Hospital,
Athens, Greece;E-mail: ipgavaliatsis@pathfinder.gr*Manuscript received December 2, 2012;**Revised manuscript accepted December 31, 2012*

Conflict of Interest: none declared

CORONARY “COLLATERALIZATION” OR “DE-COLLATERALIZATION” BY PCI



the majority of coronary angiographies, visualized and classified into 4 categories according to a scale proposed by Rentrop et al.^{4,5} This is based on collateral recipient artery filling by the contrast agent; grade 0 = no collaterals; grade 1 = small collateral vessels coming off the recipient artery without filling of the main epicardial artery; grade 2 = partial collateral filling of the main epicardial recipient artery; and grade 3 = complete collateral filling of the main epicardial recipient artery up to the level of occlusion. Thus, in the first patient with chronic total LAD occlusion, who also had a critical lesion of the RCA, on initial angiographic assessment there were no visible collaterals, which became fully functional (grade 3 by the Rentrop scoring system) right after the successful PCI of the RCA lesion (*collateralization by PCI*) (upper panels). In the second patient with the acute myocardial infarction undergoing primary PCI of a total LAD occlusion, there was good (grade 2) collateral supply (provided by the RCA), which vanished upon restoration of antegrade flow to the LAD (*de-collateralization by PCI*) (lower panels).

REFERENCES

1. Bach RG, Donohue TJ, Caracciolo EA, Wolford T, Aguirre FV, Kern MJ. Quantification of collateral blood flow during PTCA by intravascular Doppler. *Eur Heart J* 1995; 16 (Suppl J): 74-77.
2. Traupe T, Gloekler S, de Marchi SF, Werner GS, Seiler C. Assessment of the human coronary collateral circulation. *Circulation* 2010;122:1210-1220.
3. Rentrop KP, Cohen M, Blanke H, Phillips RA. Changes in collateral channel filling immediately after controlled coronary artery occlusion by an angioplasty balloon in human subjects. *J Am Coll Cardiol* 1985; 5: 587-592.
4. Rentrop KP, Thornton JC, Feit F, Van Buskirk M. Determinants and protective potential of coronary arterial collaterals as assessed by an angioplasty model. *Am J Cardiol* 1988; 61:677-684.