

REVIEW

Acute Aortic Syndromes: Surgical, Endovascular or Medical Treatment

John Kokotsakis, MD, Dimitris Tassopoulos, MD,
Vania Anagnostakou, MD

ABSTRACT

The term acute aortic syndrome (AAS) refers to a heterogeneous group of conditions that cause a common set of signs and symptoms, the foremost of which is aortic pain. Various pathological entities may give rise to this syndrome, but the topic has come to focus on penetrating aortic ulcer and intramural hematoma and their relation to aortic dissection. Penetrating aortic ulcer is a focal atherosclerotic plaque that corrodes a variable depth through the intima into the media. Intramural hematoma is a blood collection within the aortic wall not freely communicating with the aortic lumen, with restricted flow. It may represent a subcategory of aortic dissection that manifests different behavior by virtue of limited flow in the false lumen. The initial management of all patients with AAS involves pain relief and aggressive blood pressure control. Subsequent surgical, endovascular or medical treatment depends on the type of AAS and associated procedural risk. An overview of AAS conditions, their pathophysiology and management is herein attempted.

*Second Cardiac Surgery Department,
Evangelismos General Hospital, Athens,
Greece*

KEY WORDS: *acute aortic syndrome;
aortic dissection; intramural aortic
hematoma; penetrating aortic ulcer*

ABBREVIATIONS

AAS = acute aortic syndrome

CTA = computerized tomography
angiography

ECG = electrocardiogram

IMH = intramural hematoma

IRAD= International Registry of Acute
Aortic Dissection

MRI = magnetic resonance imaging

PAU = penetrating aortic ulcer

Correspondence to:

John Kokotsakis, MD, Second
Department of Cardiac Surgery,
Evangelismos Hospital, Athens,
Greece;

e-mail: ikok78@otenet.gr

Manuscript received May 15, 2012;

*Revised manuscript received and
accepted January 7, 2012*

INTRODUCTION

The term acute aortic syndrome (AAS), coined by Vilacosta and associates in 1998,¹ refers to a heterogeneous group of conditions that cause a common set of signs and symptoms, the foremost of which is aortic pain. The pain is acute, severely intense often maximally so at its outset and may be described as tearing, ripping, migrating, or pulsating. Pain located in the anterior chest and neck is related to involvement of the ascending aorta and may be easily confounded with that of acute ischemic syndromes. Back and abdominal pain may indicate that there is involvement of the descending aorta. Syncope may be the presenting symptom in up to 20% of cases and is associated with a proximal dissection. The onset of syncope or central neurological deficits indicates probable complications such as obstruction of cerebral vessels, cardiac tamponade, or activation of cerebral baroreceptors.¹ Hirst, Johns, and Kime⁴ state: “The patient will frequently volunteer the information that it feels as if ‘something has broken loose’ in the chest”. Marfan’s syndrome, Ehlers-Danlos syndrome, familial forms of aortic aneurysm and dissection, as well as bicuspid aortic valve are genetic conditions that predispose patients to develop an acute aortic syndrome and correlate with earlier presentations.

Conflict of Interest / Author Statement: The authors have no conflicts of interest to disclose and received no financial support for the purposes of this article. The manuscript is original and has never been published before.

Patients with thoracic aortic disease have been shown to have increased levels of a group of proteins (metalloproteins) whose primary function is to degrade extracellular matrix.³

DEFINITION AND EPIDEMIOLOGY

Acute aortic syndrome includes five classes of aortic disease.

- Class I – Classic aortic dissection
- Class II – Intramural hematoma
- Class III – Localized dissection, intimal tear without extensive intimal flap formation, localized in the aortic wall
- Class IV – Penetrating aortic ulcers
- Class V – Iatrogenic or post traumatic dissection

While being distinct pathological processes, there is the possibility of progression from one entity to another. A diagnostic evaluation algorithm for patients with acute aortic syndrome is outlined in **Figure 1**. This stepwise approach includes several tests. The electrocardiogram (ECG) is an important first diagnostic test performed for all patients presenting with acute chest pain, whether typical or atypical for an acute aortic syndrome, as this can promptly provide initial information about the presence of acute ischemia. Imaging studies are most important and include chest radiography, computerized tomography angiography (CTA), magnetic resonance imaging (MRI), echocardiography (transthoracic and/or transesophageal) and finally invasive aortography.

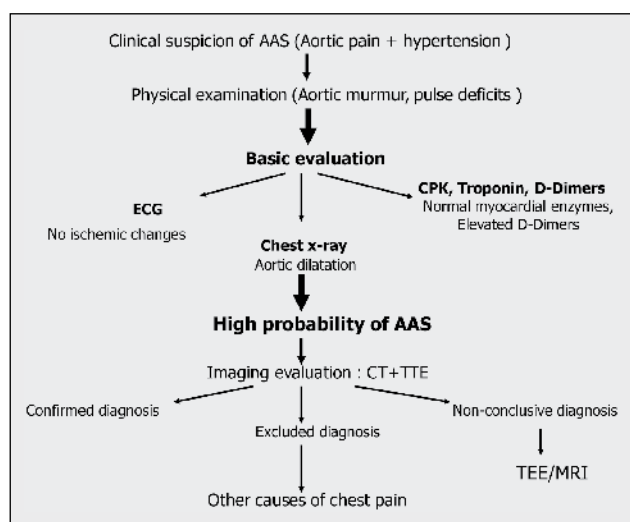


FIGURE 1. Diagnostic algorithm of patients with acute aortic syndrome (AAS). CPK = creatine phosphokinase; CT = computed tomography; ECG = electrocardiogram; MRI = magnetic resonance imaging; TEE = transesophageal echocardiography; TTE = transthoracic echocardiography.

MANAGEMENT

The initial management of all patients with AAS involves pain relief and aggressive blood pressure control. In normalizing the blood pressure, the goal is to reduce the force of left ventricular ejection (dP/dt), which is the primary cause of dissection extension and aortic rupture. Beta-blockers are the preferred agents because they not only reduce systemic pressure but also lower heart rate, commonly combined with vasodilators. For most patients, the goal is a systolic pressure between 100 and 120 mmHg and heart rate <60 bpm or lowest tolerable levels that provide adequate cerebral, coronary, and renal perfusion.⁴

AORTIC DISSECTION

Classic aortic dissection (class I) is the most common cause of acute aortic syndromes (70%) (**Fig. 2-6**). Aortic dissection is the most common aortic catastrophe occurring two to three times more frequently than abdominal aortic rupture. The exact incidence is unknown but studies quote it to be 2.6-3.5 per 100,000 person years. Information gathered from the International Registry of Acute Aortic Dissection (IRAD) show that two thirds of patients are male with a mean age of 63 years. Women are affected less often and present at a mean age of 67 years. Patients with dissection involving the ascending aorta tend to present at a younger age (50-55 years) than those with dissection of the descending aorta (60-70 years) (**Fig. 2-4**). Risk factors for the development of aortic dissection include the following. Hypertension is the most common predisposing factor (72%). This is followed by a history of atherosclerosis (31%), cardiac surgery (18%), and Marfan's syndrome (5%).

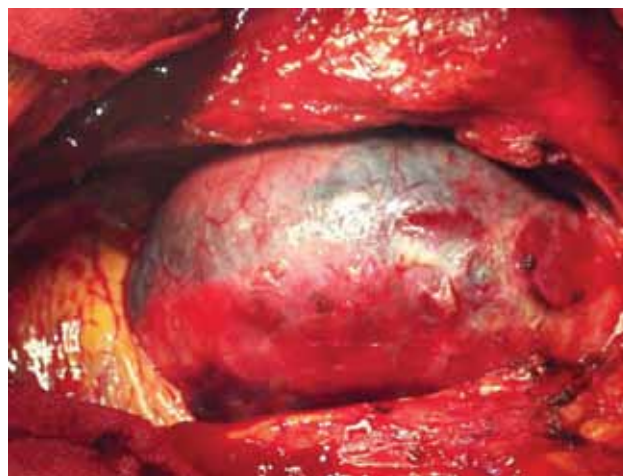


FIGURE 2. Acute type A dissection of the aorta.

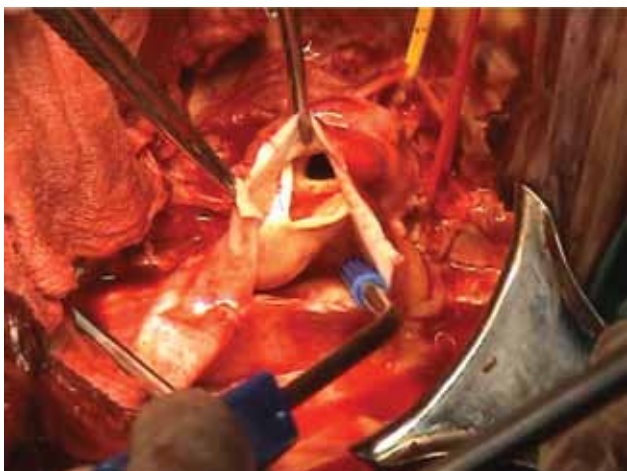

FIGURE 3. Acute type B dissection of the descending aorta.

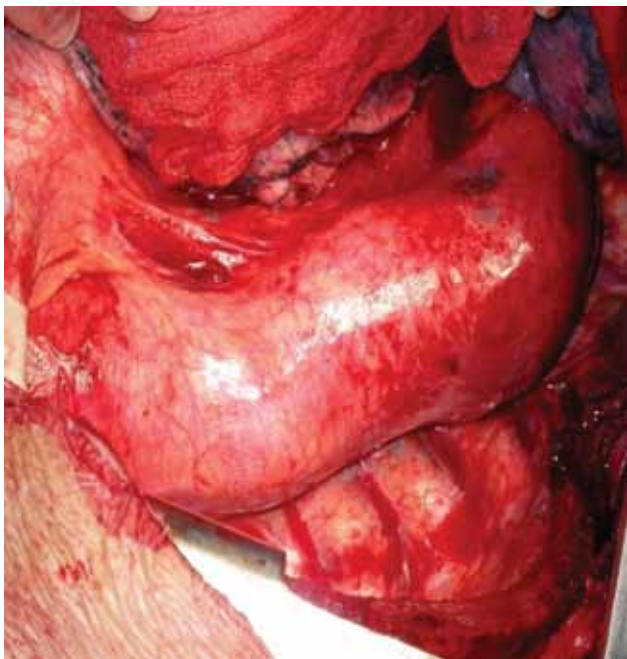

FIGURE 4. Surgical picture of acute type B dissection.

Younger patients (<40 years of age) who present with aortic dissection most often have associated Marfan's syndrome, a bicuspid aortic valve or a history of aortic surgery.⁵

Classic aortic dissections are characterized by an intimal tear with separation of the aortic media into two layers, the inner two thirds and outer one third. The vast majority of dissections originate from intimal tears in the ascending aorta within several centimeters of the sinuses of Valsalva where torsional movement of the aortic annulus provokes additional downward traction in the aortic root and increases longitudinal stress in

that segment of aorta (Fig. 2 & 5). The other common site for an intimal tear to originate is in the descending aorta just distal to the origin of the left subclavian artery at the site of the ligamentum arteriosum (Fig. 6). From this point, blood under pressure extends the dissection in an antegrade direction, although retrograde extension is also possible, thus forming a false lumen and double channel aorta. A further reentrance tear allows blood to circulate in the false lumen and communicate with the true lumen. Reentry tears are often located in the abdominal aorta. The true lumen is most often the smaller of the two and is surrounded by calcifications if present. Class III dissections are characterized by the presence of an intimal tear without a flap or hematoma formation.

Dissections resulting from cardiac surgical procedures may occur during the procedure, early in the postoperative period, or their presentation may be delayed for years. The incidence varies between 0.12% and 0.35% of cardiac surgeries, but the mortality is high unless recognized early. Injury to the aorta can occur at the site of cross clamp placement, cannulation and decannulation, aortotomy, cardioplegic cannulation, or aortocoronary anastomosis. Preexisting atherosclerotic or connective tissue disease, increased aortic diameter, previous heart surgery, a history of hypertension and elevated cardiopulmonary bypass pressures are all risk factors. Retrograde type A dissections after endograft placement for type B dissections have been reported with an incidence of 10-27%. Other procedures associated with an increased risk of aortic dissection include the insertion of intra-aortic balloon pumps, percutaneous coronary angioplasty, and stenting for coarctation of the aorta. A dissection has a mortality rate of 1-2% per hour during the first hours of symptom onset and without surgical treatment; the mortality rate is 20% by 24 hours, 30% by 48 hours, 40% at 1 week, and 50% at 1 month. Aortic arch and descending

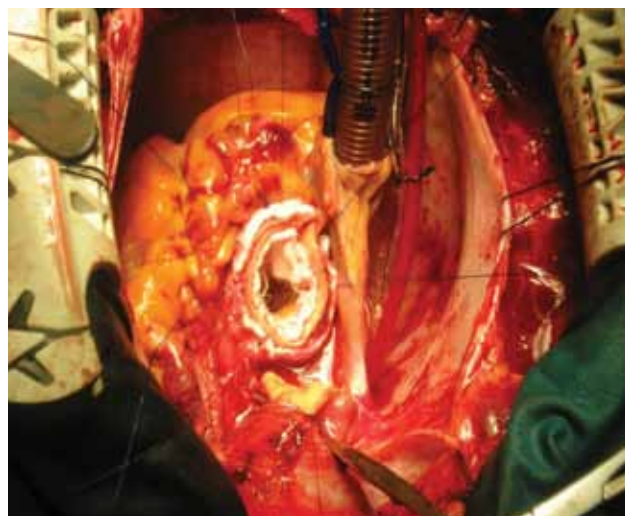


FIGURE 5. Surgical repair of acute type A dissection.

ACUTE AORTIC SYNDROMES

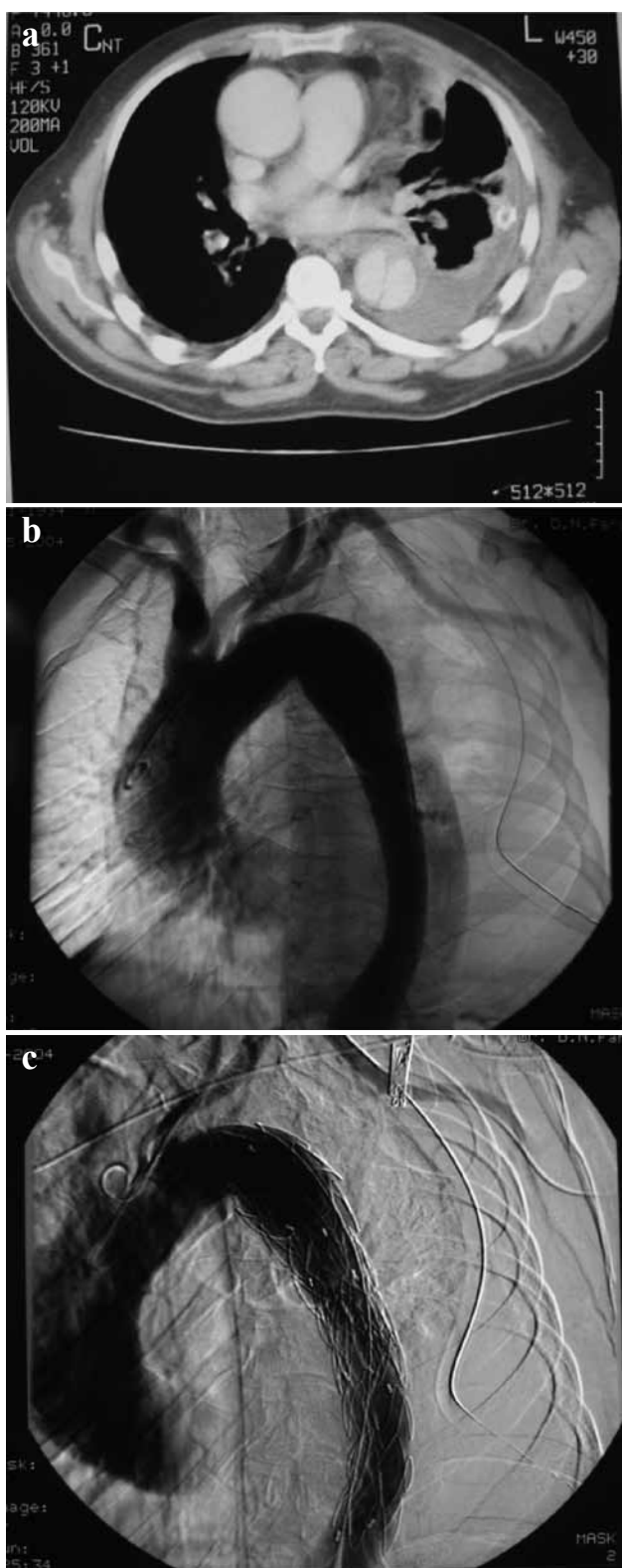


FIGURE 6. Acute type B dissection (a & b); endovascular (via stent - graft) repair (c).

thoracic intimal tears are seen in 20%-30% of patients with type A dissection and if left untreated predispose to later distal reoperation. If a dissection extends into the descending thoracic aorta, an elephant trunk extension of the arch graft is an option.

For uncomplicated type B dissection, medical management (analgesics and anti-hypertensive therapy) still remains the mainstay of therapy for patients with uncomplicated type B disease. It is safe to treat patients medically with close follow-up for ischemic complications, disease progression, or aneurysmal enlargement. Complicated type B aortic disease is differentiated by the presence of a distal malperfusion syndrome or rapid disease progression. Indications for intervention are similar to those for type A disease; the prevention of life-threatening complications such as organ or limb ischemia, aneurysm expansion and risk of rupture, periaortic blood collection, intractable pain, aneurysm expansion or uncontrolled hypertension. The mortality rate for open surgical repair (graft replacement, fenestration, or bypass procedures) is 30-35% and even higher with the presence of visceral malperfusion. Aortic endovascular grafting may be particularly beneficial in this group and has shown improved mortality rates (16%) (Fig. 6). An additional benefit of stent grafts is the ability to relieve dynamic and combined static and dynamic obstructions successfully in complicated acute type B dissections.

Type A aortic dissections are highly lethal. Overall, mortality at 1 month is 20% with and 50% without surgical treatment for type A dissections. The risk of death is higher if there are complications of pericardial tamponade, involvement of the coronary arteries causing acute myocardial ischemia, or a malperfusion syndrome. Age greater than 70 has been identified as an independent risk factor for hospital death for acute type A dissection. Shock, hypotension, and tamponade are other risk factors for increased mortality. For type B dissections, the overall mortality rate is 10% with medical treatment. Circulatory shock and visceral ischemia predispose to a higher mortality in type B dissection. In patients with surgically corrected type A dissections (Fig. 5), survival differences were based on the presence or absence of distal false lumen flow. The primary reasons for higher, long-term mortality in type B dissections were aneurysmal expansion and rupture. Dilatation occurs at a faster rate in patients with false lumen flow when compared to absent false lumen flow in type B dissections. All patients with a known aortic disease require close surveillance following discharge. Lifelong treatment of hypertension is required and regular assessments of the aorta should be performed at 1, 3, 6, 9, and 12 months as well as every 6-12 months thereafter, depending on the aortic size.

PENETRATING AORTIC ULCER

The incidence of penetrating aortic ulcer (PAU) in AAS

ranges from 2.3% to 11%. PAU, initially described by Shennan³ in 1934, is a focal atherosclerotic plaque that corrodes a variable depth through the internal elastic lamina into the media. It may form a pseudoaneurysm or may rupture into the media, forming an intramural hematoma (IMH) in the media or between the media and adventitia. The hematoma may propagate locally or, rarely, may give rise to classic aortic dissection. PAU tends to occur in older men with severe systemic atherosclerosis but without connective tissue diseases. The lesions which may be single or multiple (31.6% in the series reported by Botta⁶ and associates), are predominantly situated in the descending aorta, but less frequently occur in the arch or abdominal segments, and rarely in the ascending aorta. The reason why most atherosclerotic ulcers do not penetrate the internal elastic lamina

and few penetrate the media and adventitia is not clear. This may precipitate a localized, intramural hemorrhage following progressive erosion and rupture of the vasa vasorum.

IMAGING

Penetrating aortic ulcer has a characteristic appearance on angiography, reminiscent of duodenal ulcer (although this is now rarely performed for penetrating aortic ulcer), whereas non-invasive imaging modalities (contrast or non-contrast computed tomography) are used more frequently and provide important information on periaortic tissues (Fig. 7). Contrast enhanced magnetic resonance is useful for confirming enhance-

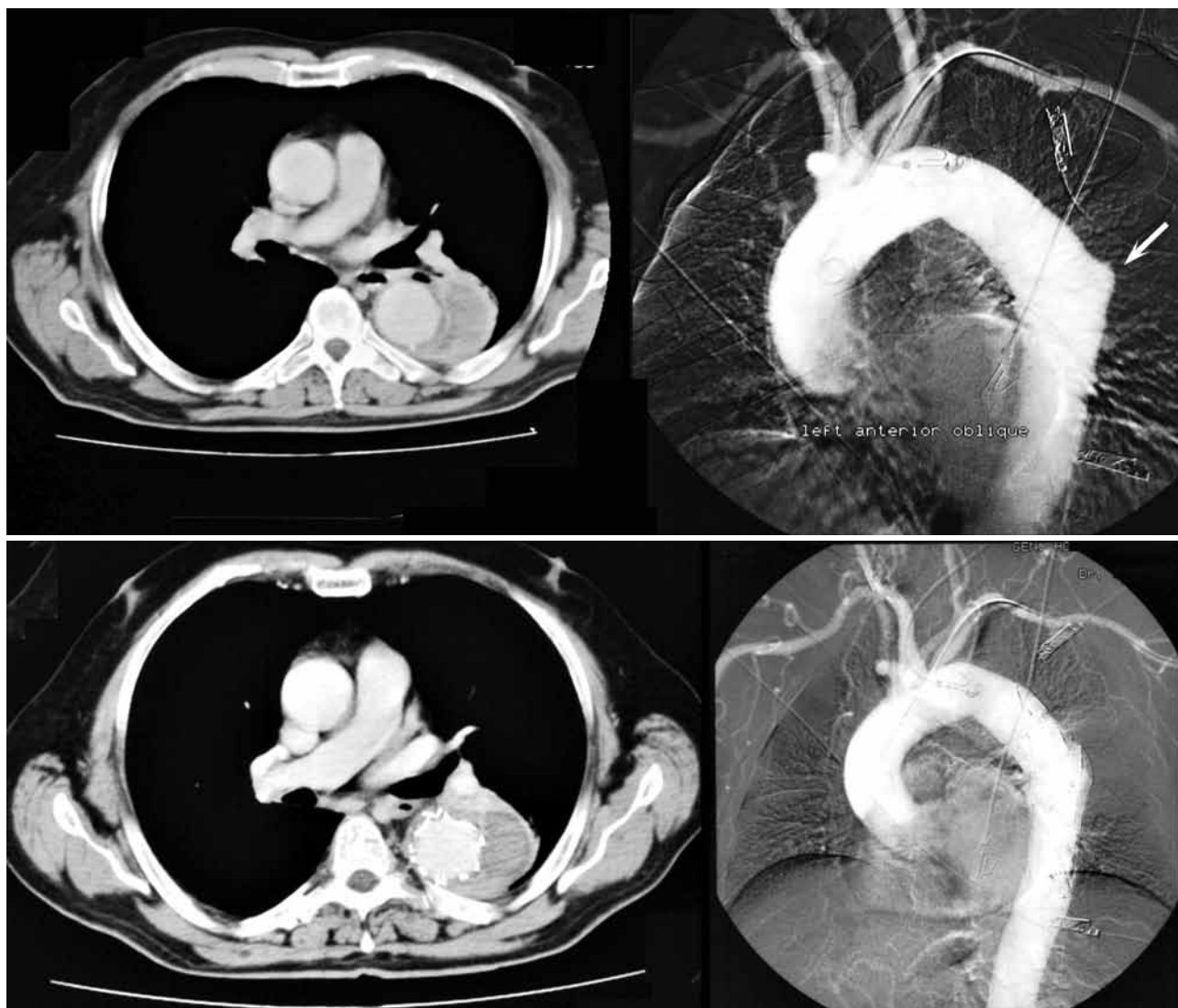


FIGURE 7. Penetrating aortic ulcer; computed tomography angiography (CTA) pre (upper panels, arrow) and post (lower panels) endovascular repair.

ment of the ulcerated tissue and adjacent aortic wall.

TREATMENT

Endovascular stent placement is an accepted form of treatment, although determining which patients to treat and when to treat them remains controversial. Patients with symptomatic penetrating aortic ulcers of the descending aorta who are poor surgical candidates (typically in their seventh decade in the majority of cases with a life expectancy of less than 10 years) are good candidates for urgent stent graft placement (Fig. 7). Criteria for endograft placement in the acute setting, advanced by Botta's group, include recurrent pain, aortic diameter greater than 55 mm, increase in size greater than 10 mm per year with recommended threshold values of 20 mm for PAU diameter and 10 mm for PAU depth.

INTRAMURAL HEMATOMA (IMH)

Intramural hematoma (IMH), first described by Krukenberg² in 1920, has been described as "dissection without intimal tear." Histologically, the hematoma generally extends within the media, but it may be subadventitial. On diagnostic imaging, IMH appears as a smooth, crescentic, or circular thickening greater than 5 to 7 mm. With expansion, the hematoma may encroach upon the aortic lumen and, if intimal calcium is present, displace it centrally. By definition, intramural hematoma lacks a detectable intimal tear or disruption, and has therefore no communication with the aortic lumen, but is confined within the aortic wall. Intramural hematoma accounts for approximately 6-10% of all acute aortic syndromes according to a European cohort but can account for 30-40% of acute aortic syndrome patients in some Asian populations. Symptoms of IMH may be very similar to those of classic dissection, and patients cannot be reliably distinguished by clinical presentation alone. Intramural hematoma comprises 10% to 30% of AAS. The patients tend to be older, and most are hypertensive. It is commonly held that aortic dissection arises from an intimal tear, whereas IMH arises from "rhexis" of the vasa vasorum, without an intimal tear. However, the issue has long been debated, and many hold that a single mechanism gives rise to both entities; some believe that IMH represents aortic dissection with a thrombosed false lumen, whereas others believe IMH represents intramedial hemorrhage, without rupture into

the true lumen. Intramural hematomas often occur in patients with severe atherosclerotic disease in which penetrating aortic ulcers or atherosclerotic plaques rupture causing intimal injury with blood entering the media. In patients with mild or no atherosclerosis, spontaneous rupture of the vasa vasorum may initiate aortic wall degeneration, which leads to hematoma formation in the aortic wall, splitting of the medial layer, and dissection formation without an intimal tear. Patients in the first group tend to be older and have coexisting coronary and peripheral vascular disease. Evolution of the IMH is difficult to predict. In some cases, the hematoma does not change in size. Resolution occurs in fewer than 10% of cases, but is more likely with less hematoma and aortic wall thickness. When an IMH resolves, a localized aneurysm may develop because if a weakened media and remodeling, requiring close surveillance. Progression of IMH may lead to weakening and disruption of the intimal layer causing a classic dissection. Progression to dissection has been shown to occur in 16-47% of patients with IMH.

IMAGING

The use of non-contrast computed tomography images is paramount in detection of an intramural hematoma; discrimination of an intramural hematoma from a dissection on a contrast enhanced computed tomography alone is more difficult because the attenuation of acute hemorrhage in the wall of the aorta is higher than that of intraluminal blood (Fig. 8). Magnetic resonance imaging is also useful for detecting intramural hematoma, as the signal characteristics of hemoglobin breakdown products help distinguish between acute and chronic blood. In addition, transesophageal echocardiography provides important information for diagnosing intramural hematoma.

TREATMENT

The management of IMH is not well established although it is similar to that for aortic dissection. Involvement of the ascending aorta demands urgent surgical repair because of the risk of rupture or progression to frank dissection into other parts of the thoracic aorta. IMH confined to the aortic arch or the descending thoracic aorta (type B intramural hematoma) may primarily be safely treated non-surgically or endovascularly with close imaging follow up (Fig. 8).

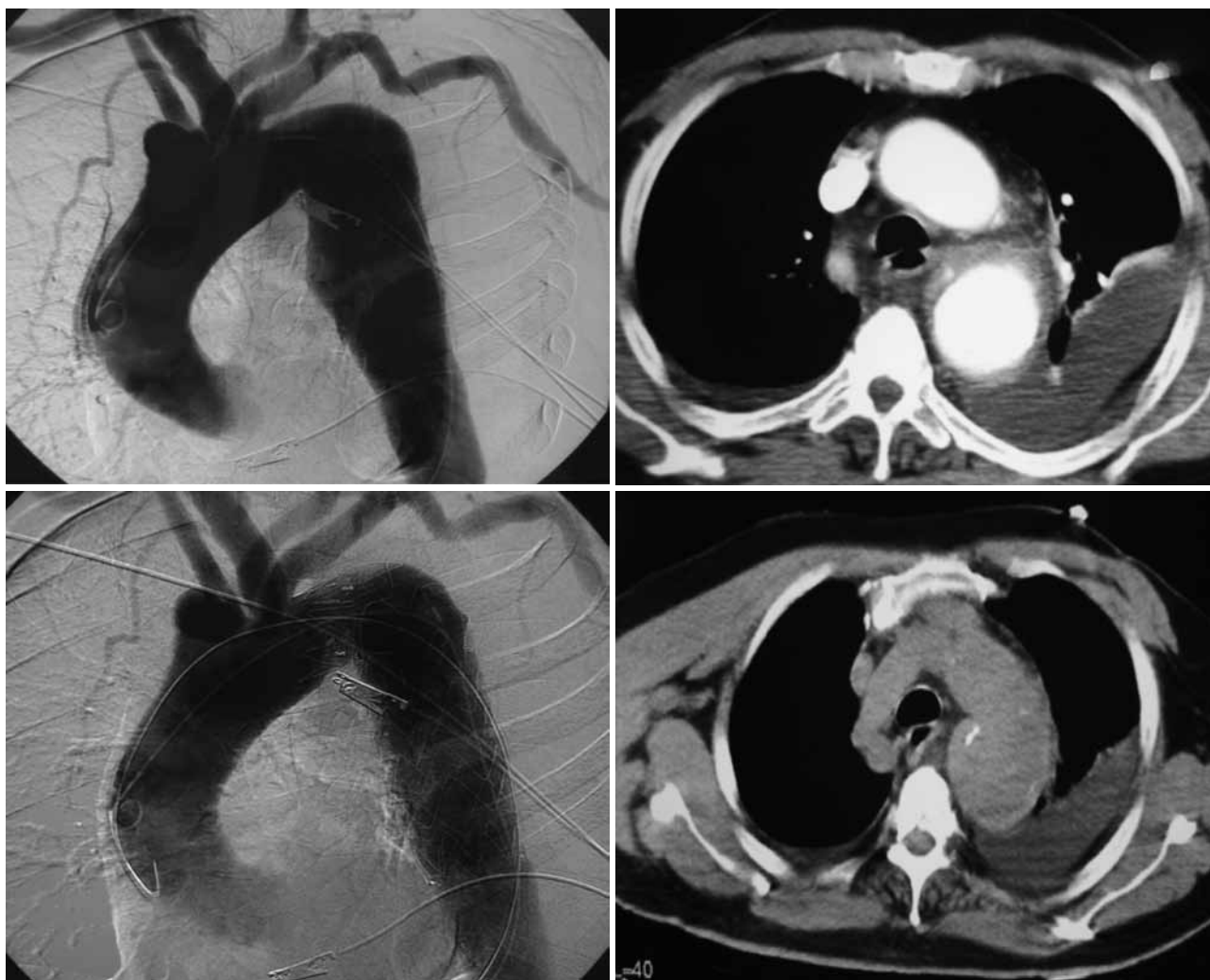


FIGURE 8. Type B intramural hematoma. CTA pre (two upper panels) and post (two lower panels) endovascular repair. CTA = computed tomography angiography.

REFERENCES

1. Vilacosta I, Aragoncillo P, Canadas V, San Roman JA, Ferreiros J, Rodriguez E. Acute aortic syndrome: a new look at an old conundrum. *Heart* 2009; 95:1130-1139.
2. Evangelista A, Mukherjee D, Mehta RH, et al. Acute intramural hematoma of the aorta: a mystery in evolution. *Circulation* 2005; 111:1063-1070.
3. Lansman SL, Saunders PC, Malekan R, Spielvogel D. *J Thorac Cardiovasc Surg* 2010; 140(6 Suppl):S92-7; discussion S142-S146.
4. Hirst AE Jr, Johns VJ Jr, Kime SW Jr. Dissecting aneurysm of the aorta: a review of 505 cases. *Medicine (Baltimore)* 1958; 37:217-279.
5. Song J-K, Yim JH, Ahn J-M, et al. Outcomes of patients with acute type A aortic intramural hematoma. *Circulation* 2009; 120:2046-2052.
6. Kan C-B, Chang R-Y, Chang J-P. Optimal initial treatment and clinical outcome of type A aortic intramural hematoma: a clinical review. *Eur J Cardiothorac Surg* 2008; 33:1002-1006.
7. Park K-H, Lim C, Choi JH, et al. Prevalence of aortic intimal defect in surgically treated acute type A intramural hematoma. *Ann Thorac Surg* 2008; 86:1494-1500.
8. Cho KR, Stanson AW, Potter DD, Cherry KJ, Schaff HV, Sundt TM III. Penetrating atherosclerotic ulcer of the descending thoracic aorta and arch. *J Thorac Cardiovasc surg* 2004; 127:1393-1401.
9. Quint LE, Williams DM, Francis IR, et al. Ulcer-like lesions of the aorta: imaging features and natural history. *Radiology* 2001; 218:719-723.
10. Mac Haalany J, Yam Y, Ruddy TD, et al. Potential clinical and economic consequences of non-cardiac incidental findings on cardiac computed tomography. *J Am Coll Cardiol* 2009;

ACUTE AORTIC SYNDROMES

- 54:1533-1541.
11. Lehman SJ, Abbara S, Cury RC, et al. Significance of cardiac computed tomography incidental findings in acute chest pain. *Am J Med* 2009; 122:543-549.
 12. Ganaha F, Miller DC, Sugimoto K, et al. Prognosis of aortic intramural hematoma with and without penetrating atherosclerotic ulcer: a clinical and radiological analysis. *Circulation* 2002; 106:342-348.
 13. Kitai T, Kaji S, Yamamuro A, et al. Clinical outcomes of medical therapy and timely operation initially diagnosed type A aortic intramural hematoma: a 20-year experience. *Circulation* 2009; 120(11 Suppl):S 292-8.
 14. Halsted JC, Meier M, Etz C, et al. The fate of the distal aorta after repair of acute type A aortic dissection. *J Thorac Cardiovasc Surg* 2007; 133:127-135.
 15. Fattouch K, Sampognaro R, Navarra E, et al. Long-term results after repair of type A acute aortic dissection according to false lumen patency. *Ann Thorac Surg* 2009; 88:1244-1250.
 16. Estera A, Miller C III, Lee T-Y, et al. Acute type A intramural hematoma: analysis of current management strategy. *Circulation* 2009; 120(11 Suppl):S287-291.