

**CASE REPORT**

# Kounis Syndrome Manifesting as Acute ST-Segment Elevation Due to Coronary Vasospasm After Cefuroxime-Induced Anaphylactic Shock

Nikolaos Laschos, MD, Stavros Tzerefos, MD, Andreas Katsaros, MD,  
Dimitrios Chrissos, MD

*Department of Cardiology, General  
Hospital of Tripolis, Tripolis, Greece*

**KEY WORDS:** *cefuroxime; allergic  
reaction; acute coronary syndrome;  
Kounis syndrome*

**ABBREVIATIONS**

ACS = acute coronary syndromes  
CK = creatine kinase  
CMR = cardiac magnetic resonance  
(imaging)  
ECG = electrocardiogram  
ER = emergency room

*Correspondence to:*

Nikolaos Laschos, MD,  
8 Pezopoulou Street,  
11526 Ampelokipi, Athens, Greece;  
Tel.: +30 6980374949;  
E-mail: [nicklaschos@yahoo.com](mailto:nicklaschos@yahoo.com)

*Manuscript received March 12, 2012;  
Revised manuscript received August 31,  
2012; Accepted September 23, 2012*

**ABSTRACT**

A 41-year-old patient presented to the emergency room after intake of cefuroxime 500 mg. He had dyspnea and hypotension and the electrocardiogram (ECG) showed ST-segment elevation in leads II, III, aVF, V<sub>2</sub>-V<sub>6</sub>. He was successfully managed with oxygen, intravenous corticoids, antihistamines and epinephrine. This constellation of presenting symptoms and signs was attributed to a manifestation of Kounis syndrome (allergic angina). The connection between acute coronary syndromes and anaphylaxis seems to be strong. The same mediators released during acute allergic reactions are increased in blood or urine of patients suffering from acute coronary syndromes of non allergic etiology.

**INTRODUCTION**

Cefuroxime is a second-generation cephalosporin antibiotic that has been widely available around the world for a long time (since 1977 in the USA). Cefuroxime is generally well tolerated and side effects are usually transient. Most common side-effects are diarrhea, nausea, vomiting, headaches, migraines, dizziness, and abdominal pain. There is a widely quoted cross allergy risk of 10% between cephalosporin and penicillin. In the medical literature, cefuroxime has been implicated as a cause of Kounis syndrome. Kounis syndrome is defined as the concurrence of acute coronary syndromes with conditions associated with mast cell activation involving interrelated and interacting inflammatory cells, and including allergic or hypersensitivity and anaphylactic insults.

**CASE REPORT**

A 41-year-old man was admitted to the emergency room (ER) of a General Hospital in a state of shock. He had received a tablet of cefuroxime because of an upper

**Authors' Disclosure:** All authors have substantially contributed to the collection and interpretation of data, the writing and editing process, and finally have read and approved the submitted manuscript. This article has not been published before and is not under consideration for publication elsewhere. There is any conflict of interest for authors concerning the submitted work.

## KOUNIS SYNDROME

respiratory tract infection. He had no medical record of drug allergies. Five to ten minutes after taking the pill, he developed pruritus and a quickly expanded skin rash. He complained of dyspnea and dizziness. In the ER he presented with skin rash, weak pulmonary sounds on auscultation with prolonged expiration, quiet heart sounds, regular heart rate at 70 beats per minute, and blood pressure of 85/45 mmHg. Complete blood count showed eosinophilia (7.4%), neutrophilia (82.6%), and no other abnormalities. Biochemical analysis showed mild hyperglycemia (glucose 8.9 mmol/l). Electrolytes, liver enzymes, creatine kinase, blood urea nitrogen, and creatinine were all normal. Troponin T was negative. Arterial blood gas analysis showed a pH of 7.35, pCO<sub>2</sub> 36 mmHg, pO<sub>2</sub> 62 mmHg, and oxygen saturation 90%. ECG revealed ST-segment elevation in leads II, III, aVF, and V<sub>2</sub>-V<sub>6</sub> without ST-segment elevation in the right precordial leads (Fig. 1).

The patient was treated with oxygen via a Venturi mask providing a fraction of inspired oxygen of 35%, intravenous hydrocortisone (250 mg bolus dose) and an antihistamine agent (dimethindene maleate 4 mg intravenously). He was then transferred to the intensive care unit where he was placed on continuous monitoring. At 20 minutes after his admission, the ST-segment elevation was not present (Fig. 2). The patient developed dyspnea and wheezing, for which he received epinephrine (1 mg subcutaneously) in order to maintain arterial O<sub>2</sub> saturation above 90%. His clinical condition improved quickly but treatment was continued with intravenous methylprednisolone 40 mg tid and per os cetirizine dihydrochloride 10 mg bid for three more days. Repeat ECG recordings showed a

regular heart rhythm and a rate of 72 bpm with negative T-wave in leads II, III, aVF, and V<sub>2</sub>-V<sub>6</sub> three days after admission (Fig. 3). Troponin T reached 0.45 ng/ml the next day (normal <0.1 ng/ml) and became negative two days later. Electrolytes and creatine kinase (CK)-MB were within normal range. Echocardiography revealed no wall motion abnormalities (left ventricular ejection fraction 60-65%) with normal systolic and diastolic function. Measurements of specific IgE, histamine and tryptase serum levels were not performed. Patient was subsequently scheduled for coronary angiography and cardiac magnetic resonance (CMR) imaging. Coronary angiography did not show any severe obstructive atherosclerotic lesions, while CMR was negative for myocarditis.

## DISCUSSION

Acute coronary syndromes (ACS) are a serious clinical problem. The association between ACS and anaphylaxis seems to be strong. It has been shown that the same mediators released during acute allergic reactions are increased in blood or urine of patients suffering from ACS of non allergic etiology. Released mediators involved in Kounis syndrome are histamine, neutral proteases such as chymase and tryptase, platelet activating factor, cytokines, chemokines, arachidonic acid products, leukotriens and prostaglandins. These substances activate and interact with macrophages, T-lymphocytes and endothelial cells.<sup>1-3</sup> Locally activated mast cells participate in the weakening of atherosclerotic plaques predisposing to

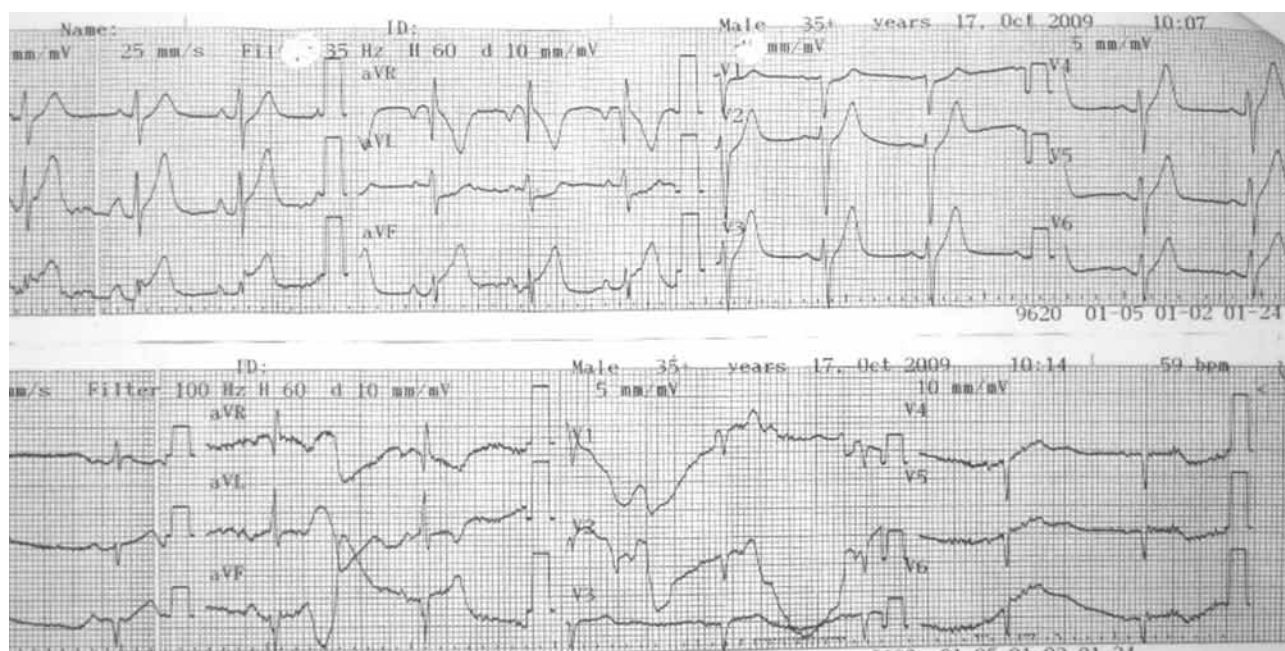


FIGURE 1. Patient's ECG at presentation in the emergency room.

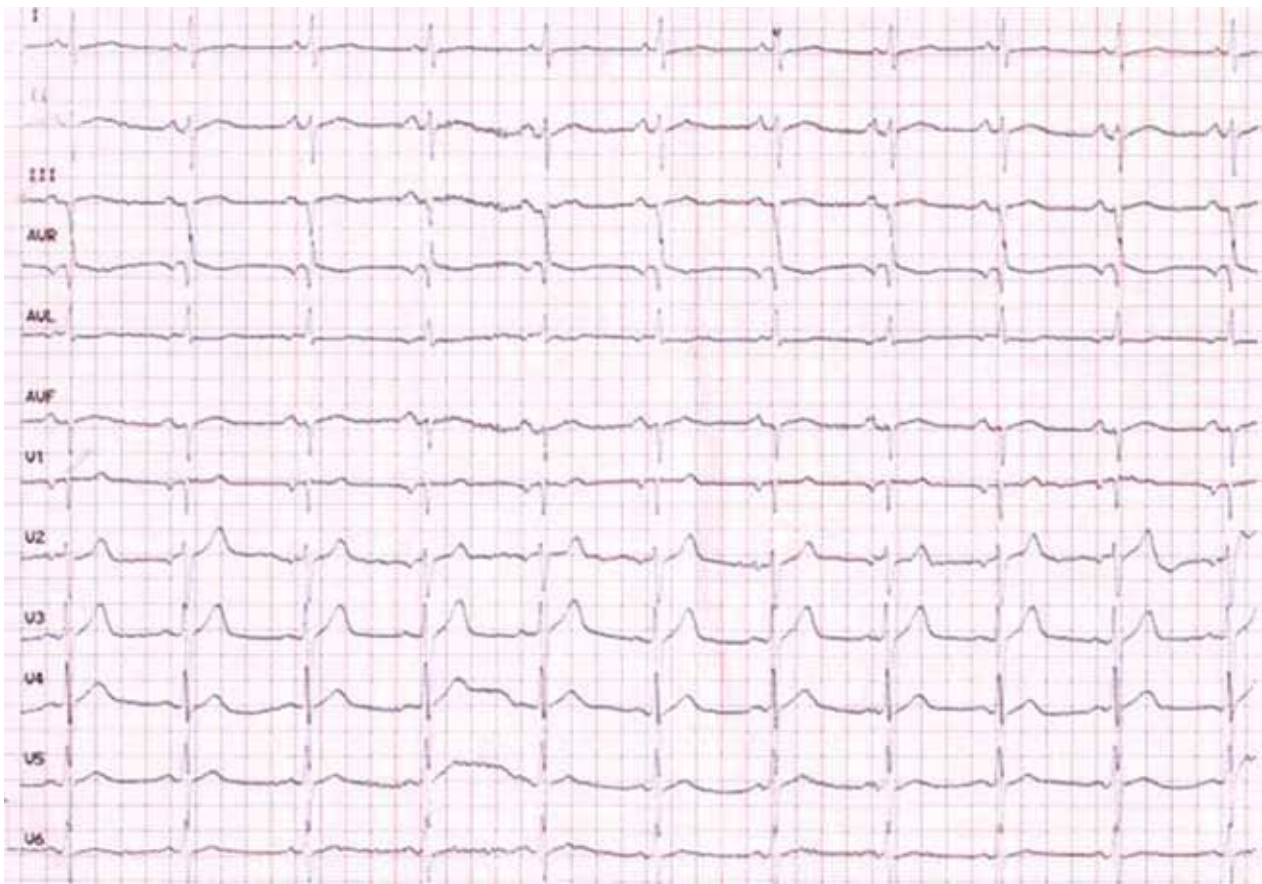


FIGURE 2. Patient's ECG 20 minutes after initial treatment.

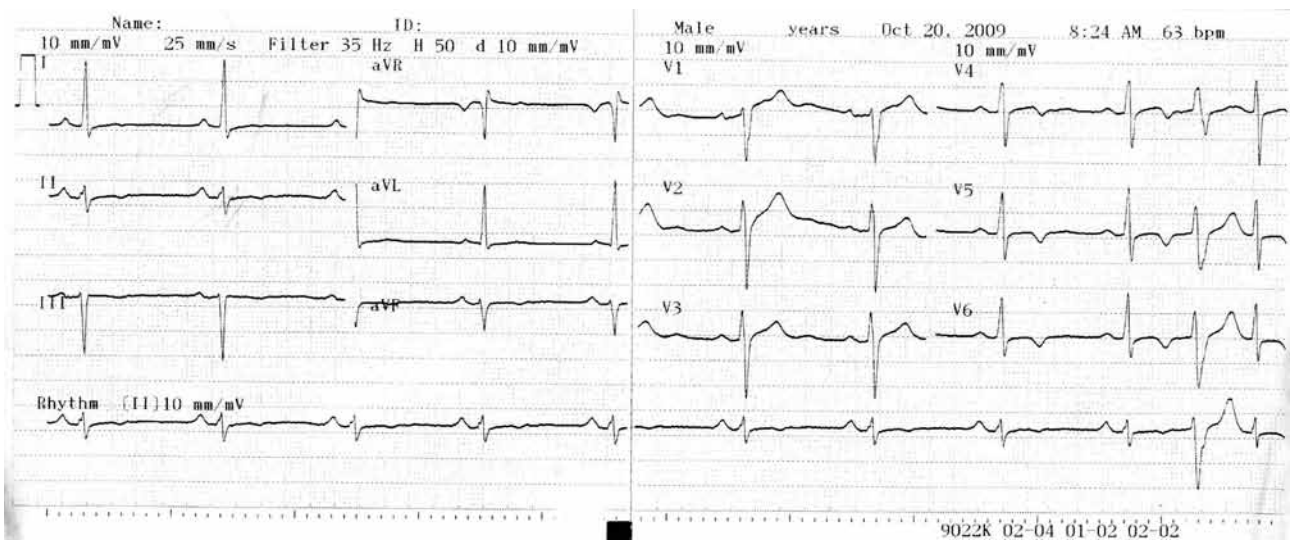


FIGURE 3. Patient's ECG three days after admission.

plaque erosion or rupture.<sup>4</sup>

There are three variants of Kounis syndrome. The type I variant includes patients with normal coronary arteries without predisposing factors for coronary artery disease, in whom the acute release of inflammatory mediators can induce either coronary artery spasm without increase of cardiac enzymes and troponins or coronary artery spasm progressing to acute myocardial infarction with raised cardiac enzymes and troponins.

Type II variant includes patients with culprit but quiescent pre-existing atherosclerotic disease, in whom the acute release of inflammatory mediators can induce either coronary artery spasm with normal cardiac enzymes and troponins or plaque erosion or rupture manifesting as acute myocardial infarction.

Type III variant includes patients with coronary artery thrombosis (including stent thrombosis), in whom aspirate thrombus specimens stained with hematoxylin-eosin and Giemsa demonstrate the presence of eosinophils and mast cells respectively.<sup>3,5</sup>

Several conditions are related to Kounis syndrome such as angioedema, bronchial asthma, food allergy, mastocytosis, serum sickness, urticaria, Churg-Strauss syndrome, and idiopathic anaphylaxis. Allergens that trigger the release of mediators are antibiotics, analgesics, corticosteroids, antineoplastics, contrast media, anticoagulants, thrombolytics, stings (ants, bee wasp, and jellyfish), poison ivy, viper venom poisoning, and millet allergy.<sup>3</sup>

Apparently the presented case was type I Kounis syndrome. To our knowledge, in the literature there are four reports with Kounis syndrome after either per os or intramuscular administration of cefuroxime axetil.<sup>6-9</sup> Kounis syndrome is reported in a wide range of ages, from 9 to 90 years old. Other antibiotics that have been implicated as causative agents of Kounis syndrome are listed in **Table 1**.

Involvement of the heart during an anaphylactic episode has been reported. It is generally believed that, during an allergic reaction, systemic vasodilation, reduced venous return and leakage of plasma and volume loss due to increase in vascular permeability contribute to coronary hypoperfusion and myocardial damage. However, clinical and experimental evidence indicates that the heart can be the primary target of anaphylaxis. It was shown that within three minutes after antigen administration, the cardiac output decreased 90%, arterial blood pressure decreased 35%, and end-diastolic left ventricular pressure rose. Arterial blood pressure started declining four minutes after antigen administration. Rapid increase in end-diastolic pressure of left ventricle suggests that reduced venous return and volume loss are not the primary causes of documented depression in cardiac output and blood pressure.<sup>15,16</sup> The presence of Kounis syndrome in intact coronary arteries is a strong argument that allergic mediators have a direct role in myocardial damage.<sup>16</sup>

Physicians have to be familiar with Kounis syndrome, otherwise the diagnosis is difficult. Patients have to be aware

**TABLE 1.** Antibiotics reported as causative agents of Kounis syndrome

Cefuroxime <sup>6</sup>
Ampicillin <sup>10</sup>
Ampicillin-sulbactam <sup>10</sup>
Amoxicillin <sup>11</sup>
Amoxicillin-clavulanic acid <sup>12</sup>
Cefoxitin <sup>13</sup>
Ciprofloxacin <sup>13</sup>
Amikacin <sup>14</sup>
Cefazolin <sup>14</sup>
Cephadrine <sup>14</sup>
Cinoxacin <sup>14</sup>
Lincomycin <sup>14</sup>
Vancomycin <sup>14</sup>

of any allergies and not only drug related. Allergy alert cards should be provided from health authorities. Drugs and natural molecules which stabilize mast cell membrane and monoclonal antibodies that protect mast cell surface could emerge as novel therapeutic modalities capable to prevent acute coronary and cerebrovascular events.

## REFERENCES

1. Kounis NG, Grapsas ND, Goudevenos JA. Unstable angina, allergic angina, and allergic myocardial infarction. *Circulation* 1999; 100:e156.
2. Kounis N. Kounis syndrome (allergic angina and allergic myocardial infarction): A natural paradigm? *Int J Cardiol* 2006; 110:7-14.
3. Nikolaidis LA, Kounis NG, Gradman AH. Allergic angina and allergic myocardial infarction: a new twist on an old syndrome. *Can J Cardiol* 2002; 18:508-511.
4. Lindstedt KA, Kovanen PT. Mast cells in vulnerable coronary plaques, potential mechanisms linking mast cell activation to plaque erosion and rupture. *Curr Opin Lipidol* 2004; 15:567-573.
5. Chen JP, Hou D, Pendyala L, Goudevenos JA, Kounis NG. Drug-eluting stent thrombosis: the Kounis hypersensitivity-associated acute coronary syndrome revisited. *JACC Cardiovasc Interv* 2009; 2:583-593.
6. Murat SN, Kurasu BB, Ornek E, Akdemir R. Cefuroxime axetil induced allergic angina: an insight into classification management of Kounis syndrome. *Int J Cardiol* 2011; 151:e53-55.
7. Ilhan E, Güvenç TS, Poyraz E, Ayhan E, Soylu Ö. Kounis syndrome secondary to cefuroxime axetil use in an asthmatic patient. *Int J Cardiol* 2009; 137:e67-69.
8. Biteker M, Duran NE, Biteker FS, et al. Kounis syndrome secondary to cefuroxime axetil use in an octogenarian. *J Am Geriatr Soc* 2008; 56:1757-1758.

9. Mazarakis A, Koutsojannis CM, Kounis NG, Alexopoulos D. Cefuroxime-induced coronary artery spasm manifesting as Kounis syndrome. *Acta Cardiol* 2005; 60:341-345.
10. Kilic D, Evrengül H, Ozcan AV, Tanriverdi H, Caglayan O, Kaf-tan A. Acute ST segment elevation myocardial infarction after sulbactam-penicillin induced anaphylactic shock in an adult with significant coronary artery disease: a case report. *Int J Car-diol* 2009; 135:e30-33.
11. Tigen K, Cevik C, Basaran Y. Acute myocardial infarction following amoxicillin allergy: coronary angiography and ultra-sound findings. *Acta Cardiol* 2007; 62:525-528.
12. Biteker M, Duran NE, Biteker FS, et al. Kounis syndrome sec-ondary to amoxicillin/clavulanic acid use in a child. *Int J Cardiol* 2009; 136:e3-5.
13. Almpanis G, Siahos S, Karogiannis NC, et al. Kounis syndrome: two extraordinary cases. *Int J Cardiol* 2011; 147:e35-38.
14. Lopez PR, Peiris AN. Kounis syndrome. *South Med J* 2010; 103:1148-1155.
15. Felix SB, Baumann G, Berdel WE. Systemic anaphylaxis -- separation of cardiac reactions from respiratory and peripheral vascular events. *Res Exp Med* 1990; 190:239-252.
16. Fassio F, Almerigogna F. Kounis syndrome (allergic acute coro-nary syndrome): different views in allergologic and cardiologic literature. *Intern Emerg Med* 2012; 7:489-495.