

IMAGES IN MEDICINE

Catheter Ablation of Two Accessory Pathways in Elusive Ebstein's Anomaly: Procedure Facilitation With Use of a Long Vascular Sheath

Antonis S. Manolis, MD, Spyridon Koulouris, MD,
Efthymia Rouska, MD, Costas Kappos, MD

*First and Second Departments of
Cardiology, Evagelismos General
Hospital of Athens, Athens, Greece*

KEY WORDS: *accessory pathways;
Wolff-Parkinson-White syndrome;
Ebstein's anomaly; catheter ablation;
radiofrequency ablation*

Correspondence to:
Antonis Manolis, MD,
First Department of Cardiology,
Evagelismos Hospital, Athens,
Greece;
E-mail: asm@otenet.gr

*Manuscript received September 9, 2011;
revised manuscript received November 4,
2011; accepted November 11, 2011*

A 17-year-old adolescent male presenting with multiple episodes of palpitations over the preceding 9 months refractory to antiarrhythmic drug therapy and with manifest preexcitation on the 12-lead surface electrocardiogram-ECG (type B Wolff-Parkinson-White syndrome) was referred for radiofrequency (RF) catheter ablation. The initial echocardiographic evaluation was reported normal. The first procedure was tedious and prolonged, hampered by the occurrence of mechanical block in the anterograde conduction of the accessory pathway (loss of preexcitation) for the duration of the procedure. There was only retrograde conduction noted via a right lateral accessory pathway and inducible atrioventricular (AV) reentrant tachycardia with the participation of this concealed pathway, which was successfully ablated after the delivery of 9 RF energy applications.

At 2 months later the patient had a recurrence of symptomatic tachycardia, while the ECG showed manifest preexcitation again (Fig. 1, left upper panel). At 10 months after the initial procedure, the patient consented to a second RF catheter ablation procedure. During this procedure a long vascular sheath (Swartz) was employed to better stabilize the mapping and ablation catheter at the tricuspid annulus and possibly avoid the mechanical block in the accessory pathway conduction. Indeed, electrophysiological mapping localized this manifest accessory pathway with bidirectional conduction at a different position from the previous right lateral concealed accessory pathway. This was located at the antero-septal region in juxtaposition to the AV node-His bundle area (Fig. 1, right upper panel). With the assistance of the long vascular sheath (Fig. 1, left lower panel), the pathway was successfully ablated after only 3 applications of RF energy. The use of the long sheath assisted in the stabilization and good contact of the ablation catheter and the successful ablation, but also rendered feasible the avoidance of injury to the AV node-His bundle region which would have led to a feared complication of AV block.

Following this second procedure and for the ensuing 5 years, the patient has remained free of any tachycardia recurrences, while there has been no preexcitation noted on the ECG (Fig. 1, right lower panel). Meanwhile, a repeat echocardiographic examination did demonstrate a typical case of moderate Ebstein's anomaly (Fig. 2) with the downward displacement of the septal and posterior leaflets of the tricuspid valve toward the right ventricular apex, with a large ventricularized right atrium but

ACCESSORY PATHWAYS IN ELUSIVE EBSTEIN'S ANOMALY

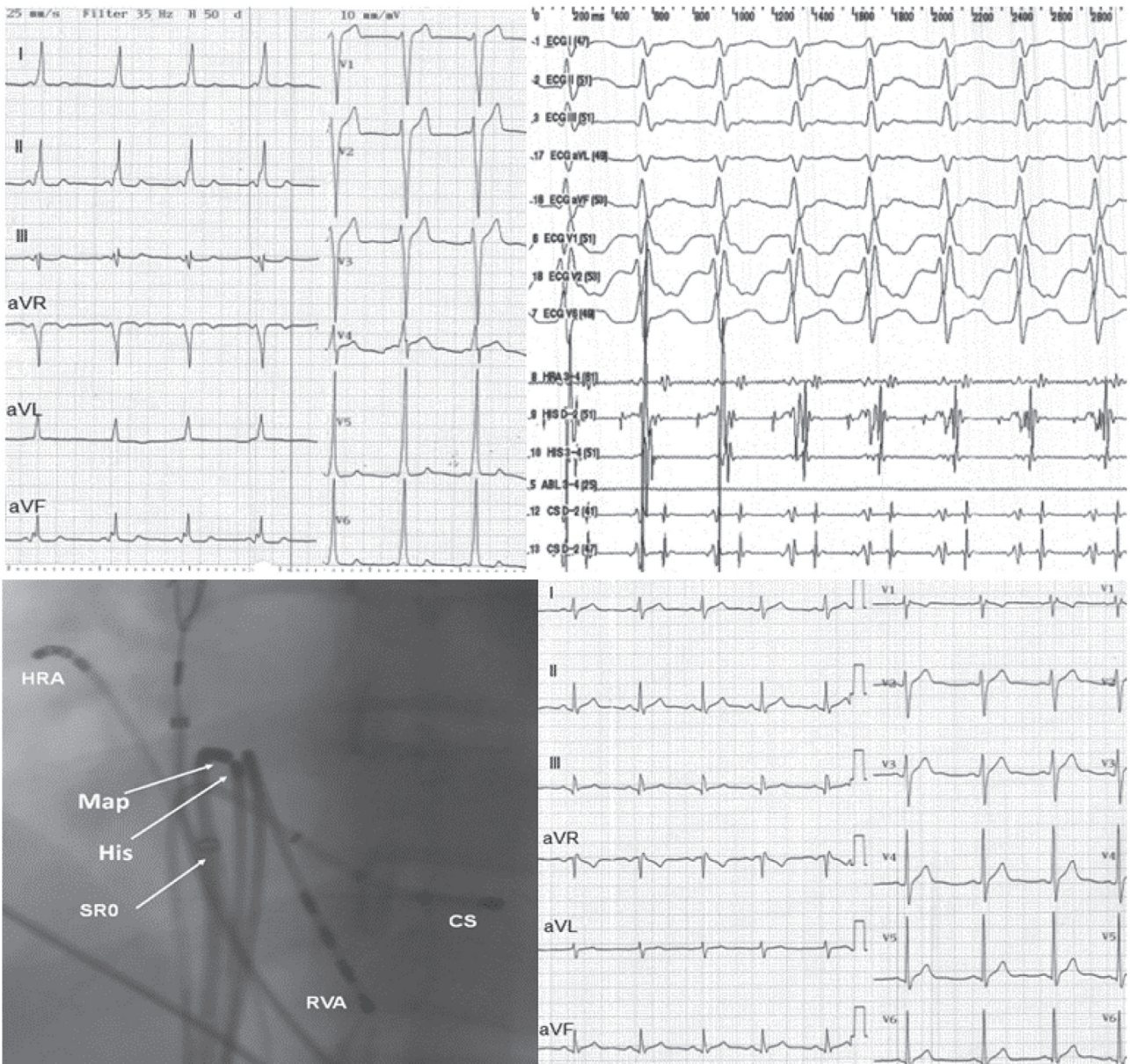

FIGURE 1. Preexcitation was manifest on the 12-lead electrocardiogram (ECG) (left upper panel) when the patient returned for a second radiofrequency ablation procedure due to recurrence of symptoms. During the procedure an anteroseptal accessory pathway was localized in close proximity to the bundle of His (No. 9 / His-D recording at the right upper panel indicates very short ventriculo-atrial interval during the supraventricular tachycardia). This accessory pathway was successfully ablated with the assistance of a long sheath (SR0) which stabilized the ablation catheter (Map) (left lower panel). After the procedure a normal 12-lead ECG is recorded free of preexcitation (right lower panel). CS = coronary sinus; HRA = high right atrium; RVA = right ventricular apex.

with mild tricuspid valve regurgitation and no interatrial communication. This better explains the difficulties encountered during the first ablation procedure when the right lateral concealed accessory pathway required multiple attempts before successful ablation and in view of non-use of the stabilizing sheath, which immensely facilitated the second procedure.

•••

Ebstein's anomaly accounts for <1% of congenital heart diseases, characterized by downward apical displacement of the tricuspid valve (Fig. 2) and cardinal, but variable, clinical symptoms of cyanosis, right-sided heart failure and arrhythmias.¹ Manifest preexcitation has been reported in 5-25% of

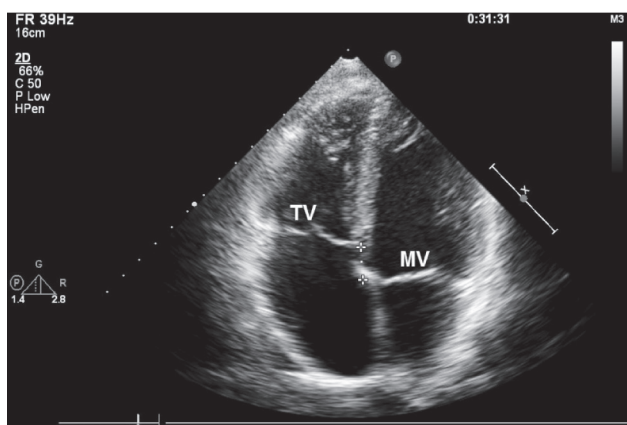


FIGURE 2. Two-dimensional echocardiography (four-chamber view) depicts the attachment of the septal and posterior leaflets of the tricuspid valve (TV) displaced apically (by 15 mm) in comparison with the attachment of the anterior (septal) leaflet of the mitral valve (MV), all consistent with mild-to-moderate Ebstein's anomaly. While the septal and posterior tricuspid leaflets are mildly hypoplastic, the anterior tricuspid leaflet (not shown) was big, sail-like, and its attachment to the right ventricular free wall almost normal.

patients with Ebstein's anomaly, while paroxysmal AV reentrant tachycardia may occur in 25% to 30% of these patients due to additional presence of concealed accessory pathways. Furthermore, almost half of patients with Ebstein's anomaly and accessory pathways have multiple accessory pathways, mainly located on the right side.

Catheter ablation of accessory pathways² in Ebstein's anomaly is a more challenging and demanding procedure.^{3,4} Specifically, the atrialized portion of the right ventricle renders the mapping procedure more difficult due to recording of abnormal (fragmented) local electrograms impeding the identification of relevant electrical signals. Additionally, these patients usually have multiple accessory pathways localized

along the atrialized right ventricle, complicating matters further. Repeat procedures are usually required in almost up to half of the patients undergoing a first ablation attempt due to recurrences. This commonly relates to both multiple accessory pathways but also to technical issues pertaining to the dysplastic tricuspid annulus and dilated right atrium both impairing arrhythmia mapping and catheter stability. The latter issue was apparently important in the present case and the use of a long vascular sheath helped stabilize the catheter which was a decisive factor in succeeding to ablate the second accessory pathway during the repeat procedure.

The typical echocardiographic feature of the disease is the apical displacement of the septal leaflet of tricuspid leaflet of greater than 8 mm, however, this may go unnoticed in milder forms with milder degrees of leaflet tethering, as it initially happened in the present case. Ebstein's anomaly has a highly variable natural history depending on the degree of abnormality and deformity of the tricuspid valve, with a spectrum ranging from mild to severe forms. If it were not for the arrhythmia recurrence and a more astute echocardiographer, it would have gone unnoticed in the present case.

REFERENCES

1. Attenhofer Jost CH, Connolly HM, Edwardsb WD, Hayes D, Warnes CA, Danielson GK. Ebstein's anomaly – review of a multifaceted congenital cardiac condition. *SWISS MED WKLY* 2005; 135 : 269 – 281.
2. Manolis AS, Wang PJ, Estes NAM III. Radiofrequency catheter ablation for cardiac tachyarrhythmias. *Ann Intern Med* 1994; 121:452-461.
3. Cappato R, Schluter M, Weiss C, et al. Radiofrequency current catheter ablation of accessory atrioventricular pathways in Ebstein's anomaly. *Circulation* 1996;94:376-383.
4. Hebe J. Ebstein's anomaly in adults. Arrhythmias: diagnosis and therapeutic approach. *Thorac Cardiovasc Surg* 2000;48:214-219.