

## IMAGES IN MEDICINE

## Ciprofloxacin-Induced Cardiac Arrest

Athanasios J. Manolis, MD,<sup>1</sup> Leonidas Poulimenos, MD,<sup>1</sup>  
Antonis S. Manolis, MD<sup>2</sup>

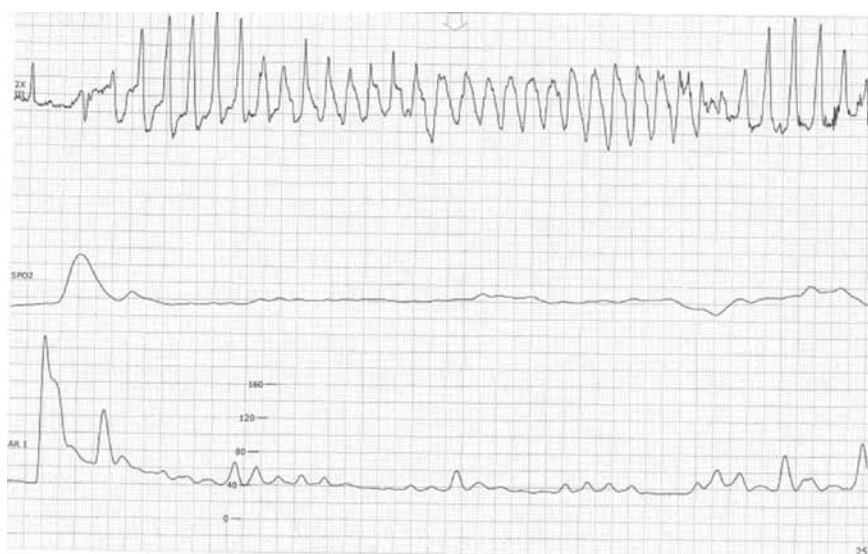
## ABSTRACT

<sup>1</sup>Department of Cardiology,  
Asclepieion General Hospital,  
<sup>2</sup>First Department of Cardiology,  
Evangelismos Hospital, Athens, Greece

Polymorphic ventricular tachycardia in the form of torsade des pointes occurred in a patient on chronic therapy with amiodarone and a baseline prolonged QT interval, only when ciprofloxacin was added for treatment of urinary tract infection and did not recur after discontinuation of the antibiotic.

**KEY WORDS:** *polymorphic ventricular tachycardia; torsade des pointes; ciprofloxacin; acquired long QT syndrome; amiodarone*

An 87-year-old patient was hospitalized for respiratory insufficiency and diastolic heart failure. The patient was on chronic amiodarone therapy for paroxysmal atrial fibrillation and had a baseline prolonged QT interval at 600 ms, but had no prior history of ventricular tachyarrhythmias. He had chronic renal failure with a creatinine at 2.2 mg/dl. While in the intensive care unit, the patient developed a urinary tract infection for which he was placed on intravenous ciprofloxacin, 400 mg bid. The next day the patient sustained an episode of cardiac arrest due to polymorphic ventricular tachycardia in the form of typical torsade des pointes (Figure, upper panel), leading to immediate collapse of oximetry (mid panel) and blood pressure (lower panel), for which he required electrical cardioversion. Electrolytes were checked and found to be within normal limits. There was no evidence of acute ischemia. The antibiotic was discontinued and there was no further recurrence of ventricular tachyarrhythmias.



Correspondence to:  
Athanasios J. Manolis, MD  
Director of Cardiology  
Asclepieion General Hospital  
Voula, Athens, Greece  
E-mail: [ajmanol@otenet.gr](mailto:ajmanol@otenet.gr)

Manuscript received & accepted  
December 15, 2010



Quinolones are broad-spectrum antibiotic agents commonly prescribed for respiratory or urinary tract infections. However, they are associated with the possible proarrhythmic side-effect of QT prolongation causing concern with regards to the development of life-threatening ventricular tachyarrhythmias in the form of polymorphic VT (torsade des pointes) leading to cardiac arrest. Among other quinolones, ciprofloxacin often is chosen because of its perceived weaker proarrhythmic potential conferring lower rates of torsade des pointes compared with the other compounds of this class of antibiotics. However, as shown in the present case and a few other reports in the literature,<sup>1-3</sup> it also possesses a cardiotoxic effect and can lead to serious proarrhythmia by causing torsade des pointes. This is particularly noted in the presence of other concomitant risk factors, among which one should in-

clude chronic amiodarone therapy which consistently prolongs the QT interval, albeit rarely does it by itself cause torsades des pointes compared with other antiarrhythmic agents (e.g., quinidine or sotalol). Thus, in patients with a baseline prolonged QT interval, other potentially QT-prolonging agents should best be entirely avoided.

#### REFERENCES

1. Amankwa K, Krishnan SC, Tisdale JE. Torsades de pointes associated with fluoroquinolones: Importance of concomitant risk factors *Clinical Pharmacology & Therapeutics* 2004; 75:242-247.
2. Prabhakar M, Krahn AD. Ciprofloxacin-induced acquired long QT syndrome. *Heart Rhythm* 2004; 1:624-626.
3. Flanagan MC, Mitchell ES, Haigney MCP. Ciprofloxacin-induced torsade de pointes. *Intern J Cardiol* 2006; 113:239-241.

