

CASE REPORT

Concomitant Intraoperative Radiofrequency and Microwave Ablation of Atrial Fibrillation and Repair of Atrial Septal Defect

Mihalis Argiriou, MD, Athanase Krassas, MD,
Victor Panagiotakopoulos, MD, Constantine Spiliotopoulos, MD,
Dimitris Asimomitis, MD, Christos Charitos, MD

*2nd Department of Cardiac Surgery,
Evangelismos General Hospital of
Athens, Athens, Greece*

KEY WORDS: atrial fibrillation;
radiofrequency ablation; microwave
ablation; atrial septal defect

ABSTRACT

Atrial fibrillation (AF) is the most frequent form of atrial arrhythmias in adults with congenital heart disease. Some serious complications are related with the presence of AF after surgery. Because of the complexity and the risk of bleeding, the Maze III procedure has been largely replaced by alternative energy sources. A patient with multiple atrial septal defects (ASD) and AF underwent surgical closure with autologous pericardial patch and radiofrequency and microwave ablation of AF.

INTRODUCTION

Atrial fibrillation (AF) is quite common among patients with atrial septal defect (ASD) and is associated with increased morbidity in this cohort. Surgical closure of the ASD in these patients can be performed with a low mortality rate and improves their clinical status. Intraoperative treatment of AF has been traditionally performed with the Maize procedure, which is though a complex surgical technique with its attendant risks. We herein present a patient with both ASD and AF, whom we submitted to surgical ASD closure combined with intraoperative radiofrequency and microwave ablation of AF.

CASE REPORT

We report a case of successful left atrial radiofrequency bipolar - microwave ablation for chronic atrial fibrillation (AF) in a patient who had multiple atrial septal defects (ASDs). Preoperative echocardiogram showed that the patient was in permanent AF for at least 24 months. The pulmonary (Qp) to systemic (Qs) flow ratio was calculated at 2.1:1. The left atrial dimension was 50 mm, the right atrial area 48 x 67 mm² and the

ABBREVIATIONS

AF = atrial fibrillation
ASD = atrial septal defect

Correspondence to:

Mihalis Argiriou, MD
2nd Department of Cardiac Surgery
Evangelismos General Hospital of
Athens
Athens, Greece
E-mail: mihalisargiriou@ath.
forthnet.gr

ASD REPAIR & AF ABLATION

right ventricular dimension 34 mm (Fig. 1). The operation was performed under cardiopulmonary bypass. Cold, antegrade blood cardioplegic solution was used. Ablation was performed in both the right and left atrium. Right atrial ablation lines included: (1) from the superior vena cava cannulation to inferior vena cava cannulation; (2) from the right appendage to the tricuspid valve annulus; (3) from the inferior vena cava to the coronary sinus; and (4) from the coronary sinus to the tricuspid valve annulus. In the left atrium, the ablation lines were as follows: (1) around the base of the left atrial appendage; (2) around the left and right pulmonary veins; (3) a line connecting the left atrial appendage with the left superior pulmonary vein (4) a line connecting the two pulmonary vein circles; and (5) connecting the middle of the line to the posterior mitral valve annulus. Lesions (1), (2), (3) in the left atrium were created

with the Atricure® isolator Synergy ablation clamp (Atricure Inc., West Chester, OH, USA), which creates a uniform, column-shaped lesion, pulsating energy between the two pairs of electrodes. The result is a robust, high-definition lesion. The (4) and (5) left atrium lesions which were created through the ASD and the right atrial lesions were produced with microwave energy source using the Guidant® Flex 4 microwave system (Boston Scientific-Guidant Co., Natick, MA, USA) (Fig. 2 & 3). The duration of the ablation procedure was 18 min. Closure of ASDs was performed with use of autologous pericardial patch (Fig. 4). There were no complications related to radiofrequency and microwave ablation and the patient was discharged home in sinus rhythm. The electrocardiogram at the 3-month follow-up showed sinus rhythm.

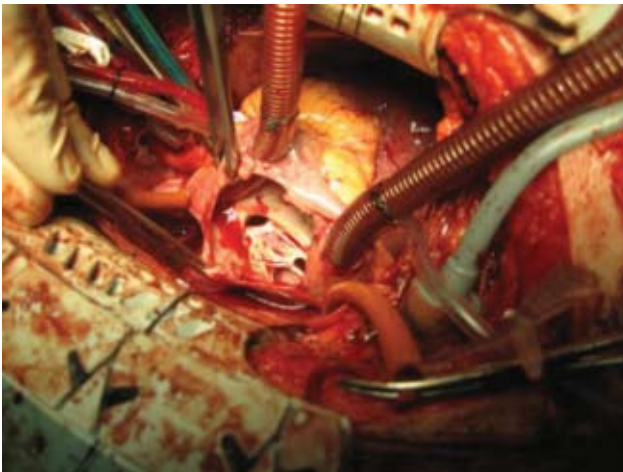


FIGURE 1.

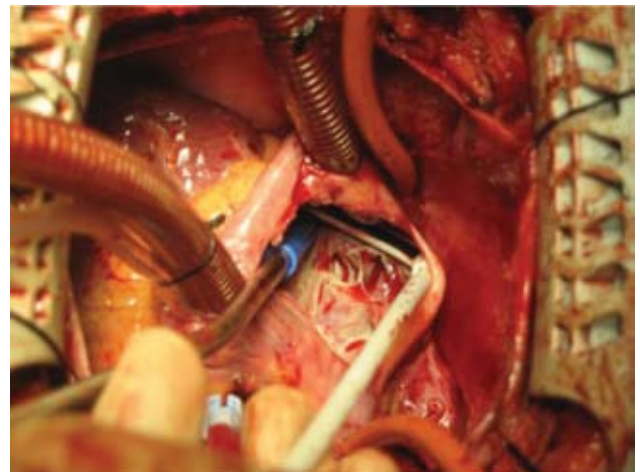


FIGURE 3.

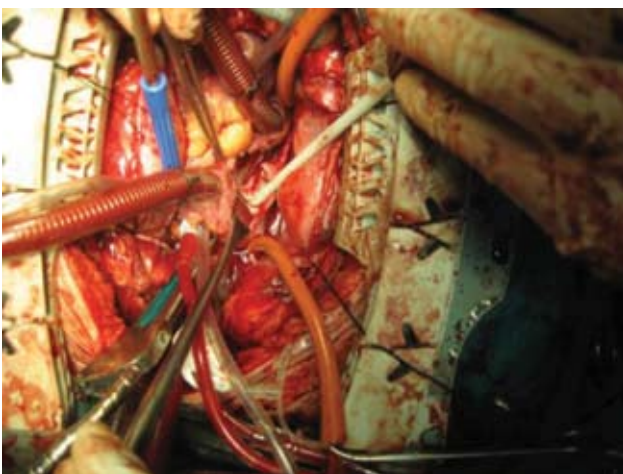


FIGURE 2.

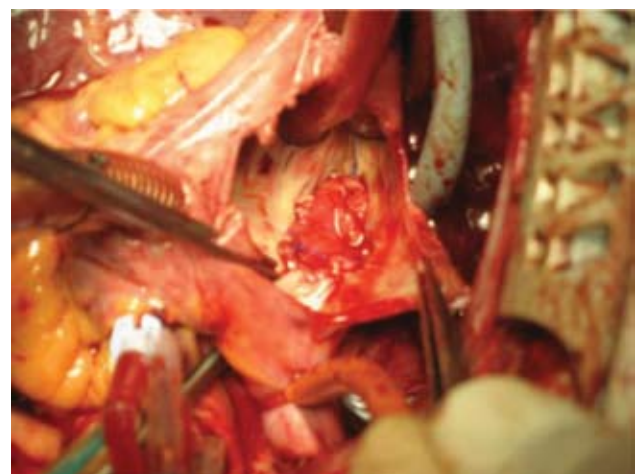


FIGURE 4.

DISCUSSION

Atrial fibrillation (AF) is the most frequent form of atrial arrhythmia in adults with congenital heart disease. The incidence of AF in adults with atrial septal defect (ASD) varies from 8% to 25%, and it increases with age. The occurrence of atrial arrhythmias does not decrease even when the defect is successfully surgically corrected.^{1,2} Atrial fibrillation is found at late follow-up in approximately half of all adults who have had correction of ASD, even if it were not present preoperatively. These atrial tachycardias have a poor response to medication. These patients are thus exposed to the risks of stroke and chronic drug therapy even after a successful operation. Surgical correction of an ASD leads to regression of the incidence of atrial flutter but not AF. Thus, surgical repair of an ASD to abolish supraventricular tachyarrhythmias in adults is warranted, but in patients with AF, it may have to be combined with a Maze operation.

CONCLUSION

The small added risk and the substantial benefit of eliminating AF suggest that this approach of intraoperative ablation of AF is warranted in selected adult patients with ASD. Radiofrequency bipolar ablation and microwave ablation³ is an easy, effective, safe and economic concomitant operation to eliminate AF in adult patients with congenital heart defect and AF.

REFERENCES

1. Konstantinides S, Geibel A, Olschewski M, et al. A comparison of surgical and medical therapy for atrial septal defect in adults. *N Engl J Med* 1995; 333:469–473
2. Berger F, Vogel M, Kramer A, et al. Incidence of atrial flutter/fibrillation in adults with atrial septal defect before and after surgery. *Ann Thorac Surg* 1999; 68:75–78.
3. Topkara VK, Williams MR, Barili F, et al. Radiofrequency and microwave energy sources in surgical ablation of atrial fibrillation: a comparative analysis. *Heart Surg Forum* 2006;9: E614-617.