

CASE REPORT

# Hypersensitivity to Proton Pump Inhibitors: Lansoprazole-Induced Kounis Syndrome

Georgios Ch. Almpanis, MD,<sup>1</sup> Simos P. Siachos, MD,<sup>1</sup>  
Nicholas P. Vlahos, MD,<sup>2</sup> Andreas Mazarakis, MD<sup>1</sup>

<sup>1</sup>*1<sup>st</sup> Department of Cardiology, "Agios Andreas" State General Hospital, Patras, Greece*

<sup>2</sup>*Department of Cardiology, Pyrgos State General Hospital, Pyrgos, Greece*

**KEY WORDS:** *allergic myocardial infarction; Kounis syndrome; lansoprazole; proton pump inhibitors*

**LIST OF ABBREVIATIONS:**  
CK = creatine-kinase  
ECG = electrocardiogram  
HDL = high-density lipoprotein

*Correspondence to:*  
Georgios Almpanis, MD  
1st Department of Cardiology  
"Agios Andreas" Patras State General Hospital  
Patras, Greece  
Tel.: +30- 2610-227516  
E-mail: galmpan@gmail.com

ABSTRACT

Proton pump inhibitors are commonly used in clinical practice for the treatment of peptic ulcer disease and gastro-esophageal reflux and are well tolerated by patients. Their use is rarely associated with hypersensitivity and anaphylactic reactions. According to the reports in the Uppsala Monitoring Center database the frequency of hypersensitivity reactions among all reported adverse reactions for proton pump inhibitors and H<sub>2</sub>-histamine receptor antagonists were between 0.2% and 0.7%. A few cases of hypersensitivity to lansoprazole have been reported. Herein, we report a patient who developed Kounis syndrome after taking 40 mg of lansoprazole. To our knowledge, this is the first report of Kounis syndrome associated with lansoprazole administration in the world literature.

INTRODUCTION

Proton pump inhibitors are the main medications currently used for the treatment of various gastrointestinal disorders. In cardiac patients these agents are usually prescribed prophylactically in conjunction with aspirin and/or clopidogrel administration. They are non-competitive inhibitors of the parietal cell membrane enzyme H<sup>+</sup>/K<sup>+</sup> adenosine triphosphatase. This enzyme acts as "acid pump" or "proton pump" which constitutes the final stage of the hydrochloric acid secretion in the stomach. They are metabolized in the liver via cytochrome P450. Their use is rarely associated with side-effects and especially with hypersensitivity reactions. The following report concerns a patient who developed urticarial reaction after ingesting 30 mg of lansoprazole and immediately afterwards an acute inferior myocardial infarction presumably related to the allergic reaction to the medication<sup>1-4</sup>.

CASE REPORT

A 52-year-old man was transferred to the emergency department of our hospital

complaining of generalized itching, malaise, shortness of breath, difficulty in swallowing, and abdominal pain and numbness over his entire body. On physical examination he had an erythematous skin rash covering the whole body with facial edema; he was diaphoretic, pale, and agitated. His symptoms started 10 min after receiving 30 mg of lansoprazole for his abdominal pain. He gave a history of previous peptic ulcer and hematemesis and was taking occasionally various antiulcer preparations including omeprazole and ranitidine with good tolerance. He was a non-smoker without any previous personal or family history of allergy or other drug sensitivity.

His blood pressure was 110/80 mmHg, the pulse rate 102 beats/min regular and the electrocardiogram (ECG) was within normal limits (Fig. 1A). Pulse oximetry showed an oxygen saturation of 92%. He was treated with 500 mg of hydrocortisone sodium succinate and 4 mg of dimetindene (antihistamine) intravenously (IV). He also received inhalation of corticosteroid for difficulty in breathing.

However, while he was in the emergency room, he suddenly developed severe retrosternal pain radiating to both arms and

started vomiting. A repeat ECG (Fig 1B) showed elevation of the ST-segment in leads II, III, aVF compatible with acute inferior wall myocardial infarction. His blood pressure dropped to 80/60 mmHg. At that time the patient was given a second bolus of 500 mg of hydrocortisone sodium succinate IV, 10 mg of morphine sulphate and a blood sample was taken for cardiac enzymes, troponin, histamine, tryptase, IgE immunoglobulins, complement protein and blood count.

The patient was subsequently admitted to the coronary care unit where he was thrombolized with a bolus dose of 7000 IU of teneceplace. His symptoms gradually subsided during the ensuing 24 hours and the ECG changes returned to normal (Fig. 1C). Echocardiographic examination performed at bedside revealed hypokinesia of the inferior wall with an estimated left ventricular ejection fraction of 50%. The results of blood testing showed increased troponin T of 1.5 ng/ml (normal range <0.1 µg/L) and peak creatine kinase (CK) of 1342 IU/L with CK-MB of 150 IU/L. Blood eosinophils were raised to 9% but the complement proteins C3 and C4 were normal. Other specific blood measurements related to allergic

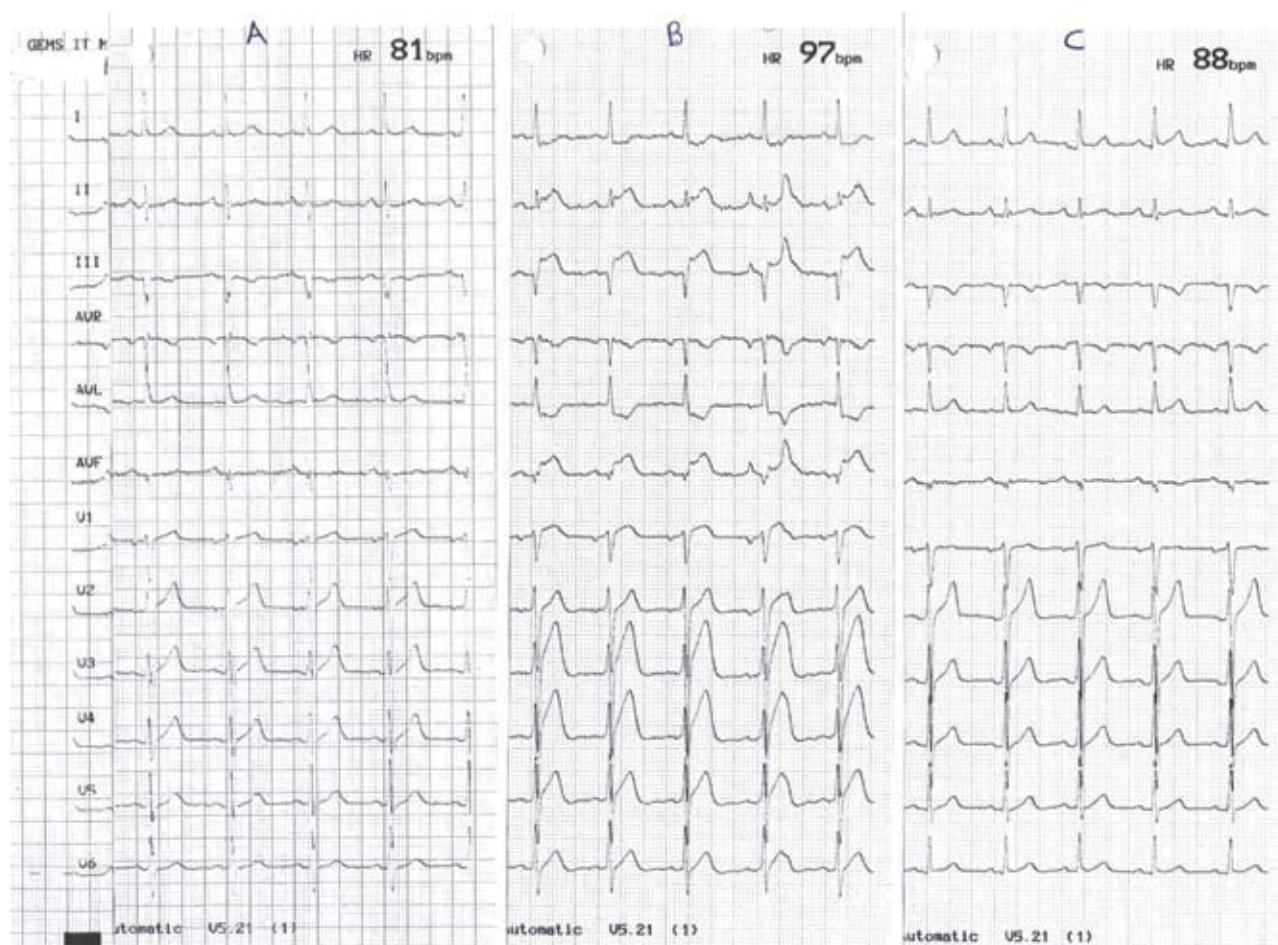


FIGURE 1.

## KOUNIS SYNDROME

reactions were increased as follows: serum tryptase 20, 35, 15 µg/l at 1, 2, 3 hours respectively (normal range 5.6-13.5), histamine 0.9 ng/L (normal range <0.2), immunoglobulin IgE 190 IU/ml (normal range <110).

The patient underwent a treadmill stress test and a hyperventilation test which were normal. Oral test dose with lansoprazole was not performed in view of the acute myocardial infarction as this was deemed clinically unsafe. However, a hypersensitivity skin test with lansoprazole (30 mg in 1 ml saline) was performed, which produced a wheal of 3 mm in diameter at 20 minutes. Similar testing with omeprazole (20 mg in 1 ml saline), pantoprazole (20 mg in 1 ml saline), ranitidine (50 mg in ml saline) and buffered saline produced no reaction, thus confirming hypersensitivity limited to lansoprazole. The patient was discharged home on the seventh day of admission. Coronary angiography performed in the neighbouring university hospital showed 80% right coronary artery lesion and the patient underwent a successful coronary angioplasty and stenting procedure.

---

### DISCUSSION

---

To the best of our knowledge this is the first patient in the literature to develop acute myocardial infarction following an allergic reaction after ingestion of lansoprazole. The association of an acute coronary syndrome and an allergic reaction has been suggested by Kounis (Kounis syndrome).<sup>1</sup> There are various drugs capable to induce Kounis syndrome<sup>5</sup> and include antibiotics, analgesics, antineoplastics, contrast media, intravenous anesthetics, corticosteroids, non-steroidal anti-inflammatory drugs, thrombolytics and skin disinfectants. Few proton pump inhibitors used in everyday practice have been implicated on rare occasions in hypersensitivity reactions. The older preparations omeprazole<sup>6-10</sup>, lansoprazole<sup>11-14</sup> and pantoprazole<sup>15-17</sup> have all been, although rarely, associated with hypersensitivity reactions. A recent review of the literature<sup>14</sup> has shown that only the newest proton pump inhibitors rabeprazole and esomeprazole are free, so far, of such reactions. Cross reactivity among the various brands has also been reported.<sup>12</sup>

The proton pump inhibitors are modified benzimidazoles containing the pyridine ring and they differ from each other in the substitution chains. They act by increasing the intragastric pH levels, which may enhance the effectiveness of the local immune response, reduce the washout of antibiotics from the gastric mucosa, and lower the minimal inhibitory concentrations of pH-sensitive antibacterial agents.<sup>10</sup>

Our patient experienced an episode of generalized urticaria after oral intake of lansoprazole, which was followed by acute inferior myocardial infarction. The clinical presentation, the positive skin test to lansoprazole, the elevated IgE concentrations, and the raised serum histamine and tryptase

levels suggest that an IgE mediated mechanism was involved in both reactions, namely, urticaria and acute myocardial infarction. During hypersensitivity reactions, vasoconstricting and collagen-degrading compounds are released locally and in peripheral circulation from activated mast cells. Preformed mediators, such as histamine, chymase, tryptase, neuropeptides, and proteoglycans, as well as newly synthesized mediators, such as arachidonic acid products, an array of chemokines and cytokines, and platelet activating factor 3 are some of them. Clinical and experimental studies<sup>18</sup> have shown that these mediators can induce coronary artery spasm and/or acute myocardial infarction. In particular, histamine is raised in the coronary circulation of patients with variant angina and can induce tissue factor expression. Tryptase has been implicated in acute coronary syndromes and can degrade HDL. Indeed, tryptase and histamine were elevated in the serum of our patient during the hypersensitivity reaction and the subsequent acute myocardial infarction.

This report shows that the proton pump inhibitor lansoprazole can be an allergic trigger for acute myocardial infarction and should be added in the list of drugs capable to induce Kounis syndrome. Since cross reactivity between these agents has been proven, physicians should be aware of this risky association and should always think about Kounis syndrome when they treat hypersensitivity complications induced by any of these compounds.

### REFERENCES

1. Kounis NG. Kounis syndrome (allergic angina and allergic myocardial infarction): a natural paradigm? *Int J Cardiol* 2006; 110: 7-14.
2. Kounis NG. Serum tryptase levels and the Kounis syndrome. *Int J Cardiol* 2007; 114: 407-408.
3. Tavil Y, Turfan M, Turkoglu S, Abaci A. Kounis syndrome secondary to amoxicillin/clavulamic acid use. *Int J Cardiol* 2008;124: e4-7. Epub 2007 Mar 13.
4. Vivas D, Rubira JCG, Ortiz AF, Macaya C. Coronary spasm and hypersensitivity to amoxicillin: Kounis or not Kounis syndrome? *Int J Cardiol* 2008;128:279-281. Epub 2007 Aug 16.
5. Mazarakis A, Koutsojannis CM, Kounis NG, Alexopoulos D. Cefuroxime-induced coronary artery spasm manifesting as Kounis syndrome. *Acta Cardiol* 2005; 60: 341-345.
6. Ottevwanger JP, Phaff RAS, Vermeulen EGJ, Sticker BHC. Anaphylaxis to omeprazole. *J Allergy Clin Immunol* 1966; 97: 1413-1414.
7. Haeney MR. Angio-oedema and urticaria associated with omeprazole. *Br Med J* 1992; 305: 870.
8. Bowlby HA, Dickens GR. Angioedema and urticaria associated with omeprazole confirmed by drug rechallenge. *Pharmacotherapy* 1994; 14: 119-122.
9. Galindo PA, Borja J, Feo F, Gomez E, et al. Anaphylaxis to omeprazole. *Ann Allergy Asthma Immunol* 1999; 82: 52-54.
10. Confino-Cohen R, Goldberg A. Anaphylaxis to omeprazole:

- diagnosis and desensitization protocol. *Ann Allergy Asthma Immunol* 2006; 96:33-36.
11. Perez RF, de los Rios IL, Rodrigues E. Lansoprazole and glottis edema. *Am J Gastroenterol* 1999; 94: 1995.
  12. Parcel S, Rodriguez A, Jimenez S, Alvarado M, Hernandez J. Allergy to lansoprazole: study of cross-reactivity among proton pump inhibitors. *Allergy* 2005;60: 1987-1988.
  13. Pimiento AJP, Lastra LP, Cabrerios MIR, Sanchez LAG. Hypersensitivity to lansoprazole and rabeprazole with tolerance to other proton pump inhibitors. *J Allergy Clin Immunol* 2006; 117: 707-708.
  14. Demirkan K, Bozkurt B, Karakaya G, Kalyoncu AF. Anaphylactic reaction to drugs commonly used for gastrointestinal system diseases: 3 case reports and review of the literature. *J Invest Allergol Clin Immunol* 2006; 16: 203-209.
  15. Fardet L, Izzedine H, Ciroldi M, Tiev KP, Cabane J. Pantoprazole-induced recurrent anaphylactic shock. *Am J Gastroenterol* 2002; 97: 1578-1579.
  16. Kollmeier AP, Eddleston J, Zuraw BL, Christiansen SC. Recurrent anaphylaxis linked to pantoprazole. *J Allergy Clin Immunol* 2004; 114: 975-977.
  17. Kaatz M, Bauer A, Hipler C, Elsner P. Nonallergic anaphylaxis to pantoprazole. *Allergy* 2000; 55: 184.
  18. Kounis NG, Hahalis G, Theoharides TC. Coronary stents, hypersensitivity, and the Kounis syndrome. *J Interven Cardiol* 2007; 20: 314-323.