

**CASE REPORT**

# Torsade de Pointes Related to the Co-administration of Amiodarone and Digoxin

Stavros P. Kounas, MD, Konstantinos P. Letsas, MD,  
Loukas K. Pappas, MD, Gerasimos Gavrielatos, MD,  
Michalis Efremidis, MD, Antonios Sideris, MD, Fotios Kardaras, MD

*Second Department of Cardiology,  
Evangelismos General Hospital of  
Athens, Athens, Greece*

**KEY WORDS:** *Torsade de pointes,  
digoxin, amiodarone*

**ABSTRACT**

A case of acquired long QT syndrome and subsequent torsade de pointes related to the co-administration of amiodarone and digoxin is described in the present case report. The underlying electrophysiologic mechanism of this proarrhythmic event is discussed.

**INTRODUCTION**

Acquired QT interval prolongation and the following propensity towards torsade de pointes (TdP) have been attributed to a variety of situations, among which the proarrhythmic action of many antiarrhythmic agents. The proarrhythmic action of amiodarone is considered to be low since its multiple electrophysiologic properties contribute to a remarkable electrical homogeneity.<sup>1</sup> The co-administration of drugs with destabilizing properties and the role of predisposing factors are discussed in the case of a patient manifesting TdP episodes while being on amiodarone therapy for atrial fibrillation prevention.

**CASE REPORT**

A 67-year old woman with a history of mild aortic valve regurgitation and paroxysmal atrial fibrillation, first discovered after a mild stroke, presented to the emergency department of our hospital reporting syncope while undergoing her everyday house keeping. She was on digoxin, amiodarone, warfarin and amiloride for the last 2 years. The ECG on admission demonstrated sinus node bradycardia (49 beats/min) with a QT interval of 760 ms and a corrected QT (QTc) interval of 690 ms (Figure 1). Serum electrolytes and biochemical markers for myocardial damage were normal. The serum digoxin levels of 1.26 ng/ml (therapeutic concentration 1-2 ng/ml) and INR levels of 3.01 were considered within the therapeutic range. Transthoracic echocardiography revealed no structural or functional abnormalities apart from the known mild aortic regurgitation. Chest X-ray was normal. Brain CT scan demonstrated an old cerebral infarct. The patient was initially evaluated by an internist to exclude other treatable

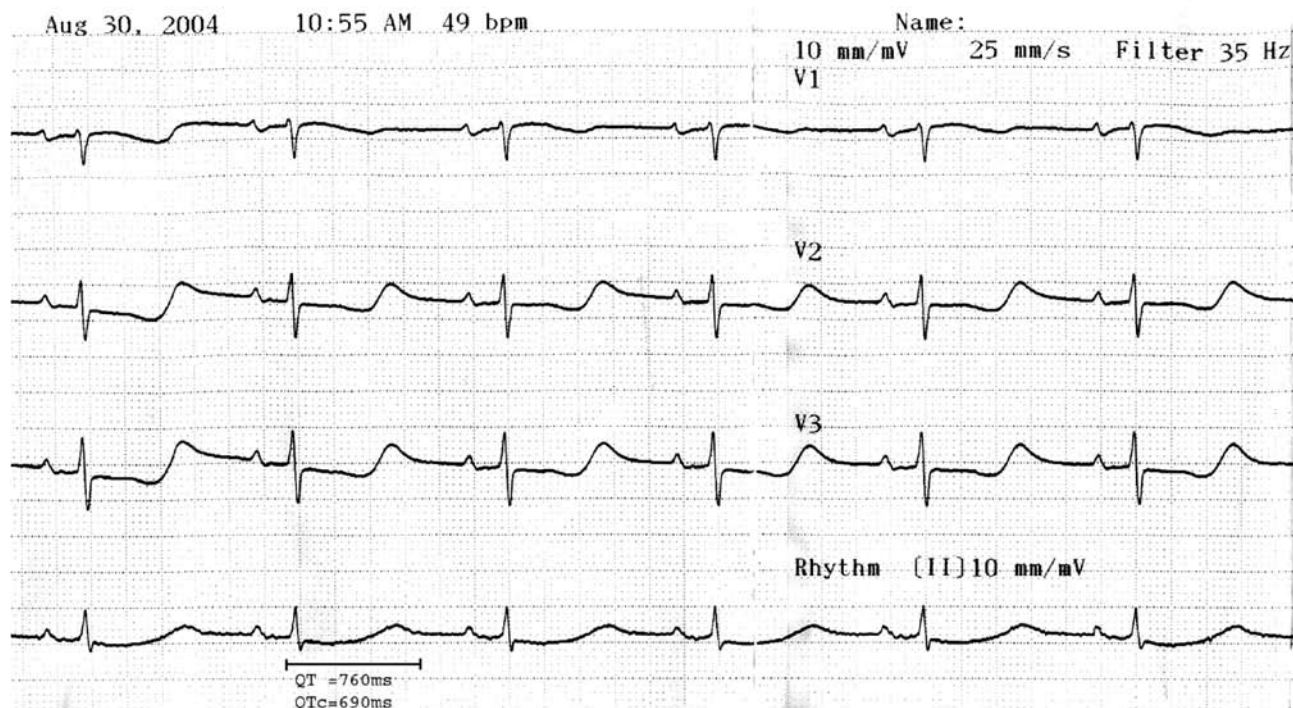
*Address for correspondence:*

Konstantinos P. Letsas, MD,  
Second Department of Cardiology,  
Evangelismos General Hospital of  
Athens,  
45-47, Ipsilantou St., 10676 Athens,  
Greece  
Tel: +302107201468  
Fax: +302107217687  
e-mail: k.letsas@mail.gr

*Manuscript received March 28, 2009;*

*Revised manuscript received  
October 13, 2009;*

*Accepted October 14, 2009*



**Figure 1.** ECG on admission showing a markedly prolonged QTc interval (690 ms).

causes of syncope, and then was transferred to the intermediate care unit for further monitoring. All her medications were discontinued apart from warfarin.

During the first 24-hour ambulatory monitoring period multiple self-terminated episodes of TdP preceded by the characteristic short-long-short cardiac cycle sequences were recorded (Figure 2), while the patient remained asymptomatic. The minimum heart rate was as low as 30 beats/min with frequent ventricular ectopic beats (VE) (850/24h). During the ensuing days ventricular ectopy gradually decreased significantly and no TdP episodes were recorded. On the fourth day the minimum heart rate was 49 bpm with 3 VE/24h. The digoxin levels were low (0.49 ng/ml) but the remaining action of amiodarone (serum levels of 3.1 mg/ml, therapeutic levels 1-3 mg/ml), due to its long half time clearance,<sup>2</sup> retained the QTc interval abnormal (520 ms).

The patient during her hospital stay did not experience any syncopal or presyncopal symptoms. However, on the sixth day the occurrence of disturbing palpitations due to a paroxysm of atrial fibrillation necessitated the use of amiodarone and the implantation of a DDDR pacemaker to avoid extreme bradycardia. She was discharged home on amiodarone and warfarin therapy and has remained under regular follow-up for her pacemaker without complaining of any symptoms.

## DISCUSSION

Torsade de pointes characterizes the adverse proarrhythmic effects of agents that prolong myocardial repolarization, specifically class III antiarrhythmics.<sup>2</sup> The exact mechanism is not completely defined but it seems that two electrophysiological phenomena play a major role in the pathogenesis including the early afterdepolarization (EAD)-induced triggered activity and the development or enhancement of repolarization heterogeneity between adjacent myocardial segments. It has been assumed that the prolongation of repolarization offers the functional reentry substrate while the genesis of extrasystoles is the firing event for the development of multiform ventricular tachycardia.<sup>3</sup> A "short-long-short" sequence precedes the onset of TdP in most cases.<sup>4</sup> A ventricular extrasystole is followed by a post-extrasystolic pause, and the subsequent sinus beat may have an especially long QT and/or deformities of T or U waves. A new ventricular extrasystole then falls on the exaggerated T or U wave of the sinus beat (vulnerable period) and precipitates the onset of TdP.<sup>5</sup>

In contrast to other anti-arrhythmic agents, amiodarone is associated with the least proarrhythmic risk. The largest published review of 17 studies including more than 2800 patients under amiodarone exhibited a low percentage of proarrhythmia justifying the long held opinion about its safety profile. Having

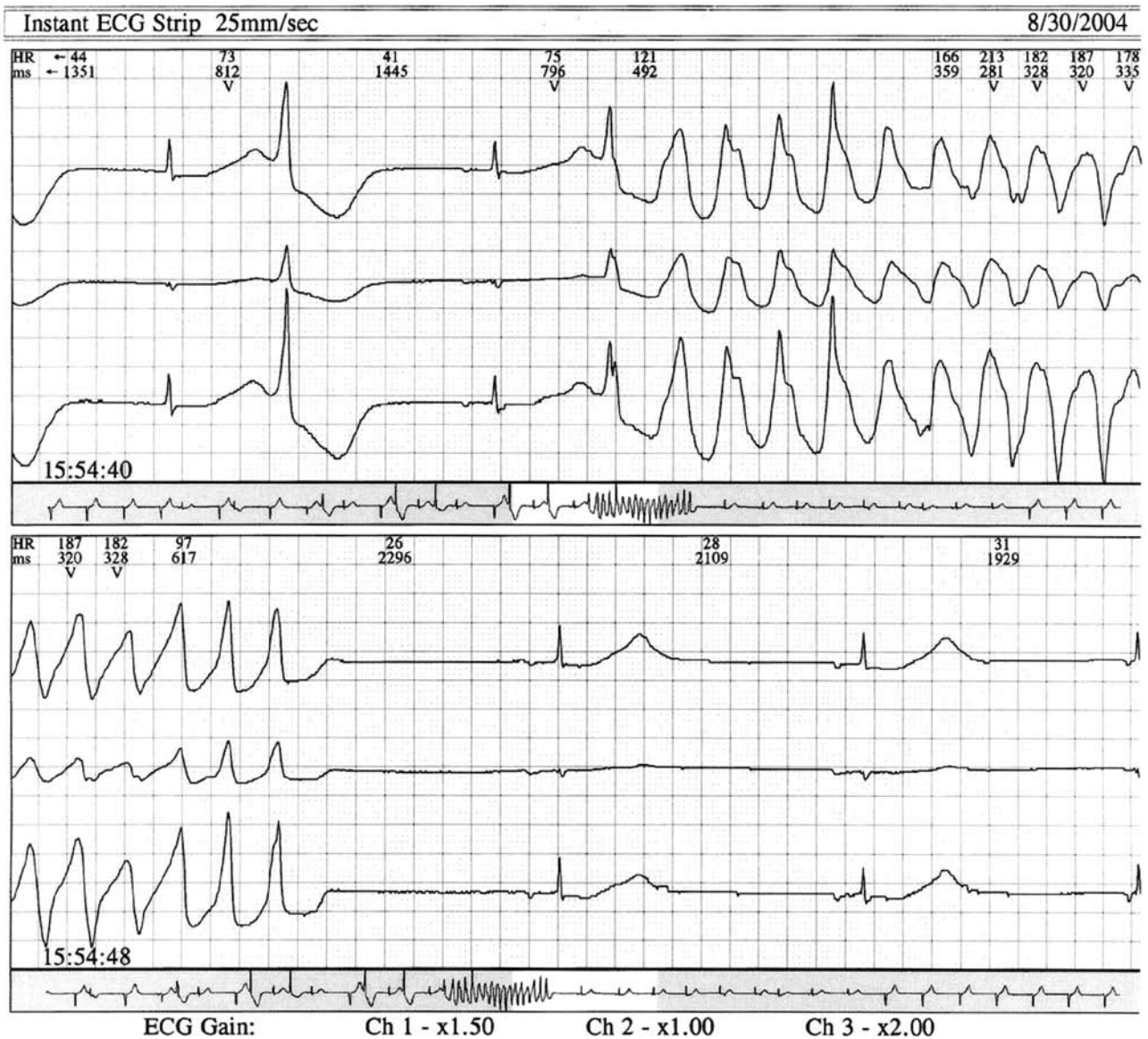

Figure 2: Self-terminated episodes of TdP preceded by the characteristic short-long-short sequence.

a less than 1% (0.7%) TdP, amiodarone is reasonably considered one of the safest antiarrhythmic options for supraventricular arrhythmia prevention in ischaemic or structural cardiomyopathies, specially knowing the unfavourable effect of other anti-arrhythmic drugs in patients with underlying structural heart disease (CAST, SWORD studies).<sup>6</sup>

Aside from decreasing the slow and rapid component of the repolarizing potassium current ( $I_{Ks}$ - $I_{Kr}$ ),<sup>7</sup> amiodarone also inactivates sodium channels,<sup>8</sup> and the L-type (long-lasting) calcium channels,<sup>9</sup> actions that inhibit the development of EADs. Also it has been clinically proven that amiodarone has minimal effects on ventricular repolarization heterogeneity,

as expressed by QT dispersion measurements.<sup>10</sup>

Although in the literature there have been described cases of TdP related to amiodarone, in the majority of those the presence of a number of predisposing factors known to prolong QT interval is reported, like female gender, hypokalaemia and concomitant drug use.<sup>8</sup> Females are at increased risk of TdP development.<sup>11</sup> It has been estimated that approximately 70% of cases of drug-induced TdP occur in females.<sup>12</sup> A reduced cardiac repolarization reserve closely related to sex steroids has been proposed to explain the increased propensity of women to develop drug-induced TdP.<sup>13</sup> Although amiodarone carries a low potential for producing TdP compared with sotalol and

dofetilide, the prevalence of TdP in women is at least twice that in men for all these drugs.<sup>14</sup> However, not even one case of proarrhythmia could be demonstrated in a cohort of 674 patients on amiodarone monotherapy in placebo controlled studies.<sup>8</sup> It is remarkable also that amiodarone has been given safely in drug-induced TdP, without arrhythmia recurrence despite the QT interval prolongation.<sup>15</sup> A prolonged QT interval is not enough for the development of TdP in the absence of the triggering effect of EADs.<sup>16</sup>

In the present case it was assumed that the co-administration of digoxin, combined with the slow heart rate, precipitated the TdP manifestation providing the substrate of prolonged ventricular repolarization caused by amiodarone. The proarrhythmic combination of digoxin and amiodarone has been described in previous cases.<sup>17</sup> Digoxin by blocking the Na/K pump indirectly enhances the Na/Ca exchanger function, which in combination to its bradycardic properties, leads to intracellular calcium accumulation and EADs.<sup>18,19</sup> In our patient the cessation of digoxin, followed by a drop of its serum levels from 1.26 ng/ml to 0.49 ng/ml, was associated with a heart rate increment with disappearance of ventricular extrasystoles and TdP episodes despite the remaining QT prolongation. This observation conforms to the concerns about the real therapeutic digoxin levels since post hoc analysis data from the DIG trial imply that levels of 0.9 ng/mL should be considered safer.<sup>20</sup>

In **conclusion**, patients receiving amiodarone are regarded to have a very low probability of developing TdP. However, the presence of other predisposing factors can increase the proarrhythmic risk. Other drugs, especially those with bradycardic actions, like digoxin, are capable of precipitating a sudden arrhythmic event, and for that reason their concomitant use should be considered with caution.

## REFERENCES

- Hohnloser SH. Proarrhythmia with class III antiarrhythmic drugs: types, risks, and management. *Am J Cardiol* 1997; 80:82-89.
- Pollak PT, Bouillon T, Shafer SL. Population pharmacokinetics of long-term oral amiodarone therapy. *Clin Pharmacol Ther* 2000; 67:642-652.
- El-Sherif N, Chinushi M, Caref EB, Restivo M. Electrophysiological mechanism of the characteristic electrocardiographic morphology of torsade de pointes tachyarrhythmias in the long-QT syndrome: detailed analysis of ventricular tridimensional activation patterns. *Circulation* 1997; 96:4392-4399.
- Kay GN, Plumb VJ, Arciniegas JG, Henthorn RW, Waldo AL. Torsade de pointes: the long-short initiating sequence and other clinical features: observations in 32 patients. *J Am Coll Cardiol* 1983; 2:806-817.
- Yap YG, Camm AJ. Drug induced QT prolongation and torsades de pointes. *Heart* 2003; 89:1363-1372.
- Hohnloser SH, Klingenhoben T, Singh BN. Amiodarone-associated proarrhythmic effects. A review with special reference to torsade de pointes tachycardia. *Ann Intern Med* 1994;121:529-535.
- Colatsky TJ, Follmer CH, Starmer CF. Channel specificity in antiarrhythmic action. Mechanism of potassium channel block and its role in suppressing and aggravating cardiac arrhythmias. *Circulation* 1990;82:2235-2242.
- Mason JW, Hondeghem LA, Katzung BG. Amiodarone blocks inactivated cardiac sodium channels. *Pflugers Arch* 1983; 396:79-85.
- Nattel S, Talajic M, Quantz M, DeRoode M. Frequency-dependent effects of amiodarone on atrioventricular nodal function and slow-channel action potentials: evidence for calcium channel blocking activity. *Circulation* 1987; 76:442-449.
- Meierhenrich R, Helguera ME, Kidwell GA, Tebbe U. Influence of amiodarone on QT dispersion in patients with life-threatening ventricular arrhythmias and clinical outcome. *Int J Cardiol* 1997;60:289-294.
- Letsas KP, Efremidis M, Kounas SP, et al. Clinical characteristics of patients with drug-induced QT interval prolongation and torsade de pointes: identification of risk factors. *Clin Res Cardiol* 2009; 98:208-212.
- Zeltser D, Justo D, Halkin A, Prokhorov V, Heller K, Viskin S. Torsade de pointes due to noncardiac drugs: most patients have easily identifiable risk factors. *Medicine (Baltimore)* 2003; 82:282-290.
- Arya A. Gender-related differences in ventricular repolarization: beyond gonadal steroids. *J Cardiovasc Electrophysiol* 2005; 16:525-527
- Wolbrette DL. Risk of proarrhythmia with class III antiarrhythmic agents: sex-based differences and other issues. *Am J Cardiol* 2003; 91:39-44.
- Mattioni TA, Zheutlin TA, Sarmiento JJ, Parker M, Lesch M, Kehoe RF. Amiodarone in patients with previous drug-mediated torsade de pointes. Long-term safety and efficacy. *Ann Intern Med.* 1989; 111:574-80.
- van Opstal JM, Schoenmakers M, Verduyn SC, et al. Chronic amiodarone evokes no torsade de pointes arrhythmias despite QT lengthening in an animal model of acquired long-QT syndrome. *Circulation* 2001; 104:2722-2727.
- Bajaj BP, Baig MW, Perrins EJ. Amiodarone-induced torsades de pointes: the possible facilitatory role of digoxin. *Int J Cardiol* 1991; 33:335-337.
- Levi AJ, Dalton GR, Hancox JC et al. Role of intracellular sodium overload in the genesis of cardiac arrhythmias. *J Cardiovasc Electrophysiol* 1997; 8:700-721.
- January CT, Riddle JM. Early afterdepolarizations: mechanism of induction and block. *Circ Res* 1989; 64:977-990.
- Ahmed A, Rich MW, Love TE et al. Digoxin and reduction in mortality and hospitalization in heart failure: a comprehensive post hoc analysis of the DIG trial. *Eur Heart J* 2006; 27:178-186.