

**CASE REPORT**

# Generalised Pustular Psoriasis (von Zumbusch type) following renal Transplantation. Report of a case and review of the literature

Vougas V<sup>1</sup>, Dedemadi G<sup>1</sup>, Noutsis K<sup>2</sup>, Apostolou Th<sup>1</sup>,  
Pantelidaki C<sup>3</sup>, Drakopoulos S<sup>1</sup>

<sup>1</sup>Transplant Unit, “Evangelismos”  
Hospital, Athens, Greece

<sup>2</sup>Department of Dermatology,  
“Evangelismos” Hospital, Athens,  
Greece

<sup>3</sup>Department of Pathology,  
“Evangelismos” Hospital, Athens,  
Greece

**KEY WORDS:** Renal transplantation,  
Pustular psoriasis, Cyclosporine A,  
Methotrexate

**ABSTRACT**

Generalized pustular psoriasis appears as an uncommon variant form of psoriasis consisting of widespread pustules on an erythematous background (von Zumbusch). A 39-year-old male patient with a history of plaque psoriasis since the age of nine who had an acute onset of generalized pustular psoriasis twelve days after he underwent renal transplantation is presented. Despite administered immunosuppression for transplantation, the addition of cyclosporine A and methotrexate did not reverse the ongoing process of disease and the patient died on the 57<sup>th</sup> post-transplant day due to multiorgan failure following severe bone marrow suppression.

**INTRODUCTION**

Generalized pustular psoriasis is an uncommon skin disease with resistance to medical treatment causing diagnostic pitfalls. Patients suffering from the disease are presented with an extensive area of erythematous background and multiple small pustules. Severity of disease and response to medical treatment can vary [1]. The activation of T-lymphocytes and tumour necrosis factor alpha (TNF- $\alpha$ ) determines the type and severity of manifestation [2]. Acute generalized type (von Zumbusch variant) is associated with fever and toxicity.

The disease is unusual in Great Britain, while the prevalence in Japan is 7.46 per million of population. Both genders are affected equally. Etiology has not been completely clarified. Although many factors can be considered as triggering eruption of disease, the most important seems to be a sudden withdrawal of steroids after systematic use and drugs including salicylates, lithium, and penicillin. Other factors such as infections of the upper respiratory system, pregnancy, exposure to sunlight, phototherapy, jaundice, hypocalcemia, and hypoparathyroidism have also been incriminated [2]. Generalized pustular psoriasis rarely appears in patients after organ transplantation, with the exception of only two cases so far reported in the literature [3,4].

*Address for correspondence:*

Dedemadi G.  
37 Vlahernon Street,  
153 51 Pallini,  
Attiki - Greece  
Tel.: +302107201741  
e-mail: gdedemadi@yahoo.gr

*Submitted:* 02-07-07,

*Revised:* 08-10-07,

*Accepted:* 15-10-07

**CASE REPORT**

The case of a 39-year-old male patient with a 20-year history of chronic kidney

disease of unknown etiology, on regular hemodialysis for the last nine years is presented. The patient suffered from tetralogy of Fallot treated successfully with surgery at the age of eight. In 1993, after a transient episode of collapse, a pacemaker was implanted because of a sinoventricular block. In 2001, he had a mild cerebrovascular attack which resulted in minor left sided hemiplegia. A history of allergy to non-steroidal anti-inflammatory drugs and vancomycin was reported. Since childhood, he suffered from mild psoriasis receiving local corticosteroids and moisturizers. Skin lesions had seasonal accentuation with aggravation in spring and remission during summer. Being on the waiting list for a renal transplant, he underwent total thyroidectomy and parathyroidectomy due to multinodular goiter and hyperparathyroidism.

A cadaveric renal transplantation was performed in April 2006, using a HLA A<sub>2</sub> and DR<sub>14</sub> compatible (4 mismatches) graft. The patient received induction treatment with Daclizumab (1mg/kg/day) and a triple immunosuppressive regimen with Tacrolimus (0.1mg/kg/day), Mycophenolate Mofetil (2gr/day), and methylprednisolone according to protocol (1gr IV during surgery followed by prednisolone of 200 mg on the 1st postoperative day, which was tapered to oral prednisolone of 20 mg/day within 2 weeks and to 10mg/day within a month). Beside immunosuppression, the patient continued on cefotaxime, ciprofloxacin, erythropoietin, protein pump inhibitors, and furosemide during his postoperative course.

Due to delayed graft function he remained on hemodialysis. On the 6<sup>th</sup> postoperative day, he developed trunk erythematous lesions and local corticoid treatment (Fluticasone) was applied (Picture 1). Twelve days postoperatively, skin lesions aggravated, expanding to the whole trunk and extremities while multiple clusters of nonfollicular, superficial 2 to 3mm pustules appeared (Picture 2). A gram staining and pus culture from pustules did not reveal any microorganisms. After reducing prednisolone to 10mg/day, on the 30<sup>th</sup> postoperative day, the patient ex-

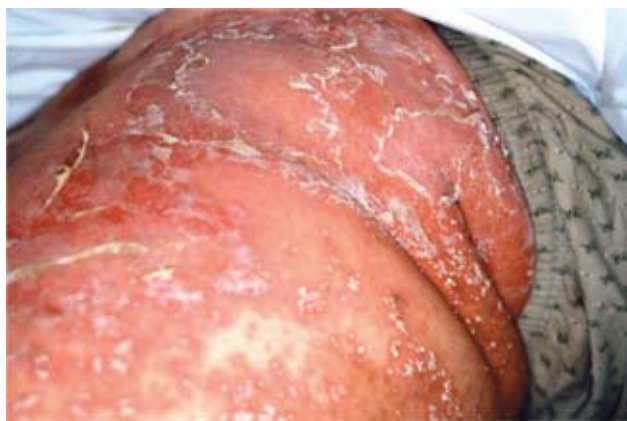hibited a dramatic deterioration of skin lesions, consisting of a widespread and generalized body pustular exanthema. A skin biopsy revealed pustular psoriasis of the von Zumbusch variant, with eosinophilic infiltrate indicative of drug toxicity (Picture 3 and 4). Renal graft biopsy confirmed signs of acute rejection, treated with methylprednisolone, 500mg for 3 days. On the 37<sup>th</sup> postoperative day, the patient became toxic with increasing pyrexia and reduced urinary output. Mycophenolate Mofetil and Daclizumab were discontinued; Tacrolimus was substituted by Cyclosporine A (3.0mg/kg/day), with an increase of steroids to 30mg/day. As skin lesions were extending to the whole body surface, becoming life threatening, 50mg of methotrexate were administered on days 39 and 46 postoperatively. The patient developed sepsis, a body temperature of 39.5 °C, pancytopenia (WBC: 0.320×10<sup>3</sup>/nl, Hct: 25.1%, Hb: 8.4g/dl, PLT: 29×10<sup>3</sup>/nl), signs of disseminated intravascular coagulation, oliguria (400ml/day), and respiratory distress. Red blood cells and platelets transfusions as well as glycosylated recombinant form of human granulocyte colony stimulating factor r-HuG-CSF were also added. On the 57<sup>th</sup> postoperative day, the patient died from multi-organ failure.

---

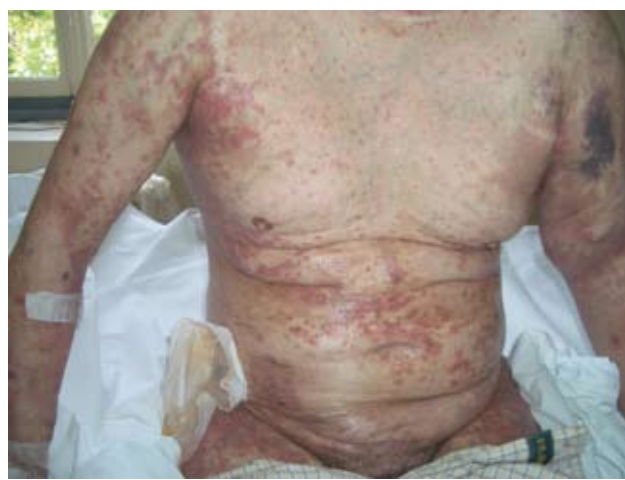## DISCUSSION

---

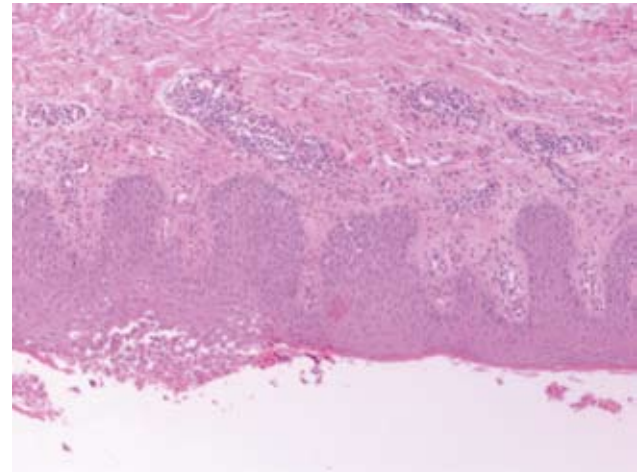
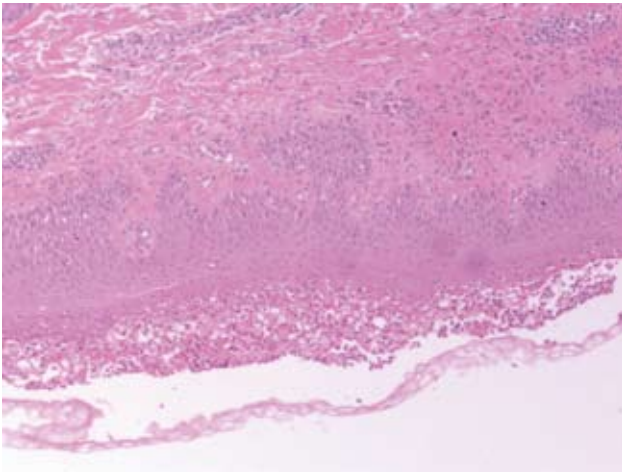
Psoriasis is a chronic, inflammatory skin disease affecting approximately 2% of Caucasians, but it is rare among Japanese, Eskimos, West Africans, and North American blacks and very uncommon in North American and South American natives. The cause for these variations is likely to be both genetic and environmental [5]. There is a considerable epidemiologic verification that genetic factors determine the pathogenesis of psoriasis. The disease is multifactorial in origin and has a



PICTURE 1. Generalized eruption with multiple small pustules.



PICTURE 2. Generalized pustular psoriasis of the body and upper extremities.



PICTURE 3 & PICTURE 4. Psoriasis. Psoriasiform epidermal hyperplasia with spongiform pustules of Kogoj. H.E. X 200.

multigenetic inheritance [6].

Pustular psoriasis is an uncommon variant of psoriasis and may be classified into several types depending on the clinical course: acute, subacute or chronic. The acute type (von Zumbusch variant) occurs with erythematous lesions producing burning sensation and may be associated with upper respiratory system or other systemic infections. High temperature appears suddenly with shiver and chills. The patient experiences constitutional signs and symptoms. Formation of multiple small pustules on an erythematous background occurs in a generalized pattern. In the acute type, the pustules often become confluent to form lakes of pus [7]. Sometimes the disease is followed by pulmonary capillary leakage, pulmonary emphysema, jaundice, or renal failure due to hypoproteinemia and hypocalcaemia [8]. In the more common subacute and chronic types, the patients appear to have only skin symptoms [9].

No radical treatment is available so far, therefore, aim of treatment is improvement of patient's quality of life [10]. Lately many authors have mentioned the benefit of calcineurin inhibitors to treat psoriasis [11-13]. Cyclosporine A inhibits T- lymphocytes and affects the function of phospholipase A and the activation of interleukin 1 and 2, via its action against calcineurin, factors determinant for psoriasis [1,14]. There is strong evidence to support administration of Cyclosporine A which is considered the most effective and safe drug for treating severe psoriasis [15]. Some authors report a relapse of disease after withdrawal of Cyclosporine A [16-18].

Medical treatment with retinoids includes natural retinoids, vitamin A, and its active derivatives. The mechanism of action of retinoids in psoriasis is not completely understood. It has been considered that retinoids contribute to improvement of symptoms by normalizing keratinisation and proliferation of epidermal cells. They also control the production of cytokines

(TNF $\alpha$ , IL-1 and IL-6) [19,20].

Methotrexate has also been proposed as a treatment of severe psoriasis. It inhibits the differentiation and proliferation of epidermis. It affects the immune system by inhibiting macrophages and neutrophils, as well as T and B lymphocytes [21]. Due to numerous side effects and toxicity, methotrexate should be used cautiously especially in patients with renal failure [22]. In our patient, methotrexate administration was necessary, despite delayed graft function, due to deterioration of skin disease and the above mentioned given treatment was ineffective. Whether sepsis and multiorgan failure was related to pustular psoriasis per se or to over-immunosuppression, this was not elucidated upon.

A novel concept in the treatment of pustular psoriasis may be biologic therapies, using anti-TNF-alpha agents, designed to selectively interfere with the immune mechanisms that induce psoriasis. TNF-alpha antibodies (infliximab) and TNF-alpha receptors (etanercept) combine a rapid onset of action in the initiation therapy with a lower risk for severe adverse events [23,24]. The long term safety of all these agents has not yet been established.

Other anti-inflammatory and immunosuppressive drugs, such as corticosteroids, are used for pustular psoriasis, particularly early on in the acute stage. Reduction or withdrawal of corticosteroids may lead to relapse of disease [10]. They could be administered in combination with retinoids (Acitretin), Cyclosporine A, or Methotrexate during the acute stage.

Local treatment includes corticosteroid compounds and products of vitamin D3.

All these alternatives can be used for treating pustular psoriasis either alone or in combination. While standard systemic therapy is effective in the short term, unpredictable toxicity and gradual decline in efficacy could complicate a long term use. Rotating or combining different treatment modalities



mitigates against these problems, but for a significant group of patients with severe disease adequate control is impossible or achieved only with actual or high risk of drug toxicity and consequent morbidity. It is remarkable that in our case, Cyclosporine A, an immunosuppressive agent, drug of choice for transplantation and main treatment for psoriasis was not able to prevent rapid ongoing process of disease. Very good results are reported after administration of combined therapy including Cyclosporine A and Methotrexate in twenty patients with severe psoriasis without renal disease [25].

The literature provides data on the incidence of patients with severe psoriasis and chronic renal failure as well as the potential beneficial outcome after hemodialysis or peritoneal dialysis [26, 27], but such an improvement was not noticed in our patient.

Pustular psoriasis is a rare disease among patients undergoing transplantation, with only two reports in the literature. The first concerns a patient with generalized pustular psoriasis after renal transplantation that was treated with combination therapy including cyclosporine A and low dose methotrexate, while the recent report represents azathioprine as an alternative treatment for resistant psoriasis along with phototherapy and cyclosporine [3,4]. European guidelines for renal transplantation reported by the EBPG Expert Group in 2000 do not include psoriasis in the exclusion criteria [28]. With only two cases reported so far, as well as ours with a dismal prognosis, it is difficult to draw definite conclusions about whether patients with a history of psoriasis and chronic renal failure should be listed for transplantation.

## REFERENCES

- Berth-Jones J. The use of ciclosporin in psoriasis. *J Dermatolog Treat* 2005; 16:258-277.
- Ohkawara A, Yasuda H, Kobayashi H, Inaba Y, et al. Generalized pustular psoriasis in Japan; two distinct groups formed by differences in symptoms and genetic background. *Acta Derm Venereol* 1996; 76:68-71.
- Coulson IH, Evans CD, Holden CA. Generalized pustular psoriasis after renal transplantation--failure to suppress with cyclosporin A. *Clin Exp Dermatol* 1988; 13:416-417.
- Kaaroud H, Béji S, Jebali A, Ben Hamida F, et al. Pustular psoriasis after renal transplantation. *Transplant Proc* 2007; 39:1130-1131.
- Giardina E, Sinibaldi C, Novelli G. Mapping the future of common diseases: lessons from psoriasis. *Front Biosci* 2007; 12:1563-1573.
- Pasic A, Grahovac B, Lipozencic J, Kastelan M, et al. The genetics of psoriasis. *Acta Dermatovenereol Croat* 2004; 12:18-25.
- Zelickson BD, Muller SA. Generalized pustular psoriasis. A review of 63 cases. *Arch Dermatol* 1991; 127:1339-1345.
- Sadeh JS, Rudikoff D, Gordon ML, Bowden J, et al. Pustular and erythrodermic psoriasis complicated by acute respiratory distress syndrome. *Arch Dermatol* 1997; 133:747-750.
- Baker H (1985) Generalized pustular psoriasis. In: Roenigk HH Jr, Maibach HI (eds). Psoriasis. Marcel Dekker, New York, 1985:15-33.
- Umezawa Y, Ozawa A, Kawasima T, Shimizu H, et al. Therapeutic guidelines for the treatment of generalized pustular psoriasis (GPP) based on a proposed classification of disease severity. *Arch Dermatol Res* 2003; 295:Suppl:S43-54.
- Sarzi-Puttini P, Cazzola M, Panni B, Turiel M, et al. Long-term safety and efficacy of low-dose cyclosporin A in severe psoriatic arthritis. *Rheumatol Int* 2002; 21: 234-238.
- De Ric MA, Meinardi MM, Bos JD. Analysis of side-effects of medium- and low-dose cyclosporin maintenance therapy in psoriasis. *Br J Dermatol* 1990; 123:347-353.
- Christophers E, Mrowietz U, Henneicke HH, Farber L, et al. Cyclosporine in psoriasis: a multicenter dose-finding study in severe plaque psoriasis. The German Multicenter Study. *J Am Acad Dermatol* 1992; 26:86-90.
- Bunjes D, Hardt C, Rollinghoff M, Wagner H. Cyclosporin A mediates immunosuppression of primary cytotoxic T cell responses by impairing the release of interleukin 1 and interleukin 2. *Eur J Immunol* 1981; 11:657-661.
- Berth-Jones J, Henderson CA, Munro CS, Rogers S, et al. Treatment of psoriasis with intermittent short course cyclosporin (Neoral). A multicenter study. *Br J Dermatol* 1997; 136: 527-530.
- Mahendran R, Grech C. Generalized pustular psoriasis following a short course of cyclosporin (Neoral) *Br J Dermatol* 1998; 139:934.
- Ho VC, Griffiths CE, Albrecht G, Vanaclocha F, et al. Intermittent short courses of cyclosporin (Neoral(R)) for psoriasis unresponsive to topical therapy: a 1-year multicentre, randomized study. The PISCES Study Group. *Br J Dermatol* 1999; 141:283-291.
- Heidenheim M, Oxholm A, da Cunha Bang F. Generalized pustular psoriasis in relation to withdrawal of cyclosporin A. *Br J Dermatol* 1990; 122:719.
- van de Kerkhof PC. Update on retinoid therapy of psoriasis in: an update on the use of retinoids in dermatology. *Dermatol Ther* 2006; 19:252-263.
- Yamauchi PS, Rizk D, Lowe NJ. Retinoid therapy for psoriasis. *Dermatol Clin* 2004; 22:467-476.
- Boffa MJ, Chalmers RJ. Methotrexate for psoriasis. *Clin Exp Dermatol* 1996; 21:399-408.
- Boey O, Van Hooland S, Woestenburg A, Van der Niepen P, et al. Methotrexate should not be used for patients with end-stage kidney disease. *Acta Clin Belg* 2006; 61:166-169.
- Gisoni P, Girolomoni G. Biologic therapies in psoriasis: A new therapeutic approach. *Autoimmun Rev* 2007; 6:515-519. Epub 2007.
- Weisenseel P, Prinz JC. Sequential use of infliximab and etanercept in generalized pustular psoriasis. *Cutis* 2006; 78:197-199.
- Aydin F, Canturk T, Senturk N, Turanli AY. Methotrexate and ciclosporin combination for the treatment of severe psoriasis. *Clin Exp Dermatol* 2006; 31:520-524.
- Nissenson AR, Rapaport M, Gordon A, Narins RG. Hemodialysis

GENERALISED PUSTULAR PSORIASIS (VON ZUMBUSCH TYPE) FOLLOWING RENAL TRANSPLANTATION

- in the treatment of psoriasis. A controlled trial. *Ann Intern Med* 1979; 91:218-220.
27. Kramer P, Brunner FP, Brynger H, Chantler C, et al. Dialysis treatment and psoriasis in Europe. *Clin Nephrol* 1982; 18:62-68.
28. EBPG (European Expert Group on Renal Transplantation); European Renal Association (ERA-EDTA); European Society for Organ Transplantation (ESOT). European best practice guidelines for renal transplantation (Part 1) *Nephrol Dial Transplant* 2000; 15 Suppl 7:1-85.