

ARTIGO CIENTÍFICO

Evaluation of proliferative activity in oral squamous cell carcinoma by the AgNOR staining method

Avaliação da atividade proliferativa do carcinoma espinocelular pelo método AgNOR

ABSTRACT

Aim: the objective of this study was to evaluate the cellular proliferative activity of argyrophilic nucleolar organizer regions (AgNORs) in a series of oral squamous cell carcinoma (OSCC) cases and to correlate this activity with the histopathologic grade of the tumor defined by the World Health Organization (WHO).

Methodology: twenty cases of OSCC obtained from the Diagnostic Histopathology Service of UPF database were studied. Age, gender and ethnic origin of the patients and oral site affected by the tumor were obtained directly from the histopathologic reports. The AgNOR technique was used for histochemical analysis of the tumors.

Results: there was a predominance of OSCC in male patients in the sixth decade of life. The lip was the most affected oral site and WHO grade I was the predominant histologic grade. The mean number of NORs per nucleus in the sample was 2.00 (standard deviation: 0.58). Pearson's correlation test showed that the number of NORs in OSCC was directly correlated with histologic tumor grade ($p = 0.021$).

Conclusion: the AgNOR method was useful as a diagnostic tool and prognostic indicator of OSCC when combined with conventional histopathologic analysis.

Keywords: AgNOR; Cell Proliferation; Diagnostic; Squamous Cell Carcinoma; Treatment.

RESUMO

Objetivo: avaliar a atividade proliferativa celular das regiões organizadoras nucleolares (AgNORs) em uma série de casos de carcinoma espinocelular da cavidade bucal (CECB) e correlacionar esta atividade com o grau histológico do tumor, definida pela Organização Mundial da Saúde (OMS).

Metodologia: vinte casos de CECB estudados foram obtidos a partir de diagnóstico do Serviço de Diagnóstico Histopatológico da UPF. Dados relativos à idade, sexo e origem étnica dos pacientes, além da localização da lesão na cavidade bucal, foram obtidos a partir dos relatórios histopatológicos. A técnica de AgNOR foi utilizada para análise histoquímica dos tumores.

Resultados: houve predomínio de CECB em pacientes do sexo masculino na sexta década de vida. O lábio foi o local mais afetado e o grau histológico I foi o predominante. O número médio de NORs por núcleo na amostra foi de 2,00 (desvio padrão: 0,58). O teste de correlação de Pearson mostrou que o número de NORs no CECB foi diretamente correlacionado com o grau histológico do tumor ($p = 0,021$).

Conclusão: o método AgNOR foi útil como uma ferramenta de diagnóstico e indicador de prognóstico do CECB, quando combinado com a análise histopatológica convencional.

Palavras-chave: AgNOR; Proliferação Celular; Diagnóstico; Carcinoma Espinocelular; Tratamento.

Soliete Oliveira da Silva*
Kaleb Pretto Gatto**
João Paulo De Carli*
Paulo Henrique Couto Souza***
Carmen Silvia Busin**

* DDS, MS, PhD, School of Dentistry, University of Passo Fundo, Passo Fundo, RS, Brazil.

** DDS, MS, PhD, Institute of Biological Sciences, University of Passo Fundo, Passo Fundo, RS, Brazil.

*** DDS, MS, PhD, School of Dentistry, Pontifical Catholic University of Paraná, Curitiba, PR, Brazil.

Corresponding author:

João Paulo De Carli
Rua Bento Gonçalves, 967/204, 99010-010 - Passo Fundo/RS, Brazil.
E-mail:
joaostomatologia@yahoo.com.br

Enviado: 07/01/2011

Aceito: 21/02/2011

INTRODUCTION

It is difficult to establish the prognosis of patients with oral squamous cell carcinoma (OSCC) and most often it depends on an early and accurate diagnosis of this kind of cancer. Consequently, new diagnostic and prognostic methods of OSCC are necessary to guide the correct choice of the therapeutic modality for this disease¹.

Nucleolar organizer regions (NORs) are structures present inside the nucleolus of interphase cells and in acrocentric chromosome of the 13, 14, 15, 21 and 22 pairs from human cells in division process². Several studies have been demonstrated an association between the increased number of NORs and the higher tumor aggressiveness, considering that the median number of NORs per nucleus in malignant tumors is higher when compared to benign lesions, mainly in those cases presenting a malignant high-grade and poor prognosis³⁻⁹.

The silver staining technique for the detection of NORs (AgNOR) is used in histopathology because of its feasibility and low cost¹⁰. However, some studies evaluating neoplastic lesions with different characteristics by the AgNOR method have not found correlation between number of NORs and tumor behavior¹¹⁻¹², suggesting that NOR score is not a prognostic indicator of those lesions.

Therefore, the objective of the present study was to evaluate cellular proliferative activity of OSCC cases by argyrophilic nucleolar organizer regions (AgNORs) method and to correlate it with the histologic grade of this tumor defined by the World Health Organization (WHO).

MATERIAL AND METHODS

The study was approved by the Ethics Committee of the University of Passo Fundo (UPF), Passo Fundo, RS, Brazil (protocol 117/2008).

Twenty cases of OSCC diagnosed between 2000 and 2006 were randomly obtained from the Diagnostic Histopathology Service database, Institute of Biological Sciences, UPF. Age, gender and ethnic origin of the patients, as well as the affected oral site, were obtained from the histopathologic reports. Previously, all hematoxylin-eosin histological slides from either incisional or excisional biopsies were carefully reviewed by an oral pathologist in order to confirm the diagnosis.

After that, a retrospective histochemical study of the OSCC cases was performed. For this, 5- μ m sections were obtained from the 20 paraffin-embedded blocks and AgNOR staining was carried out according to the protocol described by Ploton *et al.*¹³. The number of NORs was determined in 200 nuclei of epithelial cells, randomly chosen, per tumor under immersion. Printed pictures of the different microscopic fields enlarged by 1000X of each OSCC, were obtained for this purpose. Only NORs present in truly dysplastic cells, which showed pleomorphism and hyperchromatism, identified during diagnostic confirmation of hematoxylin-eosin-stained lesions, were scored.

The results were analyzed by descriptive statistics of frequency and by the Pearson correlation test.

RESULTS

Among the 20 OSCC cases studied, there was a predominance of male patients ($n = 18$) in the sixth decade of life ($n = 10$). The lip was the most frequently affected site ($n = 6$) and WHO grade I was the predominant histologic grade found ($n = 10$) (Tab. 1).

Table 1. Epidemiological data, mean number of NORs per nucleus and WHO histologic grade of the 20 cases of oral squamous cell carcinoma studied.

| Case | Gender | Age (decade of life) | Anatomic location | Mean number of NORs/nucleus | Histologic grade (WHO) |
|------|--------|-------------------------|-------------------|--------------------------------|---------------------------|
| 1 | Male | 6th | Floor/tongue | 1.66 | I |
| 2 | Male | 6th | Lip | 1.22 | I |
| 3 | Male | 5th | Tongue | 2.66 | III |
| 4 | Male | NA | Cervical region | 2.73 | III |
| 5 | Male | 6th | Tongue/retromolar | 1.83 | III |
| 6 | Male | 8th | Lip | 1.54 | I |
| 7 | Male | 7th | Lip | 1.34 | I |
| 8 | Male | 7th | Lip | 1.31 | I |
| 9 | Male | 8th | Lip | 1.52 | I |
| 10 | Male | NA | Floor | 1.97 | I |
| 11 | Female | 7th | Tongue | 2.08 | I |
| 12 | Male | 6th | Floor | 1.48 | I |
| 13 | Male | 6th | Floor | 2.80 | II |
| 14 | Male | 6th | Floor | 2.54 | II |
| 15 | Male | 7th | Tongue | 3.12 | II |
| 16 | Male | 6th | Lip | 1.85 | I |
| 17 | Male | 5th | Floor | 2.65 | II |
| 18 | Female | 6th | Cheek mucosa | 2.17 | II |
| 19 | Male | 6th | Cheek mucosa | 2.68 | III |
| 20 | Male | 6th | Cheek mucosa | 2.88 | III |

NA = data not available in the patient record.

The mean number of NORs per nucleus in the sample was 2.00 (standard deviation: 0.58) (Fig. 1). The three cases with the largest number of NORs per nucleus involved the floor of the mouth, tongue and cheek mucosa of men in their sixth and seventh decades of life. Two of these tumors presented grade II and one grade III. Pearson's correlation test showed a direct association between the number of NORs in OSCC and histologic tumor grade ($p = 0.021$).

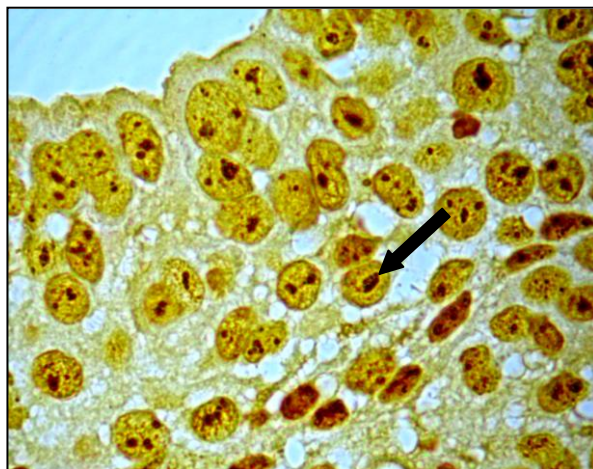


Figure 1. Histopathologic slide of an oral squamous cell carcinoma stained submitted to silver staining (AgNOR) showing NORs (black arrow) in the cell nucleus.

DISCUSSION

Considering the casuistic evaluated in the present research, we found that the prevalence of oral squamous cell carcinoma within 20 cases was 90% among men ($n = 18$). The mean number of NORs per nucleus was higher in women (2.12) than in men (2.09). These findings suggest that women might present a higher cellular proliferative activity of OSCC than men.

Male patients in their sixth decade of life were the most affected age group (50%). A larger mean number of NORs per nucleus was observed in the fifth decade of life (2.65), followed by the sixth decade (2.11), seventh decade (1.96), and eighth decade (1.53). These findings suggest that as much as younger the patient, higher is the proliferative activity of OSCC and, consequently, the aggressiveness of the tumor. The oral site most affected by OSCC was the lip. However, the mean number of NORs per nucleus, in decreasing order, was cervical region (2.73), cheek mucosa (2.58), tongue (2.27), floor of the mouth (2.18), retromolar region (1.83), and lip (1.46). Thus, OSCC in the cervical region presented the most aggressive behavior, whereas those affecting the lip presented the least aggressive behavior.

Pearson's correlation test showed a direct association ($p = 0.021$) between the number of NORs in OSCC and WHO histologic grade¹⁴. Similarly, this result is reported in other studies demonstrating an association between the increased number of NORs and the greater tumor aggressiveness³⁻⁹. Furthermore, Santo *et al.*⁵ showed that OSCC with 6 or more NORs per nucleus presents a more aggressive behavior and poorer prognosis than those with fewer NORs. In addition, Warnakulasuriya & Johnson⁸ studied the distribution of NORs as diagnostic markers of hyperkeratosis, dysplasia and OSCC and concluded that the number of NORs is a valuable prognostic marker for many malignant conditions, including OSCC.

In contrast to, Epivatianos *et al.*¹¹ investigated a possible correlation between anatomic location of the tumor and number of NOR in OSCC and did not observe any significant differences. These authors suggested that the number of NORs may not be a prognostic indicator of OSCC, as opposed to the results found in the present study. According to Vuhahula *et al.*¹⁵ there is a positive correlation between the number of NORs and the anatomic location of OSCC. In that study, most patients with tumors in the floor of the mouth, retromolar region and salivary glands presented an elevated number of NORs and a fatal prognosis, whereas only two of 10 patients with tumors involving the palate presented an elevated number of NORs and an unfavorable prognosis. In addition, Teixeira *et al.*⁷ reported that the expression of NORs is a good indicator of the recurrence-free interval and prognosis of OSCC, results that are somehow in accordance with the present findings.

One limitation of the present study is the fact that it was not possible to correlate the mean number of NORs/nucleus in OSCC with the clinical aggressiveness and prognosis of the tumor. Since the Diagnostic Histopathology Service of the Institute of Biological Sciences/UPF is only a diagnostic service, the dentists responsible for the biopsies refer the patients to other services for treatment. In relation to the application of the AgNOR technique, it is suitable and easy to be performed when the established protocol is followed. In the same way, Suto *et al.*¹⁰ stated that silver staining is an easy and low-cost method and is therefore widely used in histopathology studies.

The current findings show a correlation between proliferative activity and WHO histologic grade of the tumor and suggest that the AgNOR method may be useful as diagnostic tool and prognostic indicator of oral carcinomas in combination with conventional histopathologic analysis. However, this is a preliminary study and further investigations involving different samples are necessary to confirm and optimize the correlation established in the present study. For example, AgNOR might be combined with other histochemical or immunohistochemical markers as reported by, Teresa *et al.*¹⁶ who concluded that a combination of Ki-67 and AgNOR is effective in the determination of proliferative activity of oral carcinoma epithelial cells.

CONCLUSION

- The present investigation shows the potentiality of the AgNOR method as a reliable diagnostic tool and prognostic indicator of OSCC in combination with conventional histopathologic analysis, taking into account the histopathologic parameters proposed by the WHO.

REFERENCES

1. Bryne M. Is the invasive front of an oral carcinoma the most important area for prognostication? *Oral Dis* 1998; 4(2): 70-77.
2. Anastassova-Kristeva M. The nucleolar cycle in man. *J Cell Sci* 1977; 25: 103-110.

3. Freitas RA, Araujo VC, Araújo NS. Argyrophilia in nucleolar organizer regions (AgNORs) in adenoid cystic carcinoma and low-grade polymorphous adenocarcinoma of salivary gland. *Eur Arch Otorhinolaryngol* 1993; 250: 213-217.
4. Piffkò J, Bàngfalvi A, Ofner D, Bryne M, Rasch D, Joos U et al. Prognostic value of histobiologic factors (malignancy grading and AgNOR content) assessed at the invasive tumor front of oral squamous cell carcinomas. *Br J Cancer* 1997; 75(10): 1543-1546.
5. Sano K, Takahashi H, Fujita S, Inokuchi T, Pe MB, Okabe H, Tsuda N. Prognostic implication of silver-binding nucleolar organizer regions (AgNORs) in oral squamous cell carcinoma. *J Oral Pathol Med* 1991; 20(2): 53-56.
6. Schwint AE, Savino TM, Lanfranchi HE, Marschoff E, Cabrini RL, Itoiz ME. Nucleolar organizer regions in lining epithelium adjacent to squamous cell carcinoma of human oral mucosa. *Cancer* 1994; 73(11): 2674-2679.
7. Teixeira G, Antonangelo L, Kowalski L, Saldiva P, Ferraz A, Silva Filho G. Argyrophilic nucleolar organizer regions staining is useful in predicting recurrence-free interval in oral tongue and floor of mouth squamous cell carcinoma. *Am J Surg* 1996; 172(6): 684-688.
8. Warnakulasuriya KAAS, Johnson NW. Nucleolar organizer region (NOR) distribution as a diagnostic marker in oral keratosis, dysplasia and squamous cell carcinoma. *Oral Pathol Med* 1993; 22(2): 77-81.
9. Xie X, Clausen OP, Sudbö J, Boysen M. Diagnostic and prognostic value of nucleolar organizer regions in normal epithelium, dysplasia, and squamous cell carcinoma of the oral cavity. *Cancer* 1997; 79(11): 2200-2208.
10. Suto T, Sugai T, Nakamura S, Funato O, Nitta H, Sasaki R, et al. Assessment of the expression of p53, MIB-1 (Ki-67 antigen), argyrophilic nucleolar organizer regions in carcinoma of the extrahepatic bile duct. *Cancer* 1998; 82(1): 86-95.
11. Epivatianos A. Evaluation of nucleolar organizer region associated proteins in oral squamous cell carcinoma. *Ann Dent* 1994; 53(1): 33-36.
12. Pillai KR, Sujathan K, Kannan S, Abraham EK, Mathew B, Amma NS, et al. Argyrophilic nucleolar organizer regions in the evaluation of tumour progression in the oral mucosa: correlation with tissue pathology. *J Cancer Res Clin Oncol* 1994; 120(12): 723-726.
13. Ploton D, Menager M, Jeannesson P, Himber G, Pigeon F, Adnet JJ. Improvement in the staining and in the visualization of the argyrophilic proteins of the nucleolar organizer region of the optical level. *Histochem J* 1986; 8(1): 5-14.
14. Barnes L, Eveson JW, Reichart P. World Health Organization Classification of Tumours. Pathology and Genetics of Head and Neck Tumours. Lyon: IARC Press, 2005.
15. Vuhahula EAM, Nikai H, Ogawa I, Miyauchi M, Takata T, Ito H. Prognostic value of argyrophilic nucleolar organizer regions (AgNOR) count in adenoid cystic carcinoma of salivary glands. *Pathol Int* 1994; 44(5): 368-373.

16. Teresa DB, Neves KA, Neto CB, Fregonezi PAG, Oliveira MRB, Zuanon JAS, et al. Computer-assisted analysis of cell proliferation markers in oral lesions. *Acta Histochem* 2007; 109(5): 377-387.