

CASE REPORT

Vieussens' Arterial Ring Attenuates the Consequences of an Otherwise Large Anterior Myocardial Infarction

Emmanouil Poulidakis, MD, Konstantinos Triantafyllou, MD, Eleni Margioulas, MD, Evangellos Giannoulis, MD, Konstantinos Kappos, MD

Department of Cardiology, Evagelismos General Hospital of Athens, Athens, Greece

Running Title: **Vieussens' Ring**

Corresponding author: Emmanouil Poulidakis, MD, Evagelismos Hospital, Ipsilantou 45, Athens 106 76, Greece; Phone +30-6936980370; Fax +30-2132041495; e-mail: poylidakis@yahoo.com

Conflict of Interest: Nothing to disclose

Manuscript submitted September 4, 2016; Revised manuscript received and accepted November 1, 2016

Abstract

A 55-year-old patient, with a history of a recent ST-elevation myocardial infarction (STEMI) diagnosed elsewhere but not treated due to patient's refusal, was urgently admitted to our hospital with symptoms of post-infarction angina over the last 48 hours. The patient, who remained hemodynamically stable, underwent urgent coronary angiography via a transradial access. Total occlusion of the left anterior descending (LAD) coronary artery was visualized right after the first diagonal branch, while the periphery of the LAD was opacified through collaterals from the proximal right coronary artery (RCA), an anatomic variation also known as the Vieussens' ring. Decision was taken not to proceed with revascularization, until viability in the territory of the LAD could be documented. *Rhythmios 2016;11(4):98-99.*

Key Words: Vieussens' ring; myocardial infarction; coronary collaterals

List of Abbreviations

CAD = coronary artery disease; D = Diagonal; ED = emergency department; LAD = left anterior descending; LVEF = left ventricular ejection fraction; RCA = right coronary artery; STEMI = ST elevation myocardial infarction

Introduction

The presence of collateral coronary circulation is crucial to patients with coronary artery disease (CAD) that can mitigate the consequences of significant coronary stenosis or most importantly during abrupt vessel closure during a myocardial infarction and is also useful in making decisions on their management. Thus, during coronary angiography such collaterals should be carefully sought by obtaining various projections for better visualization. One of these coronary collateral circulations is the Vieussens'

arterial ring, which is an infrequent collateral pathway between the conus branches of the right and left coronary arteries. A patient with a recent anterior myocardial infarction in whom coronary angiography revealed such a collateral vessel is herein presented.

Case Report

A 55-year-old male patient, was admitted to our hospital's emergency department (ED), due to ongoing chest pain for the last 48 hours. Acute coronary syndrome was diagnosed, compatible with post-infarction angina in the setting of an anterior ST-elevation myocardial infarction (STEMI) of late presentation. The patient had visited an ED in his country of origin a few days earlier, and while hospitalization was advised for the treatment of the diagnosed STEMI, he left the hospital against medical advice. He had multiple risk factors for coronary artery disease (CAD), including diabetes mellitus, dyslipidemia and positive family history. His medical history was otherwise unremarkable and he was not taking any medications.

On admission, the patient had ongoing anginal chest pain, radiating to his shoulders. He had a blood pressure of 110/70 mmHg and a heart rate of 85 bpm. Auscultatory findings included an S4 gallop, with no murmur or crackles, classifying the patient as Killip I. The ECG tracing indicated sinus rhythm with poor R wave progression in the precordial leads. Echocardiography revealed preserved systolic function, with hypokinesis confined to the apex and the apical-septal segment and an estimated left ventricular ejection fraction (LVEF) of around 50%.

Complete blood count was unremarkable and biochemical analysis demonstrated normal electrolyte levels and renal function. The first high-sensitivity troponin T (hs-TnT) measurement was 713 pg/ml. Patient's TIMI risk score was 2 while the calculated GRACE score was 90. Loading dose of dual antiplatelet therapy was administered and intravenous infusion of nitroglycerin was established.

The patient was promptly transferred to the catheterization laboratory, for urgent coronary angiography, which was performed via the right radial artery, using a 6 French sheath. Angiography revealed a mild atheromatosis in the proximal LAD, and total occlusion of the vessel with a blunt stump right after the origin of the first diagonal (D1). Antegrade TIMI II flow in the LAD was visualized from its middle segments to its periphery, through collaterals originating mainly from the proximal RCA. Minor collaterals from septal perforators were noted as well. This anatomic variation was first described by Vieussens and is characterized by the formation of a ring around the great vessels. Non-

significant stenoses were spotted in the proximal part of the first obtuse marginal (20%) and the posterior descending coronary artery (30%) as well as in the middle segment of the RCA (50%).

At this point, the decision was made not to proceed with percutaneous coronary intervention (PCI), taking into account the total occlusion of the culprit vessel, the late presentation of the patient and the fact that he was already asymptomatic during the angiography. Instead, reperfusion was opted to be deferred until viability in the territory of the LAD artery was documented.

He left the hospital after 3 days of hospitalization, asymptomatic, without complications from the procedure, and with a left ventricular ejection fraction of 50-55%. A steady drop in troponin values was noted as well. Prior to discharge, scintigraphy revealed viable myocardium among scar tissue in the left ventricular apex. The patient was advised to seek cardiac surgery consultation post discharge.

Discussion

The anatomy variant present in our patient was first described in 1706 by Raymond de Vieussens, and is a rare pathway connecting the conus branch of the right coronary artery with the left conus branch of the left anterior descending artery, across the right ventricular outflow tract.¹ The left conus branch is the first and the largest of the right ventricular branches originating from the proximal LAD.² Occasionally, it can anastomose with the right conus artery, and this pathway could be further augmented by critical stenoses in the LAD or, less often, in the RCA.³

The importance of the arterial ring is the provision of antegrade collateral blood flow, which is increasingly important in cases of proximal coronary artery occlusion. Thus, it could serve as a natural bypass. It has been described that Vieussens' arterial ring could preserve good systolic function despite proximal LAD occlusion or even left main agenesis.^{4,5}

In the present case the ring provided collateral blood flow from the proximal RCA to the LAD distally to the site of the total occlusion. Through this ring, mainly, it is postulated that the extent of an otherwise large anterior infarction was minimized and viability in the LAD territory was preserved.

REFERENCES

1. Hansen MW, Merchant N. Images in cardiovascular medicine. Vieussens' ring: combining computed tomography coronary angiography and magnetic resonance imaging in assessing collateral pathways. *Circulation* 2006;114:e545-546.

2. Atallah PC, Atallah PC, Spears JR. Vieussens' ring with congenitally hypoplastic left coronary arterial system. *Int J Cardiol* 2011;152:e31-32.

3. Hirzallah MI, Horlick E, Zelovitzky L. Coronary artery to main pulmonary artery fistulae via a Vieussens' arterial ring. *J Cardiovasc Comput Tomogr* 2010;4:339-341.

4. Plácido R, Almeida AG, Canas da Silva P, Pinto F. Left main ostial agenesis and right coronary artery occlusion: the importance of the "Vieussens" arterial ring'. *Eur Heart J* 2016;37:1170.

5. Germing A, Mügge A. Images in cardiology: Vieussens' ring. *Clin Cardiol* 2003;26:441.

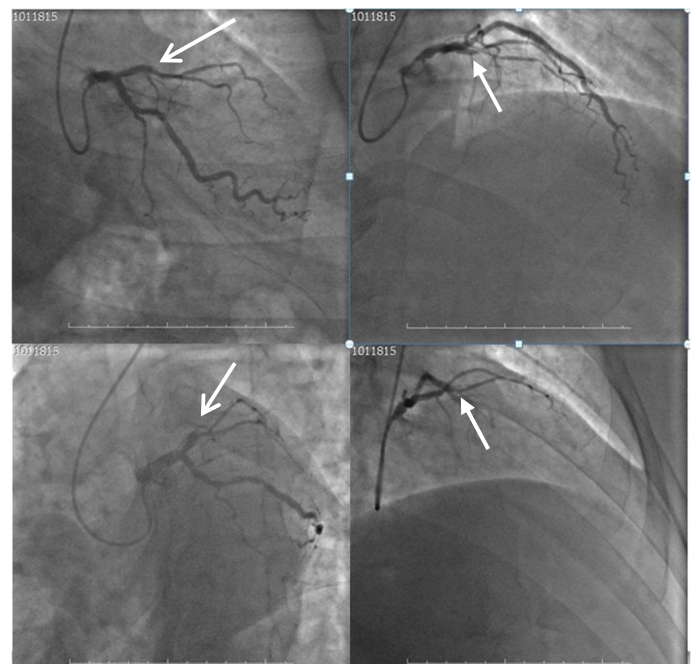


Figure 1: Total occlusion of the LAD (white arrow).

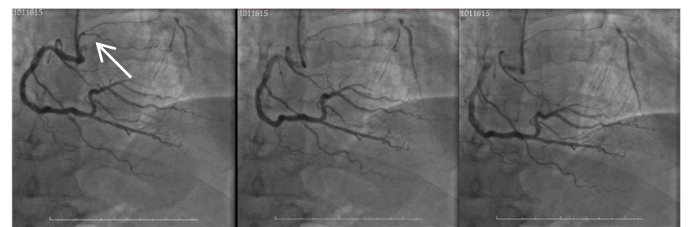

Figure 2. Conus branch reaches the LAD (white arrow).