



Hydrometra and mucometra in goats diagnosed by ultrasound and treated with PGF_{2α}⁽¹⁾

(Hidrometra e mucometra em caprinos diagnosticados por ultra-som e tratados com PGF_{2α})

"Artigo Científico/Scientific Article"

EPBX Moraes^A, MHB Santos^A, IJ Arruda^A, FQG Bezerra^A, CR Aguiar Filho^A,
JP Neves^B, PF, Lima^A; MAL Oliveira^{A (*)}

^ALaboratório de Biotécnicas Reprodutivas do Departamento Medicina Veterinária/Universidade Federal Rural de Pernambuco (UFRPE). Av. Dom Manoel de Medeiros s/n, Dois Irmãos, 52171 900 Recife-PE, Brazil

^BFaculdade de Agronomia e Medicina Veterinária, Universidade de Brasília, Campus Universitário Darcy Ribeiro, 70910-900 Brasília-DF, Brazil.

Abstract

The aim of this study was to report the incidence and treatment of hydrometra and mucometra in goats submitted to ultrasonographic examination for the early pregnancy diagnosis. The exams were performed in females raised together with bucks and then separated from them for at least 30 days. Females showing liquid or mucous collection in the uterus were examined again after 15 days to confirm the pathological condition. Females exhibiting these uterine alterations received 0.5 mg of PGF_{2α}. A total of 146 treated females entered estrus, including 3 (75.0%) Saanen, 2 (66.0%) American Alpine, 1 (100%) Anglo-Nubian, 3 (75.0%) Boer and 1 (100%) Moxotó goat after the first administration, and 1 (25.0%) Saanen, 1 (34.0%) American Alpine and 1 (25.0%) Boer goat after the second administration. The treated females were examined by ultrasound between days 30 and 35 after mating and pregnancy was diagnosed in 13 (100%). No difference in the incidence of hydrometra or mucometra was observed among the herds monitored ($P > 0.05$). The results permit us to conclude that ultrasonography is an important tool to detect early uterine alterations, as well as that PGF_{2α} is efficient in the treatment of hydrometra and mucometra.

Key-words: uterus, pseudopregnancy, anestrus, progesterone

Resumo

Neste trabalho teve-se o objetivo de relatar a incidência e o tratamento da hidrometra e da mucometra em cabras submetidas a exames ultra-sonográfico para diagnosticar precocemente a gestação. Os exames foram realizados nas fêmeas com histórico de permanência junto a reprodutores e de terem sido separadas há, no mínimo, 30 dias. As que não foram diagnosticadas como gestantes e que apresentaram acúmulo de muco ou líquido no útero foram novamente examinadas após 15 dias para confirmação da condição patológica. As fêmeas portadoras dessas alterações uterinas receberam 0,5 mg de PGF_{2α}. As 146 fêmeas tratadas manifestaram estro, sendo 3 (75,0%) Saanen, 2 (66,0%) Alpina Americana, 1 (100%) Anglo-Nubiana, 3 (100%) Boer e 1 (100%) Moxotó após a primeira administração e 1 (25,0%) Saanen e 1 (34%) Alpina Americana e 1 (25%) Boer depois da segunda. As fêmeas tratadas foram ultrasonograficamente examinadas entre o 30º e o 35º dia da cobertura e 13 (100%) foram diagnosticadas como gestantes. Os resultados não apontaram diferença ($P \geq 0,05$) na incidência de hidrometra e mucometra entre os rebanhos monitorados. Os resultados permitem concluir que a ultra-sonografia é uma importante ferramenta tanto para diagnosticar precocemente a gestação quanto para detectar alterações uterinas, bem como que a PGF_{2α} é eficiente no tratamento de hidrometra e mucometra.

Palavras-chave: útero, pseudogestação, anestro, progesterona

⁽¹⁾Trabalho extraído da Dissertação de Mestrado do primeiro autor apresentado ao Programa de Pós-Graduação em Ciência Veterinária da Universidade Federal Rural de Pernambuco.

^(*)Autor para correspondência (maloufrpe@uol.com.br; malo@dmv.ufrpe.br)

Introduction

Brazil possesses approximately 2% of the world goat population (FAO, 2004), with more than 90% of its herd being concentrated in the Northeast region (IBGE, 1996). Despite this potential, the productivity of the herds is low because it mainly consists of crossbred animals that are well adapted to the climatic conditions and that have been extensively exploited without reproductive or even productive control. The importation of animals of specialized breeds has led, although slowly, to changes in the rearing system because of the need to adopt more technical exploitation models which require a more effective control of reproductive problems that affect the productivity of the herds (Bandeira et al., 2004).

Hydrometra and mucometra, clinically called pseudopregnancy before the advent of ultrasonography due to the lack of equipment that would permit a more precise diagnosis (Lopes Júnior et al., 2004), represent relevant problems in goat rearing because they occur both during and outside the reproductive season (Pieterse and Taverne, 1986; Hesselink, 1993). These uterine disorders are only differentiated by the physical characteristics of the fluid present in the uterus (Nascimento and Santos, 2003) which accumulates between the second and fifth month after mating (Martel, 2001). Due to the aseptic character of the fluid collection in the uterus, no modification in the general clinical status of the animals is observed at least at the beginning of the process (Lêga and Toniollo, 1999). However, the animals behave as if they were pregnant due to the presence of a pseudopregnant corpus luteum (Martel, 2001), with an increase in the interval between deliveries and a reduction in reproductive efficiency (Wittek et al., 1998; Lêga and Toniollo, 1999; Martel, 2001). The etiology of this pathological condition is still not completely understood (kornalunslipper, 1997; Wittek et al., 1998),

although obstruction of the cervix or vagina, hyperestrogenism and hymen persistence have been suggested to be responsible for it (Nascimento and Santos, 2003).

Ultrasonography has established a new dimension in animal reproduction by permitting not only the visualization of the reproductive tract but also the early diagnosis of pregnancy, monitoring of embryonic and fetal development, determination of fetal sex, identification of the phase of the estrous cycle and, especially, the diagnosis of reproductive system disorders such as hydrometra, mucometra and pyometra (Wittek et al., 1998; Lêga and Toniollo, 1999; Martel, 2001).

Hydrometra is characterized by an enlarged uterus due to the accumulation of hypoechogenic fluid (Lêga and Toniollo, 1999), presence of mobile, echogenic and relatively thin trabeculae, and the absence of placental structures or other signs of the presence of an embryonic or fetal structure (Martel, 2001).

In view of the above considerations and since ultrasound is a noninvasive method that combines the possibility of early diagnosis and accuracy, the objective of the present study was to determine the incidence of hydrometra and mucometra in Saanen, American Alpine, Boer, Anglo-Nubian and Moxotó goats submitted to ultrasonographic examination for the early pregnancy diagnosis.

Material and Methods

A total of 143 goats ranging in age from 1 to 6 years were studied: 30 Saanen and 34 Anglo-Nubian goats belonging to two properties in the Municipality of Sertânia (08° 04' 25" South latitude and 35° 15' 52" longitude West), Pernambuco - Brazil, 23 American Alpine goats from a property in the Municipality of Brejo da Madre de Deus (08° 08'45" South Latitude and 36° 22' 16" Longitude West), Pernambuco - Brazil, 39 Boer goats from a property in the Municipality of Gravatá (08° 12' 04" South

Latitude and 35° 33' 53" Longitude West), Pernambuco - Brazil, and 17 Moxotó goats from EMEPA, Municipality of Soledade in Pendência Experimental Farm (07° 03' 26" South Latitude and 36° 21' 46" Longitude West), Paraíba- Brazil.

Saanen females aged 1 to 4 years reared in an intensive system were milked twice a day. Immediately after each milking, the animals had access to bulk food, forage palm (*Opuntia ficusindica*) and concentrate (wheat bran + cotton bran + corn flour). Anglo-Nubian animals aged 3 to 5 years and reared in a semi-intensive system grazing on native pasture as the main forage source when confined in corrals and receiving manioc (*Manihot esculenta*) hay when kept in stables.

American Alpine goats aged 1 to 5 years and also reared semi-intensively were milked only once a day. When grazing, they had access to native grass and when kept in the stable they received Buffel (*Cenchrus ciliaris* L.), Urocroa (*Urochloa moçambicensis* Dandy) and Algaroba (*Prosopis juliflora*) hay grass, as well as chopped palm and dairy goat ration. Boer females ranging in age from 2 to 5 years reared in a semi-intensive system had access to corrals covered with Pangola (*Digitaria decumbens*) grass and received 200 g of balanced ration when feeding from a trough. The Moxotó animals aged 3 to 4 years were reared in an intensive system. At all properties, the females had access to water and mineral salt *ad libitum*.

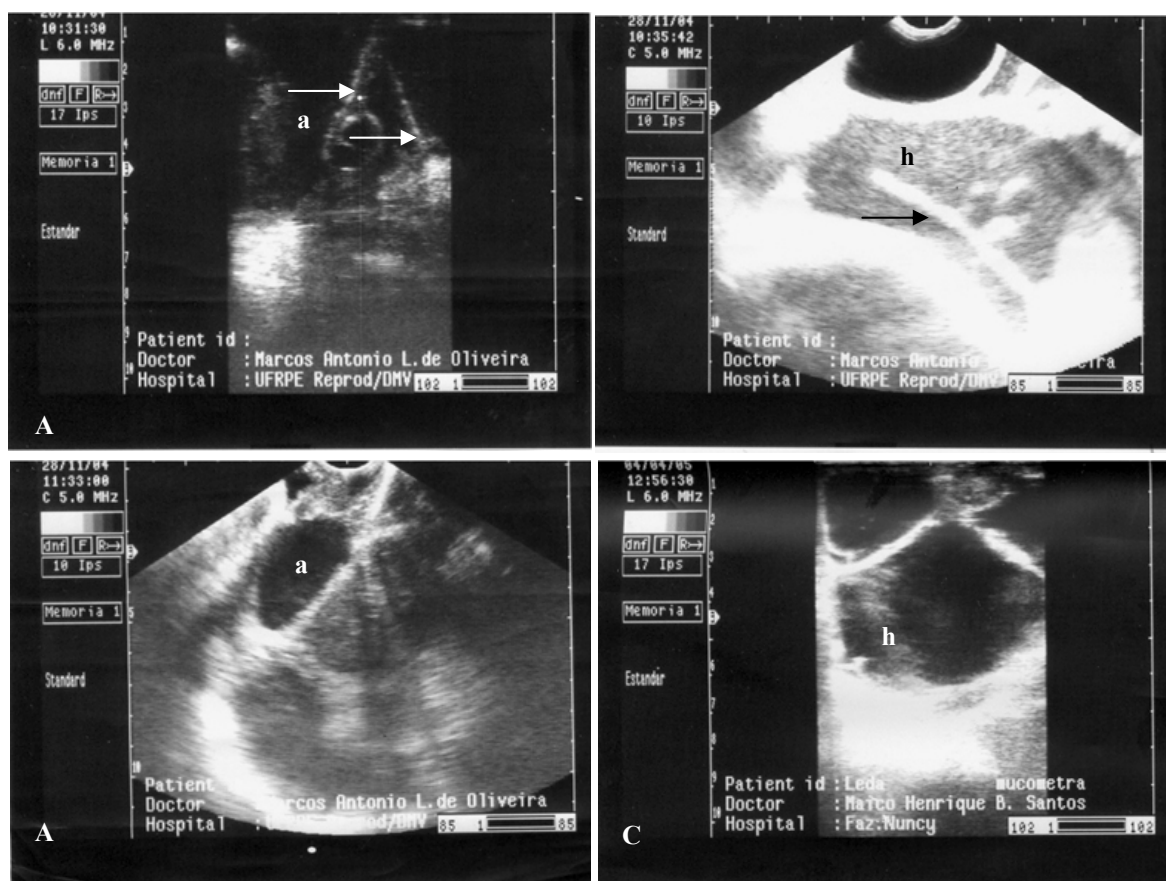


Figure 1 - Fluid accumulation in the uterus forming hyperechoic trabeculae (—→). Uterine collection exhibiting an anechoic image (a) diagnosed as hydrometra (A and B) and a hypoechoic image (h) diagnosed as mucometra (C and D).

The ultrasonographic exams were performed with the animal in a standing position using the 240 Parus ultrasound system (Pie Medical) equipped with a linear transducer (6.0 and 8.0 MHz) adapted to a PVC support to facilitate manipulation in the animal's rectum and a microconvex endocavity transducer (5.0 and 7.5 MHz) covered with a plastic protection at its end for transvaginal ultrasound, as suggested by Oliveira et al. (2004). Pictures obtained by ultrasound were printed using a Sony printer (Seikosha VP/1200). All examinations were performed by the same operator.

At the properties monitored, females kept together with bucks and then separated from them for at least 30 days were submitted to ultrasonographic examination. Animals that were not diagnosed as pregnant and that presented mucus or fluid accumulation in the uterus, forming hyperechoic and relatively thin mobile trabeculae (Figure 1A and C), were examined again after 15 days for confirmation of the pathological condition. Cases in which the uterine collection exhibited an anechoic image were diagnosed as hydrometra (Figure 1A and B) and those presenting an hypoechoic image were

diagnosed as mucometra (Figure 1C and D).

Females in which these uterine alterations were diagnosed, initially received 0.5 mg Dinoprost (Lutalyse, Pfizer), intramuscularly. Animals in which no estrus was detected over the subsequent 5 days were reassessed by ultrasound and, if the presence of intrauterine fluid was confirmed, received again the same prostaglandin dose on day 11 after the first administration. Clinical signs of estrus were verified by experienced examiners using teasers. Females in estrus were then mated with the same bucks as described earlier 12 h after estrus detection. Pregnancy was diagnosed between day 30 and day 35 after mating by ultrasound as described above.

The data were analyzed statistically by the chi-square test, with the level of significance set at 5%.

Results

The results are shown in Tables 1 and 2. Among the 80 non-pregnant females, hydrometra was diagnosed in 11 and mucometra in two, corresponding to an incidence of 18.6% (Table 1), with no significant difference between breeds ($P > 0.05$).

Table 1 - Incidence of uterine alterations in different goat breeds.

Breed	N° of animals	Diagnostic			
		Pregnant n (%)	Non Pregnant n (%)	Hydrometra n (%)	Mucometra n (%)
Saanen	30	17 (56.7)	9 (30.0)	3 (10.0)	1 (3.3)
American Alpine	23	4 (17.4)	16 (69.6)	3 (13.0)	-
Anglo-Nubian	34	23 (67.6)	10 (29.4)	1 (2.9)	-
Boer	39	8 (20.5)	27 (69.5)	3 (7.7)	1 (2.5)
Moxotó	17	11 (64.7)	5 (29.4)	1 (5.9)	-
Total	143	63 (44.1)	67 (46.8)	11 (7.7)	2 (1.4)

As shown in Table 2, all females entered estrus after treatment with prostaglandin, regardless of whether they were treated once or twice. Females were detected as being in estrus within a period of 120 h, including 6 (46.2%) animals after 48 h, 5 (38.5%) after 72 and 2 (15.3%) after 96 h. Pregnancy was diagnosed in 100% of

the females between day 30 and day 35 after mating (Table 2).

Discussion

In the present study, 11 cases of hydrometra and two cases of mucometra were diagnosed among the 143 animals examined, corresponding to a frequency of 9.0%, a value

considered to be normal compared to literature reports showing an incidence of uterine alterations in goats of 3.0 to 9.0% (Hesselink, 1993; Wittek et al., 1998; Batista et al., 2000). However, separate analysis of each herd showed that the frequency of these alterations was within the reported limit of variation only in Anglo-Nubian, Boer and Moxotó animals. These data agree with Martel (2001) who reported that meat

breeds are less susceptible to the occurrence of hydrometra and mucometra. It is also important to note that the frequencies obtained for the Saanen (13.3%) and American Alpine (12.1%) herds were slightly higher than the 9.0% reported by Hesselink (1993) and much higher when compared to the 3.0 and 5.0% obtained by Wittek et al. (1998) and Batista et al. (2000), respectively.

Table 2 - Frequency of estrus and pregnancy in females with hydrometra and mucometra after treatment with prostaglandin.

Breed	N° of animals	Estrus		Pregnancy n (%)
		First injection n (%)	Second injection n (%)	
Saanen	4	3 (75.0)	1 (25.0)	4 (100)
American Alpine	3	2 (66.6)	1 (34.0)	3 (100)
Anglo-Nubian	1	1 (100)	-	1 (100)
Boer	4	3 (75.0)	1 (25.0)	4 (100)
Moxotó	1	1 (100)	-	1 (100)
Total	13	10 (76.9)	3 (23.1)	13 (100)

Although nutritional management differed between the properties studied, this factor does not seem to have triggered or even predisposed to the occurrence of these uterine conditions. It is particularly interesting that the higher incidence of hydrometra and mucometra was observed exactly in those animals that theoretically received feed of better quality, suggesting that these alterations are not related to the nutritional condition of the herd. According to Batista et al. (2000), there is no evidence that feeding and sanitary management are etiological factors of these uterine alterations.

Martel (2001) indicated the rearing system as a possible factor responsible for a higher or lower incidence of hydrometra and mucometra in goats. However, the present results do not support this theory since higher frequencies were observed for the Saanen herd, reared in an intensive system, and the American Alpine herd reared in a semi-intensive manner similar to the system adopted for Boer, Anglo-Nubian and Moxotó

animals.

Still regarding the management system, it should be emphasized that American Alpine females were milked only in the morning, whereas Saanen females were milked in the morning and afternoon. Although Wittek et al. (1998) ruled out the influence of milk production on the occurrence of uterine alterations in goats, and it was not possible to precisely determine the etiology of hydrometra and mucometra in the females examined here, there is the possibility that milk production was related to the present findings. This hypothesis is based on the well-known fact that, at least in cattle, endocrine function can be altered by milk production and that the action of endogenous opioids resulting from the stress induced by milk production might have been responsible for the larger number of females with these uterine alterations. This hypothesis is supported by the reports of Hesselink (1993) and Martel (2001) who observed a relatively higher incidence in dairy goats compared to

meat breeds.

According to Martel (2001), another factor that might induce these uterine alterations is the administration of hormones for estrus synchronization. Although Lopes Júnior et al. (2004) concluded that the prevalence of pseudopregnancy is statistically the same in Saanen goats with normal or synchronized estrous cycles, hyperestrogenism is known to be a determining factor of hydrometra (Nascimento and Santos, 2003), and hydrometra has been shown to be more frequent in animals submitted to ovulation induction (Mizenga and Verma, 1984; Mialot et al., 1991; Humblot et al., 1995). However, this possibility can completely be ruled out in the present study since the animals were not submitted to assisted reproduction programs. Moreover, according to Hesselink (1993), it is still unclear how the exogenous induction of ovulation increases the incidence of pseudopregnancy. In addition, well-conducted hormonal treatment does not leave sequelae, nor should it be considered responsible for hydrometra and mucometra in goat herds as reported by Batista (2000) and Lopes Júnior et al. (2004).

The prolonged activity of the pseudopregnant corpus luteum in animals with hydrometra and mucometra reflects the absence of a luteolytic action of uterine origin (Currie et al., 1988). Since in the present study all females responded to exogenous treatment with a luteolytic agent, one may suppose that these alterations were the consequence of disturbances in the luteolytic mechanism. Immunization against the action of prostaglandin resulting in the persistence of luteal function, with a consequent accumulation of fluid in the uterus, has been demonstrated in Saanen goats by Kornalijper et al. (1997). These authors observed that the presence of the pregnant corpus luteum associated with a progesterone concentration higher than 2 ng/mL induces the accumulation of fluid in the uterus.

Spontaneous elimination of the uterine collection is only partial, thus

impairing luteolysis of the pregnant corpus luteum and leading to the recurrence of hydrometra or mucometra (Pieterse and Taverne, 1986; Lopes Júnior et al., 2004). The results reported by Pieterse and Taverne (1986) demonstrate that a single administration of prostaglandin or oxytocin is not sufficient to eliminate the fluid present in the uterus of goats. According to Hesselink (1993), a second administration of prostaglandin within an interval of 12 days significantly increases the reproductive performance of this species. However, the present study demonstrated that a single dose of prostaglandin does not induce estrus in all animals but is efficient in the treatment of hydrometra and mucometra because all females in estrus became pregnant after one mating. In our opinion, it is important not to inseminate the female naturally or artificially during the first post-treatment estrus as adopted in the present study.

In agreement with Lêga and Toniollo (1999), we conclude that ultrasound is a rapid, precise and efficient method for the diagnosis of pregnancy and that prostaglandin is an important tool in the treatment of hydrometra and mucometra.

References

- BANDEIRA, D.A. et al. Aspectos gerais da caprino-ovinocultura no Brasil e seus reflexos produtivo e reprodutivo. In: SANTOS, M.H.B. et al. **Diagnóstico de gestação na cabra e na ovelha**. São Paulo: Varela, 2004. Cap. 1, p. 1-9.
- BATISTA, M. et al. Incidence and treatment of hydrometra in the Canarian goat. In: **Proceedings of the 7th International Conference on Goats**. Lyon, France, 2000. p. 15-21.
- CURRIE, W.B. et al. Endocrine changes, with special emphasis on oestradiol-17 β , prolactin and oxytocin, before and during labour and delivery in goats. **Journal of Reproduction and Fertility**, v. 82, p. 299-308, 1988.
- FAO., 2004. **Statistical database**. Disponível em: <<http://www.fao.org>>. Acesso em: 25 out. 2005.
- HESELINK, J. W. Incidence of hydrometra in dairy goats. **Veterinary Record**, v. 132, n. 5, p. 110-112, 1993.

- HUMBLLOT, P. et al. Embryo mortality in the dairy goat after oestrus synchronization and artificial insemination outside the normal breeding season. In: PROCEEDINGS OF THE LES COLLOQUES DES 2^{EMES} RECONTRES DES RECHERCHES SUR RUMINANTS, Paris, France: **Institut de l'Élevage**, 1995. p. 387-389.
- IBGE, 1996. Anuário Estatístico do Brasil. Rio de Janeiro.
- KORNALIJNSLIJPER, J. E. et al. Induction of hydrometra in goats by means of active immunization against prostaglandin F_{2α}. **Animal Reproduction Science**, v. 46, p. 109-122, 1997.
- LÊGA, E.; TONIOLLO, G. H. Hydrometra in goats – Report of a case in *Capra hircus*. **Brazilian Journal of Animal Reproduction**, v. 23, p. 446-447, 1999.
- LOPES JUNIOR, E. S. et al. Pseudopregnancy in Saanen goats (*Capra hircus*) raised in northeast Brazil. **Veterinary Research Communications**, v. 28, p. 119-125, 2004.
- MARTEL, J. L. M. Incidência de la hidrómetra em la agrupacion caprina canária. **Vetor Plus**, v. 18, p. 28-34, 2001.
- MIALOT, J.P. et al. La pseudogestation chez la chevre. Observations preliminaires. **Récueil de Médecine Vétérinaire**, v. 167, p. 383-390, 1991.
- MIZENGA, K.M.; VERMA, O.P. LHRH-induced ovulation and fertility of anoestrous goats. **Theriogenology**, v. 21, p. 435-446, 1984.
- NASCIMENTO, E. F.; SANTOS, R. L. Alterações regressivas. In: NASCIMENTO, E. F.; SANTOS, R. L. **Patologia da Reprodução dos Animais Domésticos**. Rio de Janeiro: Guanabara Koogan, 2003. Cap. 3, p. 52.
- OLIVEIRA, M.A.L. et al. Aplicabilidade do Scan B na reprodução de pequenos ruminantes. In: SANTOS, M.H.B. et al. **Diagnóstico de gestação na cabra e na ovelha**. São Paulo: Varela, 2004. Cap. 13, p.85-96.
- PIETERSE, M.C.; TAVERNE, M.A.M. Hydrometra in goats: diagnosis with real-time ultrasound and treatment with prostaglandins or oxytocin. **Theriogenology**, v. 26, p.813-821, 1986.
- WITTEK, T. et al. Histology of the endometrium, clinical-chemical parameters of the uterine fluid and blood plasma concentrations of progesterone, estradiol-17β and prolactin during hydrometra in goats. **Small Ruminant Research**, v. 30, p. 105-112, 1998.