



ISSN: 2091-2749 (Print)  
2091-2757 (Online)

#### Correspondence

Dr. Shanta Bir Maharjan  
Department of Surgery  
Patan Hospital, Patan Academy  
of Health Sciences, Lalitpur,  
Nepal  
Email: shantabm@yahoo.com

#### Peer Reviewers

Asst Prof. Dr. Sumana  
Bajracharya  
Patan Academy of Health  
Sciences

Asst. Prof. Dr. Ashis Shrestha  
Patan Academy of Health  
Sciences

#### Submitted

14 Nov 2018

#### Accepted

2 Dec 2018

#### How to cite this article

Shanta Bir Maharjan, Sanjaya Paudyal, Sailendra Shah, Romi Dahal, Jay Narayan Shah. Clinical profile and surgical outcome of abdominal hydatid cyst at a university hospital, Nepal. Journal of Patan Academy of Health Sciences. 2018Dec;5(2):52-57.

## Clinical profile and surgical outcome of abdominal hydatid cyst at a university hospital in Nepal

Shanta Bir Maharjan,<sup>1</sup> Sanjaya Paudyal,<sup>2</sup> Sailendra Shah,<sup>3</sup> Romi Dahal,<sup>3</sup> Jay Narayan Shah<sup>4</sup>

<sup>1</sup>Assistant Professor, <sup>2</sup>Associate Professor, <sup>3</sup>Lecturer, <sup>4</sup>Professor, Department of Surgery, Patan Hospital, Patan Academy of Health Sciences, Lalitpur, Nepal

### Abstract

**Introductions:** Hydatid cyst is caused by the tapeworm. It is common in sheep and cattle rearing communities. Liver is the most common affected organ. There are various methods of surgical approaches for hydatid cyst.

**Methods:** This was a retrospective descriptive study of patients operated for intra-abdominal hydatid cysts from July 2012 to June 2018 at Patan Hospital, Patan Academy of Health Sciences, Nepal. Ethical approval from institutional review committee was obtained. Patient files with incomplete data were excluded. Variables analyzed were, age, gender, site and numbers of cyst, methods of surgery, complications and mortality. Data were descriptively analyzed.

**Results:** There were 19 patients of abdominal hydatid cysts who underwent surgery during the study period. Five records files could not be accessed and were excluded. In remaining 14, male were 6 (42.85%), female 8 (57.15%), mean age  $39.57 \pm 17.35$  years (14-70), cyst size  $11 \pm 4.22$  cm (5-21), complain of abdominal pain in 10 (71%). Open surgery for liver cyst was done in 11 and laparoscopic in one, and open splenectomy for two splenic cysts. One patient developed superficial wound infection. Four had cystobiliary communication of which one underwent ERCP. Post ERCP patient developed acute severe pancreatitis and expired. Mean hospital was  $8.57 \pm 2.24$  days (6-14).

**Conclusions:** Liver was the main organ involved, abdominal pain and lump were main presenting complaints. Surgery had successful outcome. Open surgery was the mainstay of treatment.

**Keywords:** echinococcus granulosus, hydatid cyst, hydatidosis

## Introductions

Hydatid disease (HD) is a zoonotic disease caused by tapeworm, echinococcus. The *E. granulosus* and *E. multilocularis* are commonest causes of human cystic and alveolar HDs respectively.<sup>1-4</sup> Canine, like dogs are the definitive hosts, while sheep and cattle are intermediate hosts. Humans are intermediate host acquiring the disease by accidentally ingesting food contaminated with the eggs of tapeworms.<sup>1</sup> The HD is endemic in sheep rearing communities, like Middle East, Far East, South America, Africa, New Zealand, Australia, Turkey and Mediterranean.<sup>1,2</sup> Liver is most commonly affected organ, followed by lungs; while peritoneum, spleen, kidney and pancreas are rarely affected.<sup>2-6</sup>

Clinical features depend upon site, size, stages of development of cyst and its complications. Abdominal pain and masses are common clinical features of abdominal HD.<sup>2,7</sup> Abdominal ultrasound (USG), computed tomography (CT) and magnetic resonance imaging (MRI) are helpful for diagnosis.<sup>3,4,7</sup> Features like double layer thick walls, floating membrane, cart wheel appearance, calcified wall and presence of daughter cysts are positive radiology and Eosinophilia, positive serology like ELISA (Enzyme Linked Immunosorbent Assay) are laboratory findings.<sup>1,3,7</sup>

The treatment options are medical and surgeries- PAIR (Puncture Aspiration Injection Reaspiration), open and laparoscopic surgery.<sup>2,3,7</sup> We analyze the different clinical features, surgical approach, and outcomes of abdominal HD.

## Methods

This cross-sectional retrospective study includes patients operated for abdominal HD during July 2012 to June 2018 at Patan hospital, Patan Academy of Health Sciences (PAHS), Nepal. Ethical approval was obtained from institutional review committee (IRC) of PAHS. The hospital admission numbers of patients were obtained from operation room

record book. The record files were obtained from hospital record section. Patient files were analyzed for data on age, sex, clinical features, radiological details of cyst (size, site, numbers), serological test (ELISA), methods of operation, and outcomes of surgery (complications-cysto-biliary communications, anaphylaxis, wound infection; hospital stay in days; and mortality). The data were analyzed using descriptive statistics.

## Results

Total 19 patients underwent surgery for abdominal HDs during 6-year period at Patan Hospital. Five records files could not be accessed and were excluded. Data analyzed for remaining 14 patients revealed male 6/14 (42.85%), female 8 (57.15%), male:female ratio 0.75:1, mean age  $39.57 \pm 17.35$  years (14-70). Clinical presentations were abdominal pain in 10 (71%), abdominal lump 8 (57.14%), (Table 1). The USG of abdomen and pelvis was performed in all patients. Cyst was located in liver 12/14 (86%), (Table 2). The CT done in 10/14 (71.4%) cases were consistent with USG findings. Mean cyst size was  $11 \pm 4.22$  cm (5-21). The ELISA was positive in 8/14 (57.14%), negative in 2 (14.28%) and not available in 4 (28.57%). Eosinophilia was found in 2 (14.28%). For liver cyst- open surgeries 11/14 (78.6%, 8-cyst evacuation omentopexy, 3-evacuation marsupialization) and one laparoscopic cyst drainage were done. Splenectomy were performed for two splenic cysts, (Figure 1). One patient developed superficial wound infection. Postoperatively, four liver cysts had cystobiliary communication showing bile in the abdomen drain. One cystobiliary communication continued to drain bile 250-300 ml/day and underwent ERCP sphincterotomy biliary stenting on 9<sup>th</sup> day. He developed acute severe pancreatitis and expired on 11<sup>th</sup> postoperative day, the 2<sup>nd</sup> day following ERCP. Mean hospital was  $8.57 \pm 2.24$  days (6-14). Demographically 8 (57.15%) patients were from Kathmandu valley, (Table 3).

**Table 1. Clinical features of patients (n=14) with abdominal hydatid cyst (HD) operated at Patan Hospital, Patan Academy of Health Sciences (PAHS), Nepal**

Clinical Feature	N (out of 14)	%
Abdominal Pain	10	71.43
Abdominal Lump	8	57.14
Jaundice	2	14.28
Asymptomatic	1	7.14

**Table 2. Site and size of abdominal HD (n=14)**

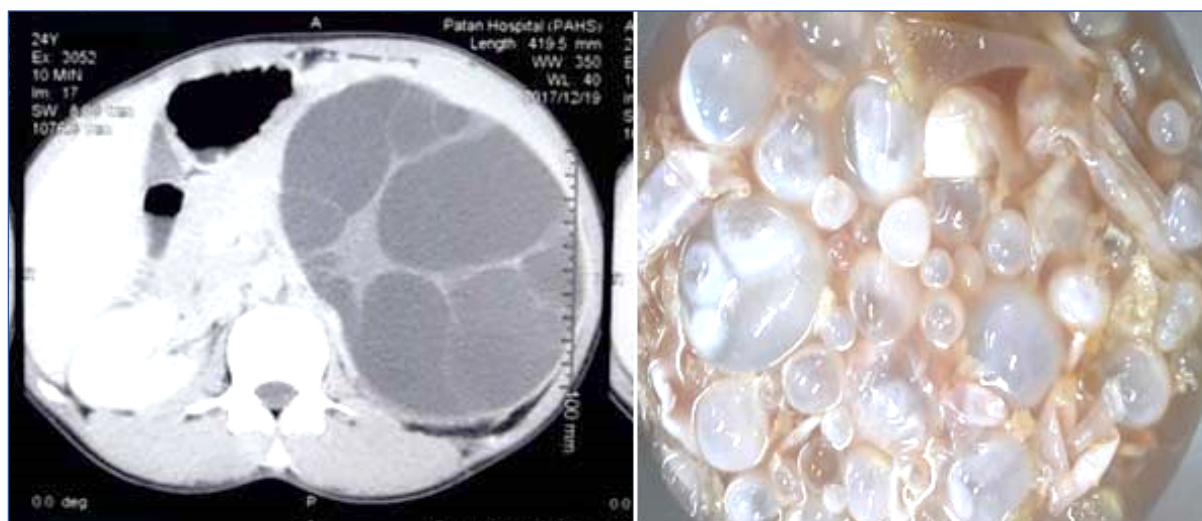
Location	N	%
Liver	12	85.71
Right Lobe	8	57.14
Left Lobe	3	21.42
Both Lobe	1	7.14
Spleen	2	14.28
Cyst Size cm	5-21	11±4.22 cm (5-21)

**Table 3. District/residence of patients with HD (n=14) operated at Patan Hospital, PAHS, Nepal**

District/Residence	N	%
Kathmandu Valley	8	57.13
Kathmandu	6	42.85
Lalitpur	2	14.28
Dang	2	14.28
Makwanpur	1	7.14
Chitwan	1	7.14
Biratnagar	1	7.14
Ramechhap	1	7.14

**Table 4. Surgical outcome of HD (n=14)**

Complications/Outcome	N	%
Cystobiliary Communication	4	28.57
SSI- Surgical site infection, superficial	1	7.14
Mortality	1	7.14



**Figure 1a. CT and splenectomy specimen of a 24 year female HD patient operated at Patan Hospital, PAHS**

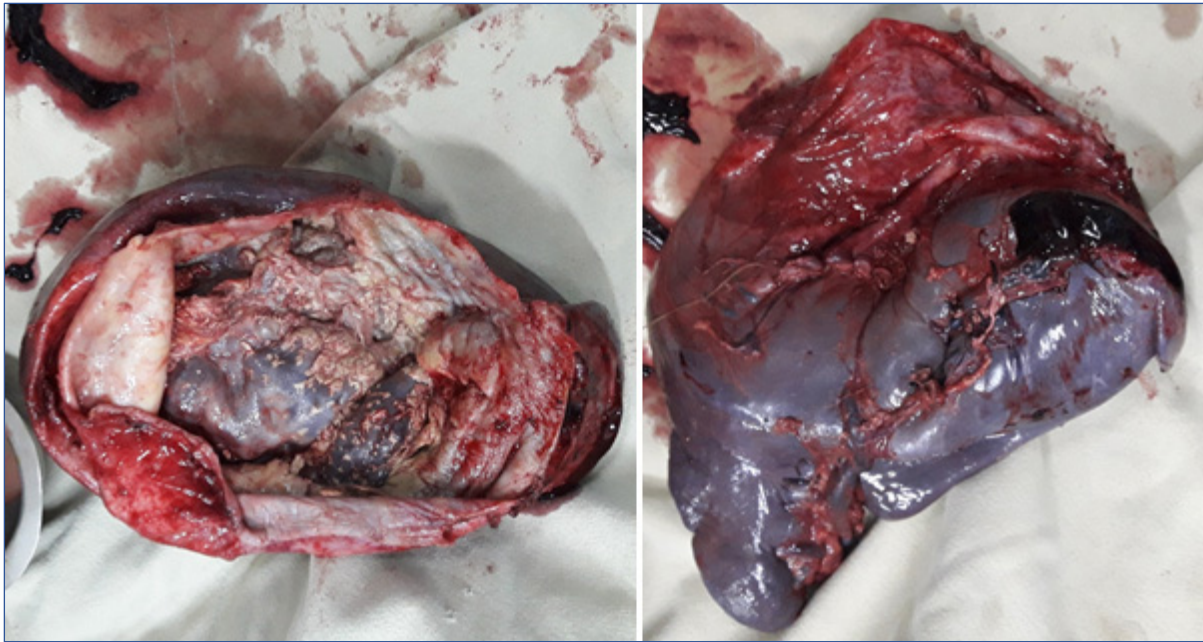


Figure 1b. CT and splenectomy specimen of a 24 year female HD patient operated at Patan Hospital, PAHS

### Discussions

In this six years of retrospective review of abdominal HD, with average age 39.57 years and male:female ratio 0.75:1, similar to the findings reported from Saudi Arabia, Yemen and Nepal.<sup>2,8-10</sup> Clinically, abdominal pain was main presenting symptoms in 10 (71.43%) and abdominal lump in 8 (57.14%), consistent with other published reports of up to 84% abdominal pain in liver hydatid cyst.<sup>2,11</sup> In our study, liver 12 (85.71%) was the most common organ involved in abdomen HDs, followed by spleen 2 (14.28%). Right lobe of liver was more commonly involved 8 (57.14%). Similarly, other studies also report liver involved in 2/3 of HD, and other less common are spleen and kidney; while adrenal glands, gall bladder, omentum, peritoneum, appendix and ureter are rarely involved.<sup>2,6,8,10</sup>

In most cases, initial diagnosis of abdominal HD is difficult by clinical features alone. In our study, abdomen USG was performed in all cases and CT when in doubt or to rule out involvement of other organs in the abdomen. Presence of cyst wall calcification, cart wheel appearances, split wall sign and presence of daughter cysts are important radiological features of HD. The US and CT have good sensitivity and specificity for detecting hydatid

cyst.<sup>2-4,11,12</sup> The CT are more accurate for detecting cyst number, size, localization and useful in when USG findings are inconclusive.<sup>2,3,12</sup>

In this study eosinophilia was found in 2 (14.28%) and ELISA positive in 8/14 (57.14%). The study reports eosinophilia in less than 25% infected with HD.<sup>7</sup> Serological tests are also commonly used in the diagnosis and recurrence monitoring. Liver cysts are more likely to elicit an immune response than pulmonary cysts.<sup>3,7</sup>

In our study, most patients 8 (57.14%) were from Kathmandu valley. This may be due to migration of patients from other parts of the country. There are similar reports showing 60% of patients with liver HD from the urban areas.<sup>2,11</sup> The option of treatment for hydatid cyst ranges from simple cyst drainage (evacuation) to resection of the whole or part of the involved organ, or liver transplantation.<sup>2,10,13,14</sup> In this study, we performed open surgery deroofting, evacuation, marsupialization and omentoplasty for liver cyst and laparoscopic evacuation in one only. The laparoscopic surgery has been recently started in our center. In one case total splenectomy (splenic hydatid cyst) was performed because the cyst

was large with little remnant splenic parenchyma. Literature describes many surgical options, like simple evacuation, capitonnage, deroofting, omentoplasty, pericystectomy and resection.<sup>3,7,13</sup>

Our hospital practice is to prescribe albendazole for at least one week prior to surgery and one full course of three weeks after the surgery. Albendazole, mebendazole and praziquantel are good chemotherapeutic agents for HD but efficacy of albendazole is better than others.<sup>7</sup>

The PAIR is safe and effective outpatient treatment modality in selected cases, usually with deep seated small single cyst.<sup>15-17</sup> and laparoscopic management are other good option, increasingly becoming popular as a safe and effective modality.<sup>18-22</sup>

In all cases of surgical management, care must be taken not to spill the cyst fluid to prevent anaphylaxis, and use of appropriate scolicidal agent is important to deactivate the live scolices to prevent the dissemination of disease.<sup>21,23</sup> In recent years, we have shifted from the historical use of 1% silver nitrate solution to 10% povidone iodine solution at our hospital.

Classification of HD (of liver) is important to determine the evolutionary stages of cyst in order to plan and choose the best method of management.<sup>24,25</sup>

Post operatively, cystobiliary communications were noted in four patients with bile draining from abdominal drain tube which we routinely keep in all patients. The bile drainage stopped spontaneously in three patients but in one it continued. This patient underwent ERCP, sphincterotomy and stenting on 9<sup>th</sup> postoperative day. Unfortunately, this patient developed severe pancreatitis and expired on 11<sup>th</sup> postoperative day. One patient developed superficial surgical site infection which was managed with dressing and antibiotic. Average follow up in this study was 2.8 months, without USG evidence of recurrence.

## Conclusions

Abdominal pain and lump were main clinical features of abdominal hydatid cysts. Liver and its right lobe was commonly involved. Ultrasound and CT scan were modality for diagnosis and management. The ELISA was diagnostic in majority. Open surgery was safe and effective. Most of our patients were from urban non-endemic Kathmandu valley, may be due to migration.

## References

1. Pedrosa I, Saiz A, Arrazola Juan, Ferreiros J, Pedrosa CS. Hydatid disease: radiologic and pathologic features and complications. *Radiographics*. 2000;20(3):795-817. DOI: 10.1148/radiographics.20.3.g00ma06795 [GoogleScholar](#)
2. Abebe E, Kassa T, Bekele M, Tsehay A. Intra-abdominal hydatid cyst: sociodemographics, clinical profiles, and outcomes of patients operated on at a tertiary hospital in Addis Ababa, Ethiopia. *J Parasitol Res*. 2017;2017:4837234. DOI: 10.1155/2017/4837234
3. Rasheed K, Zargar SA, Telwani AA. Hydatid cyst of spleen: a diagnostic challenge. *N Am J Med Sci*. 2013;5(1):10-20. DOI: 10.4103/1947-2714.106184 PMID: 23378949
4. Eris C, Akbulut S, Yildiz MK, Abuoglu H, Odabasi M, Ozkan E, Atalay S, Gunay E. Surgical approach to splenic hydatid cyst: single center experience. *Int Surg*. 2013;98(4):346-53. DOI: 10.9738/INTSURG-D-13-00138.1
5. Abebe E, Tsehay A. Hydatid cyst disease in the left lateral neck: an uncommon presentation. *Ethiop Med J*. 2016;54(3):145-7. [PDF](#)
6. Biluts H, Minas M, Bekele A. Hydatid disease of the liver: a 12 year experience of surgical management. *East and Central African Journal of Surgery*. 2006;11(2):54-60. [PDF](#)
7. Moro P, Schantz PM. Echinococcosis: a review. *Int J Infect Dis*. 2009;13(2):125-33. DOI: 10.1016/j.ijid.2008.03.037 PMID: 18938096
8. Ghartimagar D, Ghosh A, Shrestha MK, Talwar OP, Sathian B. A 14 years hospital based study on clinical and morphological spectrum of hydatid disease. *J Nepal Med Assoc*. 2013;52(190):349-53. PMID: 24362658 [PDF](#)
9. Alghoury A, El-Hamshary E, Azazy A, Hussein E, Rayan HZ. Hydatid disease in Yemeni patients attending public and private hospitals

- in Sana'a City, Yemen. *Oman Med J.* 2010;25(2):88-90. DOI: 10.5001/omj.2010.26 PMID: 22125707
10. Jastaniah S, Malatani T, Eshy SA, et al. Hydatid cyst disease (*Echinococcus granulosus*): experience at Asir Central Hospital. *Saudi J Gastroenterol.* 1997;3(3):140-3. PMID: 19864792
  11. Wuestenberg J, Gruener B, Oeztuerk S, et al. Diagnostics in cystic echinococcosis: serology versus ultrasonography. *Turkish J Gastroenterol.* 2014;25:398-404. PDF
  12. Marrone G, Crino F, Caruso S, et al. Multidisciplinary imaging of liver hydatidosis. *World J Gastroenterol.* 2012;18(13):1438-47. DOI: 10.3748/wjg.v18.i13.1438 PMID: 22509075
  13. Goja S, Saha SK, Yadav SK, Tiwari A, Soin AS. Surgical approaches to hepatic hydatidosis ranging from partial cystectomy to liver transplantation. *Ann Hepatobiliary Pancreat Surg.* 2018;22(3):208-15. DOI: 10.14701/ahbps.2018.22.3.208
  14. Keong B, Wilkie B, Sutherland T, Fox A. Hepatic cystic echinococcosis in Australia: an update and diagnosis and management. *ANZ J Surg.* 2018;88(1-2):26-31. DOI: 10.1111/ans.14117
  15. Filice C, Pirola F, Brunetti E, Dughetti S, Strosselli M, Foglieni CS. A new therapeutic approach for hydatid liver cysts: aspiration and alcohol injection under sonographic guidance. *Gastroenterology.* 1990;98(5):1366-8. DOI: 10.1016/0016-5085(90)90358-8 PMID: 2182372
  16. Koroğlu M, Erol B, Gürses C, Türkbey B, Baş CY, Alparslan AŞ, Koroğlu BK, Toslak İE, Çekiç B, Akhan O. Hepatic cystic echinococcosis: percutaneous treatment as an outpatient procedure. *Asian Pac J Trop Med.* 2014;7(3):212-5. DOI: 10.1016/S1995-7645(14)60023-7
  17. Bakdik S, Arslan S, Oncu F, Tolu I, Eryilmaz MA. Percutaneous treatment of hepatic cystic echinococcosis: the success of alcohol as a single endocavitary agent in PAIR, catheterization, and modified catheterization techniques. *Radiol Med.* 2018;123(2):153-60. DOI: 10.1007/s11547-017-0820-0
  18. Shrestha SK, Thapa PB, Maharjan DK, Tamang TY. Laparoscopic approach for management of hydatid cyst of liver. *J Nepal Health Res Council.* 2017;15(35):67-70. DOI: 10.3126/jnhrc.v15i1.18017 PMID: 28714495
  19. Zaharie F, Bartos D, Mocan L, Zaharie R, Iancu C, Tomus C. Open or laparoscopic treatment for hydatid disease of the liver? A 10-year single-institution experience. *Surg Endosc.* 2013;27(6):2110-6. DOI: 10.1007/s00464-012-2719-0
  20. Acharya H, Agrawal V, Tiwari A, Sharma D. Single-incision trocar-less endoscopic management of giant liver hydatid cyst in children. *J Minim Access Surg.* 2018;14(2):130-3. DOI: 10.4103/jmas.JMAS\_42\_17
  21. Jani K. Spillage-free laparoscopic management of hepatic hydatid disease using the hydatid trocar canula. *J Minim Access Surg.* 2014;10(3):113-8. DOI: 10.4103/0972-9941.134873 PMID: 25013326
  22. Duta C, Pantea S, Lazar C, Salim A, Barjica D. Minimally invasive treatment of liver hydatidosis. *JSLS: Journal of the Society of Laparoendoscopic Surgeons.* 2016;20(1):e2016.00002. DOI: 10.4293/JSLS.2016.00002 PMID: 27019575
  23. Sharafi SM, Sefiddashti RR, Sanei B, Yousefi M, Darani HY. Scolicidal agents for protoscolices of *Echinococcus granulosus* hydatid cyst: review of literature. *J Res Med Sci.* 2017;22:92. DOI: 10.4103/jrms.JRMS\_1030\_16 PMID: 28900448
  24. WHO Informal Working Group. International classification of ultrasound images in cystic echinococcosis for application in clinical and field epidemiological settings. *Acta Tropica.* 2003;85(2):253-61. DOI: 10.1016/S0001-706X(02)00223-1
  25. Gharbi HA, Hassine W, Brauner MW, Dupuch K. Ultrasound examination of the hydatid liver. *Radiology.* 1981;139(2):459-63. DOI: 10.1148/radiology.139.2.7220891

[GoogleScholar](#)