

## Surgical benefits of liver hanging maneuver for hepatectomy of huge liver tumor

Makoto Meguro<sup>1)</sup>, Toru Mizuguchi<sup>1)</sup>, Masaki Kawamoto<sup>1)</sup>  
Minoru Nagayama<sup>1)</sup>, Toshihiko Nishidate<sup>1)</sup>, Kenji Okita<sup>1)</sup>, Masafumi Imamura<sup>1)</sup>  
Takayuki Nobuoka<sup>1)</sup>, Yasutoshi Kimura<sup>1)</sup>, Hideyasu Takagi<sup>2)</sup>, Shigeru Sasaki<sup>2)</sup>  
Yutaka Kawano<sup>3)</sup>, Koji Miyanishi<sup>3)</sup>, Tomohisa Furuhashi<sup>1)</sup>  
Junji Kato<sup>3)</sup>, Yasuhisa Shinomura<sup>2)</sup>, Koichi Hirata<sup>1)</sup>

<sup>1)</sup>First Department of Surgery

<sup>2)</sup>First Department of Internal Medicine

<sup>3)</sup>Fourth Department of Internal Medicine

Sapporo Medical University School of Medicine, Sapporo, Japan

### ABSTRACT

**Background.** In hepatic surgery, it is very important to control bleeding during liver resection. However, in hepatectomy for a huge liver tumor it is often difficult to reduce bleeding volume and maintain an excellent surgical view. The anterior approach, which is hepatectomy done using the liver hanging maneuver, has beneficial effects reducing bleeding volume and preventing scattering of cancer cells from huge liver tumors. We investigated the surgical benefits of the liver hanging maneuver during hepatectomy for huge liver tumors in our department.

**Materials and Methods.** Between April 2003 and August 2008, we reviewed 182 patients who had to undergo liver resection in our department. The diagnoses of these patients were 114 cases of hepatocellular carcinoma, 48 of colorectal metastasis, 6 of echinococcus, 5 of hemangioma, 5 of cholangiocellular carcinoma, 2 of focal nodular hyperplasia, 1 of angiomyolipoma, and 1 of embryonal sarcoma. In the huge-tumor group, with tumor diameters of 10 cm or more, 20 patients underwent liver resection. In the small and medium-sized tumor groups, in which

the tumors were 5 cm or less and between 5 and 10 cm in diameter, respectively, 124 and 38 patients underwent liver resection, respectively. Twelve patients underwent right or left lobectomy in the huge-tumor group. Of these, 8 patients underwent liver resection using the hanging maneuver.

**Results.** The mean maximum tumor diameter, operation time, and amount of bleeding volume in the huge-tumor group were significantly larger, longer, and larger, respectively, than those of the small and medium groups. We found that the intraoperative bleeding volume of the group in which the hanging maneuver was used was significantly smaller than that of the group in which it was not for patients who underwent right or left lobectomy in the huge-tumor group.

**Conclusions.** The liver hanging maneuver is useful when liver tumors are 10 cm or more in diameter because it can reduce the intraoperative bleeding volume. However, the hanging maneuver must be conducted carefully to prevent bleeding in the retrohepatic IVC areas.

---

CORRESPONDENCE TO : Makoto Meguro, First Department of Surgery,  
Sapporo Medical University School of Medicine,  
South-1, West-16, Chuo-ku, Sapporo 060-8556, Japan  
e-mail : meguro@sapmed.ac.jp Tel. +81-11-611-2111 Fax. +81-11-613-1678

**Key words :** Huge liver tumor, Liver hanging maneuver, Hepatectomy

## INTRODUCTION

In hepatectomy for huge liver tumors, it is very difficult to operate because the surgical view cannot be maintained. Several reports<sup>1,2)</sup> showed that liver mobilization for huge liver tumors increases the risks for bleeding, tumor cell dissemination, and hemodynamic instability. The "anterior approach"<sup>3)</sup>, which was established by Lai *et al.*<sup>4)</sup>, is said to reduce these risks during liver mobilization. Furthermore, when a huge tumor exists in the liver, there is often congestion of hepatic veins due to pressure or obstruction by the huge tumor<sup>5,6)</sup>. Therefore, there is much blood loss during the hepatic transection, especially deeper parenchymal transection. It is reported that the liver hanging maneuver is useful in several types of major hepatectomy<sup>2)</sup>. The aim of this study was to investigate the surgical benefits of the hanging maneuver in patients with huge liver tumors treated in our de-

partment.

## METHODS

### Patients

We reviewed 182 patients with a mean age of 62.9 years (range: 22–86 years) who underwent liver resection at the First Department of Surgery, Sapporo Medical University School of Medicine, between April 2003 and August 2008. The clinicopathological features and surgical treatments of the 182 patients are summarized in Table 1. In the huge liver tumor group, in which tumor diameter was 10 cm or more, 20 patients with a mean age of 56.0 years (range: 29–79 years) underwent liver resection. In the small liver tumor group, in which tumor diameter was 5 cm or less, 124 patients with a mean age of 63.7 years (range: 34–86 years) had to undergo liver resection. In the medium-sized liver tumor group, in which tumor diameter was

**Table 1 Data for 182 patients who underwent liver resection**

	Maximum liver tumor diameter (cm)			P values
	Small-tumor group(< 5)	Medium-sized group(5-10)	Huge-tumor group(10 <)	
Numbers of patients	124	38	20	
Age, mean (range) (years)	63.7 (34–86)	64.0 (22–80)	56.0 (29–79)	N. S.
Sex, male : female	87 : 37	26 : 12	12 : 8	N. S.
Remnant liver				
NL : CH : LC	47 : 33 : 44	11 : 15 : 12	13 : 4 : 3	p<0.05
Diagnosis,				
HCC	82	23	9	N. S.
Colorectal metastasis	35	10	3	
Hemangioma	1	1	3	
Echinococcus	3	1	2	
CCC	2	2	1	
Angiomyolipoma	0	0	1	
Embryonal sarcoma	0	0	1	
FNH	1	1	0	
Type of liver resection (%)				
right lobectomy	6 (4.8%)	6 (15.8%)	9 (45.0%)	p<0.05
left lobectomy	3 (2.4%)	4 (10.5%)	3 (15.0%)	
right trisegmentectomy	1 (0.8%)	1 (2.6%)	2 (10.0%)	
left trisegmentectomy	1 (0.8%)	2 (5.3%)	0	
segmentectomy	32 (25.8%)	9 (24.7%)	6 (30.0%)	
subsegmentectomy	33 (26.6%)	6 (15.8%)	0	
partial hepatectomy	40 (32.3%)	10 (26.3)	0	
enucleation	8 (6.5%)	0	0	

Abbreviations : NL, normal liver ; CH, chronic hepatitis ; LC, liver cirrhosis ; HCC, hepatocellular carcinoma ; CCC, cholangiocellular carcinoma ; FNH, focal nodular hyperplasia ; N. S., not significant



between 5 and 10 cm, 38 patients with a mean age of 64.0 (range: 22–80 years) underwent liver resection (Table 1). Various types of liver tumors were diagnosed in the three groups. There were significantly more patients with normal liver tissue in the remnant liver of the huge tumor group than in the other groups ( $p < 0.05$ ) (Table 1). There were significantly more patients who received right or left lobectomy (60%) in the huge tumor group than in the other groups ( $p < 0.05$ ) (Table 1).

In the huge-tumor group 12 of the 20 patients had right or left lobectomy. Of these 12 patients, 8 underwent liver resection using the hanging maneuver (Table 2). There were no significant differences between the characteristics of the patients in the two groups (Table 2).

### Surgical procedures

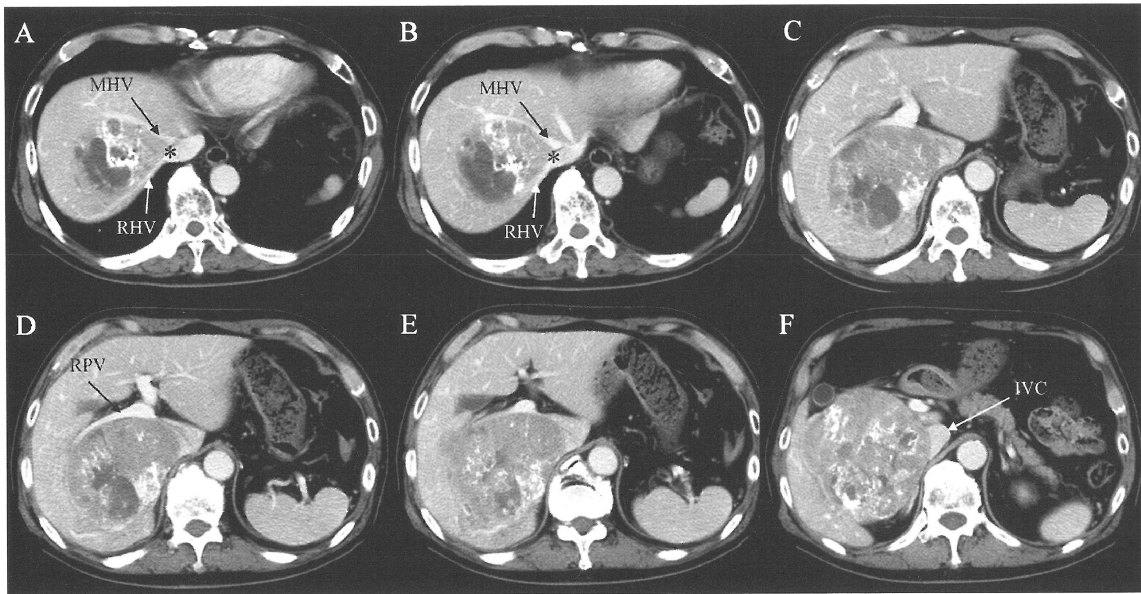
One example of a hepatectomy using the hanging maneuver is shown in Fig. 1–3. The maximum liver tumor diameter was about 12 cm in this patient. Abdominal enhanced computed tomography (CT) revealed that the huge liver tumor, which was diagnosed as hepatocel-

lular carcinoma (HCC), compressed and stretched the middle hepatic vein (MHV) to the left, right hepatic vein (RHV) to the back, and right portal vein (RPV) (Fig. 1). Based on a pre-operative examination, we thought that it would be difficult to resect the deep parenchymal tissue of the paracaval caudate lobe of the liver. Liver function was very good; the Child–Pugh grade was A, the liver-damage was grade A, and ICGR15 (indocyanin green retention at 15 min) was 8.9 %. We scheduled a right lobectomy preserving the MHV using the liver hanging maneuver. The liver was exposed through an abdominal incision using a contrary T- or L-shaped incision (Fig. 3A). The upper surface of the liver was exposed up to the anterior surface of the suprahepatic inferior vena cava (IVC) (Fig. 2A). The space between the right hepatic vein (RHV) and the middle hepatic vein (MHV) was dissected and moved 2 to 3 cm downwards with a right-angled vascular clamp. For caudal retrohepatic dissection, the caudal edge of the caudate lobe was lifted from the IVC, and small short hepatic veins were divided and ligated up to the level of the inferior RHV (Fig. 2C). The

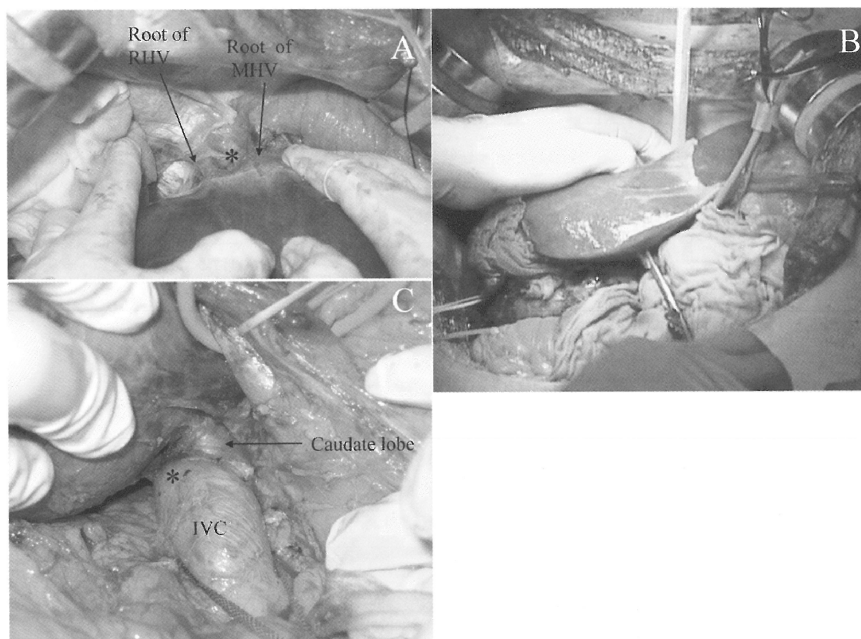
**Table 2** Data for patients who underwent right or left lobectomy in the huge group

	Hanging maneuver		P values
	(+)	(-)	
Numbers of patients	8	4	
Age, mean(range)(years)	59.5 (39–79)	58.0 (49–66)	N. S.
Sex, male : female	6 : 2	3 : 1	N. S.
Maximum tumor diameter, mean $\pm$ SD (cm)	13.1 $\pm$ 2.0	12.9 $\pm$ 2.2	N. S.
Operation time, mean $\pm$ SD (min)	569 $\pm$ 228	896 $\pm$ 525	N. S.
Remnant liver			
NL : CH : LC	6 : 1 : 1	3 : 0 : 1	N. S.
Diagnosis,			
HCC	4	1	N. S.
Colorectal metastasis	2	0	
Hemangioma	1	0	
Echinococcus	1	1	
CCC	0	1	
Angiomyolipoma	0	1	
Type of liver resection			
right lobectomy	6	3	N. S.
left lobectomy	2	1	

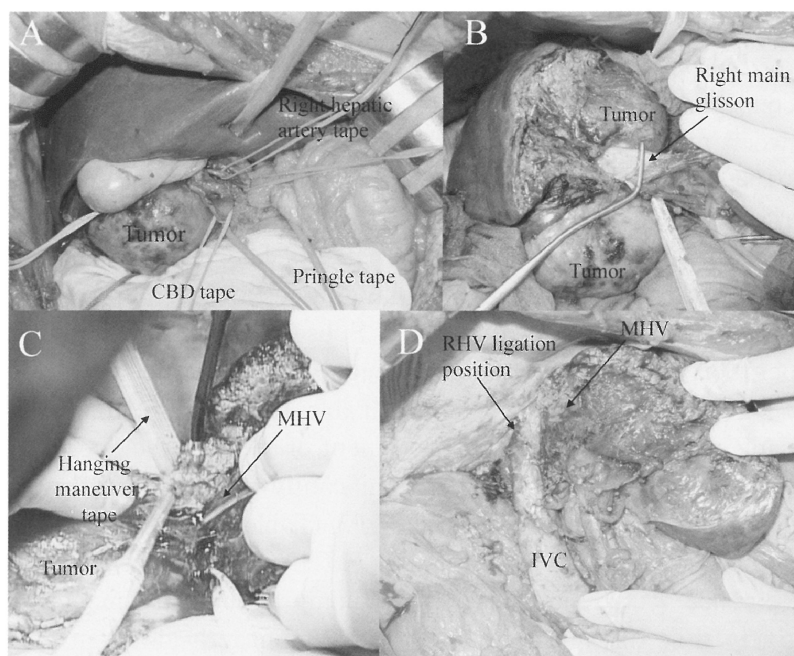
Abbreviations: NL, normal liver; CH, chronic hepatitis; LC, liver cirrhosis; HCC, hepatocellular carcinoma; CCC, cholangiocellular carcinoma; FNH, focal nodular hyperplasia; N.S., not significant; SD, standard deviation

**Fig. 1**

A and B, a liver huge tumor exists between the middle hepatic vein (MHV) and right hepatic vein (RHV), and presses and stretches these hepatic veins. \* is the anterior surface of the inferior vena cava (IVC) between the 10 and 11 o'clock positions. C-F, the liver huge tumor presses the right portal vein (RPV) and IVC, and exists in an extrahepatic projection.

**Fig. 2**

A, the upper surface of the liver is exposed up to the anterior surface of the suprahepatic inferior vena cava (IVC). The space (\*) between the root of the right hepatic vein (RHV) and the root of the middle hepatic vein (MHV) is dissected and moved 2 to 3 cm downwards with a right-angled vascular clamp. B, a 6-mm-wide soft Penrose drain is grasped with the clamp and pulled down through the retrohepatic space for the hanging maneuver. C, for caudal retrohepatic dissection, the caudal edge of the caudate lobe is lifted from the IVC, and small short hepatic veins are divided and ligated up to the level of the inferior RHV. \* is the space of the IVC between the 10 and 11 o'clock positions for the hanging maneuver. To reduce the risk of bleeding during the hanging maneuver, we controlled the infrahepatic IVC with tape.

**Fig. 3**

A, the liver is exposed through an abdominal incision using a contrary T-shaped incision. The tapes dividing and controlling the hepatic pedicle for the Pringle maneuver, common bile duct, right portal vein and right hepatic artery, respectively, are shown. B, During liver resection, we transected the right main glisson. C, we suspended the drain tape during the hepatic transection. This liver hanging maneuver technique helps to reduce hepatic venous backflow bleeding, especially with deeper parenchymal transection. D, right lobectomy of the liver preserving the patency of the middle hepatic vein (MHV) and inferior vena cava (IVC).

right-angled vascular clamp was inserted behind the caudate lobe just to the left of the RHV and passed cranially along the anterior surface of the IVC between the 10 and 11 o'clock positions (\* in Fig. 1A and B, Fig. 2A and 2C), by carefully opening and closing the clamp, toward the previously dissected space between the RHV and MHV until the clamp tip reached the suprahepatic space. Normally, we can perform retrohepatic dissection without encountering any resistance. When adhesion or pressure between the IVC and liver is severe due to previous surgery or inflammation and the huge tumor in the caudal part of the retrohepatic IVC causes resistance to the dissection, the retrohepatic dissection is discontinued. A 6-mm-wide soft Penrose drain was grasped with our clamp and pulled down through the retrohepatic space (Fig. 2B). We usually perform hepatic parenchymal transection with intermittent clamping of the hepatic pedicle (Pringle maneuver<sup>7)</sup> via irri-

gated monopolar coagulation using Dissecting Sealer 3.5c<sup>®</sup> (TissueLink Medical, USA) and an ultrasonic surgical aspirator (CUSA EXcel<sup>™</sup>) (Integra LifeSciences Corporation, USA). We suspended the drain tape during the hepatic transection (Fig. 3C). This liver hanging maneuver technique helps to reduce venous back flow bleeding, especially during deeper parenchymal transection (Fig. 3C). Before the liver resection, we performed dissection of a coronary and triangle ligament of the liver. However, it is very difficult to obtain a view for the dissection of these ligaments because a huge tumor prevents a surgical view. We often perform the parenchymal transection before the dissection of these ligaments in the case of a huge tumor.

#### Statistical Analysis

Data are expressed in the form of mean  $\pm$  standard deviation (SD). Comparisons were performed using the Kruskal Wallis test and the

unpaired Student's *t*-test. Statistical analysis was performed using the StatView 5.0 software package (Abacus Concepts, Inc., Berkeley, CA). The difference between means was considered significant when  $p < 0.05$ .

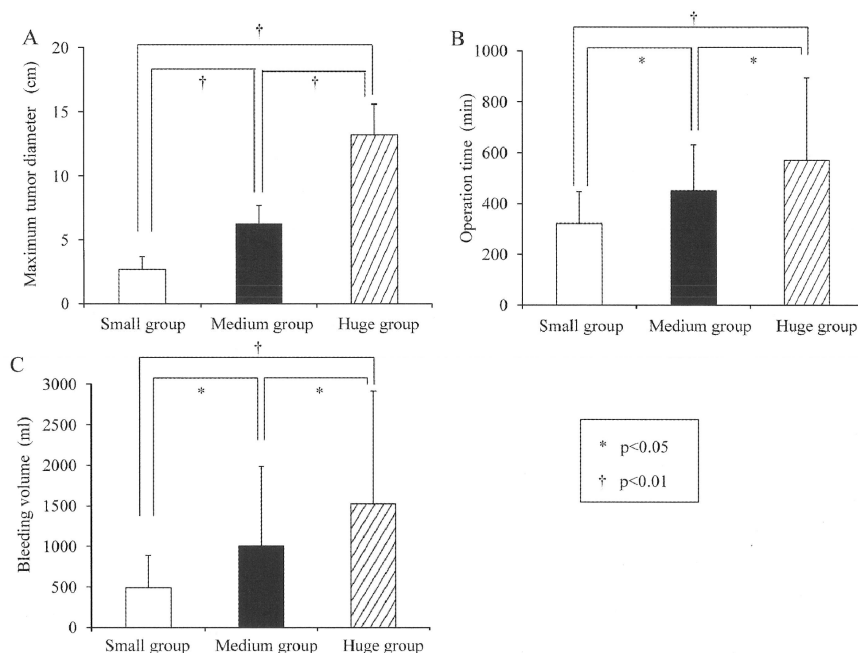
## RESULTS

In the 20 patients of the huge-tumor group, the mean  $\pm$  standard deviation (SD) maximum tumor diameter, operation time, and amount of bleeding were  $13.2 \pm 2.4$  cm,  $571 \pm 323$  min, and  $1,524 \pm 1,390$  ml, respectively (Fig. 4). In the 124 patients of the small-tumor group, the mean  $\pm$  standard deviation (SD) maximum tumor diameter, operation time, and amount of bleeding were  $2.7 \pm 1.0$  cm,  $322 \pm 126$  min, and  $489 \pm 399$  ml, respectively (Fig. 4). In the 38 patients of the medium-sized tumor group, the mean  $\pm$  standard deviation (SD) maximum tumor diameter, operation time, and amount of bleeding were  $6.3 \pm 1.4$  cm,  $450 \pm 181$  min, and  $1,003 \pm 984$  ml, respectively (Fig. 4). The mean maxi-

um tumor diameter, operation time, and amount of bleeding in the huge-tumor group were significantly larger ( $p < 0.01$ ), longer ( $p < 0.01$  and  $p < 0.05$ ), and larger ( $p < 0.05$  and  $p < 0.01$ ), respectively, than in the small and medium groups (Fig. 4). Furthermore, significantly fewer patients had cirrhosis in the remnant liver in the huge tumor group than in the other groups.

Subsegmentectomy and partial hepatectomy were not performed in the huge-tumor group (Table 1). Major hepatectomy in which a bisegment or more of the liver was resected was significantly frequent in the huge-tumor group ( $p < 0.05$ ) (Table 1).

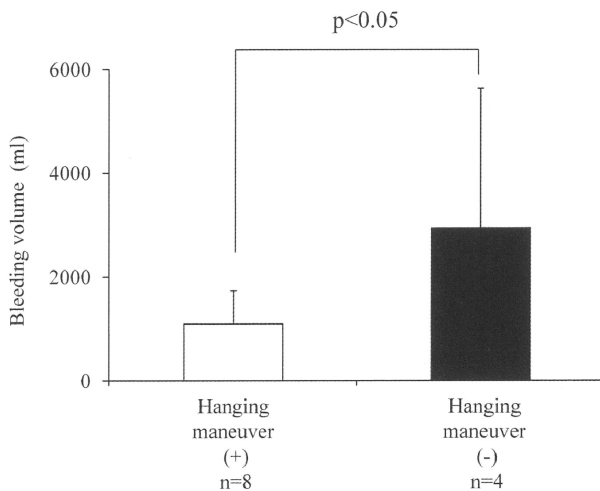
The characteristics of the patients for whom the hanging maneuver was used were not significantly different from those for whom it was not among the patients who underwent right or left lobectomy in the huge-tumor group (Table 2). However, we found that the intraoperative bleeding volume ( $1,094 \pm 636$  ml) of the group with the hanging maneuver was signifi-



**Fig. 4**

Mean maximum tumor diameter (A), operation time (B), and bleeding volume (C) in the huge-tumor group were larger ( $p < 0.01$ ), longer ( $p < 0.01$  and  $p < 0.05$ ), and larger, respectively ( $p < 0.05$  and  $p < 0.01$ ) than those of the small and median groups. Furthermore, the mean maximum tumor diameter (A), operation time (B), and bleeding volume (C) in the medium-sized tumor group were larger ( $p < 0.01$ ), longer ( $p < 0.05$ ), and larger, respectively ( $p < 0.05$ ), than those of the small group.

cantly less than that ( $2,950 \pm 2,683$  ml) of the group without the hanging maneuver ( $p < 0.05$ ) (Fig. 5).



**Fig. 5**

Intraoperative bleeding volume in the group ( $n=8$ ) with the hanging maneuver was significantly smaller than that in the group ( $n=4$ ) without the hanging maneuver for the 12 of the 20 patients in the huge-tumor group patients who underwent right or left lobectomy ( $p < 0.05$ ).

## DISCUSSION

In hepatic surgery, it has been thought that smaller liver tumors are easier to resect than larger ones. When a huge tumor exists in the liver, there are many bleeding points because such huge tumors are near the main glissons<sup>8</sup> and hepatic veins<sup>9</sup>. Furthermore, huge liver tumors are already advanced, including the existence of satellite nodules or macrovascular invasion<sup>10</sup>. There are several reports<sup>11,11)</sup> that patients who have liver tumors greater than 10 cm in diameter have a poor prognosis. Thus, we considered that a huge liver tumor was one 10 cm or more in diameter and evaluated the characteristics of the patients in the huge liver tumor group. In our study, the intraoperative bleeding volume was gradually larger the larger the size of the liver tumor (Fig. 4B). It is very important to limit intraoperative bleeding volume in the huge liver tumor group.

We usually try to do a liver hanging maneuver in all patients with huge liver tumors. However, the hanging maneuver was used only for only 8 of the 12 patients (66.7%) who underwent successful right or left lobectomy of the liver. Ogata et al.<sup>2)</sup> reported that the success rate with the hanging maneuver was 88.1% in 241 patients for whom major hepatectomy was performed. It was found that the hanging maneuver was very difficult when the liver tumors were huge. However, the intraoperative bleeding volume in the group in which the hanging maneuver was possible was smaller than that in the group for which it was not. On the other hand, the intraoperative bleeding volume in the group with tumors 10 cm or less in diameter was not significantly different from that in liver resection with or without the hanging maneuver (data not shown). Thus we think that there are some surgical benefits of trying to perform the hanging maneuver when the liver tumors are huge ones.

There are some reports about modified methods of conducting the liver hanging maneuver. The hanging maneuver is performed blind, with a risk of damaging the small retrohepatic veins. To overcome this problem, instead of performing blind dissection using a long vascular clamp, a flexible choledochoscope<sup>12)</sup>, ultrasonically assisted method<sup>13)</sup>, and a secure technique utilizing a surgical probe<sup>14)</sup> are used to dissect the retrohepatic space filled by loose alveolar tissue anterior to the IVC. We often perform the hanging maneuver by means of blind dissection using a vascular clamp. We think that our rate of success with the hanging maneuver has been increased by trying these safer methods.

In conclusion, the liver hanging maneuver is useful when liver tumors are 10 cm or more in diameter because it can reduce the intraoperative bleeding volume. However, the hanging maneuver must be carefully conducted to prevent bleeding in the retrohepatic IVC areas.

## REFERENCES

1. Lee SG, Hwang S, Jung JP, Lee YJ, Kim KH, Ahn CS. Outcome of patients with huge hepatocellular carcinoma after primary resection and treatment of recurrent lesions. *Br J Surg* 2007; 94: 320-326.
2. Ogata S, Belghiti J, Varma D, Sommacale D, Maeda A, Dondero F, Sauvanet A. Two hundred liver hanging maneuvers for major hepatectomy: a single-center experience. *Ann Surg* 2007; 245: 31-35.
3. Suzuki M, Unno M, Katayose Y, Takeuchi H, Rikiyama T, Onogawa T, Sato T, Mizuma M, Ohtuka H, Mastuno S. Hepatic resection through an anterior approach employing a modified liver hanging maneuver in patients with a massive liver tumor severely oppressing the inferior vena cava. *Hepatogastroenterology* 2004; 51: 1459-1463.
4. Lai EC, Fan ST, Lo CM, Chu KM, Liu CL. Anterior approach for difficult major right hepatectomy. *World J Surg* 1996; 20: 314-317.
5. Chen XP, Qiu FZ, Wu ZD, Zhang BX. Hepatectomy for huge hepatocellular carcinoma in 634 cases. *World J Gastroenterol* 2006; 12: 4652-4655.
6. Chen XP, Qiu FZ, Wu ZD, Zhang BX. Chinese experience with hepatectomy for huge hepatocellular carcinoma. *Br J Surg* 2004; 91: 322-326.
7. Pringle JH. V. Notes on the arrest of hepatic hemorrhage due to trauma. *Ann Surg* 1908; 48: 541-549.
8. Dong Q, Jiang B, Lu Y, Zhang H, Jiang Z, Lu H, Yang C, Zhao J, Hao X. Surgical management of giant liver tumor involving the hepatic hilum of children. *World J Surg* 2009; 33: 1520-1525.
9. Hamady ZZ, Malik HZ, Finch R, Adair R, Al-Mukhtar A, Prasad KR, Toogood GJ, Lodge JP. Hepatic resection for colorectal metastasis: impact of tumour size. *Ann Surg Oncol* 2006; 13: 1493-1499.
10. Pawlik TM, Delman KA, Vauthey JN, Nagorney DM, Ng IO, Ikai I, Yamaoka Y, Belghiti J, Lauwers GY, Poon RT, Abdalla EK. Tumor size predicts vascular invasion and histologic grade: Implications for selection of surgical treatment for hepatocellular carcinoma. *Liver Transpl* 2005; 11: 1086-1092.
11. Ng KK, Vauthey JN, Pawlik TM, Lauwers GY, Regimbeau JM, Belghiti J, Ikai I, Yamaoka Y, Curley SA, Nagorney DM, Ng IO, Fan ST, Poon RT. Is hepatic resection for large or multinodular hepatocellular carcinoma justified? Results from a multi-institutional database. *Ann Surg Oncol* 2005; 12: 364-373.
12. Lai PB, Wong J, Ng WW, Lee WL, Cheung YS, Tsang YY, Lee KF. Safe modification of the liver-hanging maneuver by endoscopic-assisted dissection of the retrohepatic tunnel. *Surg Today* 2007; 37: 915-917.
13. Kokudo N, Imamura H, Sano K, Zhang K, Hasegawa K, Sugawara Y, Makuuchi M. Ultrasonically assisted retrohepatic dissection for a liver hanging maneuver. *Ann Surg* 2005; 242: 651-654.
14. Takatsuki M, Eguchi S, Hidaka M, Tajima Y, Kanematsu T. A secure taping technique for a liver hanging maneuver using a surgical probe. *Surg Today* 2008; 38: 1155-1156.

(Accepted for publication, Jan. 15, 2010)