

Biomédica 2002;22:287-95

## REVISION DE TEMA

## Viral hemorrhagic fevers of South America

Robert B. Tesh

Department of Pathology and Center for Tropical Diseases, University of Texas Medical Branch, Galveston, Texas, USA.

This paper reviews the epidemiology and distinguishing features of three viral hemorrhagic fevers (dengue hemorrhagic fever, yellow fever and arenaviral hemorrhagic fever) that have emerged as important public health problems in South America. Although the etiology, natural history and control of the three diseases are different, their clinical manifestations and histopathology findings are similar and can be difficult to differentiate. Consequently, early recognition and correct diagnosis are essential for effective control measures to be initiated.

**Key words:** viral hemorrhagic fever, dengue, yellow fever, epidemiology, clinical pathology, arbovirus diseases.

### Fiebres virales hemorrágicas en Suramérica

El artículo revisa la epidemiología y rasgos distintivos de tres fiebres virales hemorrágicas (dengue hemorrágico, fiebre amarilla y fiebre hemorrágica por arenavirus), que han emergido como serios problemas de salud pública en Suramérica. Aunque la etiología, la historia natural y el control de estas tres enfermedades difieren, sus manifestaciones clínicas y los hallazgos histopatológicos son similares y pueden ser difíciles de diferenciar. En consecuencia, la detección temprana y el diagnóstico correcto son esenciales para la aplicación de medidas de control.

**Palabras clave:** fiebre viral hemorrágica, dengue, fiebre amarilla, epidemiología, patología clínica, enfermedades por arbovirus.

During the last several decades, three viral hemorrhagic fevers have emerged as important public health problems in South America: dengue hemorrhagic fever, yellow fever and arenaviral hemorrhagic fever. Although the causative agents, epidemiology and control of these diseases are quite different, their clinical manifestations and histopathological findings are often similar and difficult to differentiate. Thus, correct diagnosis and early recognition are essential for effective control measures to be initiated. The emergence of these hemorrhagic diseases in the region has resulted in part from changing health priorities, human migration, population growth and urbanization, and changing land use patterns. In this review, the epidemiology

of the three hemorrhagic fevers will be reviewed as well as their distinguishing features and causes.

### Dengue hemorrhagic fever

Dengue is a mosquito-transmitted viral disease which is now common in tropical and subtropical regions of South America (1,2). The disease exists in two clinical forms: classical dengue fever (CDF) and dengue hemorrhagic fever/dengue shock syndrome (DHF). There are four dengue virus serotypes, designated dengue 1, 2, 3 and 4. All are members of the genus *Flavivirus*, family *Flaviridae*. Infection with one dengue virus serotype provides lifelong protection to the homologous serotype, but not to the other three heterologous dengue serotypes. Consequently, people can have dengue several times in their life, if they are infected with different dengue virus serotypes. Each of the four dengue virus serotypes can produce CDF and DHF. The

---

Correspondencia:

Center for Tropical Diseases, Keiller Building 1.116, 301 University Boulevard, Galveston, Texas, 77555-0609; tel. (409) 747 2431; fax (409) 747 2429; rtesh@utmb.edu

Recibido: 20/06/02; aceptado: 23/08/02

frequency of DHF in persons infected with dengue virus is relatively low (~1:2,000); but considering the total number of persons in the world who are infected with dengue viruses each year (estimated >100 million), DHF has become a major public health problem. The reasons why some dengue virus infections result in DHF, but most do not, is still uncertain. Various risk factors have been proposed to explain the development of DHF; these include prior infection with other dengue virus serotypes, immune enhancement, virulence of the infecting dengue virus genotype, and host factors (1,3,4).

In the Americas, dengue viruses are transmitted mainly by *Aedes aegypti* mosquitoes. The *A. aegypti* mosquito is peridomestic and breeds in artificial containers in and around human dwellings. In addition, this mosquito preferentially feeds on humans, which is one reason why it is such an efficient disease vector. The recent emergence of DHF in South America can be explained in large part by the reintroduction of this vector into areas previously free of the mosquito, and by human migration, population growth and urbanization which have created conditions for enhanced breeding of *A. aegypti* (1,2).

Figure 1 shows the distribution of *A. aegypti* in the Americas in 1930, in 1970 and in 1998. During the 1930s, the vector was widely distributed in cities and towns in tropical America. Then, during the 1940s and 1950s, the Pan American Health Organization began an ambitious *A. aegypti* eradication program which was originally designed to permanently eliminate urban yellow fever from the region. This eradication program was quite successful, and by 1970, the mosquito had been eliminated from most countries in South America. The elimination of *A. aegypti* also stopped dengue virus transmission in areas free of the vector. However, during the 1970s, support for mosquito surveillance and control programs decreased and many countries were reinfested with *A. aegypti*. This mosquito has now returned to its original distribution in South America.

Because dengue fever and DHF are now common in tropical America, these diseases are often over-diagnosed; consequently, many non-specific febrile illnesses and hemorrhagic diseases are incorrectly diagnosed as 'dengue fever' and 'DHF', respectively. Various studies have demonstrated that the clinical diagnosis of dengue is not very accurate (5,6). But, the laboratory confirmation

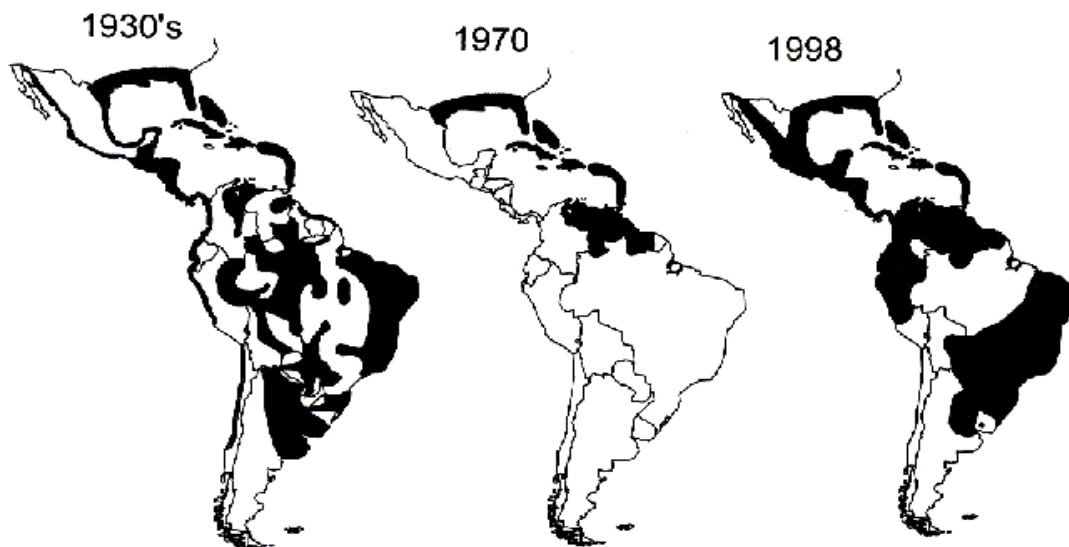


Figure 1. Distribution of *Aedes aegypti* in 1930, in 1970 and in 1998 (1).

of DHF may also be difficult, because it is often not possible to isolate dengue virus from cases of DHF and the results of serologic tests on patients with multiple dengue virus infections are not easy to interpret. Furthermore, the laboratory and histopathologic findings in patients with DHF can mimic those of severe cases of yellow fever (YF) and arenaviral hemorrhagic fever (AHF). All three of these diseases can produce leukopenia, thrombocytopenia, elevated serum transaminase levels, liver necrosis, and Councilman bodies (eosinophilic depositions in hepatocytes) (7-17). This is an important consideration, since correct diagnosis and early recognition of any of these diseases is essential for their treatment, as well as for the appropriate public health response.

### Yellow fever

Yellow fever (YF) remains an important cause of morbidity and mortality in South America. During the 10-year period from 1986 to 1995, the Pan American Health Organization reported a total of 2,022 cases of YF from the region (18). Figure 2 shows the number of officially reported YF cases in South America during that 10-year period by country. Undoubtedly, these are underestimates, since milder cases of the disease are not recognized or reported. Based on the high case-fatality rates in South America, Monath has estimated that the true incidence of the disease in the continent is actually 5-10 times higher (18).

Like dengue, YF is caused by another mosquito-transmitted flavivirus, the yellow fever virus. The virus has two distinct cycles in South America: 1) an endemic or sylvan cycle, thought to involve monkeys and tree-hole breeding forest mosquitoes of the genera *Haemagogus* and *Sabethes*; and 2) an epidemic or urban cycle, involving humans and the domestic mosquito vector, *A. aegypti* (19). In fact, it was Jorge Boshell Manrique who first demonstrated where *Haemagogus* mosquitoes lived in the forest canopy and that they were the principal vectors of sylvan YF in the Americas (20).

During the 17th., 18th. and 19th. centuries, YF caused major urban epidemics in Africa, European port cities and the Americas (19). The literature suggests that the mortality rate in natural

YF infection is in the range of 20-25%. YF, and fear of the disease, played an important role in the settlement and commerce of the New World during that period. Two years ago, at the International Congress of Tropical Medicine, Dr. Hernando Groot gave an interesting historical account of how an outbreak of YF decimated the attacking forces of the English pirate Henry Morgan, and saved Cartagena from capture. There is just one example of how YF influenced development and commerce in the New World.

Because of the high mortality resulting from urban YF epidemics in the Americas and the success of United States' efforts in controlling the disease in Cuba and Panama by sanitation and vector control, the Brazilian Government began a nationwide campaign to eradicate *A. aegypti* in the 1930s (19). The early success of that program and the introduction of DDT led the Pan American Sanitary Bureau to initiate the hemisphere-wide *A. aegypti* eradication campaign mentioned before. Between 1947 and 1972, this mosquito was eliminated from Central America and most of South America, and urban YF disappeared. The

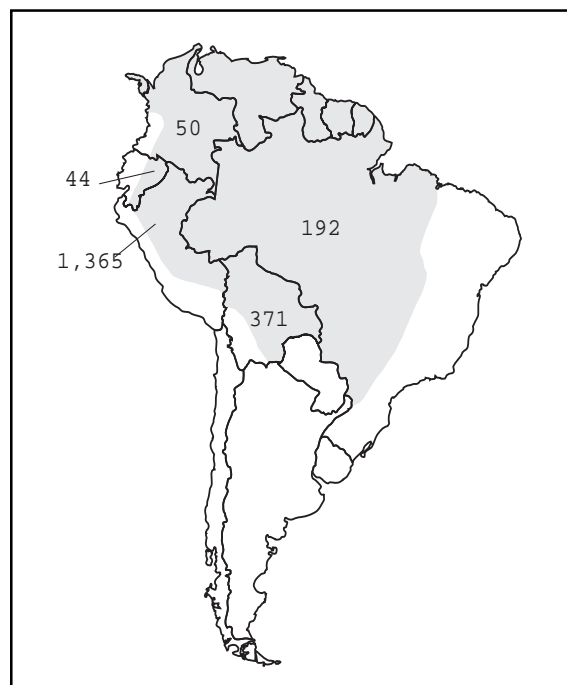


Figure 2. Distribution of officially reported yellow fever cases by country during the decade, 1986-1995 (18).

last documented *A. aegypti*-associated epidemic of YF occurred in Acre State in the Brazilian Amazon in 1942 (19).

The development of an effective, inexpensive vaccine also played an important role in elimination of the urban YF from the Americas. The 17D YF vaccine was first used in Brazil in 1937; and during the next 30 years, many millions of persons throughout the Americas received the vaccine (19). However, following the eradication of *A. aegypti* and the disappearance of urban YF, many South American countries stopped mass vaccination campaigns. The current policy in most countries of the region is to wait for the appearance of sylvan cases, and then to vaccinate around them in order to contain the outbreak and prevent spread to urban areas.

Ironically, during the last 25 years as many South American countries discontinued or de-emphasized YF vaccination campaigns, the urban YF vector *A. aegypti* was reinfesting the same countries. The mosquito now occupies its pre-eradication geographic distribution in the Americas (figure 1). The reemergence of dengue and DHF in South America during the past two decades attests to the current widespread distribution and abundance of *A. aegypti* in the hemisphere (22). Dengue also is now endemic in many cities in the Amazon Basin, such as Belem and Manaus in northern Brazil; Iquitos, Tarapoto and Pulcalpa in eastern Perú, and Santa Cruz in eastern Bolivia demonstrating that *A. aegypti* now exists in close proximity to areas where sylvan YF occurs. The continued presence of sylvan YF in South America constitutes a real threat as a source of introduction into the urban environment (23). Given the continuing encroachment of people into the sylvan habitat of YF fever virus, it would seem inevitable that the virus will eventually be introduced into an urban community and that epidemic YF will reappear.

Two recent outbreaks in Perú and Bolivia illustrate the potential danger of YF being introduced into urban areas. Ten or 15 years ago, when the Sendero Luminoso (Shining Path) terrorist group was active in the Andean foothills of eastern Perú, many civilians fled the region. After the defeat of

the Sendero Luminoso group in the early 1990's, people began to move back into the region and to reclaim their land. Thousands of contract workers were recruited from impoverished highland communities and brought to work clearing land in the jungle. Most of these people had never been vaccinated against YF. In 1995, Perú reported more than 500 cases of YF; most of these cases were among contracted workers from the highlands. A similar scenario could occur in Colombia, when peace finally comes to the nation and people begin to return to rural areas where sylvan YF is still present.

Actually, a small urban outbreak of YF occurred recently in Santa Cruz, Bolivia. In the early 1990's, the Bolivian government privatized most of the mines in the highlands. With privatization, many non-productive mines were closed, and massive unemployment among miners resulted. Many of these workers and their families moved to lowland areas where more jobs were available. Some of these people settled in Santa Cruz where they established 'colonias' around the city. They found work as agricultural workers on surrounding farms in a region where YF is endemic. Between December 1998 and June 1999, 6 cases of YF (5 fatal) were reported among residents of Santa Cruz, now a city of about one million inhabitants (24). At the time of this outbreak, dengue was endemic in Santa Cruz, *A. aegypti* mosquitoes were abundant, and the level of YF immunity among the resident population of the city was only about 30%. Fortunately, the YF cases were recognized early, and a mass vaccination campaign and *A. aegypti* control program were rapidly initiated by local authorities. A major epidemic of urban YF was probably averted. But this situation illustrates the danger of the introduction of YF into an urban area where dengue occurs, and the difficulty in differentiating DHF from YF initially.

Clinically, the two diseases may be similar: acutely ill patients with fever, leukopenia and hemorrhagic manifestations (7-13). Although YF patients often have icterus, this is not always obvious in people with dark skin. The histopathological diagnosis of YF is also sometimes difficult, unless special staining procedures are used. Typically in fatal cases of YF, one sees midzonal hepatocyte necrosis, microvesicular steatosis, pyknotic

nuclei, and acidophilic or eosinophilic depositions within the cytoplasmic of dying liver cells (figure 3). These eosinophilic depositions or so-called Councilman bodies were once thought to be diagnostic of YF; but it is now known that Councilman-like bodies can be seen in a number of diseases where liver cell necrosis or apoptosis occurs. This includes DHF (8,9) and AHF (14-17).

We have recently developed a new hamster model of fulminant YF, which shows many of the clinical and pathologic features of the severe disease in humans (12,21). After infection, hamsters develop a high YF viremia that peaks on day 3 and that lasts 5 or 6 days (21). Antibodies (hemagglutination inhibition and IgM) first appear between day 4 and 5. About 20% of adult hamsters die from YF infection; death usually occurs in the animals on day 5 or 6, as in severe human cases of the disease. These animals also have elevated serum transaminase and bilirubin levels (21).

#### **Arenaviral hemorrhagic fevers**

To date, a total of 17 different indigenous arenaviruses have been identified in the Americas (25-27). Most of the New World arenaviruses occur in South America. In general, they have a rather restricted geographic distribution; and most of the viruses are associated with a single vertebrate species, usually a rodent (25-27). The natural rodent reservoirs of arenaviruses usually develop a persistent infection and continuously shed virus in their urine, feces and saliva (25,28). Human infection is thought to result primarily from inhalation of aerosols of infected rodent excreta, although venereal transmission and nosocomial infections have also been reported (16,25).

Four of the South American arenaviruses have been associated with severe hemorrhagic disease (AHF) in humans (25). Each of these arenaviruses is associated with a disease of a different name: Junin virus with Argentine hemorrhagic fever (AgtHF); Machupo virus with Bolivian hemorrhagic fever (BHF); Guanarito virus with Venezuelan hemorrhagic fever (VHF), and Sabia virus with Brazilian or Sao Paulo hemorrhagic fever. In reality, the clinical manifestations and laboratory findings in the four diseases are indistinguishable. After an incubation period of 7-14 days, AHF begins

insidiously with progressive development of fever, chills, malaise, anorexia, myalgia and sore throat (16,25,29). During the first 3-5 days, the signs and symptoms are indistinguishable from a variety of other non-specific viral and bacterial illnesses. As the disease progresses, patients develop weakness, arthralgia, back pain, nausea, vomiting, epigastric pain, dizziness, conjunctivitis, flushed face and bleeding gums. By the 6th. or 7th. day, the patients are usually acutely ill with dehydration, disorientation and frequently hemorrhagic and/or neurological manifestations. If death occurs, it usually results from massive hemorrhage and/or shock. If the patient survives this period, improvement begins about the 10th. or 12th. day and a slow convalescence ensues. The mortality rates in patients with untreated AHF range from about 10 to 33%. Mortality rates of AHF decrease with early hospitalization and intensive supportive care, including immune human plasma or the antiviral drug ribavirin (16).

The frequency of the South American AHFs vary widely, and less is known about their epidemiology than is known about DHF and YF. To date, only 4 cases of Sao Paulo hemorrhagic fever have been reported; two natural cases and two accidental infections among laboratory personnel working with Sabia virus (25).

The first documented outbreak of BHF occurred between 1962 and 1964 in the town of San Joaquín in the Beni department of northeastern Bolivia (16,25). About 1,000 human cases occurred during that initial outbreak. Since that time, only sporadic cases of BHF have been reported. However, cases still do occur; we made an isolate of Machupo virus from a human case of BHF last year.

The two AHFs that have been most thoroughly studied are (AgtHF) and VHF. AgtHF was first recognized as a distinct entity during the 1950s in an agricultural region north of Buenos Aires (25). From 1958 to 1994, more than 24,000 human cases were reported with annual totals ranging from 200-3,000 cases (25). AgtHF affects mostly adult male agricultural workers. Cases of the disease occur mainly during the harvest season, with a peak incidence in May. Since the

introduction of the Candid-1 vaccine in 1991, the annual incidence of the disease has decreased dramatically (25).

VHF was first recognized in 1989 in an agricultural region of Portuguesa state (29). Between September 1989 and August 1998, more than 200 cases of VHF were reported. The disease has occurred in a sporadic cyclical manner; cases have been reported in every month of the year, but the majority have occurred in the months of November, December and January (29). This period corresponds with the end of the rainy season and beginning of the dry season in the endemic region, and it is a period of intense agricultural activity. During the past dry season (November 2001- January 2002), another 30 cases of the disease were reported. Like the pattern observed with AgtHF, VHF occurs mainly among adult male agricultural workers, suggesting that infection occurs outside of the home in rodent-infested fields and grasslands (29).

One of the interesting questions about VHF is why were cases not recognized until 1989. The answer seems largely related to human migration and land use patterns in the affected region. During the period from 1985-2000, there was a major movement of people into the llanos of Venezuela, especially Portuguesa and Barinas states. Much of this land was originally forested; but with development, the forest was removed and was replaced by agricultural fields and pastures (25,30). This ecologic change provided increased habitat for certain grassland rodents, one being *Zygodontomys brevicauda*, the reservoir of Guanarito virus. Thus, there were increased numbers of infected rodents, and increased numbers of susceptible people living in the same region. A similar pattern was observed in Argentina when intensive agriculture (soy beans and corn) was developed in the Pampa region where AgtHF now occurs (16,25,31). Cultivated fields and the surrounding grasslands provided habitat for the rodent reservoirs of Junin virus (31). The arenaviruses are very old and probably evolved with their rodent hosts; but when people change the ecology, allowing an increase in the abundance of the rodent hosts, the risk of human-virus contact increases (25).

As noted before, the initial clinical manifestations of AHF are indistinguishable from a variety of other non-specific viral and bacterial illnesses (16,25). In fact, the first two isolates of Guanarito virus were made from fatal cases initially diagnosed as DHF (29). Table 1 shows the clinical diagnosis of 56 confirmed VHF cases at the time of the patients' hospitalization (25). Despite the relative frequency of VHF in the endemic region, it is a difficult diagnosis to make. Patients with VHF appear at a clinic or hospital with a 4-5 day history of progressively severe febrile illness; they usually have leukopenia and thrombocytopenia, and sometimes hemorrhagic manifestations are present. Laboratory studies may indicate elevated serum transaminase levels. But, at this point, the illness cannot be differentiated from DHF or YF.

Despite the severity of the illness, patients dying of AHF show surprisingly little pathology. The most consistent findings at autopsy are in the liver and have been described as multifocal hepatocytic necrosis, usually without significant inflammatory reaction (14,32,33). Focal hepatocyte necrosis can be seen as well as Councilman bodies. We recently described a hamster model of AHF, using Pirital virus. Hamsters inoculated with Pirital virus develop a progressively severe, fatal illness of about 7 days duration; the pathologic features are similar to those observed in fatal human cases of AHF (17). Figure 4 shows a H&E stained section of liver from a hamster experimentally infected with Pirital virus.

**Table 1.** Clinical diagnoses in 56 confirmed cases of Venezuelan hemorrhagic fever at time of patients' hospitalization.

Diagnosis	No. of confirmed cases of VHF
Viral syndrome	16
Classic dengue fever	11
No diagnosis	7
Venezuelan hemorrhagic fever	6
Hemorrhagic virosis	5
Dengue hemorrhagic fever	4
Tonsillitis/pharyngitis	2
Convulsive syndrome	1
Bronchopneumonia	1
Gastrointestinal hemorrhage	1
Sepsis	1
Febrile syndrome	1

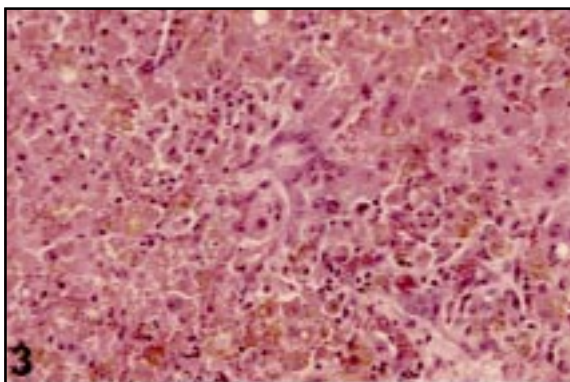


Seven days after infection focal hepatocytic necrosis can be seen with scattered acidophilic bodies.

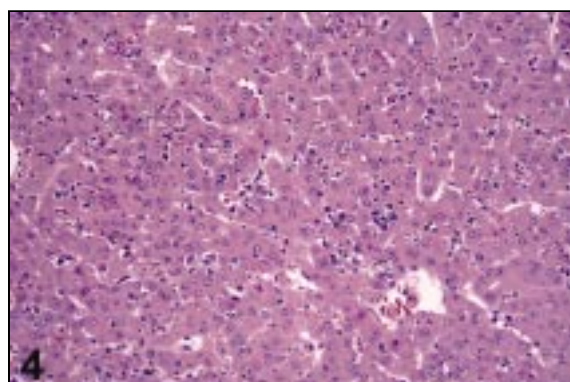
Because of the non-specific nature and high mortality of viral hemorrhagic fever, the diagnosis and etiology are often not determined until autopsy. As noted before, the major pathology observed at necropsy in cases of DHF, YF and AHF is in the liver. However, using a standard H&E stain, it is difficult to determine the precise etiology. Figure 3 shows a liver section from a fatal case of presumed viral hemorrhagic fever in Ecuador. It would be difficult for a pathologist to say with certainty whether this person died of DHF, YF or AHF. Furthermore, culture of the affected tissues may not be much more helpful.

Dengue and YF viruses are infrequently cultured from tissues at the time of death, probably because the patient already has developed antibodies to the infecting agent. The arenaviruses can be cultured from tissues at death; but they usually do not form viral cytopathic effect in mammalian cell cultures, so an indirect method (immunofluorescence, RT-PCR, etc.) must be used to confirm their presence.

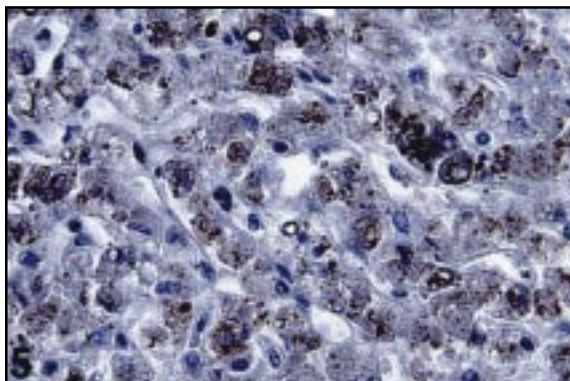
Figure 5 shows liver tissue from the same Ecuadorian patient stained by the immunoperoxidase technique, using a YF mouse immune serum. The brown-staining material within the infected hepatocytes is YF viral antigen and is diagnostic. Figure 4 shows an H&E-stained section of liver from a hamster infected with Pirital virus. Focal hepatocyte necrosis is visible, but the



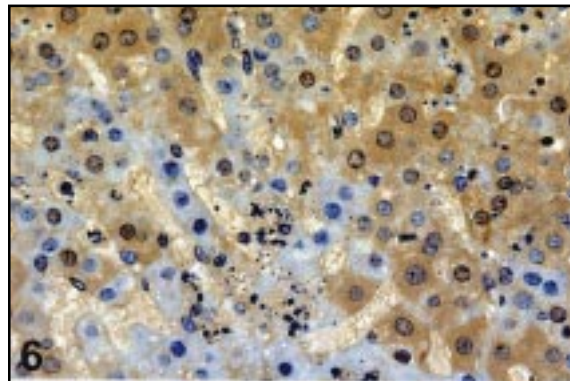
**Figure 3.** Photomicrograph of liver from fatal human case of yellow fever showing hepatocytic necrosis, microvesicular steatosis, pyknotic nuclei and eosinophilic depositions (Councilman bodies) (100X magnification).



**Figure 4.** Focal hepatic necrosis with scattered eosinophilic bodies in a hamster, seven days after infection with Pirital virus (50X).



**Figure 5.** Immunohistochemical staining for yellow fever viral antigen (reddish brown color) in liver of fatal yellow fever case (100X).



**Figure 6.** Immunohistochemical staining in liver of hamster infected with Pirital virus; viral antigen appears as diffuse brown color (model of AHF) (100X).

etiology is uncertain unless an immunostaining technique is used. Figure 6 shows a liver section of the same animal stained with the immunoperoxidase method and a Pirital mouse immune serum.

In summary, three viral hemorrhagic fevers occur in tropical regions of South America. At present, DHF is by far the most common; YF and AHF are less frequent but have a significantly higher mortality rate. The introduction of YF into an urban area in tropical America could have grave public health consequences because of the low level of immunity among most urban residents of the region, the abundance and wide distribution of the mosquito vector, and a relative shortage of the 17-D vaccine worldwide. AHF is an endemic disease and does not have the same epidemic potential as dengue or YF, although a number of nosocomial outbreaks have been reported among hospital personnel attending AFH patients (16). Also AHF is a treatable disease if therapy is initiated during the first 6 days of the illness (16). Thus, correct diagnosis and early recognition of these diseases are essential for effective control measures to be initiated.

### References

1. **Gubler DJ.** Dengue and dengue hemorrhagic fever. *Clin Microbiol Rev* 1998;11:480-96.
2. **Gubler DJ.** Dengue and dengue hemorrhagic fever; its history and resurgence as a global public health problem. In: Gubler DJ, Kuno G, editors. *Dengue and dengue hemorrhagic fever*. Oxon, UK: CAB International; 1997. p.1-22.
3. **Kouri GP, Guzman MG, Bravo JR, Triana C.** Dengue hemorrhagic fever; dengue shock syndrome: lessons from the Cuban epidemic, 1981. *Bull WHO* 1989;67:375-80.
4. **Paradoa Perez ML, Trujillo Y, Basanta P.** Association of dengue hemorrhagic fever and the HLA system. *Hematologia* 1987;20:83-7.
5. **Dietz VJ, Gubler DJ, Rigau-Perez JG, Pinheiro FP, Schatzmayr HG, Bailey R, et al.** Epidemic dengue 1 in Brazil, 1986: evaluation of a clinical based dengue surveillance system. *Am J Epidemiol* 1990;131:693-701.
6. **Kouri G, Guzman MG, Valdes L, Carbonel I, del Rosario D, Vazquez S, et al.** Reemergence of dengue in Cuba: 1997 epidemic in Santiago de Cuba. *Emerg Infect Dis* 1998;4:89-92.
7. **Kuo CH, Tai DI, Chang-Chien SC, Lan CK, Chiou SS, Liaw YF.** Liver biochemical tests and dengue fever. *Am J Trop Med Hyg* 1992;47:265-70.
8. **Muerre MR, Lan NT, Marianneau P, Hue NB, Khun H, Hung NT, et al.** Liver histopathology and biological correlates in five cases of fatal dengue fever in Vietnamese children. *Virchows Arch* 2001;438:107-15.
9. **Rosen L, Khin MM.** Recovery of virus from liver of children with fatal dengue: reflections on the pathogenesis of the disease and its possible analogy with that of yellow fever. *Res Virol* 1989;140:351-60.
10. **Bugher J.** The pathology of yellow fever. In: Strode G, editor. *Yellow fever*. New York: McGraw-Hill; 1951. p.137-63.
11. **del Rio C, Meier F.** Yellow fever. In: Nelson A, Horsburgh CJ, editors. *Pathology of emerging infections 2*. Washington, D.C.: American Society for Microbiology; 1998. p.13-41.
12. **Elton N, Romero A, Trejos A.** Clinical pathology of yellow fever. *Am J Clin Path* 1955;25:135-46.
13. **Xiao SY, Zhang H, Guzman H, Tesh RB.** Experimental yellow fever virus infection in the golden hamster (*Mesocricetus auratus*). II. Pathology. *J Infect Dis* 2001; 183:1437-42.
14. **McCormick JB, Walker DH, King IJ, Webb PA, Elliott LH, Whitfield SG, et al.** Lassa virus hepatitis: a study of fatal Lassa fever in humans. *Am J Trop Med Hyg* 1986;35:401-7.
15. **Johnson KM, Halstead SB, Cohen SN.** Hemorrhagic fevers of Southeast Asia and South America: a comparative appraisal. *Prog Med Virol* 1967;9:105-58.
16. **Peters CJ.** Arenavirus diseases. In: Porterfield JS, editor. *Exotic viral infections*. London: Chapman and Hall; 1995. p.227-46.
17. **Xiao SY, Zhang H, Yang Y, Tesh RB.** Pirital virus (Arenaviridae) infection in the Syrian golden hamster, *Mesocricetus auratus*: a new animal model for arenaviral hemorrhagic fever. *Am J Trop Med Hyg* 2001;64:111-8.
18. **Monath TP.** Epidemiology of yellow fever: current status and speculations on future trends. In: Saluzzo JR, Dodet B, editors. *Factors in the emergence of arbovirus diseases*. Paris: Elsevier; 1997. p.143-56.
19. **Monath TP.** Yellow fever. In: Monath TP, editor. *The arboviruses: epidemiology and ecology*. Vol. 5. Boca Raton (FL): CRC Press; 1989. p.139-231.
20. **Boshell J.** Informe sobre la fiebre amarilla silvestre en la región del Meta, desde Julio de 1934 hasta diciembre de 1936. *Rev Fac Med (Bogotá)* 1938;6:407-27.
21. **Tesh RB, Guzman H, Travassos da Rosa APA, Vasconcelos PFC, Dias LB, Bunnell JE, et al.** Experimental yellow fever virus infection in the golden hamster (*Mesocricetus auratus*). 1. Virologic,



- biochemical, and immunologic studies. *J Infect Dis* 2001; 183:1431-6.
22. **Monath TP.** Yellow fever and dengue - the interactions of virus, vector and host in the re-emergence of epidemic disease. *Semin Virol* 1995;5:133-45.
  23. **Robertson SE, Hull BP, Tomori O, Bele O, LeDuc JW, Esteves K.** Yellow fever. A decade of reemergence. *JAMA* 1996;276:1157-62.
  24. **Van der Stuyft P, Gianella A, Pirard M, Cespedes J, Lora J, Peredo C, et al.** Urbanization of yellow fever in Santa Cruz, Bolivia. *Lancet* 1998;353:1558-62.
  25. **Tesh RB, Salas RA, Fulhorst CF, de Manzione N, Duno G, Weaver SC, et al.** Epidemiology of arenaviruses in the Americas. In: Saluzzo JF, Dodet B, editors. Emergence and control of rodent-borne viral diseases (hantaviral and arenaviral diseases). Paris: Elsevier; 1999. p.213-24.
  26. **Moncayo AC, Hice CL, Watts DM, Travassos da Rosa APA, Guzman H, Calampa C, et al.** Allpahuayo virus: a newly recognized arenavirus (Arenaviridae) from arboreal rice rats (*Oecomys bicolor* and *Oecomys paricola*) in northeastern Peru. *Virology* 2001; 284:277-86.
  27. **Fulhorst CF, Bennett SG, Milazzo ML, Murray HG, Webb JP, Bradley RD.** Bear Canyon virus: an arenavirus naturally associated with *Peromyscus californicus* (California mouse). *Emerg Infect Dis* 2002; 8:717-20.
  28. **Fulhorst CF, Ksiazek TG, Peters CJ, Tesh RB.** Experimental infection of the cane mouse *Zygodontomys brevicauda* (family Muridae) with Guanarito virus (Arenaviridae), the etiologic agent of Venezuelan hemorrhagic fever. *J Infect Dis* 1999;180: 966-9.
  29. **de Manzione N, Salas RA, Paredes H, Godoy O, Rojas L, Araoz F, et al.** Venezuelan hemorrhagic fever: clinical and epidemiologic studies of 165 cases. *J Infect Dis* 1998;26:308-13.
  30. **Utrera A, Duno G, Ellis BA, Salas, RA, de Manzione N, Fulhorst CF, et al.** Small mammals in agricultural areas of the western llanos of Venezuela: community structure, habitat associations, and relative densities. *J Mamm* 2000;81:536-48.
  31. **Mills JN, Ellis BA, McKee KT, Maiztegui JI, Childs JE.** Habitat associations and relative densities of rodent populations in cultivated areas of central Argentina. *J Mamm* 1991;72:470-9.
  32. **Child PL, Mackenzie RB, Valverde LR, Johnson KM.** Bolivian hemorrhagic fever. A pathologic description. *Arch Pathol* 1967;83:434-45.
  33. **Walker DH, Murphy FA.** Pathology and pathogenesis of arenavirus infections. *Curr Topics Microbiol Immunol* 1987;133:89-113.