

Research Article - Basic and Applied Anatomy

Anatomic variations of the popliteal artery branches in present Spaniard population

Alfonso González-Cruz Soler^{1,2}, Laura Quiles-Guiñau^{1,*}, Federico Mata-Escolano³, Juan Alberto Sanchis-Gimeno¹¹ Department of Human Anatomy and Embryology. School of Medicine. University of Valencia. Valencia, Spain² Vascular and Interventional Radiology Unit. Department of Radiology, General University Hospital, Valencia, Spain³ CT and MRI Unit ERESA. Department of Radiology, General University Hospital of Valencia. Valencia, Spain

Abstract

The popliteal region presents a wide range of vascular anomalies. The correct diagnosis of these anatomical variations plays a key role in success of diverse surgical procedures. In this context, the aim of our study was to investigate the prevalence of the anatomic patterns of the popliteal artery branches in a sample of present Spaniard population. This is a retrospective single-center study. 1633 (97.72%) computed tomography angiography images of the popliteal artery branches were studied from a total sample of 840 Spaniard subjects that underwent a computed tomography angiography study, 695 males (82.73%) and 145 women (17.26%), aged between 18 and 97 years. The applied statistics were multivariate models for repeated measures, Student's t-test, and Pearson's chi-square test. Our results show that the Kim's et al. (1989) IA ("normal" pattern) was observed in 1507 limbs (92.28%), while the IB and IC were observed in 24 (1.46%) and 6 (0.36%) limbs respectively. The IIA-1 and IIA-2 patterns were observed in 19 (1.16%) and 27 (1.65%) subjects, while the IIB and IIC in 15 (0.91%) and 1 (0.06%) subjects. Finally, the IIIA, IIIB, IIIC patterns were observed in 24 (1.46%), 5 (0.30%) and 5 (0.30%) subjects respectively. There were no significant differences between men and women, nor between the right and left limbs. In conclusion, approximately 8% of Spaniard subjects present branching anatomic patterns of the popliteal artery different of the normal IA pattern, thus it should be taken into account in clinical practice.

Key words

Diagnostic imaging, three-dimensional imaging, popliteal artery, anatomic variation, Spain, computed tomography angiography.

Introduction

The popliteal region presents a wide range of vascular anomalies. The correct diagnosis of this anatomical variations plays a key role in success of diverse surgical procedures, such as open knee repair, surgical arterial reconstruction, percutaneous transluminal angioplasty or embolectomy, as well as in proper diagnosis of arterial occlusion or vascular damage (Sanders and Alston, 1986; Mauro et al., 1988; Kim et al., 1989; Day and Orme, 2006; Szpinda, 2006; Tindall et al., 2006; Vazquez et al., 2006; Jung et al., 2008). Therefore, knowledge of congenital anatomic varia-

* Corresponding author. E-mail: laura.quiles@uv.es

tions of the popliteal vascular branching is mandatory in surgical procedures and radiological diagnosis. In this context, Kim et al. (1989) classified the popliteal vascular branching patterns into the following categories (Figs. 1-3): IA: Normal level of bifurcation of the popliteal artery (below the knee), with a tibioperoneal trunk length of more than 0.5 cm; the anterior tibial artery is the first branch, and a tibioperoneal trunk follows up to the bifurcation in the posterior tibial artery and peroneal artery. This is the usual pattern. IB: Normal level of bifurcation of the popliteal artery (below the knee), with a tibioperoneal trunk length of less than, or equal to, 0.5 cm. Trifurcation. IC: Normal level of bifurcation of the popliteal artery (below the knee), the posterior tibial artery is the first branch. Anterior tibioperoneal trunk. IIA:

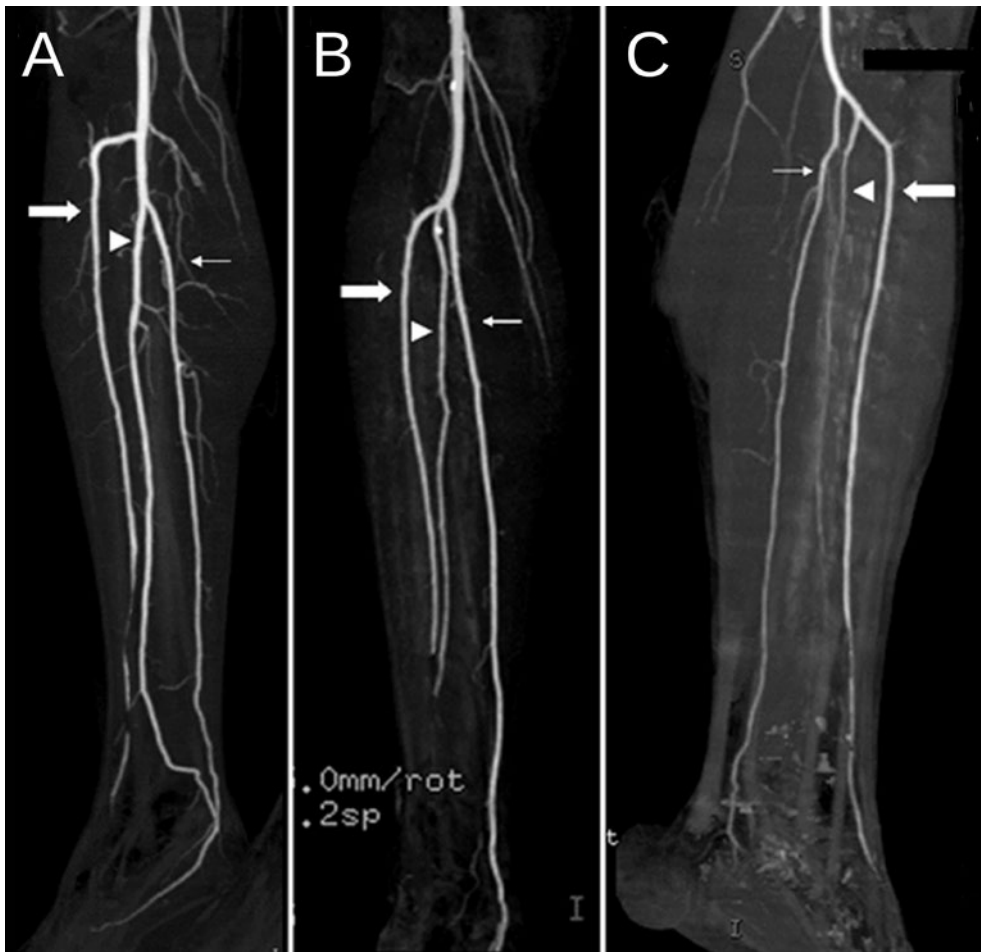

Figure 1. Type I branching patterns in maximum-intensity projection images. A) Type IA pattern in the right lower extremity. B) Type IB pattern in the right lower extremity. C) Type IC pattern in the left lower extremity. Thick arrow: anterior tibial artery; thin arrow: posterior tibial artery; arrowhead: peroneal artery.

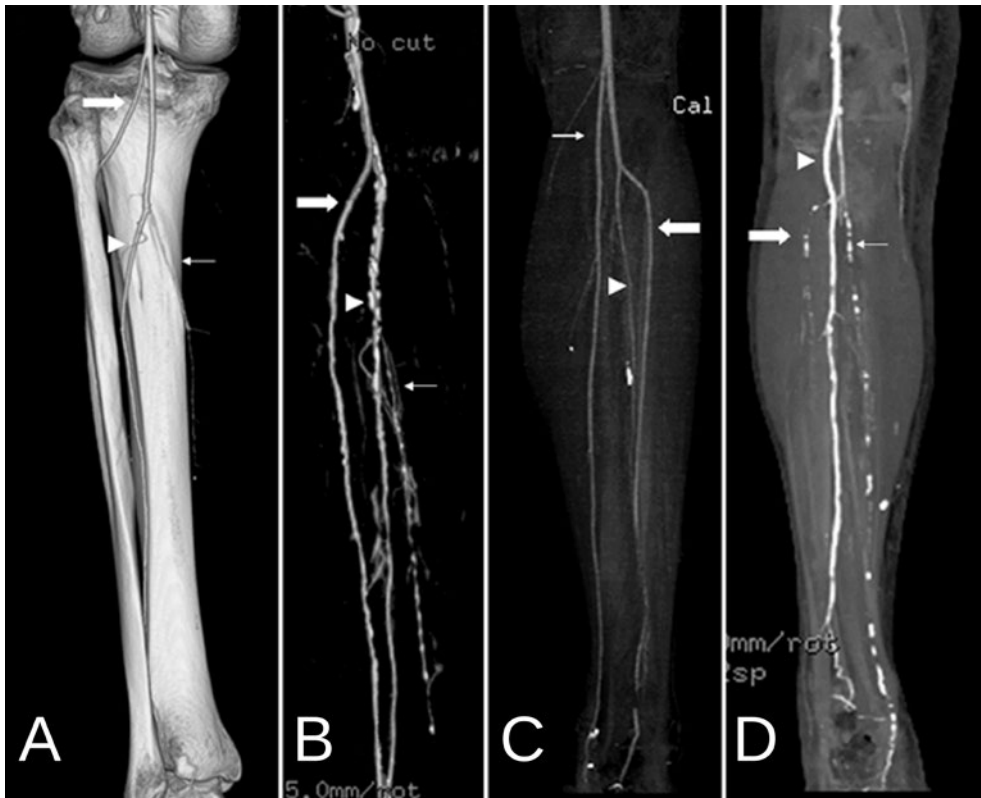


Figure 2. Type II branching patterns. A) Type IIA-1 pattern in the left lower extremity in 3D volume rendering image (posterior view). B) Type IIA-2 pattern in the right lower extremity in 3D volume rendering image, with bone subtraction. C) Type IIB pattern in the left lower extremity in maximum-intensity projection image. D) Type IIC pattern in the right lower extremity in maximum-intensity projection image. Thick arrow: anterior tibial artery; thin arrow: posterior tibial artery; arrowhead: peroneal artery.

High bifurcation of the popliteal artery (above the knee), the anterior tibial artery is the first branch and courses posterior to the popliteal muscle (Type IIA-1) or anterior to it (Type IIA-2). The anterior tibial artery rises at or above the knee joint. IIB: High bifurcation of the popliteal artery (above the knee). The PTA is the first branch and rises at or above the knee joint. IIC: High bifurcation of the popliteal artery (above the knee). The peroneal artery is the first branch and rises at or above the knee joint. IIIA: Hypoplastic or absent PTA, distal PTA replaced by peroneal artery. IIIB: Hypoplastic or absent anterior tibial artery, distal anterior tibial artery replaced by peroneal artery. IIIC: Hypoplastic or absent anterior tibial artery and PTA, both distally replaced by peroneal artery.

Anatomic variations in branching patterns of the popliteal artery have been studied by means of cadaveric dissections (Lippert and Pabst, 1985; Ozgur et al., 2009), digital subtraction angiography (Sanders and Alston, 1986; Zwass and Abdelwahab, 1986; Mauro et al., 1988; Kim et al., 1989; Piral et al., 1996; Kil and Jung, 2009;

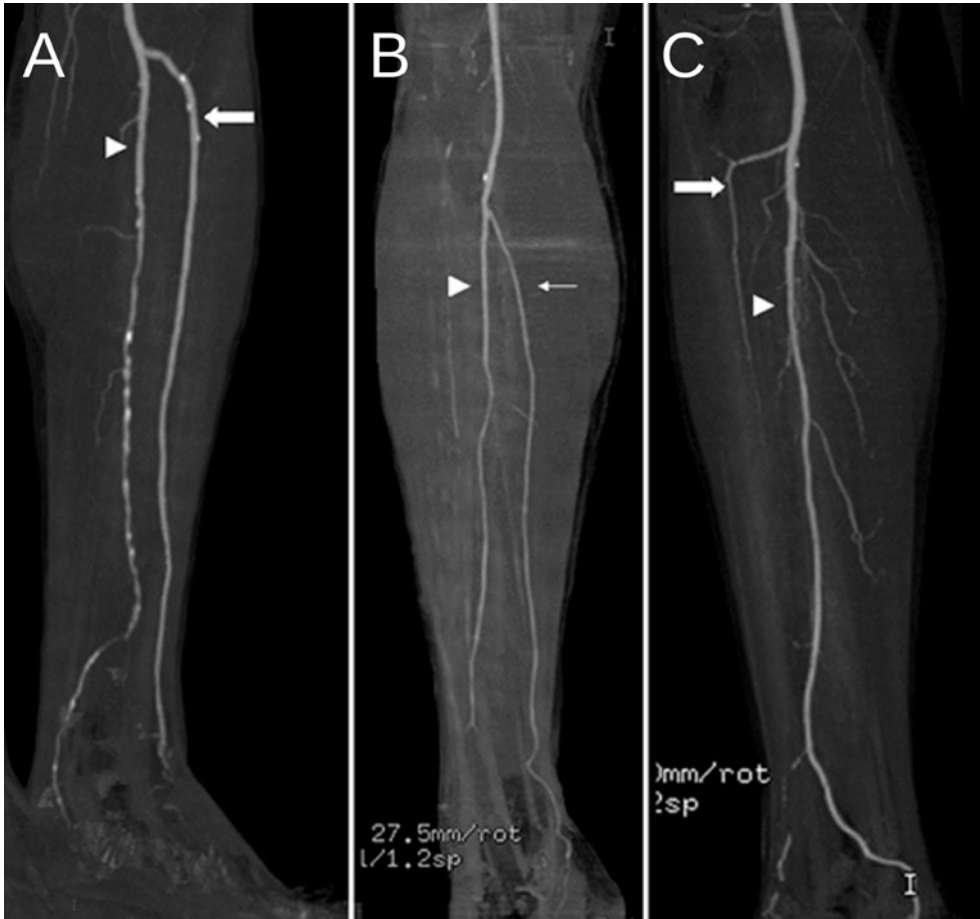

Figure 3. Type III branching patterns in maximum-intensity projection images. A) Type IIIA pattern in the left lower extremity. B) Type IIIB pattern in the right lower extremity. C) Type IC pattern in the right lower extremity. Thick arrow: anterior tibial artery; thin arrow: posterior tibial artery; arrowhead: peroneal artery.

Mavili et al., 2011), and Doppler ultrasound (Tindall et al., 2006). However, contrast enhanced computed tomography angiography (angio-CT) can provide an imaging definition that is as accurate as angiography, with the advantage of being a safer procedure that punctures a peripheral vein (usually at the dorsum of the hand) (Hiatt et al., 2005; Fleischmann et al., 2006).

Currently there is no information about the popliteal vascular branching patterns in Spanish Mediterranean subjects. Following on from this, the objective of this study was to describe the anatomic patterns of the popliteal artery branches using angio-CT in a large sample of Spanish Mediterranean subjects, and to compare with the results of the published literature.

Material and methods

Patient sample

This was a morphologically based, retrospectively designed and single-center study. It was approved by the Ethics Committee of the University General Hospital of Valencia. The procedures were performed in accordance with the World Medical Association Declaration of Helsinki (1975 and subsequent additions).

We analyzed the popliteal artery branching patterns by means of computed tomography angiography (angio-CT) of 919 consecutive Spanish Mediterranean Caucasian subjects. Angio-CT studies were carried out at the CT ERESA Unit at the University General Hospital of Valencia, Spain. The angio-CT images were reviewed by two different radiologists. Only when both radiologists coincided in the diagnosis the angio-CT images were used for the study.

Inclusion criterion for the study was a correct acquisition technique: supine position of the patient and good visualization of the whole length of the vessels with enough enhancement of the distal portion. The only exclusion criterion was previous history of vascular intervention in the region of interest.

In accordance with our inclusion and exclusion criteria, 79 subjects (8.59%) of an initial sample of 919 (100%) had to be excluded because they did not fulfilled our inclusion criteria, so we finally analyzed 840 Spaniard subjects (695 males (82.74%) and 145 females (17.26%). The mean overall age of the study sample was 66.39 ± 11.60 years, and the age range was 18-97 years. The mean age of the women (68.23 ± 13.57 years) was slightly higher than that of men (66.00 ± 11.11 years) and this difference was statistically significant (Student's *t* test, $p = 0.035$).

The main reason for performing the angio-CT scans that were analyzed in this study was intermittent claudication (73.70%), followed by other vascular diseases such as arterial dissection, acute limb ischemia, aneurysms and vascular embolism (23.94%), radiologic study before or after orthopedic or trauma surgery (1.17%), multiple trauma with involvement of lower limbs (0.93%), and cancer (0.23%).

Nine of the 840 subjects had only one limb, and the angio-CT images of 38 (2.27%) limbs did not show the vessels properly. As a result, 1633 (97.73%) lower limbs were finally used to study the branching patterns of the popliteal artery according to the classification proposed by Kim et al. (1989).

Angio-CT protocol

The patients underwent a lower limb angio-CT examination using a 64-detector scanner (VCT Lightspeed, General Electric, Milwaukee, WI, USA). In our standard CT protocol for lower limb examination, a Scanogram area from the iliac crest to the toes, in a supine position, was used as a field of view. During examination, a dose of 1.5 mL per Kg of weight of non-ionic iodinated contrast media and 30-50 ml of saline solution were injected using the bolus-tracking method with an automatic injector at a rate of 5 mL/sec and 3mL/sec, respectively, by puncturing a peripheral vein (at the dorsum of the hand or the antecubital vein). The region of interest was positioned at the iliac bifurcation, and a threshold for CT angiography was set as 150 Hounsfield Units (HU). When the threshold was surpassed, helical scanning was

automatically initiated. Scan parameters were 0.8 sec rotation time with a slice thickness of 0.625 mm.

The axial images from angio-CT studies were transferred to a workstation for analysis. In addition to the axial source data, post-processed multiplanar reconstruction (MPR), maximum-intensity projection (MIP), and 3D volume rendering (3DVR) images were evaluated by two radiologists, and the decisions were made in consensus. The anatomic features of the popliteal arteries, tibioperoneal trunks, anterior tibial arteries, posterior tibial arteries, and peroneal arteries were analyzed and anatomic variations were recorded.

Statistical analyses

The descriptive statistics were calculated to define the sample. Multivariate models for repeated measures were used to adjust for uncertain variables like age and sex. Student's t test was used to evaluate the differences of the means between two independent groups. Pearson's chi-squared test was used to compare the distributions of the frequencies. A p value of ≤ 0.05 was considered significant. Continuous variables are shown as average and standard deviation of the mean. Categorical variables are shown as frequencies. The statistical analyses were performed with SPSS ver.13 statistical software package (SPSS Inc., Chicago, IL, USA).

Results

As Table 1 shows, after adjustment for uncertain variables like sex and age, there were no statistically significant differences between men and women regarding the

Table 1. Frequency of popliteal vascular branching patterns, total and based on sex.

Vascular pattern	Total n = 1633 n (%)	Men n = 1357 n (%)	Women n = 276 n (%)	p ¹
IA	1507 (92.34%)	1253 (92.34%)	256 (92.75%)	0.811
IB	24 (1.46%)	22 (1.62%)	2 (0.73%)	0.259
IC	6 (0.36%)	6 (0.44%)	0 (0.00%)	0.268
IIA-1	19 (1.16%)	16 (1.18%)	3 (1.09%)	0.896
IIA-2	27 (1.65%)	22 (1.62%)	5 (1.81%)	0.821
IIB	15 (0.91%)	14 (1.03%)	1 (0.36%)	0.288
IIC	1 (0.06%)	1 (0.07%)	0 (0.00%)	0.652
IIIA	24 (1.46%)	17 (1.25%)	7 (2.54%)	0.106
IIIB	5 (0.30%)	4 (0.30%)	1 (0.36%)	0.853
IIIC	5 (0.30%)	2 (0.15%)	1 (0.36%)	0.447

n = number of limbs.

¹ p-value in comparison between men and women (Pearson's χ^2 test).

Table 2. Side distribution of popliteal vascular branching patterns.

Vascular pattern	Total n = 1633 n (%)	Right n = 814 n (%)	Left n = 819 n (%)	p ¹
IA	1507 (92.28%)	747 (91.76%)	760 (92.79%)	0.437
IB	24 (1.47%)	12 (1.47%)	12 (1.47%)	0.988
IC	6 (0.37%)	5 (0.62%)	1 (0.12%)	0.177
IIA-1	19 (1.16%)	12 (1.47%)	7 (0.85%)	0.243
IIA-2	27 (1.65%)	15 (1.84%)	12 (1.47%)	0.550
IIB	15 (0.92%)	7 (0.86%)	8 (0.98%)	0.805
IIC	1 (0.06%)	1 (0.12%)	0 (0.00%)	0.316
IIIA	24 (1.47%)	10 (1.23%)	14 (1.71%)	0.419
IIIB	5 (0.31%)	2 (0.25%)	3 (0.37%)	0.659
IIIC	5 (0.31%)	3 (0.37%)	2 (0.24%)	0.649

n = number of limbs.

¹ p-value in comparison between men and women (Pearson's χ^2 test).

Table 3. Review of the literature on the frequency of anatomical variations of the popliteal artery patterns.

Authors	Method used	n	Vascular pattern									
			IA (%)	IB (%)	IC (%)	IIA-1 (%)	IIA-2 (%)	II-B (%)	II-C (%)	IIIA (%)	IIIB (%)	IIIC (%)
Davies et al. [1989]	Angiography	200	88.0	6.0	-	2.0	1.5	-	2.5	-	-	-
Kim et al. [1989]	Angiography	605	92.6	2.0	1.2	3.0	0.7	0.8	0.2	3.8	1.6	0.2
Prayer et al. [1990]	Angiography	414	90.1	0.7	0.7	4.1	2.9	-	1.5	0.5	-	-
Voboril [1990]	Angiography	253	81.8	5.5	-	2.0	2.4	-	7.5	0.8	-	-
Piral et al. [1996]	Dissection	40	90.9	5.0	5.0	-	-	-	-	0.0	0.0	0.0
Day & Orme [2006]	Angiography	1037	90.7	3.2	0.3	2.1	2.4	1.1	0.2	0.8	0.1	0.1
Szpinda [2006]	Angiography	152	87.5	2.6	2.0	2.0	5.9	-	-	-	-	-
Kil & Jung [2009]	Angiography	1242	89.2	1.5	0.1	1.2	1.2	0.4	0.0	5.1	1.7	0.8
Ozgun et al. [2009]	Dissection	40	90.0	2.5	2.5	5.0	0.0	0.0	0.0	0.0	0.0	0.0
Mavili et al. [2011]	Angiography	535	82.4	5.4	0.4	2.6	1.3	1.5	0.0	3.7	2.2	0.2
Present study	Angio-CT	1633	92.28	1.46	0.36	1.16	1.65	0.91	0.06	1.46	0.30	0.30

frequencies of popliteal vascular branching patterns. The IA ("normal" pattern) was observed in 1507 limbs (92.28%), followed by IIA-2 (1.65%), IB (1.46%), IIIA (1.46%), IIA-1 (1.16%), IIB (0.91%), IC (0.36%), IIIB (0.30%), IIIC (0.30%), and IIC (0.06%). There were no significant differences between the right and left limbs (Table 2).

Discussion

We present the results of the largest study on anatomic variations of the popliteal artery and its branches in Spanish Caucasian Mediterranean subjects carried out by means of angio-CT. We used angio-CT because it makes it possible to study the peripheral vascular anatomy in a few seconds (Rubin et al., 2001) and is a perfect tool for increasing anatomic knowledge in vivo.

Since Kim et al. (1989) published their practical classification of anatomic variations in branching patterns of the popliteal artery based on the cadaveric classification of Lippert and Pabst (1985), different authors have analyzed this kind of variations using different techniques (Table 3). Our results agree with those shown in previous reports, the most frequent pattern being the IA type, and the three most frequent variations being the high origin of the popliteal artery (IIA type), the trifurcation (IB type), and the hypoplasia/absence of the anterior tibial artery (IIIA type).

The number of type III patterns is more variable than the number of type I and type II patterns (Davies et al., 1989; Kim et al., 1989; Prayer et al., 1990; Voboril, 1990; Day and Orme, 2006; Kil and Jung, 2009; Mavili et al., 2011). Previously, different authors (Davies et al., 1989; Kim et al., 1989; Prayer et al., 1990; Voboril, 1990; Day and Orme, 2006; Kil and Jung, 2009; Mavili et al., 2011) observed that the IIIA pattern is more common than IIIB pattern, which also concurs with our investigation. This may be because of the difficulty in distinguishing between congenital and acquired arterial abnormalities in the setting of patients with atherosclerotic disease (Day and Orme, 2006). Nevertheless, evaluation of atherosclerotic disease and its complications is the main application of angio-CT (Fleischmann et al., 2006).

Mavili et al. (2011) described a different pattern that consisted of a high bifurcation of the popliteal artery with a trifurcation pattern, which they called IID. We did not find this branching pattern in our study. Nevertheless, it can be expected that these patterns and others not yet described will be found during conventional anatomic dissections.

Most of the anatomic variations in the popliteal artery branching pattern can be explained by alterations in embryonic development. Anterior and posterior tibial arteries develop from the femoral artery, which is a branch of the external iliac artery and main artery of the fetal lower limb, while popliteal and peroneal arteries develop from middle and distal segments of the axial or sciatic artery, the embryonic vessel that supplies the lower limbs (Mauro et al., 1988). In developing embryos, the sciatic artery rises from the dorsal root of the umbilical artery and runs down the leg to the distal border of the popliteus muscle; then it gives rise to a perforating branch, which anastomoses with the femoral artery (Tindall et al., 2006; Jung et al., 2008). While the embryo grows, the size of the femoral artery increases and the sciatic artery decreases. This perforating branch, called *ramus communicans*, then gives rise to the definitive anterior tibial artery (Mauro et al., 1988; Tindall et al., 2006). The posterior tibial artery is formed by the anastomoses between the distal femoral artery and the popliteal artery (Tindall et al., 2006). Most of the variations can be explained by combinations between persistent primitive arterial segments, abnormal fusions, hypoplasia, and segmentary absence of this artery (Mauro et al., 1988).

Knowledge of the congenital vascular anatomical variants is essential in diagnosis. The popliteal region is well-known for its wide range of vascular anatomical varia-

tions, and a correct diagnosis bears a great influence on the success of surgical procedures (Sanders and Alston, 1986; Mauro et al., 1988; Kim et al., 1989; Day and Orme, 2006; Tindall et al., 2006; Szpinda, 2006; Vázquez et al., 2006; Jung et al., 2008). As other authors have described, mistakes in the recognition of these patterns can result in an ineffective arterial anastomosis after femorodistal bypass (Sanders and Alston, 1986; Kim et al., 1989).

The development of non-invasive vascular imaging techniques, such as angio-CT, makes it possible to study the peripheral vascular tree in a few seconds without the need for angiography, and currently can be used for diagnosis, treatment planning, and follow-up of patients with peripheral vascular disease (Rubin et al., 2001). In comparison with conventional angiography, angio-CT is less invasive and more cost-effective, and exposes the patient to lower doses of radiation (Rubin et al., 2001).

Unlike magnetic resonance angiography, angio-CT does not have the common MRI contraindications, such as the use of defibrillators or metallic implants; it avoids false angio-MRI images caused by the twisting of the vessels and allows the inclusion of bony structures in the image, which are useful anatomical references that are not visible by angio-MRI (Fleischmann et al., 2006).

In sum, angio-CT has been used to analyze the anatomic branching patterns of the popliteal artery in a large sample of Caucasian Mediterranean subjects. In addition, and from an anatomic viewpoint, our study has confirmed that approximately 8% of the Spanish Mediterranean Caucasian subjects had a different branching pattern than the normal IA Type.

Conflict of interest

The authors declare that they have no conflicts of interest.

Acknowledgments

The authors are grateful to ERESA for their support and assistance during the different stages of the study.

This research received no specific grant from any funding agency in the public, commercial, or not-for-profit sectors.

References

- Davies B.W., Husami T.W., Lewis J., Retrum E. (1989) Developmental variations of the popliteal artery and its branches: a clinical correlation. *Contemp. Surg.* 34: 28-32.
- Day C.P., Orme R. (2006) Popliteal artery branching patterns-an angiographic study. *Clin. Radiol.* 61: 696-699.
- Fleischmann D., Hallett R.L., Rubin G.D. (2006) CT angiography of peripheral arterial disease. *J. Vasc. Interv. Radiol.* 17: 3-26.
- Hiatt M.D., Fleischmann D., Hellinger J.C., Rubin G.D. (2005) Angiographic imaging of the lower extremities with multidetector CT. *Radiol. Clin. North. Am.* 43: 1119-1127.

- Jung W., Oh C.S., Won H.S., Chung I.H. (2008) Unilateral arteria peronea magna associated with bilateral replaced dorsalis pedis arteries. *Surg. Radiol. Anat.* 30: 449-452.
- Kil S.W., Jung G.S. (2009) Anatomical variations of the popliteal artery and its tibial branches: analysis in 1242 extremities. *Cardiovasc. Intervent. Radiol.* 32: 233-240.
- Kim D., Orron D.E., Skillman J.J. (1989) Surgical significance of popliteal arterial variants. A unified angiographic classification. *Ann. Surg.* 210: 776-781.
- Lippert H., Pabst R. (1985) *Arterial Variations in Man: Classification and Frequency.* JF Bergman Verlag, München.
- Mauro M.A., Jaques P.F., Moore M. (1988) The popliteal artery and its branches: embryological basis of normal and variant anatomy. *Am. J. Roentgenol.* 150: 435-437.
- Mavili E., Dönmez H., Kahriman G., **Özlaşmacı A.**, **Özcan N.**, Taşdemir K. (2011) Popliteal artery branching patterns detected by digital subtraction angiography. *Diagn. Interv. Radiol.* 17: 80-83.
- Ozgun Z., Ucerler H., Aktan Ikiz Z.A. (2009) Branching patterns of the popliteal artery and its clinical importance. *Surg. Radiol. Anat.* 31: 357-362.
- Piral T., Germain M., Princ G. (1996) Absence of the posterior tibial artery: implications for free transplants of the fibula. *Surg. Radiol. Anat.* 18: 155-158.
- Prayer L., Karnel F., Schurawitzki H. (1990) Angiographic demonstration of the branching of the popliteal artery in the arteries of the lower extremity: variations and frequency distribution. *Röntgenpraxis* 43: 100-103.
- Rubin G.D., Schmidt A.J., Logan L.J., Sofilos M.C. (2001) Multi-detector row CT angiography of lower extremity arterial inflow and runoff: initial experience. *Radiology* 221: 146-158.
- Sanders R.J., Alston G.K. (1986) Variations and anomalies of the popliteal and tibial arteries. *Am. J. Surg.* 152: 531-534.
- Szpinda M. (2006) Digital-image analysis of the angiographic patterns of the popliteal artery in patients with aorto-iliac occlusive disease (Leriche syndrome). *Ann. Anat.* 188: 377-382.
- Tindall A.J., Shetty A.A., James K.D., Middleton A., Fernando K.W. (2006) Prevalence and surgical significance of a high-origin anterior tibial artery. *J. Orthop. Surg. (Hong Kong)* 14: 13-16.
- Vázquez T., Rodríguez-Niedenfuhr M., Parkin I., Viejo F., Sañudo J.R. (2006) Anatomic study of blood supply of the dorsum of the foot and ankle. *Arthroscopy* 22: 287-290.
- Voboril R. (1990) Note on variability of the arteries of the lower extremities in man. *Folia Morphol.* 38: 265-272.
- Zwass A., Abdelwahab I.F. (1986) A case report of anomalous branching of the popliteal artery. *Angiology* 37: 132-135.