

Research Article - Basic and Applied Anatomy

# Variations in distal attachment of muscles of the leg, foot and the hand and their clinical implications in population of central Ethiopia

Soressa A. Geneti, Amenu T. Wirtu, Solomon T. Hailegiorgis

Department of Anatomy, School of Medicine, College of Health Sciences, Addis Ababa University, Ethiopia

## Abstract

Anatomical variations in the distal attachment of lower and upper limb muscles are of paramount importance in surgical and clinical practice. Reports show variations in the insertion of the fibularis longus and brevis tendon from the lateral compartment of the leg, extensor hallucis longus and fibularis tertius from the anterior compartment of the leg, flexor digitorum brevis from the sole of the foot and the existence of accessory muscles in the dorsum of the hand. However, reports are scanty from Ethiopia. The present study was aimed at assessing the existence of variation in the distal attachments of muscles of the lower and upper limbs in the central Ethiopia population. Twenty-two formalin fixed cadavers were used. Careful dissection, critical observation and imaging were done accordingly. We have found the presence of two tendons of extensor hallucis longus in one case, absence of the lateral tendon to the 5<sup>th</sup> digit of the flexor digitorum brevis of the sole of the foot in another case and the presence of the accessory extensor indicis muscle on the dorsum of the hand in a third case. These variations are important owing to the use of the tendons in tendon transfer surgeries to correct deformities of the hand, foot and ankle joint, and also for radiologists, clinicians, and surgeons in order to prevent adverse surgical events.

## Key words

Muscles, variation, dissection, Ethiopia.

## Introduction

Anatomical variations in the muscles of the leg and their insertion pattern of different tendon on the dorsum of foot are not common (Al-Saggaf, 2003). Reports show variations in the tendon insertion of the fibularis longus (Shyamsundar et al., 2012) and brevis from the lateral compartment of the leg, extensor hallucis longus and fibularis tertius from the anterior compartment of the leg, flexor digitorum brevis from sole of the foot (Patil et al., 2007; Erçkt et al., 2015; Srivastava et al., 2016). However, reports are scanty from Ethiopians.

It has been indicated by different literature reviews that the extensor hallucis longus varies in its distal attachment (Arora et al., 2011). Also, variations in the distal attachment of muscles of anterior compartment, namely tibialis anterior, extensor digitorum longus, fibularis tertius and extensor hallucis longus are rare (Al-Saggaf, 2003).

\* Corresponding author. E-mail: [abebe.soressa2017@gmail.com](mailto:abebe.soressa2017@gmail.com), [soressa.abebe@aau.edu.et](mailto:soressa.abebe@aau.edu.et)

It is well known that all these muscles insert distally onto the bones of the foot and serve for dorsiflexion and inversion of the foot. The extensor hallucis longus originates from the middle part of the anterior surface of fibula and interosseous membrane and inserts distally at the base of the distal phalanx of the hallux (big toe) (Al-Saggaf, 2003; Arora et al., 2011). Muscles of lateral compartment, fibularis longus and fibularis brevis respectively, are attached distally at the base of the 1<sup>st</sup> metatarsal bone on the plantar aspect and at the base of the 5<sup>th</sup> metatarsal bone on the dorsal aspect.

The foot is considered to be the distal segments of the free lower limb and has a plantar and dorsal aspect (Lambert et al., 2015). The plantar aspect is highly modified in that its muscles are arranged in four layers. The skeleton of the foot receives the distal attachment for most of the muscles of the leg. Several reports indicate that variants of the muscles and tendons of the leg and foot are important with regard to understanding their functions and causes of abnormalities in clinical activities (Lobo et al., 2008; Lambert et al., 2015). The variations of muscles and tendons in the hand are common. However, this type of variation is relatively rare and yet not reported in Ethiopia. The extensor indicis muscle is widely utilized in surgery for tendon transfer designed to restore a variety of finger movements (Arathala et al., 2016).

Therefore, the present study investigated the variations in distal attachment of extensor hallucis longus, the flexor digitorum brevis in the sole of the foot and the presence of accessory extensor indicis muscle in the dorsum of the hand in Ethiopian cadavers.

## Materials and methods

The study was conducted using 22 formalin fixed cadavers, hence 44 lower and upper limbs of both sexes (19 males and 3 females). They were dissected for the 1<sup>st</sup> year and 2<sup>nd</sup> year undergraduate medical students in the Department of Anatomy of Addis Ababa University, Sante Medical College and Betel Medical College in Addis Ababa, Ethiopia. The study was conducted in well preserved and controlled cadavers suitable for undergraduate medical students in accordance with the guidelines of Cunningham's Manual of Practical Anatomy and Grant's dissection principle specifically of the leg and feet. The skin of both the lower and upper limbs was reflected, the superficial fascia and deep fascia were cleaned preserving neurovascular structures and underlying muscles. In all cases, critical observation and image recordings were made. The dissected structures were carefully handled in the laboratories and observed for the presence of variations with special focus on the musculatures of the legs, feet and hands. All observations of the present study are indicated in the result section.

## Results

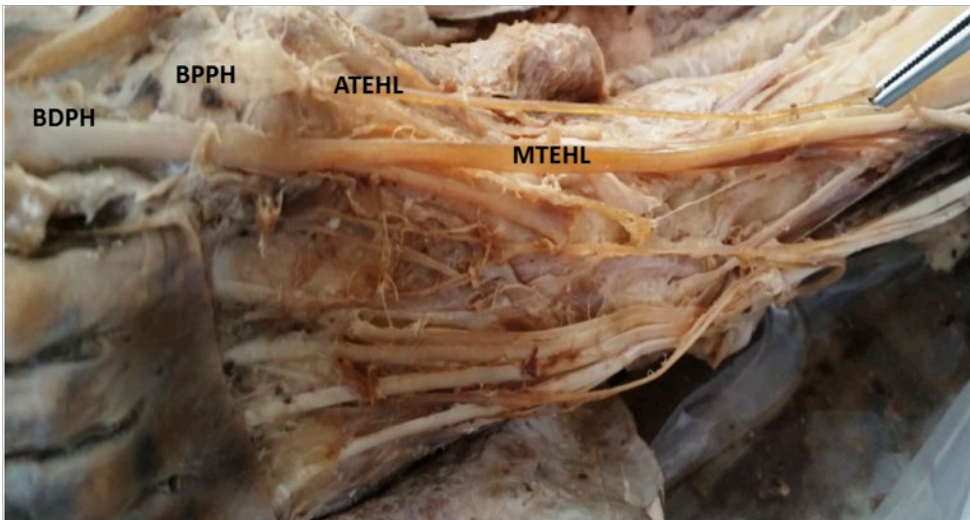
Careful observations were made during the dissection of 44 lower and upper limbs of 22 cadavers (19 males and 3 females) for 1<sup>st</sup> and 2<sup>nd</sup> year undergraduate medical students of the sampled institution, for the presence of anatomical variants with the special focus on clinically important muscles of the legs, feet and hands. As a result, we investigated the variation in patterns of insertions and the numbers of

**Table 1.** Patterns of insertion of the extensor hallucis longus.

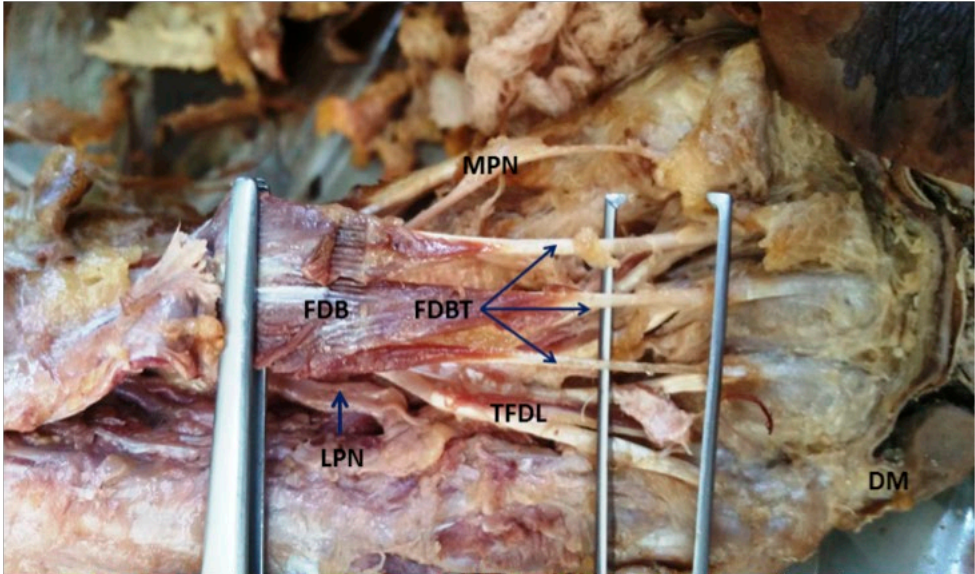
Pattern	No of tendinous slips	No. of cases	Percentage (%)
I	One	43	97.7
II	Two	1	2.3
III	Three	Nil	Nil
Total		44	100

tendinous slips of extensor hallucis longus muscle of the leg (Table 1), the variation in flexor digitorum brevis muscle of the foot and the existence of accessory muscles on the dorsum of the hand.

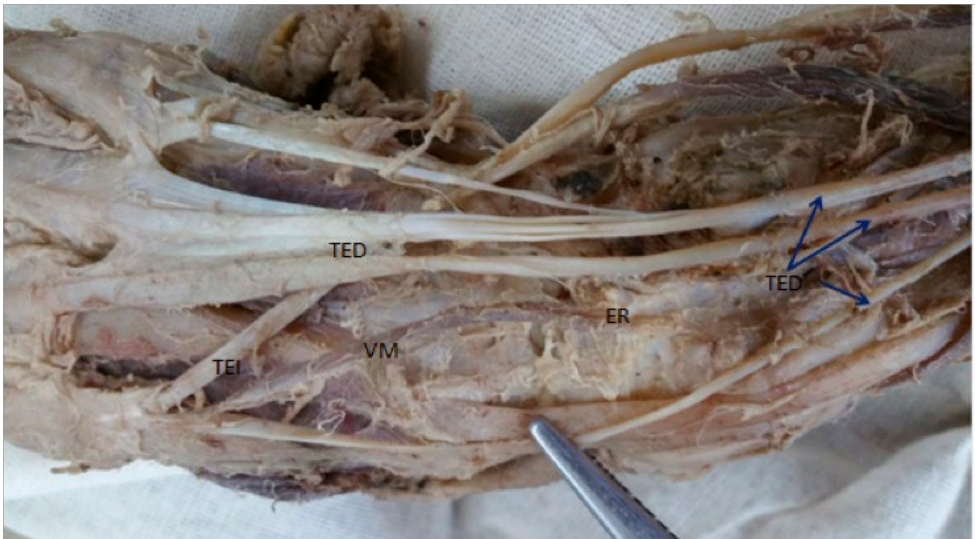
We found one case where the extensor hallucis longus originating from the middle part of the anterior surface of the fibula and the interosseous membrane run distally between the tendon of tibialis anterior and extensor digitorum. Its tendon passed deep to the extensor retinaculum. On the dorsum of the foot it bore two tendons, the main tendon was inserted onto the base of the distal phalanx of the great toe (hallux), whereas the accessory or variant tendon was inserted onto the head of the 1<sup>st</sup> metatarsal bone and base of the proximal phalanx of the great toe (Figure 1). We also found the absence of the lateral tendon to the 5<sup>th</sup> digit of flexor digitorum brevis in the sole of the foot of one case (Figure 2). As a result, the present study documented the anatomical variation of the flexor digitorum brevis muscle in population of Ethiopia. Another muscular variant found in the present study was the presence of acces-



**Figure 1.** Double tendon of extensor hallucis longus and corresponding distal attachments. MTEHL: main tendon of extensor hallucis longus; ATEHL: accessory tendon of extensor hallucis longus; BPPH: base of proximal phalanx; BDPH: base of distal phalanx.

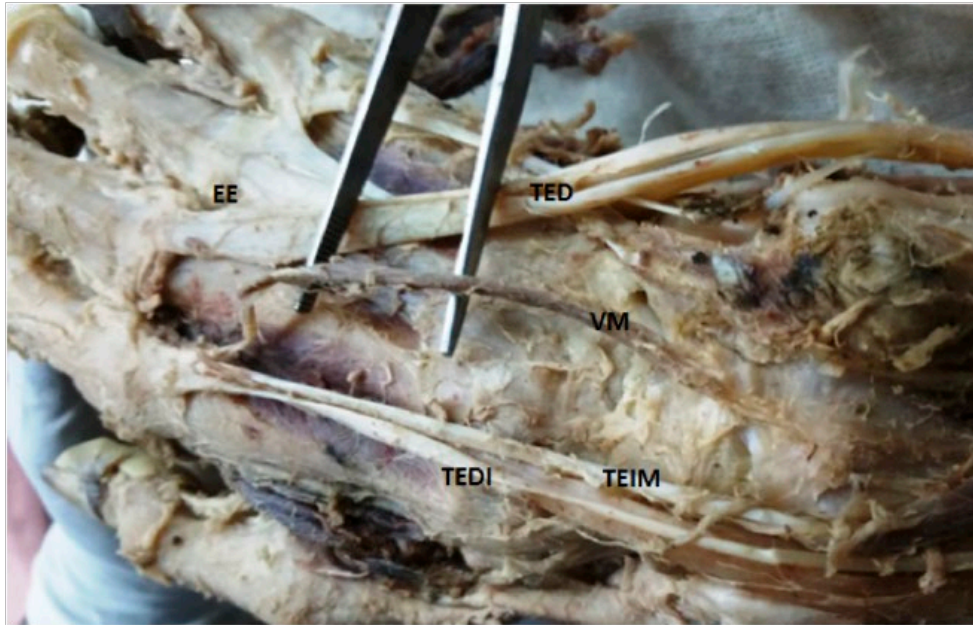


**Figure 2.** Flexor digitorum brevis lacking tendon to little toe. FDB: flexor digitorum brevis; FDBT: flexor digitorum brevis tendon; TFDL: tendon of flexor digitorum longus; DM: digitus minimus; LPN: lateral plantar nerve; MPN: medial plantar nerve.



**Figure 3.** Variant muscle on the dorsum of a right hand. TED: tendon of extensor digitorum; TEI: tendon of extensor indicis; VM: variant muscle; ER: extensor retinaculum.





**Figure 4.** Variant muscle on the dorsum of a right hand. TEDI: tendon of extensor digitorum indicis; TEIM: tendon of extensor indicis muscle; VM: variant muscle; EE: extension expansion; TED: tendon of extensor digitorum.

sory muscle on the dorsum of the hand in one of the sampled cases (Figures 3, 4). The accessory muscle originated from accessory extensor indicis (variant muscle) and the deep part of the extensor retinaculum run forward to join the extensor indicis.

## Discussion

Knowledge of anatomical variations is of paramount importance in different medical specialties and practice (Geneti, 2017). Anatomical variations have been reported in almost all regions of the muscular system (Imosemi and Atiba, 2015) but not yet in Ethiopia. They are of both surgical and academic interests as in case of entrapment syndrome and reconstructive surgery in patients with musculoskeletal disorder (Imosemi and Atiba 2015). Understanding muscle architecture of the foot may assist in the design of surgical procedures such as tendon transfer, biomechanical modeling of the foot, prosthesis design, and also in the evaluation and treatment of functional defects of the foot (Lobo et al., 2008).

The present study identified double tendon of the extensor hallucis longus. Whereby the main tendon was inserted onto the base of the distal phalanx of the big toe and the accessory tendon was inserted onto the head of the 1<sup>st</sup> metatarsal bone and the base of the proximal phalanx of the big toe in one case. This has to compared with other findings (Al-Saggaf, 2003; Arora et al., 2011; Lambert et al., 2015).

**Table 2.** Comparison of the patterns of insertions of extensor hallucis longus of the present findings with findings of Al-Saggaf (2003).

Pattern	No of tendinous slips	Percentage (%)	
		Al-Saggaf (2003)	Present study (2017)
I	One	65	97.7
II	Two	16	2.3
III	Three	5	Nil
Total		100	100

Al-Saggaf (2003) identified and summarized the patterns of insertion of extensor hallucis longus into three basic categories and their results are compared with the present study in Table 2.

The differences in percentage between the present study and Al-Saggaf (2003) findings may be due to differences in race and/or geographical location.

Flexor digitorum brevis, an intrinsic muscle of the sole of the foot, is stated as one of the muscles that shows frequent anatomical variations (Illyperuma, 2012; Baburao and Manohar, 2014). It was reported in different literature reviews that the most common variation is the absence of the tendon to the little toe (Illyperuma, 2012). We found the absence of the tendon to the digitus minimus in one of the sampled cases, which is in line with other studies conducted in different countries. Yammine (2015) performed a meta-analysis and indicated the prevalence of variations of the flexor digitorum brevis tendon in different countries of the world. Accordingly, this happens in 77.3% of Indian populations, approximately 20% in Japanese, Chinese, American, European and Turkish population, and possibly 2.3% of the Ethiopian population as indicated in the present study. The different prevalence of flexor digitorum brevis tendon variations among the populations of the world, including Ethiopia, may be due to geographical location and race. The muscle, particularly its fourth slip, has a significant clinical and surgical importance in medical practice as its musculocutaneous flap is used in the reconstruction of the heel pad (Yalçın and Ozan, 2005; Thangarajan et al., 2010; Yammine, 2015).

The extensor musculature of forearm and hand shows diverse morphological variations including presence of additional bellies with a common tendon with another muscle or the presence of an additional muscle at an unusual location (Garg et al., 2016). In line with several studies, we found an accessory extensor indicis muscle in one case.

The observed variants are clinically important due to the use of the tendons in tendon transfer surgery to correct deformities such as hallux varus, equinovarus foot, clawed hallux associated with a cavus foot, and dynamic hyper-extension of the hallux. Presence of extensor hallucis longus and flexor digitorum brevis muscles variants can complicate surgery of the foot and ankle. As a result, understandings the muscular variants of the foot and leg as well as the muscles of the hand is crucial for radiologists, clinicians, and surgeons for proper evaluation and treatment of foot and hand deformities and prevent adverse surgical outcomes.

## Conflicts of Interest

The authors declare that they have no conflicts of interest.

## Acknowledgements

We would like to thank the authorities of the three Medical Schools and their Anatomy Departments in Addis Ababa, Ethiopia, for having allowed us to use the cadavers available for dissection in their dissection room. We also extend our thanks to the laboratory technicians in those Departments for their valuable cooperation.

## References

- Al-Saggaf S. (2003) Variations in the insertion of the extensor hallucis longus muscle. *Folia Morphol.* 62: 1-9.
- Arathala R., Sankaran P.K., Ragunath G., Harsha S.S., Sugumar T. (2016) The extensor indicis brevis – A rare variation and its significance. *J. Clin. Diagn. Res.* 10: 3-4.
- Arora A.K., Verma P., Abro S. (2011) Study of extensor hallucis longus muscle in adult human cadavers of Punjab. *J. Life. Sci.* 3: 101-105.
- Baburao K.P., Manohar G.J. (2014) Variation in flexor digitorum brevis. *Sch. J. Med. Cas. Rep.* 2: 833-834.
- Erc¸kt N., Apayd N., Acer N. (2015) An additional tendon of the extensor digitorum brevis muscle of the foot: is there an accessory muscle? *Int. J. Exp. Clin. Anat.* 9: 189-191.
- Garg S., Agarwal S., Sudeva N. (2016) Anatomical variations in the muscles of extensor compartment of forearm and hand - A case report. *Int. J. Sci. Res.* 5: 584-585.
- Geneti S.A. (2017) Anatomical variations and their clinical significance in population of southwestern and central Ethiopia. *EJBPS.* 4: 101-105.
- Ilayperuma I. (2012) On the variations of the muscle flexor digitorum brevis: Anatomical insight. *Int. J. Morphol.* 30: 337-340.
- Imosemi I.O., Atiba F. (2015) Anatomical variations of the musculoskeletal system - A review of literatures. *J. Med. Sci.* 6: 151-155.
- Lambert H.W., Paulet J., Addie K., Lear J., Zdilla M. (2015) Variants of the extensor hallucis longus muscle and their importance in tendon transfer surgeries. *FASEB J.* 39: 1-5.
- Lobo S.W., Menezes R.G., Mamata S., Baral P., Hunnargi S.A., Kanchan T., Bodhe A.V., Bhat N.B. (2008) Phylogenetic variation in flexor digitorum brevis: a Nepalese cadaveric study. *Nep. Med. Coll. J.* 10: 230-232.
- Patil V., Frisch N.C., Ebraheim N.A. (2007) Anatomical variations in the insertion of the fibularis longus. *Foot Ankle Int.* 28: 1179-1182.
- Shyamsundar S., Wazir A., Allen P.E. (2012) Variations in the insertion of peroneus longus tendon - A cadaver study. *Foot Ankle Surg.* 18: 293-295.
- Srivastava A.K., Soheli S., Gupta A.K., Singh S.B., Tandon A. (2016) Phylogenetic variation of muscle flexor digitorum brevis - Rare variation on the right foot. *Ann. Int. Med. Dent. Res.* 2: 117-120.

- Thangarajan R., Bakthavatchalam P., Potu B.K., Huban R.T. (2010) Anatomical variation of the flexor digitorum brevis muscle revisited: a case report from south Indian population. *Int. J. Anat. Variations* 3: 211-213.
- Yalçın B., Ozan H. (2005) Some variations of the musculus flexor digitorum brevis. *Anat. Sci. Int.* 80: 189-192.
- Yammine K. (2015) The fourth slip of the flexor digitorum brevis muscle of the human foot. A systematic review and meta-analysis. *Ital. J. Anat. Embryol.* 120: 59-70.