

Review Article

VARIABLE LEFT AND/OR RIGHT VERTEBRAL ARTERY IN PREVERTEBRAL PART: A REVIEW OF FEATURES IN THE POSTNATAL PERIOD

Ljiljana Vasović¹, Goran Radenković², Milena Trandafilović^{1*}, Gordana Đorđević³

Faculty of Medicine, University of Niš, ¹Department of Anatomy, ²Department of Histology and Embryology, Niš, Serbia
³Health Center of Niš, Niš, Serbia

Abstract. The vertebral artery (VA), as the first upstream branch of the subclavian artery on both sides courses having four topographical parts — prevertebral, cervical, atlantic and intracranial to the interlocking connection into basilar artery. However, its amenability to the variations can be at the origin, and/or course and/or termination. The review of postnatal features of variable VA origin and its prevertebral part was performed according to the 171 literature case reports. Among them, 94 cases of variable left VA, 30 cases of variable left and right VAs and 47 cases of variable right VA have been analyzed. The left and/or right VAs were showed as simple or common vessels or segmentally duplicated at their origin from the aorta and/or subclavian or common carotid or external carotid artery or unusual arterial stems. Different patterns of single VA origin and/or arrangement associated with main supra-aortic arteries variants were presented as 30 primary (basic) and 32 complementary models. Nine different vascular and/or visceral pathological processes were common independently of unilateral or bilateral variability of the VA; however, there were only eight patients with pathological changes in variable VA.

Key words: Human vertebral artery, morphologic variants, postnatal status, associated disorders

Introduction

The cardiovascular system is the first system functioning in the developing animal or human embryo [1]. As cited by Bhatia et al. [2], the development of blood vessels is associated with local release of certain growth factors such as the placental growth factor, fibroblast growth factor-2, angiopoietins and vascular endothelial growth factor.

The development of the cardiovascular system is associated with the formation of the endocardial tube and paired primitive aortae. The endocardial tube begins to beat during the third week of gestation. It consists of four parts: (1) sinus venosus; (2) primitive atrium; (3) primitive ventricle; and (4) bulbus cordis that continues as the truncus arteriosus. Six primitive aortic arches bilaterally diverge from a dilatation of the truncus arteriosus (aortic sac) to the dorsal aortas that run through the entire length of the embryo and their segmental branches correspond to the somites. The dorsal aorta gives off thirty pairs of dorsal intersegmental arteries (DIAs), which supply the spinal cord and the developing somites. Each segment has the same number as the intersegmental artery bounding it caudally. The fusion of paired dorsal aortas could be seen just caudal to pharyngeal arches, during the 4th week.

The first pair of aortic arches embedded in the mandibular arch courses around the rostral part of the pharynx. Actually it is formed by the curving of a ventral segment of the primitive aorta (“ventral aorta”) into dorsal segment (“dorsal aorta”), between days 22–24. The first aortic arch will contribute to the development of maxillary and external carotid arteries. A second pair of aortic arches that embedded into tissue of the hyoid arch springs from the cephalic end of the heart dorsal to the ventral root of the first aortic arch. It participates in the formation of hyoid artery and its stapodial branch. The further course of development is followed by appearance of other aortic arches; five pairs (I–IV and VI) are developed between days 22–29. The development of the fifth aortic arch is followed by the disappearance of the first two arches. A proximal segment of the *third pair* will form the common carotid artery (CCA), whereas the distal part of the third arch together with some segments of the dorsal aorta will contribute to the formation of the internal carotid artery (ICA). The left *fourth* arch will form the segment of adult arch of the aorta between the left CCA and subclavian (SA) arteries; the right fourth arch will form the proximal right SA [3, 4].

There is a disagreement in the literature about the complete development of the SA. Some authors noted that the distal right SA will derive from a portion of the right dorsal aorta and the right sixth cervical intersegmental artery (CIA), whereas the left SA will be formed entirely from the left sixth CIA [5–16]. However, some embryologists [1, 3, 4], as well as most cited anatomists

*Correspondence to: Milena Trandafilović, MD
Faculty of Medicine, Dept. of Anatomy, 81 Dr. Zoran Đinđić Blvd.,
18000 Niš, Serbia
Phone: +381 18 4570029 Fax: +381 18 4238770
E-mail: mitra018@yahoo.com
Received November 17th, 2015 / Accepted December 1st, 2015

and clinicians in this paper described that the seventh CIA is a precursor of future SA and VA.

The segment of the ventral aortic roots between the fourth and third aortic arches will incorporate into the brachiocephalic trunk on the right and into the ascending aorta on the left side. The arch of the aorta will develop from the aortic sac, left 4th aortic arch, and a part of the left dorsal aorta. The *left sixth aortic arch* will participate to the formation of the pulmonary trunk, left pulmonary artery and ductus arteriosus; the right sixth arch will contribute to the right pulmonary artery. The branches of the arch of the aorta develop during the 5th and 6th weeks of gestation, and during the 8th week transformation of the aortic arch arteries leads to the development of an adult arterial system. This adult pattern is caused by degeneration or hypertrophy or anastomosis of some embryonic vessels and/or separation of one primitive vessel into two and/or formation of new arteries [3, 4, 6]. However, isolated anomalies of the arch of the aorta and its branches with normal heart can associate with chromosome 22q11 deletion [17].

Summarizing the developmental changes from stereomicroradiographic images of timed-gestation embryos, Effman et al. [1] noted the following: (1) partitioning of the truncus arteriosus; (2) initial symmetry of primitive III, IV and VI aortic arches and dorsal aortae; (3) development of the SAs from seventh CIAs caudally to their final location on the primitive aortic arch; (4) progressive decrease in the size of right IV and VI aortic arch derivatives; (5) attenuation of a segment of the right dorsal aorta distal to the right SA; (6) progressive rounding of the aortic arch; and (7) persisting large main pulmonary trunk and ductus arteriosus through late gestation.

As cited [16], primary VA stem contains three parts: (1) cervical VA with prevertebral and transversal segments; (2) atlantic part; and (3) subarachnoid part—a metencephalic longitudinal anastomosis in the direction of primitive ICA caudal branch. Any interruption or regression and reformation in the developmental process of VA can give rise to anomalies such as fenestration or duplication [12, 16, 18], as well as the variable origin [12, 16,] and/or involvement of only one VA in the BA origin [19].

Although these VA anomalies can be found both in the fetal [12, 16, 20] and adult period, in continuation of review of morphological features of the VA from prenatal to the postnatal age 21 [16], anatomo-pathological specificities of VA in a special sample of left and/or right VA variants will be highlighted.

Material and Methods

Case reports of the left and/or right VA variants from online available articles and library archives at the Faculty of Medicine of Niš dated from year 1928 to 2015 have been examined. These variants in 171 adult cases—patients and cadavers of (un)known gender that were investigated in 32 countries have been reviewed (Table 1).

Systematization of variable VAs was performed according to the location and relationships of variable VA with other supra-aortic arteries in the form of primary and complementary models. The capital letter — M (or M*) with corresponding Arabic number was used for labeling the patterns of variable left (or right) VA origin, respectively; two letters — MM* (with corresponding Arabic number) were used for marking different patterns of variable origin of both VAs. Marking of complementary model (variable VA origin associated with variation of the main supra-aortic arteries) was as follows: appropriate characters of primary models (M1... or M*1... or MM*1...) received a small letter of the alphabet. All models were personally sketched.

Unilateral and bilateral VA variability

Routine anatomy dissection of human cadavers during students' exercises, as well as surgical interventions and/or some radiological methods (aortography, or cerebral angiography, or selective vertebral angiography, or retrograde brachial angiography, or computer tomography angiography, or magnetic resonance angiography, or digital subtraction angiography, or color Doppler sonography) were applied as therapeutic and/or diagnostic procedures in patients because of different diseases during which variable VA and other vascular and/or visceral (ab)normalities were detected.

Left VA

General data

Only on the left side, a variable VA was found in 94/171 or 54.97% of cases (52 of male, 25 of female and 17 of unknown gender), from age 6 [21] to 95 [22].

Variable left VA was discovered in patients with different initial symptoms—headache [11, 13, 18, 23, 24], or motor weakness in the right upper limb [25, 26] and lower limb [27], or weakness and vertigo [23, 28], or dizziness [29] and gait instability [30, 31], or tingling on one side of the body [23] followed by cardiac murmur [21], or paresthesia in the left arm [32] and left limb [33], or chest pain [34, 35], or presyncope [36], or stroke [37, 38], or known presence of arterial aneurysm [38, 39], or transient ischemic attack [40], or dysphagia, dehydration and respiratory distress [7]. However, this VA variability was also discovered during health screening [41–43], or preoperative examination [9, 44], or suspected pacemaker failure [45], as well as in single angiographic images [15, 46–49].

Status of vessel stem

The left VA was presented as a simple or common vessel or total and segmentally duplicated at the origin from different vascular sources—the left SA and/or the arch of the aorta, or left CCA, or left external carotid artery (ECA), or left thyrocervical trunk, or so-called left brachiocephalic artery, or special left lateral SA (Fig. 1).

Table 1. Distribution of single cases of the variable vertebral artery origin

Country*	Case numbers			Σ
	Side			
	Left	Right	Left + Right	
Patients + Cadavers (m / f / u)				
1 Argentina	2 (2u)			2
2 Austria		1 (m)	1 (f)	2
3 Brazil	1(m)	1 (m)		2
4 Canada	1 (m)		1 (m)	2
5 China			2 (2f)	2
6 Croatia	1 (f)		1 (f)	2
7 Ethiopia	1 (m)			1
8 France		2 (m+f)	2 (2f)	4
9 Germany	6 (2m+4f)	2 (m+f)	1(f)	9
10 Greece	1 (u)	1 (u)		2
11 Grenada		1 (m)		1
12 India	32 (18m+3f+11u)	7 (2m+3f+2u)	5 (3m+1f+1u)	44
13 Iran	1 (m)			1
14 Ireland	1 (m)			1
15 Italy		1 (f)	2 (m+f)	3
16 Japan	12(5m+7f)	8 (5m+3f)	1 (m)	21
17 Korea	3 (2m+1f)	4 (2m+2f)	2 (2f)	9
18 Lithuania			1 (u)	1
19 Netherlands			1 (f)	1
20 Pakistan		1 (m)		1
21 Poland	1 (m)			1
22 Romania	1 (m)			1
23 Serbia	1 (m)			1
24 Slovakia	1 (f)			1
25 South Africa	6 (5m+1u)	1 (m)		7
26 Spain	1 (m)			1
27 Switzerland		1 (f)	1 (m)	2
28 Tanzania	1 (m)			1
29 Trinidad and Tobago	1 (m)			1
30 Turkey	5 (2m+2f+1u)	4 (3m+1f)	3 (3f)	12
31 UK	2 (f+u)	2 (m+u)	1 (f)	5
32 USA	12 (7m+5f)	10 (5m+4f+1u)	5 (2m+3f+1u)	26
Σ	94 (52m+25f+17u)	47 (25m+17f+5u)	30 (9m+18f+3u)	171 (85m+60f+26u)

*Alphabetical order

m, male; f, female; u, unknown gender

A single left VA of aortic origin was found between a brachio-carotid trunk and left SA [34, 46, 50], distally from the left SA [21, 23, 26, 35, 39, 48], and between the left CCA and left SA in most cases. Although infrequently, the left VA was found between the brachiocephalic trunk (BT) and left CCA [51], between the right SA and bicarotid trunk [24], between the left internal carotid artery (ICA) and left SA [52], and between the left CCA and left internal thoracic artery (InTA) [53] in single cases. Such unique cases were also the origins of the left VA from the left CCA [27] or so-called left brachiocephalic artery [45] or special left lateral SA [54]. The left VA had a common origin with the left SA at the arch of the aorta [53, 55–57], and with the left inferior thyroid artery (ITA) originating from ipsilateral SA or the arch of the aorta [41].

The left VA was totally duplicated in a female case described by Poonam et al. [58]. Namely, the authors discovered one hypoplastic VA of SA origin that coursed only in the V1 and V2 parts, and entered the C VI foramen

transversarium, whereas the second VA of ECA origin was dominant and took the course through V3 and V4 parts without entering any foramen transversarium. The left VA was segmentally duplicated while both segments originated from ipsilateral SA [28, 29, 47, 59], or SA and the arch of aorta [9, 13, 23, 25, 30, 32, 36–38, 40, 43, 49, 53, 59, 60], or the thyrocervical trunk and aorta [61].

The patterns of the variability of 93 left VAs and its association with variable main supra-aortic arteries are presented by 12 primary and 12 complementary models, respectively (Table 2).

Caliber

Some authors described that variable left VA was hypoplastic [26] and had 0.9 mm diameter [58], or was small with mild ostial narrowing [23, 45], or dilated [34, 81].

The diameter of the left VA of aortic origin ranged from 2 mm [62] to 8.4 mm [77]. A 9.5 mm diameter

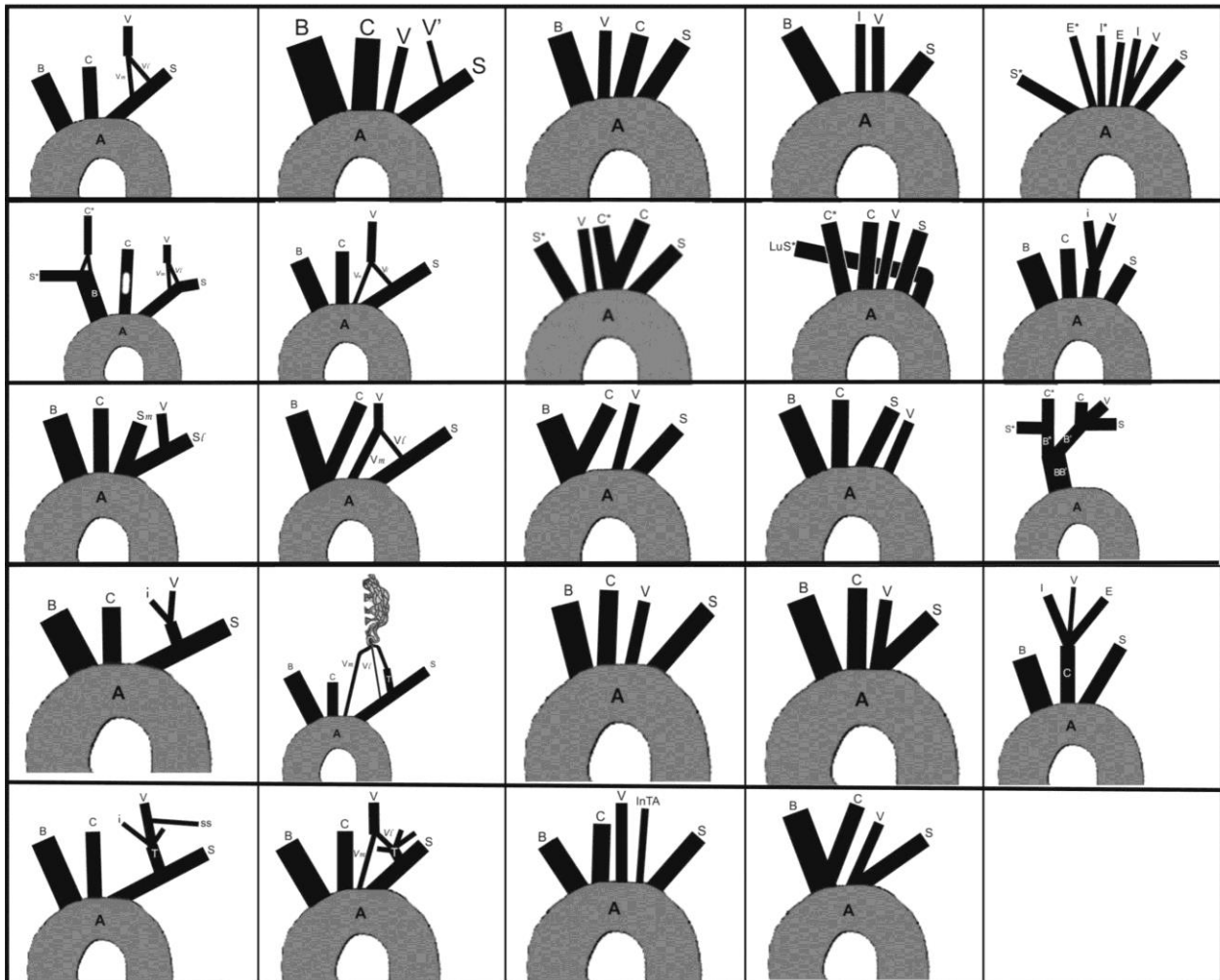


Fig. 1. Twenty four patterns of relationships of the variable left vertebral and main supra-aortic arteries.

A, arch of the aorta; B, brachiocephalic trunk; C (C*), left (right) common carotid a.; S (S*), left (right) subclavian a.; V_l (V_m), lateral (medial) segment of duplicated left vertebral artery in prevertebral part; V, left vertebral a.; S_l (S_m), lateral (medial) subclavian a.; i, left inferior thyroid a.; T, left thyrocervical trunk; ss, left suprascapular a.; LuS*, so-called lusoria right subclavian a.; BB', common trunk of so-called brachiocephalic arteries; B* (B'), so-called right (left) brachiocephalic a.; I, left internal carotid a.; E, left external carotid a.; InTA, left internal thoracic a.

was noted in a common stem of the left VA and SA in the first [56], and 10.08 mm in the second case [57].

Sikka and Jain [81] revealed that the diameters of the left VA at origin and at the entry of the corresponding cervical foramen transversarium were different — 4.9 mm and 3.9 mm, respectively. Ikegami et al. [64] described a pyramidal commencement of the left VA on the arch of the aorta with 8 mm in diameter, and its decrease to 4 mm at a point about 2 cm away from the origin.

Course in V1 part





There was no note about some special course of the variable VA in V1 part in relation to the course of the normal VA. There were descriptions that the left VA of aortic origin ascended upward and backward lying behind the left vagus, left brachiocephalic vein and left CCA [84], or in close to the left vagus and the apex of the left lung [56], sometimes of tortuous course [81]. The VA was crossed anteriorly by ITA [71], or by sympathetic trunk [77], or by thoracic duct [74]. Posteriorly, the VA was

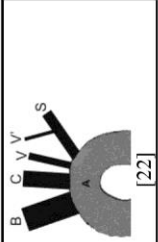
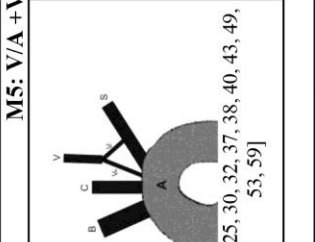

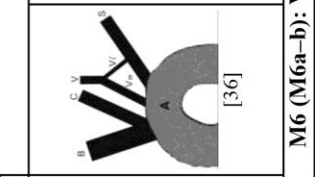
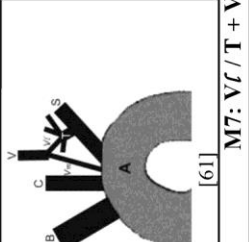
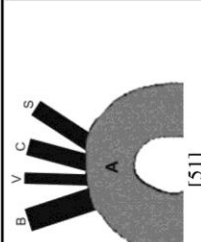
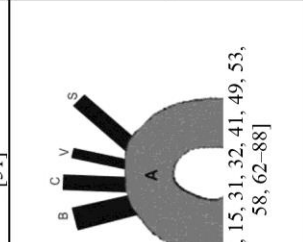
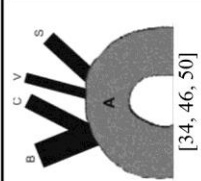
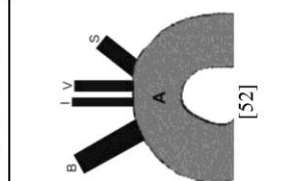
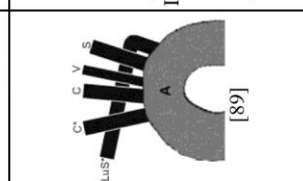
related to the longus cervicis muscle before entering the foramen transversarium of the cervical (C) vertebra at a higher level than that of the sixth [71].

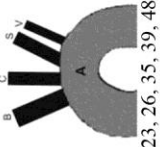
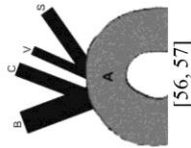
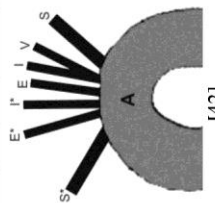
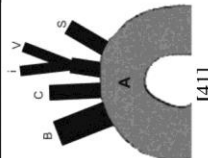
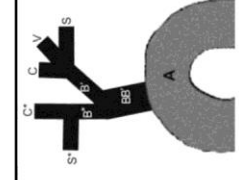
There were reports about different levels of the single (left) VA entry at the foramen transversarium of cervical vertebra — C VII [49, 56], C VI [54, 58, 65, 68–70, 72, 74, 75, 80, 82, 84], C V [11, 33, 62, 64, 71, 77], C IV [49, 55, 71, 81], C III [76, 87] and C I [27]. Moreover, in a case described by Poonam et al. [58], the left VA of aortic origin bifurcated at V1 part, where one vessel entered C VI, whereas the second vessel entered C V foramen transversarium. Unusual extension of the left VA of thyrocervical origin outside of the transverse foramina and penetration of dura in the level of foramen magnum was described in a 36-year-old woman [44].

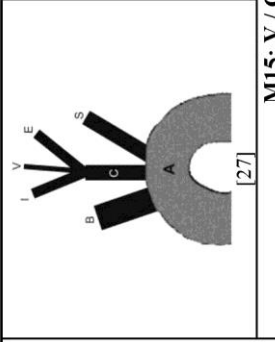
Medial and lateral segments of duplicated left VA also penetrated foramen transversarium at different levels [9, 28, 30, 38]. Their fusion differed from case to case — C VII [36], C VI [37], C V [13, 18, 23, 30, 32, 49], C IV [38, 43], or above C II [28].

Table 2. Display of primary and complementary models of left vertebral artery (VA)¹ variants in 94 cases²

Vascular source(s)	Schemes and description of primary models of variable left VA	Schemes and description of complementary models of variable left VA
Subclavian stem (S)	 <p>M1: Segmental duplication of the left VA of SA origin.</p> <p>[18, 28, 47]</p>	 <p>M1a: Additionally, fenestration of the left common carotid a. (CCA) and segmental duplication of the right CCA.</p> <p>[29]</p>
	So-called lateral left subclavian a (S _l)	<p>M1(M1a): V_l / S + V_m / S</p>
Sub-clavian branch	Vertebral -inferior thyroid trunk (V-i)	<p>M3: Common trunk of the left VA and inferior thyroid artery of SA origin.</p>  <p>[41]</p> <p>M3: V-i / S</p>
	Thyro-cervical trunk (T)	<p>M4: Left VA originates from the left thyrocervical trunk (TT).</p>  <p>[44]</p> <p>M4: V / T</p>

<p>Left subclavian a. and arch (A) of the aorta</p>	<p>Subclavian stem and aortic arch (S + A)</p>	 <p>[22]</p> <p>M5: V/A + V/S</p>  <p>[9, 13, 23, 25, 30, 32, 37, 38, 40, 43, 49, 53, 59]</p>	<p>M5: Left VA originates with two separate vessels from the arch and left SA.</p>	 <p>[36]</p>  <p>[60]</p> <p>M6a: Additionally, common stem of brachiocephalic trunk (BT) and left CCA-brachioarotid trunk [36].</p> <p>----- M6b: Additionally, an angiomatous vascular formation on the left side of the neck and connection of segmentally duplicated left VA with left IT [60].</p>
<p>Thyrocerivical trunk and aortic arch (T + A)</p>	<p>Thyrocerivical trunk and aortic arch (T + A)</p>	 <p>[61]</p> <p>M7: V/T + Vm / A</p>	<p>M7: Segmental duplication of the left VA of TT and aortic origin.</p>	<p>M6 (M6a-b): V/T / S + Vm / A</p>
<p>Arch of the aorta</p>	<p>Arch of the aorta</p>	 <p>[51]</p> <p>M8: V/T + T + Vm / A</p>  <p>[7, 11, 15, 31, 32, 41, 49, 53, 58, 62-88]</p>	<p>M8: Left VA originates from the arch as the second branch.</p> <p>M9: Left VA originates from the arch as the third branch.</p>	 <p>[34, 46, 50]</p> <p>M8a: Additionally, BT aplasia, right SA as the first branch of the arch; common stem of the left and right CCA (bicaerotid trunk) [24].</p> <p>----- M8b: Additionally, brachioarotid trunk [34, 46, 50].</p>  <p>[52]</p> <p>M9a: Additionally, left InTA as the fourth branch of the arch [53]</p> <p>----- M9b: Additionally, absence of both CCAs; left ICA as the second branch of the arch [52].</p> <p>----- M9c: Additionally, BT aplasia; right CCA and SA as the first and last branch of the arch, respectively [89].</p>  <p>[89]</p>

	 <p>[21, 23, 26, 35, 39, 48, 49]</p>	<p>M10: Left VA originates from the arch as the fourth (last) branch.</p>	
M8 (M18a-b); M9 (M19a-c); M10: V / A			
<p>M11a: Additionally, brachio-carotid trunk [56, 57].</p>	 <p>[56, 57]</p>	<p>M11: Common beginning of the left VA and SA from the arch.</p>	
M11 (M11a): V-S / A			
<p>M12a: Common beginning of the left VA and internal carotid a. Additionally, right SA as the first branch of the arch; right external carotid and internal carotid aa. as separated branches of the arch [42].</p>	 <p>[42]</p>		M12a: V-I / A
M13: V-i / A			
	 <p>[41]</p>	<p>M13: Common stem of the left VA and inferior thyroid artery originates from the arch.</p>	
<p>M14a: Left VA is a branch of so-called left brachiocephalic artery trifurcation; additionally, common stem of the left and right brachiocephalic arteries is the only branch of the arch.</p>	 <p>[45]</p>		M14a: V / B'
<p>So-called left brachiocephalic a. (B')</p>			

<p>Left common carotid a. (C)</p>		<p>M15: Left VA is a branch of the left CCA trifurcation.</p>	
---------------------------------------	---	--	--

¹Abbreviations of arteries in the text are explained during description of each pattern; abbreviations of same arteries in schemas include only the first capital letter of corresponding previous abbreviation because of practical reasons. The current relationship of VA and the main supra-aortic arteries is personally presented by "mathematical relation" in the row below corresponding pattern.

²The number of reported cases does not correspond to the number of cited references, because some authors discovered two or three same cases.

Abbreviations of arteries in inserts: A, arch of the aorta; B, brachiocephalic trunk; C (C*), left (right) common carotid a.; S (S*), left (right) subclavian a.; V (V_m), lateral (medial) segment of duplicated left vertebral artery in prevertebral part; V, left vertebral a.; S/I (S_m), lateral (medial) subclavian a.; T, left thyrocervical trunk; ss, left suprascapular a.; LuS*, so-called lusoria right subclavian a.; BB, common trunk of so-called brachiocephalic arteries; B* (B'), so-called right (left) brachiocephalic a.; I, left internal carotid a.; E, left external carotid a.; InTA, left internal thoracic a.

Collaterals

Although normally VA does not distribute collaterals in V1 part, some authors noted side branches of the variable left VA as follows: (1) suprascapular artery [44]; (2) InTA [35]; and (3) bronchial artery [31, 62].

An early bifurcation of VA of aortic origin in two vessels was also evidenced, but without description about their further course and termination [58].

Additional vascular variants

VA. A fenestration of the left VA stem after fusion of its initial double segments in 42-year-old woman [25] and 73-year-old man was also reported [30].

Distal duplication of the right VA at the craniocervical region [38], or ectatic diameter of the right VA followed segmental left VA duplication of aortic and subclavian origin [25] in two separate cases.

Aorta. There was variable number (1–6) and/or arrangement of branches of the arch (and descending aorta). The arch of the aorta with four branches of different arrangement was the most frequent in cases of variable left VA.

Rare cases of these patterns were as follows: (a) one branch—a common trunk of so-called brachiocephalic arteries [45]; (b) two branches—a brachio-carotid and left VA-SA stems [56, 57]; (c) three (variable) branches—brachio-carotid stem, a medial segment of the left VA and left SA in one [36], and BT, left CCA and left VA-SA stem in two cases [53, 55]; (d) five branches—right CCA, left CCA, left VA, left SA and lusoria right SA in the first [89], and BT, left CCA, left VA, left InTA and left SA in the second case [53]; (e) six branches—right SA, right ECA, right internal carotid artery (ICA), left ICA-VA stem, and left SA in the one case [42].

In addition, a mild dilatation of ascending aorta [26], or kinked and elongated arch of the aorta [21], or dilated arch and descending aorta [39] were associated with aortic origin of left VA distally from the left SA. Hypoplastic descending aorta was associated with segmental duplication of the left VA in one case [60].

Brachiocephalic trunk (BT). There were some cases of absence of normal BT [24, 45, 89], or the presence of a brachio-carotid stem [34, 36, 46, 50, 56, 57]. One case of BT aplasia was especially characteristic because of the presence of unusual common brachiocephalic stem that divided into two so-called brachiocephalic arteries, while the left vessel distributed the left CCA, VA and SA, whereas the right vessel bifurcated in the right CCA and SA [45].

The right ITA [64], and a variable thyroid ima artery of BT origin [86] were found in two separate cases of aortic origin of the left VA.

Common carotid artery (CCA). A common trunk of the left CCA and BT or brachio-carotid trunk was revealed in association with single left VA of aortic origin [34, 36, 46, 50, 56, 57], and segmental VA duplication [36].

The right CCA was the first branch of the arch of the aorta in a case of BT aplasia and aortic origin of left VA [89].

Fenestration of the left CCA and initial segmental duplication of the right CCA were followed by segmental duplication of the left VA [29]. Bilateral absence of CCA was discovered in two cases of aortic origin of VA [42, 52].

Subclavian artery (SA). A very interesting case was a seemingly normal left SA of aortic origin that immediately bifurcated into medial SA that gives most of the branches and the lateral ones that continue as the axillary artery [54]. The right SA as the first branch of the arch of the aorta was found in two cases of aortic origin of the left VA [24, 42]. So-called lusoria right SA (last branch of the arch of the aorta) persisted only in a case of BT aplasia and associated with aortic origin of the single VA [89].

In three separate cases of aortic origin of the left VA, InTA was revealed from the left VA [35], or the arch of the aorta [53], or the right SA about 1 cm before its continuation into axillary artery [85]. A bronchial artery was noted as a variable branch of the left SA in one case of aortic left VA origin [62]. There were two cases of variable ITA origin in the shape of ITA-VA common trunk originated from the arch of the aorta and from the left SA [41], and the third case of the right ITA branching from BT and in the presence of aortic origin of the left VA [64]. Aplasia of both ITAs was associated with aortic origin of single VA [75], and in a case of persistent thyroid ima artery [86].

Anterior cerebral artery (ACA). Right ACA branch supplying right MCA territory was associated with a common trunk of the left VA and ITA of SA origin [41]. Aplasia of the precommunicating part of the right ACA was associated with CCA origin of the left VA [27].

Posterior cerebral artery (PCA). There were two reports with data about fetal origin of the right PCA associated with segmental duplication [36], and single aortic origin of the left VA [15].

Persistent primitive arteries. Vasović et al. [7] and Lotfi et al. [24] discovered persistent left primitive trigeminal artery (PPTA) in association with aortic origin of the left VA, whereas Meila et al. [38] discovered the persistent right lateral spinal artery in a case of segmental duplication of the left VA.

Veins. Duplicate left vertebral veins at C V level [62] and between C III–IV and C V–VI [28] were revealed in cases of single aortic origin and segmental duplication of the left VA, respectively. Kawate et al. [62] also found a draining of these veins into venous angles on both sides. Ikegami et al. [64] noted enlarged veins in the neck and abdominal region in association with aortic origin of the left VA. Nathan and Seidel [89] revealed a termination of the thoracic duct in the right venous angle associated with aortic origin of left VA in a 64-year-old male.

An arteriovenous fistula between the right VA and ipsilateral veins was discovered in a 42-year-old female with a segmental duplication of the left VA [25].

Associated disorders

Basic congenital anomalies

1. Ehlers–Danlos syndrome (a group of inherited disorders that affect primarily skin, joints and blood vessel walls) and segmental left VA duplication of SA origin were presented in a 43-year-old male [18].
2. Chiari malformation (malformation of the skull) was associated with an absence of C IV foramen transversarium and VA origin from the left thyrocervical trunk in a 36-year-old female [44].
3. Dumbell neurofibroma (a type of tumor that can involve both the spinal canal and the posterior thoracic cavity) and a finding of a common trunk of left VA and ITA of aortic origin (between the left CCA and left SA) were found in a 33-year-old male [41].

Acquired pathological disorders

1. Dissections of some arteries — left VA [11], or both CCAs [34], or the right ICA [18] in a case of segmental duplication of the left VA of SA origin [18], or aortic origin of single left VA [11, 34] were noted.
2. Cerebral infarction (of different localization) was followed by segmental duplication of the left VA [18, 49], or by aortic origin of the left VA distal to the left SA [23], or by CCA origin of the left VA [27].
3. Aneurysms of different arteries — left VA and both ICAs [13], left PCA [23], left anterior temporal artery [43], ICA [38] were associated with segmental VA duplication, whereas an aneurysm of the descending aorta [39], or anterior communicating artery [41], or unnamed artery [49] was followed by aortic origin of single VA.
4. Partial thrombotic occlusion of different arteries — left ICA followed by a common trunk of the left VA and ITA [41], or the right VA and both ICAs followed by origin of the left VA from so-called left brachiocephalic artery [45].
5. Stenosis of some arteries of different grade — so-called left brachiocephalic artery [45], or the left VA [11, 37], or ICAs and/or left VA [23], or the right VA [51] was also noted.
6. Coarctation of the aorta (distally to the left SA origin) followed by segmental VA duplication was found in a 15-year-old girl [60]; pseudocoarctation of the aorta and perimembranous ventricular septal defect was associated with aortic origin of the left VA (distally to the left SA) in a 6-year-old boy [21].
7. Cerebral hemorrhage was presented in a 60-year-old woman with aortic VA origin distally to the left SA [49], whereas ventricular hemorrhage was diagnosed in a 46-year-old man with aortic origin of the left VA (between the right SA and bicarotid trunk) [24].
8. Subarachnoid hemorrhage was presented in a 52-year-old female with aortic origin of the left VA between the left CCA and left SA [41].
9. Angiomatous formation and segmental duplication of the left VA were revealed on the left side of the neck in a 15-year-old girl [60].

10. Tumor at the left cerebellopontine angle and segmental duplication of the left VA were discovered in a 27-year-old female [9].

Left and right VAs

General data

An association of variable left and right VAs, single or associated with supra-aortic arteries' variants was found in 30/171 (9 of male, 18 of female and 3 of unknown gender) or 17.54% of cases from age 4 [90] to 83 [91].

Variable left and right VAs were discovered in patients with different initial symptoms or reasons of investigation — a headache [25, 92, 93], followed by vertigo [94, 95], or cognitive impairment [91], or pain in the left eye and ear [8], or hemisensory disturbance [10], or trauma [96, 97], or subarachnoid hemorrhage [38], or personality change [98], or right-sided numbness [99], or right upper and lower limb weakness [90], or stroke [100], or central chest pain [101], or myocardial infarction [102], or carcinoma [103, 104], or spondyloepiphyseal dysplasia [105], or angiographic evaluation [106–109], or aortic valve replacement [110] or swallowing difficulties [111].

Status of vessels' stems

Variable left and right VAs were presented as simple or common vessels or segmentally duplicated at their origin. Vascular sources of variable VAs were SAs, arch of the aorta and descending aorta, BT and its common stem with the left CCA—brachio-carotid trunk, and right CCA (Fig. 2).

There were some cases of similar vascular sources —left and right SA in 2/28 cases [8, 91] and aorta in 5/28 cases [92, 96, 97, 104, 105]. Different vascular sources

were found in other 21 cases while aorta and right common carotid artery were more frequent vascular sources of the left and right VAs, respectively. Only Takasato et al. [8] described an association of double left (rudimentary and accessory) VAs with segmentally duplicated right VA of SA origin.

A variability of both VAs is presented by nine primary and nine complementary models (Table 3).

Caliber

Very interesting finding in some papers was relatively larger caliber of the variable right VA in relation to the same of the left VA. Namely, Rameshbabu et al. [108] noted that medial segment (2.2 mm in diameter) and lateral segment (2.4 mm in diameter) of the left VA united into single vessel of 3.2 mm in diameter. Simultaneously, medial segment (3.9 mm in diameter) and lateral segment (2.4 mm in diameter) of the right VA fused to form a single vessel of 4.4 mm in diameter. Diameter of the left VA of aortic origin was 3.3 mm, whereas the one of the right VA of CCA origin was 3.8 mm [114]. Diameter of the left VA of aortic origin was 6 mm, whereas the one of the right VA of BT origin was 7 mm [112].

Karcaltıncaaba et al. [97] described a widening or so-called Kommerell's diverticulum at aortic origin of the right VA.

Course in V1 part

Special course of variable (left or right) VA related to the unusual retroesophageal course of the right VA in cases of aortic origin of both VAs [96, 97, 102, 104]. They were also related to a location of the right VA in retrothyroid area and close to the thyroid gland in cases of its CCA origin [107] or segmental duplication of both VAs [38, 91, 100].

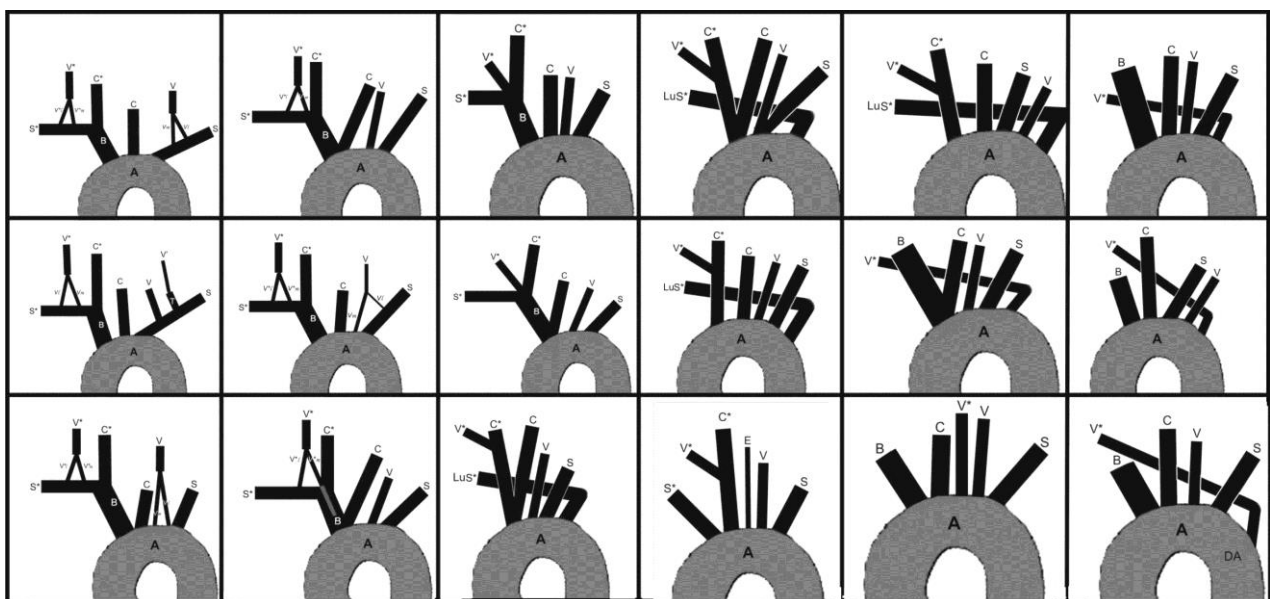
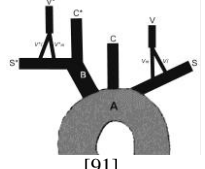
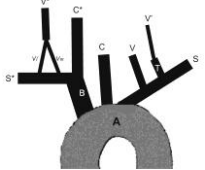
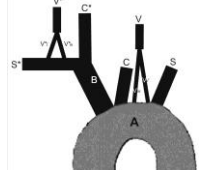
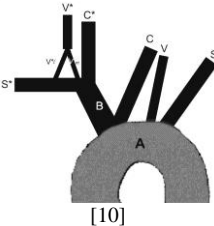
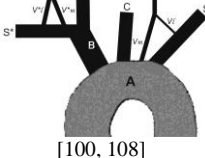
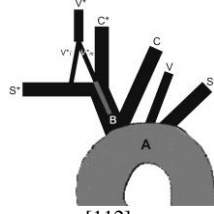
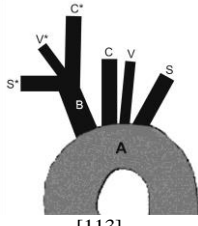
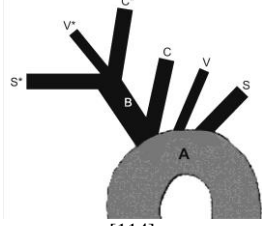
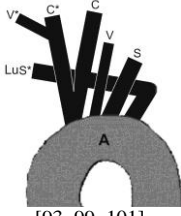
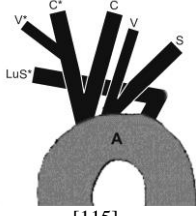
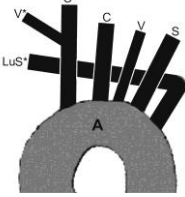
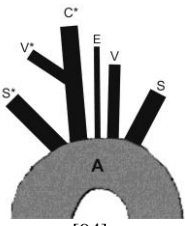
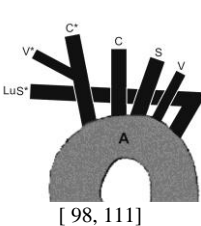


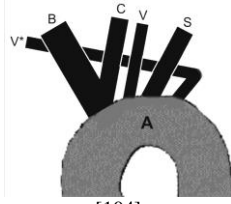
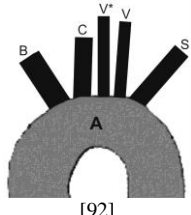
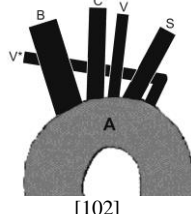
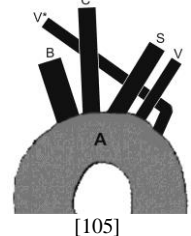
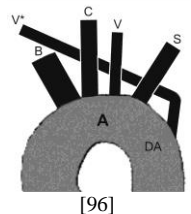
Fig. 2. Eighteen patterns of relationships of variable both vertebral and main supra-aortic arteries.

V (V^*), left (right) vertebral a.; $Vl(V^*l) + Vm(V^*m)$, lateral and medial segments of duplicated left (right) vertebral artery at prevertebral part; S (S^*), left (right) subclavian a.; LuS^* , so-called lusoria right subclavian a.; A , arch of the aorta; DA , descending aorta; B , brachiocephalic trunk; C (C^*), left (right) common carotid a.; E , left external carotid a.

Table 3. Display of primary and complementary models of left and right vertebral arteries (VAs)¹ variants in 30 cases²

Vascular source(s)	Schemes and description of primary models of variable left and right VAs	Schemes and description of complementary models of variable left and right VAs	
(Left subclavian a.) + (Right subclavian a.) (S + S*)	 <p>MM*1: Bilateral segmental duplication of vertebral aa. of subclavian (SA) origin.</p>		
	<p>MM*1: $(V_l / S + V_m / S) +$ $(V^*l / S^* + V^*m / S^*)$</p>		
(Left thyrocervical trunk) + (Right subclavian a.) (T + S*)	 <p>MM*2: Total duplication of the left VA of SA origin and segmental duplication of the right VA of SA origin.</p>		
	<p>MM*2: $(V^* / T) + (V^*l / S^* + V^*m / S^*)$</p>		
(Arch of aorta) + (Right subclavian a.) (A + S*)	 <p>MM*3: Bilateral segmental duplication of vertebral aa. of aortic origin on the left and SA origin on the right side.</p>		
			<p>MM*4a: Aortic origin of single left VA and segmental duplication of the right VA of SA origin. Additionally, common stem of brachiocephalic trunk (BT) and left common carotid artery (CCA) —brachioarotid trunk.</p>
		<p>MM*4a: $(V / A) + (V^*l / S^* + V^*m / S^*)$</p>	
(Arch of aorta + left subclavian a.) + (Right subclavian a.) (A + S) + (S*)	 <p>MM*5: Bilateral segmental duplication of vertebral aa. of aortic and SA origin on the left and SA origin on the right side.</p>		
	<p>MM*5: $(V_l / S + V_m / A) + (V^*l / S^* + V^*m / S^*)$</p>		
(Arch of aorta) + (Brachiocephalic trunk + right subclavian a.) (A) + (B + S*)			<p>MM*6a: Aortic origin of single left VA and segmental duplication of the right VA of SA origin of brachiocephalic origin. Additionally, brachioarotid trunk.</p>
		<p>MM*6a: $(V / A) + (V^*l / S^* + V^*m / BC)$</p>	

<p>(Arch of aorta + Brachiocephalic trunk) (A + B))</p>	 <p>[113]</p>	<p>MM*7: Aortic origin of single left VA and BT origin of the right VA.</p>	 <p>[114]</p>	<p>MM*7a: Additionally, brachio-carotid trunk.</p>
	<p>MM*7: (V / A) + (V* / B)</p>		<p>MM*7a: (V / A) + (V* / BC)</p>	
<p>(Arch of aorta) + (Right common carotid a.) (A + C*)</p>		 <p>[93, 99, 101]</p>	 <p>[115]</p>	<p>MM*8a: Aortic origin of single left VA (second branch) and CCA origin of the right VA. Additionally, common stem of the left and right CCA —bicarotid trunk; right SA is the last branch of the arch [93, 99, 101].</p> <p>MM*8b: Common stem of the left VA and SA (second branch) of aortic origin, and CCA origin of the right VA. Additionally, bicarotid trunk and right SA as the last branch of the arch [115].</p>
		<p>MM*8a: (V / A) + (V* / C*C)</p>	<p>MM*8b: (VS / A) + (V* / C*C)</p>	
	 <p>[90, 95, 103, 106, 107, 110, 116, 117]</p>	<p>MM*9a: Aortic origin of single left VA (third branch) and CCA origin of the right VA. Additionally, right SA is the last branch of the arch.</p>		
	 <p>[94]</p>	 <p>[98, 111]</p>	<p>MM*10a: Aortic origin of single left VA (fourth branch) and CCA origin of the right VA. Additionally, right SA is the first branch of the arch. Left CCA aplasia; left external carotid artery originated from the arch [94].</p> <p>MM*10b: Aortic origin of single left VA (fourth branch) and CCA origin of the right VA. Additionally, right SA is the last branch of the arch [98, 111].</p>	
		<p>MM*9a; MM*10a-b: (V / A) + (V* / C*)</p>		

			 <p>[104]</p>	<p>MM*11a: Aortic origin of the left (second branch) and right VAs (fourth branch). Additionally, brachio-carotid trunk.</p>
Aorta	Arch of aorta (A)	 <p>[92]</p>	<p>MM*12: Aortic origin of the right (third branch) and left VAs (fourth branch).</p>	
		 <p>[102]</p>	<p>MM*13: Aortic origin of the left (third branch) and right VAs (fifth branch).</p>	
		 <p>[105]</p>	<p>MM*14: Aortic origin of the left (fourth branch) and right VAs (fifth branch).</p>	
		MM*11a; MM*12-14: (V / A) + (V* / A)		
	(Arch of aorta) + (Descending aorta) (A + DA)	 <p>[96]</p>	<p>MM*15: Origin of the left VA (third branch) from the arch and right VA from descending aorta.</p>	
	MM*15: (V / A) + (V* / DA)			

¹Abbreviations of arteries in the text are explained during description of each pattern; abbreviations of same arteries in schemas include only the first capital letter from corresponding previous because of practical reasons. The current relationship of VA and the main supra-aortic arteries is personally presented by “mathematical relation” in the row below corresponding pattern.

²Patterns are based on 29 cases because one report was without data about precise location of variable left and right VAs on the arch of the aorta [109]

Abbreviations of arteries in inserts: *V* (*V**), left (right) vertebral a.; *Vl* (*V*l*) + *Vm* (*V*m*), lateral and medial segments of duplicated left (right) vertebral artery at prevertebral part; *V'*, left accessory vertebral a.; *S* (*S**), left (right) subclavian a.; *LuS**, so-called lusoria right subclavian a.; *A*, arch of the aorta; *DA*, descending aorta; *B*, brachiocephalic trunk; *C* (*C**), left (right) common carotid a.; *E*, left external carotid a.

Ionete and Omojola [91] and Mordasini et al. [100] described the course of both segmentally duplicated VAs as follows: The right medial segment originated proximally beyond the origin of SA and after a short loop it entered the carotid space, whereas the right lateral segment emanated from SA, coursed straight and entered the foramen transversarium of C VII vertebra. Both vessels joined in C IV–C V disk level to continue as the single right VA. On the left side, medial segment began from SA, looped slightly forward, and coursed straight up behind the left CCA, whereas lateral segment emanated just distal to the medial segment and entered the foramen transversarium of C VII vertebra; both vessels joined at C V–C VI disk level into single left VA. Meila et al. [38] presented the right lateral and medial segments at entry of the foramen transversarium of C VI and C IV vertebrae, respectively. They also found that left lateral segment entered the foramen transversarium of C V vertebra, whereas the medial segment entered it at C IV vertebra. Pauliukas [109] noted aortic origin of both VAs, but the left VA was the one which was strangulated by the sympathetic trunk and compressed at the entrance into C V foramen transversarium by longus colli muscle tendon.

Some variable VAs of single stems entered the foramen transversarium of the same cervical vertebra level on both sides [103, 105, 107, 112, 115], whereas some VAs entered the foramen transversarium at different levels [58, 102, 109]. So, the right VA of CCA origin penetrated C VI foramen transversarium, whereas the left VA of aortic origin penetrated C VII [109]; the left VA of aortic origin penetrated C VI foramen transversarium, whereas the right VA of aortic origin penetrated C IV foramen transversarium [102] or the left VA of aortic origin penetrated C IV, while the right VA of aortic origin penetrated C VII foramen transversarium [58].

Collaterals

Schwarzacher and Krammer [102] described ITA as a side branch of the left VA in a case of aortic origin of both VAs.

Additional vascular variants

Aorta. There was a variable number (3–5) and/or arrangement of branches of its arch and descending part. In addition, cervical location of the arch of the aorta above the level of the manubrium of sternum was found in a 77-year-old woman [102].

BT. Its aplasia [90, 93–95, 98, 99, 101, 103, 106, 107, 110, 114–116] was noted in 14/29 or 46.4% of the cases, whereas a common trunk of the BT and left CCA (brachio-carotid trunk) [10, 104, 111, 113] was found in 4/29 or 14.2% of the cases. BT was a vascular source of the thyroid ima artery in one case [102].

SA. So-called lusoria right SA (LuS) was found in previously mentioned 12 cases of BT aplasia, except in a case described by Abas et al. [94], when right SA was the first branch of the arch of the aorta. Besides, LuS coursed retroesophageally in most of these cases.

An early bifurcation of the left SA in two axillary arteries was associated with aortic origin of the left VA and segmental duplication of the right VA in a 46-year-old man [111]. Aplasia of the left thyrocervical trunk was revealed in an 83-year-old woman with aortic origin of both VAs [102].

CCA. A common trunk of BT and left CCA (brachio-carotid trunk) at the arch of the aorta was described in four cases [10, 104, 111, 113], a common trunk of left and right CCAs (bicarotid trunk) at the arch of the aorta was also found in four cases [93, 99, 101, 114]. Right CCA was the first single branch of the arch of the aorta in nine cases [90, 95, 98, 103, 106, 107, 110, 115, 116]. Both ECAs supplied intracranial collaterals through their dural branches in a 4-year-old girl with Moyamoya disease [90].

Aplasia of the left CCA and ICA followed by the aortic origin of the left VA and CCA origin of the right VA were discovered in a 43-year-old woman [94].

Posterior cerebral artery (PCA). Fetal origin of both PCAs associated with aortic origin of the left and right VAs was found in a 53-year-old man [92].

Associated disorders

Basic congenital anomaly

1. Down syndrome (trisomy 21) was a known congenital anomaly in a 4-year-old girl where an aortic origin of the left VA and CCA origin of the right VA was discovered [90].
2. Klippel-Feil syndrome (congenital fusion of any two of seven cervical vertebrae) was presented in a 43-year-old woman with aortic origin of the left VA and CCA origin of the right VA [94].

Acquired pathological disorders

1. Pseudocoarctation of aorta associated with aortic origin of both VAs was discovered in a 35-year-old woman after trauma [96].
2. Aneurysms of different arteries—right anterior cerebral artery [92], posterior communicating artery [38, 115], and descending aorta [101] were proved in 4/28 cases.
3. Partial stenosis of the left ICA [91, 100], or right SA [98, 99] was also associated with variable VA origin.
4. Partial occlusions of the right VA [101], or left internal jugular vein and sigmoid sinus [93] were proved in 40-year-old and 50-year-old women, respectively.
5. Cerebral infarct was developed in a 60-year-old woman with aortic origin of the left VA and segmental duplication of the right VA [10].
6. Thyroid carcinoma was primary reason of a preoperative evaluation in a 67-year-old woman when aortic origin of the left VA and CCA origin of the right VA were discovered [107].
7. Pial siderosis along the sulci of the right cerebral hemisphere were proved by MRI in a 68-year-old female with aortic origin of the left VA and CCA origin of the right VA [116].

Right VA

General data

Only unilaterally, variable right VA was found in 47/171 (25 of male, 17 of female and 5 of unknown gender) or 27.48% of cases from age 2 [118] to 76 [49, 119].

Variable right VA was discovered in patients with different initial symptoms or reasons of investigations—headache [26, 120, 121], or dizziness [30, 115, 122], or weakness [36], or blurred vision dizziness [123], or paresthesias [124], or transitory ischemic attacks [38, 125–128], or shortness of breath [118], or loss of consciousness [129], or progressive memory loss with incoherent behavior [130], or retrosternal chest pain [131], or carotid stenosis [132], or left hemiplegia [98], as well as after trauma [133, 134], or during preoperative evaluation [106, 135], or evaluation of mediastinal enlarged lymph nodes [136], or doubt for the left middle cerebral artery infarction [137] or by angiographic images [15, 49, 138–140].

Status of vessel stem

The vascular sources of variable right VA were the right SA and its (in)direct branches, the arch of the aorta, ascending and descending aorta, the brachiocephalic trunk, right CCA and right ECA (Fig. 3).

Segmentally duplicated right VA was revealed in seven cases [30, 38, 49, 122, 134, 141, 142]. Single right VA as a side branch of ipsilateral CCA was found in 10 cases [23, 49, 107, 115, 120, 125, 138, 143–145], whereas it was terminal branch of the right CCA in a case described by Morasch [140].

The right VA was of aortic origin in most cases; among them, it originated from the ascending aorta in one [131], and from descending aorta in another case [118].

In three cases the right VA originated singly from the brachiocephalic trunk [15], right thyrocervical trunk [146] and right supreme intercostal artery [147].

The right VA was presented as a simple or common vessel or segmentally duplicated at its origin; there were 9 primary and 9 complementary models (Table 4).

Caliber

Single right VA of aortic origin was described as “small” [131], or hypoplastic [26], or dilated with so-called Kommerell’s diverticulum at its beginning [133, 135, 136]. Right VA originating from the supreme intercostal artery [146], and thyrocervical trunk [147], measured 1 mm and 1.8 mm in diameter, respectively. Thomas et al. [134] described that the medial segment of duplicated right VA measured 1.3 mm in diameter and had a beaded appearance, whereas the lateral segment was of regular lumen and measured 3.1 mm in diameter.

Course in V1 part

There were some examples of unusual course of the variable right VA from the beginning to the entry at the foramen transversarium of cervical vertebra. So, Higashi et al. [119] observed that the right VA of aortic origin coursed into the first intercostal space and entered the first

costotransverse foramen, and then all of the transverse foramina from C VII to C I vertebra. Retroesophageal course of the right VA of aortic origin was also noted by some authors [26, 106, 121, 133, 135, 136, 139]. In addition, Fazan et al. [143] discovered that the right VA was crossed anterior to the ITA and upstream outside and anterior to the transverse foramina from C VII to C III, whereas Park et al. [107] reported about a location of the right VA in the retro-thyroid area and very close to the thyroid gland.

Segmentally duplicated right VA of SA origin were kinked at V1 part in one case [122], whereas simple VA stem was underdeveloped at intracranial part after fusion of its double segments in another case [113].

Hypoplastic right VA of supreme intercostal artery (SIA) origin anastomosed with the right persistent primitive hypoglossal artery (PPHA) at the internal opening of the hypoglossal canal in a 74-year-old Japanese male cadaver [146].

Collaterals

Only Higashi et al. [119] discovered the esophageal, prevertebral and second right posterior intercostal arteries as the right VA branches in V1 part.

Additional vascular variants

Left VA. It ended as the posterior inferior cerebellar artery in a case of aortic origin [36], or segmental duplication [122], or it made terminal trifurcation in a case of CCA origin [125]. Mild tortuosity and constricted portion of the left VA in a case of thyrocervical origin [147], or its hypoplasia in a case of external carotid origin of the right VA [129] were revealed.

There was a description of an anastomosis of the left VA and anterior inferior cerebellar artery in a case of SIA origin of the right VA [146].

Aorta. Multiple aortopulmonary collaterals supplying the left lung were found in a 2-year-old child [118].

BT. Aplasia of BT existed in 16/47 cases [23, 49, 98, 107, 116, 118, 120, 123, 125, 127, 131, 137, 138, 143, 145, 148]. A brachioarotid trunk was found in two cases [106, 139].

CCA. This artery on the right side was noted usually as the first single or a common branch of the arch of the aorta in cases of BT aplasia and/or origin of the right VA from ipsilateral CCA [23, 49, 98, 107, 116, 120, 123, 125, 127, 131, 137, 138, 143, 145], or aorta [118, 148]. Above mentioned brachioarotid trunk was associated with CCA or aortic origin of the right VA, respectively [106, 139]. The right CCA in a case described by Morasch [140] was bifurcated into right VA and ECA, because the right ICA was aplastic.

SA. Lusoria right SA was associated with origin of the right VA from ipsilateral CCA [23, 49, 98, 107, 116, 120, 125, 137, 138, 140, 143, 145], or the arch of the aorta [148], or ascending [131], or descending aorta [118]. Right SA, as the third branch of the arch of the aorta, passed behind the two CCAs and in front of the right VA in a case of CCA origin of the right VA [123].

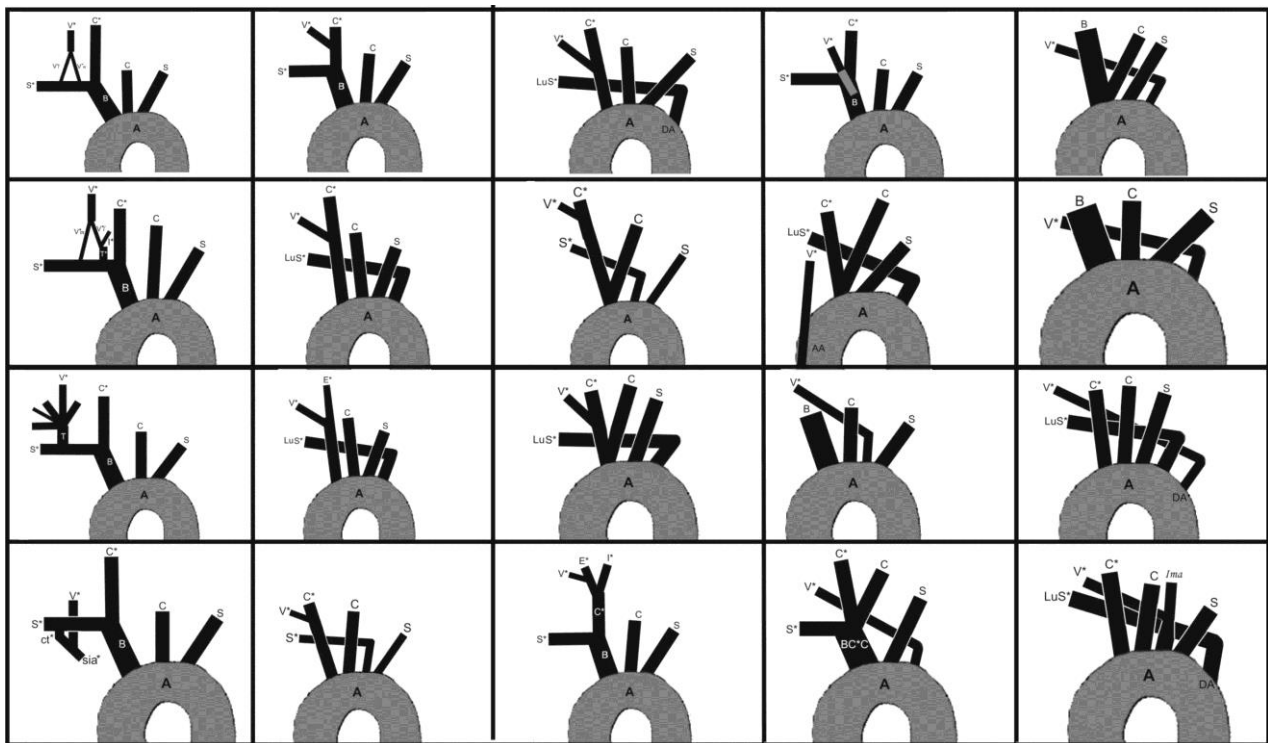


Fig. 3. Twenty patterns of relationships of the variable right vertebral and main supra-aortic arteries.

V^* , right vertebral a.; ($V^{*l} + V^{*m}$), lateral and medial segments of duplicated right vertebral artery at prevertebral part, S^* (S), right (left) subclavian a.; C^* (C), right (left) common carotid a.; B , brachiocephalic trunk; A , arch of the aorta; T^* , right thyrocervical trunk; ct^* , right costocervical trunk; sia^* , right supreme intercostal a.; AA , ascending aorta; LuS^* , so-called lusoria right subclavian a.; DA , descending aorta; E^* , right external carotid a.; I^* , right internal carotid a.; BC^*C , brachiobicaortid trunk; Ima , thyroidea ima a.

Aplasia of ITA was associated with the persistence of a common trunk of the right VA and thyroidea ima artery at the arch of the aorta [148].

Persistent primitive arteries. Right PPTA was associated with CCA origin of the right VA [120], whereas the right PPHA was associated with SIA origin of the right VA [146].

Associated disorders

Basic congenital anomaly

1. Cardiac anomaly (atrioventriculoarterial discordance, double outlet right ventricle, multiple muscular ventricular septal defects, and right ventricular outflow tract obstruction with hypoplastic right ventricle) was a primary reason of discovery of aortic origin of the right VA in a 2-year-old child [118].

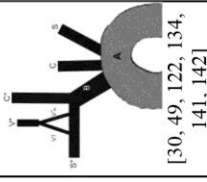
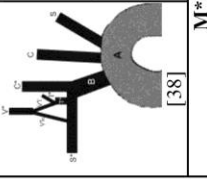
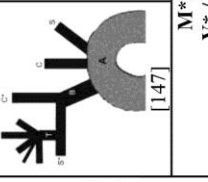
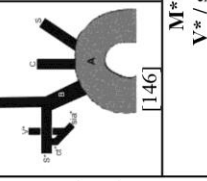
Acquired pathological disorders

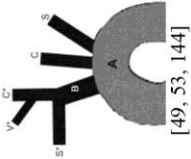
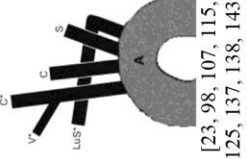

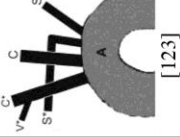

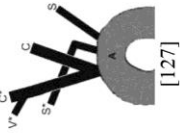

1. Dissection of the right VA was associated with its segmental duplication in a 49-year-old woman [134].
2. Aneurysms of different arteries—some cerebral artery [49], ascending [106] and abdominal aorta [135],

anterior communicating [129] and basilar arteries [134] were discovered in the presence of different origin of the right VA.




3. Infarction of the cerebrum [49], or cerebellum [36, 141], or the myocardium [23] was associated with segmental duplication, or aortic origin, or CCA origin of the right VA.
4. Partial stenosis of different arteries—right SA [98, 125] and right CCA [23, 125] was associated with CCA origin of the right VA.
5. Intracerebral hemorrhage was diagnosed simultaneously with aortic origin of the right VA after a cerebrovascular accident in a 40-year-old man [128].
6. Subarachnoid hemorrhage was diagnosed in a 32-year-old woman with CCA origin of the right VA [120].
7. Arteriovenous malformation in the right cerebellopontine angle was diagnosed simultaneously with CCA origin of the right VA in a 52-year-old woman [116].
8. Spinal neurinoma was a primary reason in a 57-year-old patient when the right VA of aortic origin was discovered [124].
9. Thyroglossal duct cyst was associated with CCA origin of the right VA in a 30-year-old man [107].

Table 4. Display of primary and complementary models of variants of the right vertebral artery (VA)¹ in 47 cases

Vascular source(s)		Schemes and description of primary models of variable right VA		Schemes and description of complementary models of variable right VA	
Right subclavian a.	Subclavian stem (S*)	 <p>M*1: Segmental duplication of the right VA of subclavian (SA) origin. [30, 49, 122, 134, 141, 142]</p>	<p>M*1: V*<i>l</i>+V*<i>m</i> / S*</p>		
		 <p>M*2: Segmental duplication of the right VA of subclavian (SA) and thyro-cervical (TT) origin. [38]</p>			
	Branch	 <p>M*3: Single right VA of TT origin. [147]</p>	<p>M*3: V* / T*</p>		
		 <p>M*4: Single right VA originates from the supreme intercostal a. [146]</p>			

<p>Right common carotid a. (C*)</p>	 <p>[49, 53, 144]</p>	<p>M*5: Single right VA of common carotid (CCA) origin.</p>	 <p>[23, 98, 107, 115, 125, 137, 138, 143]</p>	 <p>[140]</p>	 <p>[123]</p>	 <p>[120]</p>	 <p>[127]</p>	 <p>[49, 130, 145]</p>	<p>M*5a: Additionally, aplasia of the brachiocephalic trunk (BT); right CCA is the first branch and LuS* is the last branch of the arch of the aorta [23, 98, 107, 115, 125, 137, 138, 143]</p> <p>M*5b: Additionally, aplasia of the brachiocephalic trunk (BT); right CCA as the first aortic branch bifurcated into right VA and ECA, left CCA is the second; right SA is the third and left SA is the fourth branch of the arch [140].</p> <p>M5c: Additionally, aplasia of the brachiocephalic trunk (BT); right CCA is the first, left CCA is the second; right SA is the third and left SA is the fourth branch [123].</p> <p>M*5d: Additionally, aplasia of BT; right CCA is the first branch of the arch; LuS* is the branch of the descending aorta [120].</p> <p>M*5e: Additionally, aplasia of BT; common stem of the right and left CCAs (bicarotid trunk) is the first branch of the arch; right SA is the second branch of the arch of the aorta [127].</p> <p>M*5f: Additionally, aplasia of BT; common stem of the right and left CCAs (bicarotid trunk) is the first branch of the arch; LuS* is the last branch of the arch of the aorta [49, 130, 145].</p>
			<p>M*5 (M*5a-d): V* / C*</p>						<p>M*5e-f: V* / CC*</p>

Right external carotid a. (E*)	<p>[129] M*6: V* / E*</p>	<p>M*6: Single right VA of the right ECA origin.</p>	
Brachiocephalic trunk (B)	<p>[15] M*7: V* / B</p>	<p>M*7: Single right VA of BT origin.</p>	
Aorta	Ascending aorta (AA)		<p>[131] M*8a: V* / AA</p>
Arch of the aorta (A) and descending aorta (DA)	<p>[126]</p>	<p>M*8: Right VA, as the third branch of the arch of the aorta.</p>	<p>[106]</p> <p>M*8a: Additionally, common stem of so-called brachiocephalic aa. [106].</p> <p>M*8b: Additionally, brachiocephalic trunk is the first branch of the arch of the aorta. Right VA had retroesophageal course [121, 128, 139].</p>

 <p>[26, 36, 49, 119, 124, 128, 132, 133, 135, 136]</p>	<p>M*9: Right VA, as the fourth branch originates from the arch of the aorta distal to the left SA.</p>	<p>M*8 (M*8a–b): M*9: V* / A</p>	<p>M*10a: Right VA originates from the descending aorta. Additionally, BT aplasia; right CCA is the first branch of the arch; LuS* is the branch of the arch.</p>
 <p>[118]</p>	<p>M*10a: V* / DA</p>		
 <p>[148]</p>	<p>M*11a: Common stem of the right VA and thyroid ima artery originates from the arch of the aorta. Additionally, BT aplasia; right CCA is the first branch of the arch; right SA is the branch of the descending aorta.</p>	<p>M*11a: <i>Ima</i>V* / A</p>	

¹Abbreviations of arteries in the text are explained during description of each pattern; abbreviations of same arteries in schemas include only the first capital letter from corresponding previous because of practical reasons. The current relationship of VA and the main supra-aortic arteries is personally presented by “mathematical relation” in the row below corresponding pattern.

Abbreviations of arteries in inserts: *V**, right vertebral a.; (*V*/l+ V*/m*), lateral and medial segments of duplicated right vertebral artery at prevertebral part, *S** (*S*), right (left) subclavian a.; *C** (*C*), right (left) common carotid a.; *B*, brachiocephalic trunk; *A*, arch of the aorta; *T**, right thyrocervical trunk; *ct**, right thyrocervical trunk; *sid**, right supracoastal trunk; *AA*, ascending aorta; *LuS**, so-called lusoria right subclavian a.; *DA*, descending aorta; *BC*C*, brachiocephalic trunk; *Ima*, thyroid ima a.

Concluding Remarks

Common morphological features

Vascular sources. There were one or two or three vascular sources in the presence of variable left and/or right VA. The arch of the aorta was the most frequent source of single left VA and bilateral VA variabilities. Segmentally duplication of the VA was more frequent on the left side, while the vascular sources were the arch of aorta and left SA.

Although the right CCA was the vascular source of the single right VA in one third of cases, it was a vascular source of the right VA in almost half of cases with bilateral VA variability.

A specificity of the VA represented a pyramidal widening or so-called Kommerell' diverticulum of its beginning.

The origin of variable VA from the CCA (33 cases on the right and one on the left side) or right ECA in one case opens a problem of its denotation and differentiation from some of the persistent primitive CIA or PPIA.

Frequency of variable single VA origin. It was selected 94/171 cases of variable left VA, 30/171 cases of variable left and right VA and 47/171 cases of variable right VA. Our hypothesis is that the variability of the single left VA was two times higher than the variability of the right VA.

Unilateral vs. bilateral VA variability. Our hypothesis is that the variability of the single left or right VA was more frequent than bilateral variability of VA — three times for the left and 50% for the right side. In that manner, one cannot confirm the claim where one VA has an anomalous origin and the incidence of contralateral VA anomaly increases.

Sex difference. A variability of the left VA was more frequent in male specimens, whereas a variability of both VA was more frequent in female specimens, although there was no marking of gender for 25/171 cases.

Patterns of VA vs. total number of VA variability. The finding of 62 (30 of primary and 32 of complementary) patterns from 171 cases of unilateral or bilateral VA variability could suggest that in every third case can expect a special relationship of the VA and main supraaortic arteries.

Primary models vs. complementary models. Two thirds of total number of primary patterns or models of variable VA on one or both sides could indicate that it is the only vascular variation. However, most primary models were presented as single cases on the left and/or the right side, whereas 7/30 — four primary models on the left and three primary models on the right side were showed by three and more authors; this may mean that presented arrangements of VA(s) could be expected as isolated variation. Five complementary models (5/32) — one on the left, two on the right and two on both sides presented by three and more authors could indicate that only these VA variabilities are not isolated.

Course of VA. Retroesophageal course of the right VA of aortic origin could be expected in cases of aortic origin of both VAs, or aortic origin of single right VA distally from the left SA. From a morphofunctional view of point, the VA could be compressed at the higher level of entry at the foramen transversarium of cervical vertebra.

Although variable single VAs or their lateral or medial segments penetrated foramen transversarium from C IV to C VI vertebra in about one third of cases for each level, there was not a rule in relation to the VA beginning.

Caliber. It is well known that the posterior circulation is more vulnerable to ischemia in patients with VA severe hypoplasia, although most of these individuals remain asymptomatic if additional atherosclerotic factors are not associated. Having in mind only a few reports about the hypoplasia of VA, we can conclude that a way of the VA origin does not affect its caliber.

Side branches. The finding of unusual collaterals—the suprascapular artery, or ITA, or InTA, or bronchial artery, which branched from the left VA, as well as the esophageal, prevertebral and second right posterior intercostal arteries from the right VA, can point out on the VA variability.

Status of the arch of the aorta. Different patterns of branching of the arch of the aorta with respect to the number (from one to six), and/or position of these branches at the arch were main associated vascular variants with variable VA origin.

Associated supra-aortic arterial variants. A finding of lusoria right SA in almost half of the bilateral VA variability cases and in one third of variable right VA cases could be accepted as an indirect sign that variable right VA can be found, and vice versa.

Persistent primitive carotidbasilar anastomoses. According to the finding of only 5/171 cases—three PPTA, one PPHA and one lateral spinal artery, one can conclude that association of carotid-basilar anastomoses (CBAs) and a variable left VA origin was a coincidence, especially because of different embryologic base of VA and CBAs.

Common pathoanatomical conditions

Basic diseases. Nine different pathological processes — arterial dissections, aneurysms, cerebral infarction, partial thrombotic occlusion, stenosis, intracerebral hemorrhage, subarachnoid hemorrhage, (pseudo)coarctation of the aorta and different tumors, although rare, were common independently from unilateral or bilateral variability of the VA.

Pathologic changes of variable VA. On one side, some authors claimed that anomalous VA origin does not result in clinical symptoms, what was proved on the example of variable left VA where the right VA of normal (SA) origin was stenosed approximately of 60%. On the other hand, some authors described that higher incidence of spontaneous dissection was presented in cases of variable VA. However we revealed only eight patients with some

pathological changes — a dissection, or aneurysm, or stenosis of the left VA, and a dissection or thrombotic occlusion of the right VA.

References

1. Effman EL, Whitman SA, Smith BR. Aortic arch development. *RadioGraphics* 1986; 6:1065–1089.
2. Bhatia K, Ghabriel MN, Henneberg M. Anatomical variations in the branches of the human aortic arch: a recent study of a South Australian population. *Folia Morphol* 2005; 64:217–224.
3. Patten MB. *Human embryology*. Blakiston Co.: Philadelphia-Toronto, 1948.
4. Barry A. The aortic arch derivatives in the human adult. *Anat Rec* 1951; 111:221–238.
5. Padget DH. Designation of the embryonic intersegmental arteries in reference to the vertebral artery and subclavian stem. *Anat Rec* 1954; 119:349–356.
6. Lie TA (1972) Congenital malformations of the carotid and vertebral arterial systems, including the persistent anastomoses. In: Vinken PJ, Bruyn GW (eds) *Handbook of clinical neurology*, vol 12. North-Holland: Amsterdam, pp 289–339.
7. Vasović L, Đorđević Z, Stefanović N, Pavlović S, Bakić V, Antić S. Retke anomalije moždanih arterija. Perzistencija a. trigemini. *Acta med Medianae* 1990; 1:91–96. (In Serbian)
8. Takasato Y, Hayasji H, Kobayashi T, Hashimoto Y. Duplicated origin of the right vertebral artery with rudimentary and accessory left vertebral arteries. *Neuroradiology* 1992; 34: 287–289.
9. Komiya M, Nakajima H, Yamanaka K, Iwai Y. Dual origin of the vertebral artery: case report. *Neurol Med Chir (Tokyo)* 1999; 39:932–937.
10. Goddard AJP, Annesley-Williams D, Guthrie JA, Weston M. Duplication of the vertebral artery: report of two cases and review of literature. *Neuroradiology* 2001; 43:477–480.
11. Komiya M, Morikawa T, Nakajima H, Nishikawa M, Yasui T. High incidence of arterial dissection associated with left vertebral artery of aortic origin. *Neurol Med Chir (Tokyo)* 2001; 41:8–12.
12. Vasovic LP. Reevaluation of the morphological parameters according to 11 different duplications of the fetal vertebral artery at prevertebral (V1) and intracranial (V4) parts. *Cells Tissues Organs* 2004; 176:195–204.
13. Kendi ATK, Brace JR. Vertebral artery duplication and aneurysms: 64-slice multidetector CT findings. *Br J Radiol* 2009; 82:e216–218.
14. Vasović L, Mojsilović M, Anđelković Z, et al. Proatlantal intersegmental artery: a review of normal and pathological features. *Childs Nerv Syst* 2009; 25:411–421.
15. Mazioti A, Economopoulos N, Papakonstantinou O, et al. High resolution MR angiography of the posterior cerebral circulation: variants, incidence and clinical impact. *Open J Radiol* 2013; 3:209–214.
16. Vasović L, Jovanović I, Ugrenović S, Vlajković S, Jovanović P, Đorđević G. Extracranial segments of the vertebral artery: insight in the developmental changes up to the 21st year of life. In: Di Rocco C, Akalan N (eds) *Pediatric craniovertebral junction disesases*. Springer Int Publ Switzerland, 2014; pp 111–139.
17. Momma K, Matsuoka R, Takao A. Aortic arch anomalies associated with chromosome 22q11 deletion (CATCH 22). *Pediatr Cardiol* 1999; 20:97–102.
18. Polguy M, Jędrzejewski K, Topol M, Wiczorek-Pastusiak J, Majos A. Duplication of the left vertebral artery in a patient with dissection of the right internal carotid artery and Ehlers–Danlos syndrome: case report and review of the literature. *Anat Sci Int* 2013; 88:109–114.
19. Shoja MM, Tubbs RS, Khaki AA, Shokouhi G, Farahani RM, Moein A. A rare variation of the vertebral artery. *Folia Morphol* 2006; 65:167–170.
20. Sunitha V. A study of aortic arch in human fetuses of North Coastal Andhra Pradesh. *Int J Basic Applied Med Sci* 2012; 2:196–200.
21. Son JS, Hong KB, Chung DCW. Pseudocoarctation of the aorta associated with the anomalous origin of the left vertebral artery: a case report. *Korean J Radiol* 2008; 9:283–285.
22. Watanabe K, Saga T, Iwanaga J, Tabira Y, Yamaki K. A rare case of dual origin of the left vertebral artery without convergence. *Folia Morphol* 2015. file:///G:/Nova%20fascikla/Watanabe.pdf
23. Koenigsberg RA, Pereira L, Nair B, McCormick D, Schwartzman R. Unusual vertebral artery origins: examples and related pathology. *Catheter Cardiovasc Interv* 2003; 59:244–250.
24. Lotfi M, Nabavizadeh SA, Foroughi AA. Aortic arch vessel anomalies associated with persistent trigeminal artery. *Clin Imaging* 2012; 36:218–220.
25. Kim D-W. Concomitant dual origin and fenestration of the left vertebral artery resembling dissection. *J Korean Neurosurg Soc* 2009; 46:498–500.
26. Suh MJ, Lim CM, Park JK. Two cases of aberrant vertebral artery originating from aortic arch distal to left subclavian artery. *J Korean Soc Radiol* 2012; 67:157–160.
27. Patil PV, Patil AM, Apte AV, Attarde VY. Anomalous origin of the left vertebral artery from carotid bulb seen as “trifurcation” of left common carotid artery with acute infarct in ipsilateral thalamus: a case report. *J Neuroimaging* 2014. <http://onlinelibrary.wiley.com/doi/10.1111/jon.12172/abstract;jsessionid=C319F9EA4B19575F935729D212A908DC.f01t03>
28. Mahmutyazicioğlu K, Saraç K, Bölük A, Kutlu R. Duplicate origin of left vertebral artery with thrombosis at the origin: color Doppler sonography and CT angiography findings. *J Clin Ultrasound* 1998; 26:323–325.
29. Harnier S, Harzheim A, Limmroth V, Horz R, Kuhn J. Duplication of the common carotid artery and the ipsilateral vertebral artery with a fenestration of the contralateral common carotid artery. *Neurology India* 2008; 56:491–493.
30. Hashimoto H, Ohnishi H, Yuasa T, Kawaguchi S. Duplicate origin of the vertebral artery: report of two cases. *Neuroradiology* 1987; 29:301–303.
31. Amrhein TJ, Kim C, Smith TP, Washington SL. Bronchial artery arising from the left vertebral artery: case report and review of the literature. *J Clin Imaging Sci* 2011; 1:62. <http://www.ncbi.nlm.nih.gov/pmc/articles/PMC3261610/>
32. Nogueira TE, Chambers AA, Brueggemeyer MT, Miller TJ. Dual origin of the vertebral artery mimicking dissection. *AJNR Am J Neuroradiol* 1997; 18:382–384.
33. Kantarci F, Ozbayrak M, Gulsen F, Besirli K, Mihmanli I. Anatomical variations of the carotid-vertebral arteries: “double-vessel” sign on Doppler ultrasonography. *J Clin Ultrasound* 2011; 39:487–492.
34. Ad N, Lee P, Cox JL, Washington DC. Type A aortic dissection with associated anomaly of the carotid and vertebral vessels. *J Thorac Cardiovasc Surg* 2002; 123:570–571.
35. Kirch J, Williamson EE. Aberrant left internal thoracic artery off an aberrant vertebral artery. *Eur Heart J Adv* 2008. <http://eurheartj.oxfordjournals.org/content/ehj/early/2008/02/22/eurheartj.ehn039.full.pdf>
36. Satti SR, Cerniglia CA, Koenigsberg RA. Cervical vertebral artery variations: an anatomic study. *AJNR Am J Neuroradiol* 2007; 28:976–980.
37. Tobin WO, Killeen R, Kinsella JA, McCabe DJH. Dual origin of the left vertebral artery: extracranial MRA and CTA findings. *J Neurol Sci* 2010; 298:150–152.
38. Meila D, Tysiac M, M. Petersen M, et al. Origin and course of the extracranial vertebral artery: CTA findings and embryologic considerations. *Clin Neuroradiol* 2012; 22:327–333.

Acknowledgments: *The authors would like to thank the contract grant sponsor Ministry of Science and Technological Development of Republic of Serbia (nos. 43012, 41018 and 175092).*

39. Yamashiro S, Kuniyoshi Y, Arakaki K, Inafuku H, Morishima Y, Kise Y (2010) Total arch replacement with associated anomaly of the left vertebral artery. *Ann Thorac Cardiovasc Surg* 2010; 16:216–219.
40. Aja L. Vertebral artery partial duplication. *Radiopaedia.org*. 2015. <http://radiopaedia.org/cases/vertebral-artery-partial-duplication-1>
41. Sartor K, Freckmann N, Böker D-K. Related anomalies of origin of left vertebral and left inferior thyroid arteries. Report of three cases. *Neuroradiology* 1980; 19:27–30.
42. Supsupin EP Jr, Choi JM, Bonfante-Mejia EE, Sitton CW, Hochhauser L. Arteries detected by CT angiography: Case report. *Neurographics* 2012; 02:44–46.
43. Shin S-W, Park DW, Park CK, Lee YJ, Lee SR. Duplication of the left vertebral artery origin: a case report. *J Korean Soc Radiol* 2013; 68:1–4.
44. Strub WM, Leach JL, Tomsick TA. Left vertebral artery origin from the thyrocervical trunk: a unique vascular variant. *AJNR Am J Neuroradiol* 2006; 27:1155–1156.
45. McDowell DE, Grant MA, Gustafson RA. Single arterial trunk arising from the aortic arch. *Circulation* 1980; 62:181–182.
46. Jakanani GC, Adair V. Frequency of variations in aortic arch anatomy depicted on multidetector CT. *Clin Radiol* 2010; 65:481–487.
47. Anvekar B. *Neuroradiology cases: Duplication of vertebral artery*. 2011. <http://www.neuroradiologycases.com/2011/10/duplication-of-vertebral-artery.html>
48. Van der Merwe B, Ackermann C, Scheepers S, Moosa S. Is anomalous origin of the left vertebral artery indeed a rare finding? *S Afr J Rad* 2012; 16:144–146.
49. Uchino A, Saito N, Takahashi M, et al. Variations in the origin of the vertebral artery and its level of entry into the foramen transversarium diagnosed by CT angiography. *Neuroradiology* 2013; 55:585–594.
50. Manyama M, Rambau P, Gilyoma J, Mahalu W. A variant branching pattern of the aortic arch: a case report. *J Cardiothorac Surg* 2011; 6:29. <http://www.cardiothoracicsurgery.org/content/6/1/29>
51. Stănculescu R, Dorobăș B, Stănculescu L, Pantu C, Enyedi M, Filipoiu F. Anatomical variation in the origin of the left vertebral artery: literature review and case report. *Rev Rom J Funct Clin Macro Microsc Antropol* 2013; XII:235–238.
52. Rajeshwari MS. Bilateral absence of common carotid artery with variant branching pattern of aortic arch. *Int J Anat Res* 2013; 1:107–110.
53. Iyer AA. Some anomalies of origin of the vertebral artery. *J Anat* 1927; 62:121–122.
54. Nayeemuddin SM, Arora M, Ghatak S, Singh B. Variation in subclavian artery branches – a case report. *Indian J Clin Anat Physiol* 2014; 1:64–68.
55. Ottone NE, Casola L, Cirigliano V, et al. Two cases of left vertebral artery emerging from a trunk in common with the left subclavian artery from the aortic arch. *Int J Morphol* 2013; 31:646–649.
56. Yazar F, Yalçın B, Ozan H. Variation of the aortic arch branches: two main trunks originating from the aortic arch. *Gazi Med J* 2003; 14:181–184.
57. Babu CSR, Sharma V. Two common trunks arising from arch of aorta: case report and literature review of a very rare variation. *J Clin Diagn Res* 2015; 9:AD05–07.
58. Poonam, Singla RK, Sharmat T. Incidence of anomalous origins of vertebral artery – anatomical study and clinical significance. *J Clin Diagn Res* 2010; 4:2626–2631.
59. Suzuki S, Kuwabara Y, Hatano R, Iwai T. Duplicate origin of the left vertebral artery. *Neuroradiology* 1978; 15:27–29.
60. Glunčić V, Lukić IK, Kopljar M, Sabljarić Matovinović M, Hebrang A, Marušić A. Persistent cervical intersegmental artery and aortic coarctation. *Surg Radiol Anat* 2002; 24: 226–230.
61. Kubikova E, Osvaldova M, Mizerakova P, El Falougy H, Benuska J. A variable origin of the vertebral artery. *Bratisl Lek Listy* 2008; 109:28–30.
62. Kawate T, Futamata H, Kitami Y, Takeda S. Rare multiple combined anomaly of the vertebral vessels and bronchial artery. *Anat Sci Int* 2008; 83:267–272.
63. Anitha V. Abnormal origin of vertebral artery. *Int J Anat Variat* 2012; 3:1–3.
64. Ikegami A, Ohtani Y, Ohtani O. Bilateral variations of the vertebral arteries: The left originating from the aortic arch and the left and right entering the C5 transverse foramina. *Anat Sci Int* 2007; 82:175–179.
65. Imre N, Yalcin B, Ozan H. Unusual origin of the left vertebral artery. *Int J Anat Variat* 2010; 3:80–82.
66. Jayanthi V, Prakash, Nirmala Devi M, Geethanjali BS, Rajini T. Anomalous origin of the left vertebral artery from the arch of the aorta: review of the literature and a case report. *Folia Morphol* 2010; 69:258–260.
67. Jnanesh RS. Vertebral artery – a case report of anomalous origin. *Anatomica Karnataka* 2010; 4:56–58.
68. Kanasker N, Vatsalaswamy P, Sonje P. Variation in the origin of left vertebral artery: a case report. *Med J DY Patil Univ* 2014; 7:240–242.
69. Karande NA, Ambiye MV, Khambatta S. Anatomical variation of the origin of the left vertebral artery from the arch of aorta – a case report. *Int J Anat Variat* 2014; 7:96–99.
70. Kundu B, Ghosh I, Sengupta G, Bhattacharyya S. Anomalous origin of left vertebral artery. *Int J Anat Res* 2014; 2:557–560.
71. Maisel H. Some anomalies of the origin of the vertebral artery. *South Afr Med J* 1958; 48:1141–1142.
72. Nakka SR, Chaluvadi JK, Velichety SD, Pamujula S. Variation of origin of left vertebral artery: phylogenetic correlation and clinical implication. *Int J Med Health Sci* 2013; 2:472–474.
73. Nayak SR, Pai MM, Prabhu LV, D'Costa S, Shetty P. Anatomical organization of aortic arch variations in the India: embryological basis and review. *J Vasc Bras* 2006; 5:95–100.
74. Oza S, Gujar S, Modasia U, et al. A study on the variant origins of vertebral artery. *Int J Med Sci Publ Health* 2014; 3:349–351.
75. Panicker HK, Tarnekar A, Dhawane V, Ghosh SK. Anomalous origin of left vertebral artery—embryological basis and applied aspects – a case report. *J Anat Soc India* 2002; 51:234–235.
76. Patasi B, Yeung A, Goodwin S, Jalali A. Anatomical variation of the origin of the left vertebral artery. *Int J Anat Variat* 2009; 2: 83–85.
77. Premhandran D, Madhyastha S. Anomalous origin of the left vertebral artery. *Rev Arg de Anat Clin* 2013; 5:33–38.
78. Shetty RK, Shivarama CH, Dinesh SM, Avadhani R. Abnormal origin of the left vertebral artery: A case study. *Int J Biomed Res* 2013; 04 (05). <http://ijbr.ssjournals.com/index.php/journal/article/viewFile/252/235>
79. Rajangam S, Kulkarni RN. Left vertebral artery and variation in its origin. *J Mahatma Gandhi Inst Med Sci* 2013; 18:55–57.
80. Shankar VV, Radhika PM, Sheshgiri C. Anomalous origin of left vertebral artery. *Int J Health Allied Sci* 2013; 2:216–218.
81. Sikka A, Jain A. Bilateral variation in the origin and course of the vertebral artery. *Anat Res Int* 2012; (2012). <http://www.hindawi.com/journals/ari/2012/580765/>
82. Singla RK, Sharma T, Sachdeva K. Variant origin of left vertebral artery. *Int J Anat Variat* 2010; 3:97–99.
83. Suresh R, Ovchinnikov N, McRae A. Variations in the branching pattern of the aortic arch in three Trinidadians. *West Indian Med J* 2006; 55:351–353.
84. Ughade JM, Kardile PB, Ughade MN, Chaware PN, Pandit SV. Anomalous arch of aorta given rise to left vertebral artery. *Int J Biol Med Res* 2012; 3:2452–2454.
85. Vorster W, du Plooy PT, Meiring JH. Abnormal origin of internal thoracic and vertebral arteries. *Clin Anat* 1998; 11:33–37.
86. Yılmaz E, Çelik HH, Durgun B, Atasever A, İlgi S. Arteria thyroidea ima arising from the brachiocephalic trunk with bilateral absence of inferior thyroid arteries: case report. *Surg Radiol Anat* 1993; 15:197–199.
87. Aragão JA, Dos Santos JCC, Cabral DRC, Filho CAO, Barros HP. Anomalous origin of the left vertebral artery in humans: A rare anatomical finding? *Int J Basic Appl Sci* 2015; 4:224–227.
88. Berhe T. Variant origin of left vertebral artery: Cadaveric case report. *Int J Pharma Sci Res (IJSR)* 2015; 6:1117–1121.
89. Nathan H, Seidel MR. The association of a retroesophageal right subclavian artery, a right-sided terminating thoracic duct, and a left vertebral artery of aortic origin: anatomical and clinical consideration. *Acta Anat* 1983; 117:362–373.

90. Mishra A, Pendharakar H, Jayadaevan ER, Bodhey N. Anomalous origin of bilateral vertebral arteries in a child with Down syndrome and Moyamoya disease. A case report. *Interv Neuroradiol* 2012; 18:259–263.
91. Ionete C, Omojola MF. MR angiographic demonstration of bilateral duplication of the extracranial vertebral artery: unusual course and review of the literature *AJNR Am J Neuroradiol* 2006; 27:1304–1306.
92. Albayram S, Gailloud P, Wasserman BA. Bilateral arch origin of the vertebral arteries. *AJNR Am J Neuroradiol* 2002; 23:455–458.
93. Tuncel SA, Çağlı B, Şengül E, Ünlü E. Anomalous origin of both vertebral arteries combined with aberrant right subclavian artery and truncus bicaroticus. *Nobel Med* 2012; 8:124–126.
94. Abbas J, Nazzal M, Serrano P, Elmer L (2006) Aortic arch abnormality with Klippel-Feil syndrome. *Vascular* 2006; 14:43–46.
95. Wackenheim A, Kleinclaus D. Artère sous-clavière droite lusoria avec anomalie d'origine des deux artères vertébrales. Une cause d'insuffisance vertébrobasilaire fonctionnelle. *J Radiol* 1979; 60: 657–658.
96. Al-Okaili R, Schwartz ED. Bilateral aortic origins of the vertebral arteries with right vertebral artery arising distal to left subclavian artery: case report. *Surg Neurol* 2007; 67:174–176.
97. Karcaaltincaba M, Strottman J, Washington L. Multidetector-row CT angiographic findings in the bilateral aortic arch origin of the vertebral arteries. *AJNR Am J Neuroradiol* 2003; 24:157.
98. Bernardi L, Dettori P. Angiographic study of a rare anomalous origin of the vertebral artery. *Neuroradiology* 1975; 9:43–47.
99. Velioğlu M, Kaya S, Ertugru EE. Arteries get confused: an arch variation. *JBR–BTR* 2014; 97:28–29.
100. Mordasini P, Schmidt F, Schroth G, Remonda L. Asymmetrical bilateral duplication of the extracranial vertebral arteries: report of a unique case. *Eur J Radiol Extra* 2008; 67:e91–94.
101. Türkvtan A, Akgül A, Yener O, Ölçer T, Cumhuri T. Anomalous origin of bilateral vertebral arteries associated with an aberrant right subclavian artery and a common carotid trunk: case report. *Türkiye Klinikleri J Med Sci* 2010; 30:1116–1120.
102. Schwarzacher SW, Krammer EB. Complex anomalies of the human aortic arch: unique case system with both vertebral arteries as additional branches of the aortic arch. *Anat Rec* 1989; 225:246–250.
103. Ka-Tak W, Lam WWM, Yu SCH. MDCT of an aberrant right subclavian artery and of bilateral vertebral arteries with anomalous origins. *AJR* 2007; 188:W274–275.
104. Verin A-L, Creuze N, Musset D. Multidetector CT scan findings of a right aberrant retroesophageal vertebral artery with an anomalous origin from a cervical aortic arch. *Chest* 2010; 138:418–422.
105. Goray VB, Joshi AR, Garg A, Merchant S, Yadav B, Maheshwari P. Aortic arch variation: a unique case with anomalous origin of both vertebral arteries as additional branches of the aortic arch distal to left subclavian artery. *AJNR Am J Neuroradiol* 2005; 26:93–95.
106. Kau T, Gasser J, Lesnik G, Sinzig M, Hausegger KA. Two exceptionally rare branching patterns of the aortic arch. *Vasc Med* 2008; 13:89–90.
107. Park KJ, Kim SH, Kim BS, Choi G. Two cases of aberrant right subclavian artery and right vertebral artery that originated from the right common carotid artery. *Korean J Radiol* 2008; 9: S39–42.
108. Rameshbabu C S, Gupta OP, Gupta KK, Qasim M. Bilateral asymmetrical duplicated origin of vertebral arteries: Multidetector row CT angiographic study. *Indian J Radiol Imaging* [serial online] 2014; 24:61–65.
109. Pauliukas P. Loops, kinks and anomalies of vertebral arteries. 2014. <http://www.pauliukoklinika.lt/get.php?f.6365>
110. Fiorini S, Gabelloni M, Bemi P, Faggioni L, Bartolozzi C. Multiple variants of supra-aortic vessels (online). *Euro Soc Radiol* 2013. <http://eurorad.org/eurorad/case.php?id=10471>
111. Tsai I-C, Tzeng W-S, Lee T, et al. Vertebral and carotid artery anomalies in patients with aberrant right subclavian arteries. *Pediatr Radiol* 2011; 37:1007–1012.
112. Kiss J. Bifid origin of the right vertebral artery: a case report. *Radiology* 1968; 91:931.
113. Hadimani GA, Desai SD, Bagoji IB, Sahana BN. Bilateral variation in the origin of vertebral artery. *J Pharm Sci Res* 2013; 5:196–198.
114. Kumar SGL, Pamidi N, Somayaji S N, Nayak S, Vollala VR. Anomalous branching pattern of the aortic arch and its clinical applications. *Singapore Med J* 2010; 51:e182–183.
115. Gluncic V, Ivkic G, Marin D, Percac S. Anomalous origin of both vertebral arteries. *Clin Anat* 1999; 12:281–284.
116. Kim Y-D, Yeo H-T, Cho Y-D. Anomalous variations of the origin and course of vertebral arteries in patients with retroesophageal right subclavian artery. *J Korean Neurosurg Soc* 2009; 45:297–299.
117. Brouwer PA, Souza MPS, Agid R, TerBrugge KG. A five-vessel aortic arch with an anomalous origin of both vertebral arteries and an aberrant right subclavian artery. *Interv Neuroradiol* 2004; 10:309–314.
118. Mukkannavar SB, Kuthe SA, Mishra AK, Rohit MK. Aberrant right vertebral artery from descending thoracic aorta. *Ann Thorac Surg* 2013; 96:1074–1076.
119. Higashi N, Shimada H, Simamura E, Hatta T. Right vertebral artery as the fourth branch of the aortic arch. *Anat Sci Int* 2008; 83:314–318.
120. Ishihara H, San Millán Ruíz D, Abdo G, et al. Combination of rare right arterial variation with anomalous origins of the vertebral artery, aberrant subclavian artery and persistent trigeminal artery. A case report. *Interv Neuroradiol* 2011; 17:339–342.
121. Case D, Seinfeld J, Folzenlogen Z, Kumpe D. Anomalous right vertebral artery originating from the aortic arch distal to the left subclavian artery: a case report and review of the literature. *J Vasc Intervent Radiol* 2015; 8:21–24.
122. Nishijima M, Harada J, Akai T, Endo S, Takaku A. Operative correction of a kinked duplicate origin of the vertebral artery in a patient with dizziness. Case report. *Surg Neurol* 1989; 32:356–359.
123. Best IM, Bumpers HL. Anomalous origin of the right vertebral, subclavian, and common carotid arteries in a patient with four-vessel aortic arch. *Ann Vasc Surg* 2002; 16:231–234.
124. Lemke AJ, Benndorf G, Liebig T, Felix R. Anomalous origin of the right vertebral artery: review of the literature and case report of the right vertebral artery origin distal to the left subclavian artery. *AJNR Am J Neuroradiol* 1999; 20:1318–1321.
125. Dissanayake PH, Bhattacharya JJ, Teasdale EV. Terminal triplication of the left vertebral artery: a unique variation. *Interv Neuroradiol* 2007; 13:399–401.
126. Wasserman BA, Mikulis DJ, Manzione JY. Origin of the right vertebral artery from the left side of the aortic arch proximal to the origin of the left subclavian artery. *AJR* 1992; 13:355–358.
127. Ugurlucan M, Sayin OA, Surmen B, Alpagut U, Dayioglu E, Onursal E. Common carotid trunk & right vertebral artery originating from the right common carotid artery in a patient with carotid stenosis. *J Card Surg* 2006; 21:423–424.
128. Ligege P, Scholtz L. Rare variation in the origin of the right vertebral artery. *SA J Radiol* 2004; 8:34–35.
129. Nasir S, Hussain SA, Mansoor MA, Sharif S. Anomalous origin of right vertebral artery from right external carotid artery. *J Coll Phys Surg Pakistan* 2010; 20: 208–210.
130. Kumar S, Kumar P. Truncus bicaroticus with aberrant right subclavian artery and origin of right vertebral from right common carotid artery. *Surg Radiol Anat* 2014; 36:829–831.
131. Akdeniz B, Yilmaz E, Pekel N, Ergul BU. Anomalous origin of the right vertebral artery from the ascending aorta in the presence of an aberrant right subclavian artery. *Int J Cardiovasc Imaging* 2007; 23:39–42.
132. Dabus G, Walker MT. Right vertebral artery arising from the aortic arch distal to the left subclavian artery diagnosed with magnetic resonance angiography. *Arch Neurol* 2010; 67:508–509.
133. Baek SH, MD, Baek HJ. Aberrant right vertebral artery originating from the aortic arch distal to the left subclavian artery: a case report. *J Korean Soc Radiol* 2014; 70:191–194.

134. Thomas AJ, Germanwala AV, Vora N, et al. Dual origin extracranial vertebral artery: case report and embryology. *J Neuroimaging* 2008; 18:173–176.
135. Canyigit M, Akgoz A, Koksall A, Yucesou C. Aberrant right vertebral artery: a rare aortic arch anomaly. *Br J Radiol* 2009; 82:789–791
136. Lacout A, Khalil A, Figl A, Liloku R, Marcy P-Y. Vertebral arteria lusoria: a life-threatening condition for esophageal surgery. *Surg Radiol Anat* 2012; 34:381–383.
137. Layton KF, Miller GM, Kalina P. Aberrant origin of the right vertebral artery from the right common carotid artery: depiction of a rare vascular anomaly on magnetic resonance angiography. *JVIR* 2006; 17:1065–1067.
138. Jakanani GC, Adair V. Frequency of variations in aortic arch anatomy depicted on multidetector CT. *Clin Radiol* 2010; 65: 481–487.
139. Lale P, Toprak U, Yagız G, Kaya T, Uyanık SA. Variations in the branching pattern of the aortic arch detected with computerized tomography angiography. *Adv Radiol* 2014 (2014). <http://www.hindawi.com/journals/ara/2014/969728/>
140. Morasch MD. Vertebral artery disease. 2015. <http://clinicalgate.com/vertebral-artery-disease/>
141. Melki E, Nasser G, Vandendries C, Adams D, Ducreux D, Denier C. Congenital vertebral duplication: A predisposing risk factor for dissection. *J Neurol Sci* 2012; 314:161–162.
142. Rath G, Prakash R. Double vertebral artery in an Indian cadaver. *Anat Clin* 1984; 6:117–119.
143. Fazan VS, Caetano AG, Filho OA. Anomalous origin and cervical course of the vertebral artery in the presence of a retrosophageal right subclavian artery. *Clin Anat* 2004; 17:354–357.
144. Jamkar AA, Sabnis AS. An unusual variation of vertebral artery. *Int J Anat Variat* 2014; 7:32–34.
145. Windle WF, Zeiss FR, Adamski MS. Note on a case of anomalous right vertebral and subclavian arteries. *J Anat* 1928; 62:512–514.
146. Terayama R, Toyokuni Y, Nakagawa S, et al. Persistent hypoglossal artery with hypoplasia of the vertebral and posterior communicating arteries. *Anat Sci Int* 2011; 86:58–61.
147. Veeramani R, Shankar N. An unusual origin of the right vertebral artery from the thyrocervical trunk – a case report. *Int J Basic Med Sci* 2013; 5(3). http://www.ijbms.com/anatomy/an-unusual-origin-of-the-right-vertebral-artery-from-the-thyrocervical-trunk-%E2%80%93-a-case-report/#.VD4_wVcqPxU
148. Loukas M, Louis RG Jr, Gaspard J, Fudalej M, Tubbs RS, Merbs W. A retrotracheal right subclavian artery in association with a vertebral artery and thyroidea ima. *Folia Morphol* 2006; 65:236–241.