

Research Article: Basic and Applied Anatomy

Morphometric study of the lumbosacral spine and some of its related angles in Lebanese adult females

El Sayed S. Atta-Alla^{1,*}, Ibtissam M. Saab², Mohamed El Shishtawy³, Khodor Haidar Hassan³Departments of ¹Anatomy and Embryology, ²Physical Therapy and ³Forensic Medicine and Toxicology, Beirut Arab University

Submitted June 20, 2013; accepted revised October 10, 2013

Abstract

The present study was undertaken to examine the morphometric characteristics of lumbar vertebrae, lumbar intervertebral discs and some important related angles in Lebanese adult females. The subjects of this study were thirty Lebanese adult females aged between 18-22 years. The subjects were selected among students of the faculty of health sciences, Beirut Arab University. Two plain radiographic views for the lumbosacral spine were taken for each subject, an anteroposterior view and a lateral view. Measurements were made directly on the X-ray films using Vernier calliper and were recorded to the nearest tenth of a millimetre. The following measurements were taken for each lumbar vertebra: the anterior height of the body, the posterior height of the body, the horizontal diameter of the pedicle, the vertical diameter of the pedicle, the interpedicular distance, the width (transverse diameter) of the body. Also the anterior height, the posterior height and the anteroposterior diameter (disc depth) of the intervertebral disc were measured. In addition, the following angles were measured: the angle of lumbar lordosis, the lumbosacral angle and the angle of sacral inclination. The mean and standard deviation were calculated and recorded. The results offer a base line reference for normal Lebanese adult females and a guidance to clinicians for the evaluation and management of subjects complaining of low back pain, in order to propose specific preventive or rehabilitation protocols to prevent low back pain as a function of spinal alignment. Moreover, these normal figures could also be of forensic importance because of the observed racial, ethnic and regional variations.

Key words

Lumbar vertebrae, lumbar intervertebral discs, pedicle, lumbar lordosis, lumbosacral angle and sacral inclination angle.

Introduction

Lumbar lordosis is defined as the curvature assumed by the intact lumbar spine to compensate for the inclination of the sacrum, restore an upward orientation and consequently avoid forward inclination (Skaf et al., 2011).

The curvature of the lumbar spine (lumbar lordosis) and the role it plays in the transmission of body weight have been studied extensively (Hellems and Keats, 1971; Pelker and Gage, 1982; Fernand and Fox, 1985). Evidence has suggested that the interplay between the curvature and the ligaments that maintain it imparts a resil-

* Corresponding author. E-mail: Soliman449@yahoo.com.

ience that is important in protecting the vertebral column against compression and strain in various positions and during movements (Pelker and Gage, 1982). The shape of the lumbar curve varies in different individuals (Hellems and Keats, 1971); nevertheless, it has been noted that some cases of low back pain are attributable to abnormal posture or marked alteration of the curve (Pelker and Gage, 1982).

Anterior access to the L1-L5 vertebrae and discs may be technically challenging and frequently requires a special approach by the neurosurgeon for adequate exposure of the operatory field. The technique is used for lesion excision, corpectomy, vertebral body reconstruction with cages, realignment, and/or plating or screwing. For a successful anterior approach and a suitable instrumental design via screw, adequate morphometric knowledge about the body of lumbar vertebrae and the discs and standardized volumetric data are required by neurosurgeons. Thus, morphometric and volumetric evaluation of lumbar bodies and discs are needed for a safer anterior approach during surgery (Gocmen et al., 2010).

The last decades have seen an increasing use of transpedicular screwing techniques as a mean of spinal fixation (Stefee et al., 1986; Lorenz et al., 1993). A screw enables various devices (plates, rods or wires) to be applied to the spine for immobilization or fixation. The success of the technique depends upon the ability of the screw to obtain and maintain purchase within the vertebral body (Zindrick et al., 1986). This is determined, among other factors, by the accurate choice of the screw, the size of the pedicle and the quality of the pedicle bone. The choice of the screw for the procedure is in turn determined by the minimum horizontal diameter of the pedicle (Krag et al., 1986; Zindrick et al., 1987; Weinstein et al., 1992). Morphometric data on diameters of the pedicles are, therefore, useful in preoperative planning and in designing of pedicle screws.

The pioneering work of Elsberg and Dyke (1934), Landmesser and Heublein (1953), Verbiest (1954, 1955), Simril and Thurston (1955), Schwarz (1956) and Hinck et al. (1966) have established the clinical value of measuring interpedicular distance in the diagnosis of narrowing of the spinal canal. Since then, the size of the spinal canal has attracted increasing interest. Various techniques including plain radiographs, myelography, epidural venography, computed tomography and diagnostic ultrasound have been used to measure the size of lumbar spinal canal (Amonoo-Kuofi, 1982). Although each technique has its own limitation, Chynn et al. (1978) observed that plain radiographs are of great value in the diagnosis of lumbar spinal canal stenosis.

The present study was undertaken to examine morphometric characteristics of lumbar vertebrae, lumbar intervertebral discs and some important related angles in Lebanese adult females.

Subjects and methods

The subjects of this study were thirty Lebanese adult females, who were selected among students of the Faculty of Health Sciences, Beirut Arab University. The age range was 18-22 year, mean \pm standard deviation (SD) 19.67 ± 1.19 year; the weight range was 50-73 kg, mean 61.01 ± 6.2 kg; the height range was 158-180 cm, mean 163.1 ± 4.9 cm; the body mass index range was 18.7-27.6, mean 22.21 ± 2.5 (table 1).

Table 1 – Age, weight, height and body mass index of the studied subjects.

	Min.	Max.	Mean \pm SD
Age (years)	18	22	19.67 \pm 1.19
Weight (kg)	50	73	61.01 \pm 6.20
Height (cm)	158	180	163.10 \pm 4.90
BMI	18.7	27.6	22.21 \pm 2.50

The inclusion criteria were:

- 1 Age 18-22 years.
- 2 No prior spine surgery.
- 3 No history of low back pain.
- 4 No pregnancy, past or present.

The exclusion criteria were:

- 1 Definite diagnosis of lumbar spinal pathology.
- 2 Definite clinical spinal deformities from physical examination or x-ray
- 3 Definite diagnosis of diabetes, hypertension, rickets or osteoporosis

Two plain radiographic views for the lumbosacral spine were taken for each subject:

- a) An antero-posterior view.
- b) A lateral view, taken in lateral recumbent position with hips and knees flexed at 45°. This position was considered preferable in studies of the lumbar lordosis because the angle to which the knees and hips were flexed gave a balanced relaxation of the thigh and knee, thus producing a more or less normal lumbar curve (Amonoo-Kuofi, 1991).

All radiographs were taken where the X-ray beam was centred on L₃ with an anode film distance of 100 cm. The magnification resulting from the use of this technique was negligible (Amonoo-Kuofi, 1995). Measurements were made directly on the X-ray films using Vernier callipers and were recorded to the nearest tenth of a millimetre

The following measurements were taken or - where appropriate - computed:

A. Lumbar vertebrae:

1. The anterior height of the body of each lumbar vertebra on lateral view (figure 1).
2. The posterior height of the body of each lumbar vertebra on lateral view (figure 1).
3. The horizontal diameter of the pedicle of each lumbar vertebra on antero-posterior view (figure 2).
4. The vertical diameter of the pedicle of each lumbar vertebra on antero-posterior view (figure 2).
5. The inter-pedicular distance measured as the shortest distance between the medial borders of pedicles for each lumbar vertebra on anteroposterior view (figure 2).

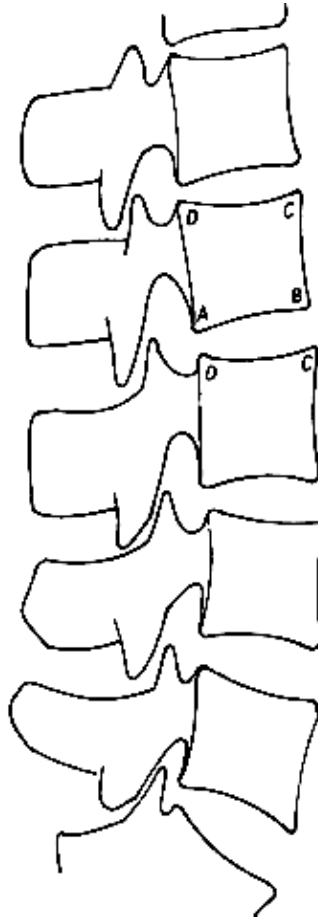


Figure 1 – Diagram of markers for measuring the intervertebral discs and bodies of lumbar vertebrae. Vertebra: CB: anterior height; DA: posterior height; Disc: BC: anterior height; AD: posterior height. Disc depth = $AB+CD/2$. After Amonoo-Kuofi (1991).

6. The width (transverse diameter) of the body of each lumbar vertebra. This was measured at the level of the narrowest part of the vertebra on antero-posterior view (figure 2).
7. The ratio of the inter-pedicular distance to the transverse diameter of the corresponding lumbar vertebra.

B. Intervertebral discs:

1. The anterior height of the intervertebral discs between the first lumbar to the first sacral vertebra on lateral view (figure 1).
2. The posterior height of the intervertebral discs between the first lumbar to first sacral vertebra on lateral view (figure 1).
3. The antero-posterior diameter of the disc (disc depth) on lateral view (figure 1).

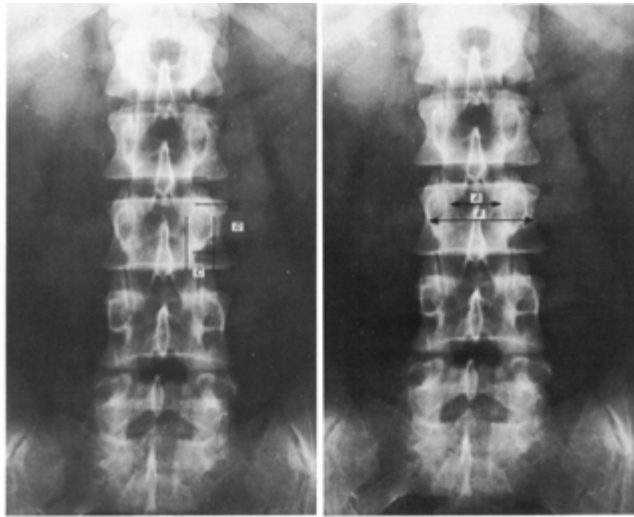


Figure 2 – Plain x-ray of lumbar spine antero-posterior view. Left panel: horizontal (C) and vertical (D) diameters of the pedicle. Right panel: interpedicular distance (A) and transverse diameter of the vertebral body (B). After Amonoo-Kuofi (1982).

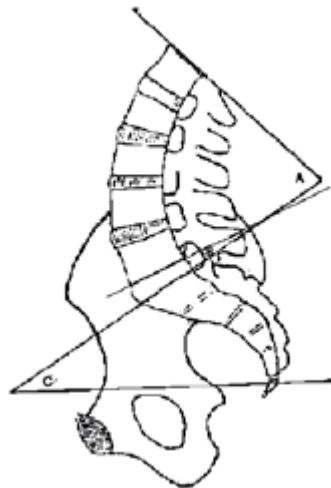


Figure 3 – Diagram of lateral view of the lumbar spine. A: angle of lumbar lordosis; B: lumbosacral angle; C: angle of sacral inclination. After Amonoo-Kuofi (1992).

C. Angles: The following angles were measured as shown in figure 3 according to Amonoo-Kuofi (1992):

1. Lumbar lordosis: the angle between the plane of the upper surface of the first Lumbar vertebra and the upper surface of the sacrum.

2. Lumbosacral angle: the angle between the plane of the inferior surface of the fifth lumbar vertebra and the plane of the upper surface of the sacrum.
3. Sacral inclination: the angle between the plane of the upper surface of the sacrum and the horizontal plane.

The mean and SD of the above mentioned parameters were calculated and recorded.

Results

The mean anterior height of the bodies of the lumbar vertebrae increased from L₁ to L₅ (table 2) while the mean posterior height increased from L₁ to L₂ and decreased from L₂ to L₅ (table 3).

The mean anterior height of the intervertebral discs showed gradual increase (table 4) while the mean posterior height showed no specific trend, except that the narrowest posterior height was at L₅/S₁ disc, while the widest posterior height was at L₄/L₅ disc (table 5).

The disc depth was approximately constant from L₁/L₂ disc to L₅/S₁ disc (table 6).

The mean horizontal diameter of the pedicles showed gradual increase in cranio-caudal direction (table 7), while their mean vertical diameter of pedicle was more or

Table 2 – Anterior height of the bodies of lumbar vertebrae (mm).

Vertebra	Anterior height		
	Min.	Max.	Mean ± SD
L1	29.0	36.3	31.8 ± 1.8
L2	29.0	36.0	32.7 ± 2.1
L3	29.5	38.6	34.1 ± 2.2
L4	29.9	39.0	34.2 ± 2.2
L5	29.8	37.2	34.5 ± 1.8

Table 3 – Posterior height of the bodies of lumbar vertebrae (mm).

Vertebra	Posterior height		
	Min.	Max.	Mean ± SD
L1	29.0	36.0	32.3 ± 1.9
L2	29.0	37.6	33.2 ± 2.1
L3	29.0	39.1	32.9 ± 2.2
L4	27.7	35.0	32.2 ± 1.8
L5	25.0	35.7	30.7 ± 3.0

Table 4 – Anterior height of lumbar intervertebral discs (mm).

Intervertebral disc	Anterior height		
	Min.	Max.	Mean ± SD
L1/L2	5.6	13.9	10.0 ± 2.2
L2/L3	5.6	17.4	12.4 ± 2.5
L3/L4	10.6	19.2	14.6 ± 2.2
L4/L5	11.7	21.1	16.5 ± 2.1
L5/S1	11.8	21.6	16.8 ± 2.6

Table 5 – Posterior height of lumbar intervertebral discs (mm).

Intervertebral disc	Posterior height		
	Min.	Max.	Mean ± SD
L1/L2	4.3	9.4	6.2 ± 1.4
L2/L3	3.5	8.7	6.0 ± 1.2
L3/L4	4.9	7.0	6.0 ± 0.5
L4/L5	4.9	10.0	6.6 ± 1.2
L5/S1	2.9	7.5	5.3 ± 1.4

Table 6 – Antero-posterior diameter of lumbar intervertebral discs (disc depth; mm).

Intervertebral disc	Anteroposterior diameter		
	Min.	Max.	Mean \pm SD
L1/L2	34.4	40.5	37.1 \pm 1.8
L2/L3	35.3	41.6	38.2 \pm 1.8
L3/L4	34.4	41.8	38.3 \pm 2.2
L4/L5	36.3	41.4	38.6 \pm 1.6
L5/S1	34.6	41.2	37.2 \pm 1.7

Table 7 – Horizontal diameter of the pedicles of the lumbar vertebrae (mm).

Vertebra	Horizontal diameter		
	Min.	Max.	Mean \pm SD
L1	5.2	11.0	6.4 \pm 1.3
L2	5.2	10.0	7.0 \pm 1.1
L3	5.8	12.2	8.5 \pm 1.4
L4	7.6	15.0	10.5 \pm 1.9
L5	10.0	17.5	13.1 \pm 2.2

Table 8 – Vertical diameter of the pedicles of lumbar vertebrae (mm).

Vertebra	Vertical diameter		
	Min.	Max.	Mean \pm SD
L1	11.0	18.0	15.0 \pm 1.4
L2	11.9	18.0	15.3 \pm 1.4
L3	11.5	20.6	15.7 \pm 2.1
L4	12.0	18.5	15.1 \pm 1.6
L5	11.4	20.3	15.8 \pm 2.6

Table 9 – Interpedicular distance for each lumbar vertebra (mm).

Vertebra	Interpedicular distance		
	Min.	Max.	Mean \pm SD
L1	19.0	27.5	23.5 \pm 2.3
L2	21.0	29.0	25.1 \pm 1.9
L3	23.1	30.0	26.1 \pm 1.9
L4	23.0	30.9	27.4 \pm 1.9
L5	28.0	37.1	32.4 \pm 2.5

Table 10 – Transverse diameter of the body of each lumbar vertebra (mm).

Vertebra	Transverse diameter		
	Min.	Max.	Mean \pm SD
L1	33.6	45.0	38.9 \pm 3.0
L2	35.3	47.2	41.0 \pm 3.1
L3	38.1	49.9	44.0 \pm 3.3
L4	41.8	54.9	48.0 \pm 2.9
L5	50.0	66.9	57.1 \pm 4.2

less constant from L₁ to L₅ (table 8). At all levels the vertical diameter was greater than the horizontal diameter. Also, moving downward the vertical diameter became more oblique at each successive level, which was accompanied by increasing inclination of the horizontal diameter as well.

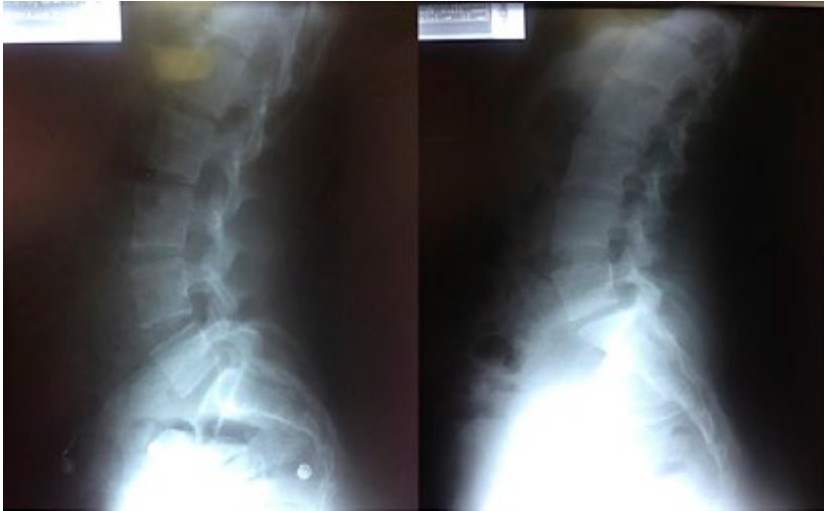The present study revealed that the mean interpedicular distance increased gradually from L₁ to L₅ (table 9). Also the mean transverse diameter of bodies of the lumbar vertebrae showed gradual increase from L₁ to L₅ (table 10), keeping the ratio of the

Table 11 – Ratio of the interpedicular distance to the transverse diameter for each lumbar vertebra.

Vertebra	Interpedicular distance	Transverse diameter	Ratio
L1	23.5	38.9	0.60
L2	25.1	41.0	0.61
L3	26.1	44.0	0.59
L4	27.4	48.0	0.57
L5	32.4	57.1	0.57

Table 12 – Angle of lumbar lordosis, lumbosacral angle and angle of sacral inclination (degrees).

Angle	Min.	Max.	Mean \pm SD
Lumber lordosis	55°	99°	71.8° \pm 12.8°
Lumbosacral angle	7°	33°	15.9° \pm 5.7°
Sacral inclination	24°	65°	45.4° \pm 10.7°

**Figure 4** – Lateral view of the lumbar spine showing that the vertical diameter of the pedicles becomes more oblique at each successive inferior level.

interpedicular distance to the transverse diameter of the body more or less constant around the value 0.6 (table 11).

The values of lumbar lordosis, lumbosacral and sacral inclination angles (range, mean, SD) are given in table 12 (figure 4).

Discussion

Low back pain is one of the most frequently observed symptom in the human musculoskeletal system. The frequency of low back pain increases with age and its frequency in adult population is reported to vary between 60 and 90 % (Altinel et al., 2008). The vertebral column presents regional curves on sagittal plane, designed to absorb impact, reduce longitudinal stiffness and intensify muscle function; it has been noted that some cases of low back pain and sciatica are attributable to abnormal alteration of the curve (Kim et al., 2006). There is a strong interdependence between the pelvis and the lumbar spine in order to maintain a balanced posture (Chaleat-Valayer et al., 2011). Chanplakorn et al. (2011) reported that as the lumbar lordosis decreases, the sacrum tends to become vertical and, on the contrary, it tends to become horizontal as the lumbar lordosis increases. This behaviour may be explained by the adaptation of the lumbar spine to facilitate balance for the pelvis.

The results of the present study should be compared with those of previous ones for the different parameters analysed. Regarding the size of lumbar vertebrae, Gocmen et al. (2010) on Anatolians recorded smaller values than the present ones for the anterior height of the bodies and the anterior height of intervertebral discs. However, their results showed a gradual cephalocaudal increase as found in the present study. Ablyazov (2012) on Uzbekistani recorded results which are nearly equal to those of the present study for the anterior and posterior height of vertebral bodies, while he recorded smaller values than the present ones for the anterior and posterior height of the intervertebral discs. These parameters can be of help to evaluate lumbar vertebral anatomy in healthy subjects as well as give guidance to surgeons during anterior approach. Moreover, knowledge of the normal lumbar intervertebral space can be helpful in predicting the appropriate size of the devices to be inserted in that space thus decreasing the risk of postoperative complications (Hong et al., 2010) when the restoration of the appropriate intervertebral disc space is recommended.

Is the intervertebral disc height related to the interspinous height? Previous investigators reported that application of lumbar interspinous spacers, although not a new concept (Whitesides, 2003), is a valuable alternative treatment for degenerative conditions such as stenosis of the spinal canal and foramina (Zucherman et al., 2005; Kondrashov et al., 2006; Siddiqui et al., 2007). Although Albietz et al. (2012) reported no correlation between the interspinous height and the anterior or posterior disc height, they stated that knowledge of anterior and posterior disc height might assist in the preoperative planning of implantation of an interspinous device as these dimensions can be more easily retrieved from a standard lateral projection radiograph than the dimension of the interspinous space.

Regarding the anteroposterior diameter of the disc (disc depth), the present results gave results coherent with those reported by Amonoo-Kuofi (1991) for Saudi Arabia.

Accurate knowledge of pedicle morphology and measurement of pedicle dimensions is crucial for treatment with pedicle screw instrumentation (Sugisaki K et al., 2009). Comparative studies reported by Zindrick et al. (1986, 1987), Weinstein et al. (1992) and Errico and Palmer (1993) established that measurements obtained directly from plain films correlated well with values measured from computerized tomograms and from anatomical specimens. The present results on this issue should be compared with those of previous studies. Olsewki et al. (1990) on cadaveric American

specimen, Amonoo-Kuofi (1995) in Saudi Arabi and Sugisaki et al. (2009) on American people reported gradual cephalocaudal (from L1 to L5) increase in the horizontal as well as in the vertical diameter. On the other hand, Zindrick et al. (1987) on Indian people, Kadioglu et al. (2003) on Anatolian people and Lien et al. (2007) on Taiwanese people reported a gradual cephalocaudal increase in the horizontal diameter, while the vertical diameter showed a gradual decrease. Thus, there is a general agreement regarding the cephalocaudal pattern of change of the horizontal diameter of the pedicle, while diverging results (increase, decrease or constant) have been recorded regarding for the vertical diameter. These latter variations may be attributed to racial, ethnic or regional variations.

The present findings are in agreement with those of Rebertson et al. (2000), Seranan et al. (2002) and Sugisaki et al. (2009), who reported that the pedicle cross-sectional morphology may be assumed as elliptical and becomes more oblique in respect to the vertical plane at each successive inferior level. Also, Sugisaki et al. (2009) reported that the vertical diameter was greater than the horizontal diameter at all levels, with which the results of the present study also are in agreement.

Amonoo-Kuofi (1982) reported that pedicles produce visible landmarks on plain anteroposterior radiographs and therefore the interpedicular distances can be measured accurately. The lumbar part of the neural canal houses the cauda equina, and narrowing of the bony ring of the canal, which may be developmental or acquired, may lead to compression of the nerve roots and cause low back pain (Verbiest 1954, 1955). Measurement of the width of the lumbar spinal canal is, therefore, a useful aid in the diagnosis of lumbar spinal stenosis syndrome.

The present study revealed that the interpedicular distance increased gradually from L₁ to L₅. At the same time, the transverse diameter of bodies of the lumbar vertebrae showed also a gradual increase from L1 to L5 keeping the ratio of the interpedicular distance to the transverse diameter of the body more or less constant about 0.6.

The present results for interpedicular distance, transverse diameter of vertebral body and the ratio between these those parameters are consistent with those of Hink et al. (1966) on White Americans and of Amonoo-Kuofi (1982) on Nigerians: both authors reported a steady increase in interpedicular distance from L₁ to L₅ in all age groups. In addition, Amonoo-Kuofi (1982) reported that the width of the canal increases proportionately with the size of the vertebrae, always maintaining a canal to body ratio of 0.6, which is the same result as the present study. Recently, Gocmen et al. (2010) reported larger transverse diameter of the bodies of lumbar vertebrae from L1 to L4 except L5, with which the results of the present study are in agreement. Ablyazov (2012) in Uzbekistani reported results regarding the interpedicular distance which are nearly the same as those obtained in the present study.

Abnormal spinal alignment in the sagittal plane may cause persistent low back pain. It is estimated that 80% of the world population will be afflicted with low back pain at least once in life time (Kelsey and White, 1980). Disc herniation and degeneration were found to increase with age (Amonoo-Kuofi, 1992; Dammers and Koehler, 2002) and have been reported to be significant factors in the genesis of low back pain, hence the importance examining young individuals. Paajanen et al. (1989) found the frequency of disc degeneration in individuals 20 years of age with low back pain to be 57%. Salminen et al. (1999) reported the presence of degenerative disc in at least

one level in individuals 15 and 18 years of age to be 31% and 42% respectively. Cheung et al. (2009), in Southern Chinese Society, detected the frequency of degenerative disc in individuals aged 18-29 years to be 42%. Several studies have shown the importance of sagittal spino-pelvic alignment in maintaining a balanced posture in normal population. However, the influence of sagittal spino-pelvic alignment on low back pain is still poorly understood. Previous investigators reported conflicting results suggesting either decreased (Ranjics et al., 2002; Barrey et al., 2007), increased (Ergun et al., 2010) or normal (George et al., 2003) lumbar lordosis in patients with low back pain. Thus, it is still unclear whether specific patterns of sagittal spino-pelvic alignment are more prevalent in patients with low back pain.

The values of lumbar lordosis, lumbosacral and sacral inclination angles found in present study are different from those reported for Egyptians of nearly corresponding age and sex (Soliman and El-Nemr, 1996), in whom the three angles were smaller than in Lebanese women. Endo et al. (2010) reported that in Japanese people the lumbar lordosis angle was $49^{\circ} \pm 10^{\circ}$ in normal control group while lumbar lordosis angle was much smaller in cases of lumbar disc herniation than in controls and that six month after surgery there was almost complete recovery. Rajnics et al. (2002) and Barrey et al. (2007) detected a decrease in lumbar lordosis and sacral slope in patients with disc degeneration and disc herniation when compared to normal individuals. This finding was confirmed by Endo et al. (2010) who reported that the degree of intervertebral disc degeneration increased in parallel with the decrease in sacral kyphosis and lumbar lordosis angles and with the increase in sacral inclination angle. On the other hand, Ergun et al. (2010) reported that a more vertical orientation of the lumbosacral spine favours the development of disc degeneration and disc herniation, as documented in young adult woman by magnetic resonance imaging.

In the light of the aforementioned previous studies it seems reasonable to hypothesize that individuals with abnormal sagittal spino-pelvic alignment have a greater risk of developing disc herniation than those with normal lumbosacral slope. As Ergun et al. (2010) reported that individuals with a straighter vertebral column have a greater risk of low back pain complaints and more severe symptoms throughout their lives than those with normal sacral slope and since adult Lebanese females present more vertical orientation of the lumbosacral structures than the subjects mentioned in the previous studies; it may be speculated that Lebanese women have a tendency to develop disc degeneration or herniation

In conclusion the measurements obtained in this study form a base line for normal Lebanese adult females and may give guidance to clinicians for the evaluation and treatment of low back pain; these age related normative values may not only help in identifying the underlying cause, but also in directing physicians towards a proper line of treatment or perhaps even towards preventive or rehabilitation protocols. Moreover, these normal figures are of possible forensic importance because of the observed racial, ethnic and regional variations.

References

- Ablyazov O. (2012) X-ray parameters of lumbar spine. *Med. Health Sci. J.* 10: 37-40.
Albietz J.S., Arellano P.R., Fleming J.C., Gurr K.R., Bailey S.I., Baily C.S. (2012) An

- anatomic study of the interspinous space of the lumbosacral spine. *Eur. Spine J.* 21:145-148.
- Altinel L., Kose K.S., Ergan V., Isik C., Aksoy Y., Ozdemir S. (2008) The prevalence of low back pain and risk factors among adult population in Afyon region Turkey. *Acta Orthop. Traumatol. Turc.* 42: 328-333.
- Amonoo-Kuofi H.S. (1982) Maximum and minimum lumbar interpedicular distances in normal adult Nigerians. *J. Anat.* 135: 225-233.
- Amonoo-Kuofi H.S. (1991) Morphometric changes in the heights and anteroposterior diameters of the lumbar intervertebral discs with age. *J. Anat.* 175: 159-168.
- Amonoo-Kuofi H.S. (1992) Changes in the lumbosacral angle, sacral inclination and the curvature of the lumbar spine during aging. *Acta Anat.* 145: 373-377.
- Amonoo-Kuofi H.S. (1995) Age related variations in the horizontal and vertical diameters of the pedicles of the lumbar spine. *J. Anat.* 186: 321-328.
- Barrey C., Junde J., Noseda O.B, Roussouly P. (2007) Sagittal balance of the pelvis-spine complex and lumbar degenerative diseases: a comparative study about 85 cases. *Eur. Spine J.* 16: 1549-1567.
- Chaleat-Valayer E., Mac-Thiong J.M., Paquet J., Berthonnaud E., Siani F, Roussouly P. (2011) Sagittal spino-pelvic alignment in chronic low back pain. *Eur. Spine J.* 20 (Suppl 5): S634-S640.
- Chanplakorn P., Wongsak S., Woratanarat P., Wajanavisit W., Laohacharoensombat W. (2011) Lumbopelvic alignment on standing lateral radiograph of adult volunteers and the classification in the sagittal alignment of lumbar spine. *Eur. Spine J.* 20: 706-612.
- Cheung K.M., Karppinen J., Chan D., Ho W.D., Sang Y.O., Sham P., Cheah K.S., Leong jc, Luk K.D. (2009) Prevalence and pattern of lumbar magnetic resonance image changes in a population study of one thousand forty-three individuals. *Spine* 34: 934-940.
- Chynn K. Y., Altman I., Shaw W. I., Finby N. (1978) The roentgenographic manifestations and clinical features of lumbar spinal stenosis with special emphasis on the superior articular process. *Neuroradiology* 16: 378-380.
- Dammers R., Koehler P.J. (2002) Lumbar disc herniation: level increases with age. *Surg. Neurol.* 58: 209- 212.
- Elsberg C.A., Dyke C.G. (1934) Diagnosis and localisation of tumours of spinal cord by means of measurements made on X-ray films of vertebrae, and correlation of clinical and X-ray findings. *Bull. Neurol. Inst. New York* 3: 359-394.
- Ergun T., Lakadamyali H., Sahin M.S. (2010) The relation between sagittal morphology of the lumbosacral spine and the degree of lumbar intervertebral disc degeneration. *Acta Orthop. Traumatol. Turc.* 44: 293-299.
- Errico T.J., Palmer K. (1993) Imaging of the spine. *Curr. Opin. Orthop.* 4: 39-48.
- Fernand R., Fox D. E. (1985) Evaluation of lumbar lordosis: A prospective and retrospective study. *Spine* 10: 799-803.
- George S.Z., Hicks G.E., Nevitt M.A., Cauley J.A., Vogt M.T. (2003) The relationship between lumbar lordosis and radiologic variables and lumbar lordosis and clinical variables in elderly, African-American women. *J. Spinal Disord. Tech.* 16 : 200-206.
- Gocmen-Mas N., Karabekir H., Ertekin T., Edizer M., Canan Y., Izzet Duyar I. (2010) Evaluation of lumbar vertebral body and disc: a stereological morphometric study. *Int. J. Morphol.* 28: 841-847.

- Hellems H.K., Keats T.E. (1971) Measurements of the normal lumbosacral angle. *Am. J. Roentgenol. Radium Ther. Nucl. Med.* 113: 642-645.
- Hinck V.C., Clark W.M., Hopkins C.E. (1966) Normal interpediculate distances (minimum and maximum) in children and adults. *Am. J. Roentgenol. Radium Ther. Nucl. Med.* 97: 141-153.
- Hong C.H., Park J.S., Jung K.J., Kim W.J. (2010) Measurement of the normal lumbar intervertebral disc space using magnetic resonance imaging. *Asian Spine J.* 4: 1-6.
- Kadioglu H.H., Takci E., Levent A. (2003) Measurements of the lumbar pedicles in the Eastern Anatolian population. *Surg. Radiol. Anat.* 25:120-126.
- Kelsey J.L., White A.A. (1980) Epidemiology and impact of low back pain. *Spine* 5: 133-142.
- Endo K., Suzuki H., Tanaka H., Kang Y., Yamamoto K. (2010): Sagittal spinal alignment in patients with lumbar disc herniation. *Eur. Spine J.* 19: 435-443.
- Kim H.J., Chung S., Kim S. (2006) Influences of trunk muscles on lumbar lordosis and sacral angles. *Eur. Spine J.* 15: 409-414.
- Kondrashov D.J., Hannibal M., Hsu K.Y. (2006) Interspinous process decompression with the X-Stop device for lumbar spinal stenosis: a 4 year follow up study. *J. Spinal Disord. Tech.* 19: 323-327.
- Krag M.H., Beynon M.S., Pope M.H., Frymoyer J.W., Haugh L.D., Weaver D.L. (1986) An internal fixator for posterior application to short segments of the thoracic, lumbar or lumbosacral spine: design and testing. *Clin. Orthop. Rel. Res.* 203: 75-98.
- Landmesser W.E, Heublein G.W. (1953) Measurement of normal interpedicular space of children. *Connecticut Med. J.* 17: 310-313.
- Lien S.B., Liou N.H., Wu S.S. (2007) Analysis of anatomic morphometry of the pedicles and the safe zone for through-pedicle procedures in the thoracic and lumbar spine. *Eur. Spine J.* 16: 1215-1222.
- Lorenz M.A., Hodges S., Vrbos L.A. (1993) Spinal fixation. *Cur. Opin. Orthop.* 4: 192-204.
- Olsewski J.M., Simmons E.H., Kallen F.C. (1990) Morphometry of the lumbar spine: anatomical perspectives related to transpedicular fixation. *J. Bone Joint Surg.* 72: 541-549.
- Paajanen H., Erkintalo M., Kuusela T., Dahlstrom S., Kormanio M. (1989) Magnetic resonance study of disc degeneration in young low back pain patients. *Spine* 14: 982-985.
- Pelker R.P., Gage J.R. (1982) The correlation of idiopathic lumbar scoliosis and lumber lordosis. *Clin. Orthop. Rel. Res.* 163: 199-201.
- Rajncics P., Templier A., Skolli W., lavaste F., Illes T. (2002) The importance of spinopelvic parameters in patients with lumbar disc lesions. *Int. Orthop.* 26: 104-108.
- Robertson P.A., Stewart N.R. (2000) The radiologic anatomy of the lumbar and lumbosacral pedicles. *Spine* 25:709- 715.
- Salminen J.J., Erkintolo M.O., Pentti J., Oksanen A., Kormanio M.J. (1999) Recurrent low back pain and early disc degeneration in young. *Spine* 24: 1316-1321.
- Schwarz G.S. (1956) Width of spinal canal in growing vertebra with special reference to sacrum: maximum interpediculate distances in adults and children. *Am. J. Roentgenol. Radium Ther. Nucl. Med.* 76: 476-481.
- Senaran H., Yazici M., Karcaaltincaba M. (2002) Lumbar pedicle morphology in the immature spine: a three-dimensional study using spiral computed tomography. *Spine* 27: 2472-2476.

- Siddiqui M., Simth F.W., Wardlaw D. (2007) One year results of X-Stop interspinous implant for the treatment of lumbar spinal stenosis. *Spine* 32: 1345-1348.
- Simril W.A., Thurston D. (1955) Normal interpediculate space in spines of infants and children. *Radiology* 54: 340-347.
- Skaf G.S., Ayoub C.M., Domloj N.T., Turbay M.J., El-Zein C., Hourani M.H. (2011) Effect of age and lordotic angle on the level of lumbar disc herniation. *Adv. Orthop.* 2011: 950576.
- Soliman E.A., El-Nemr N.M. (1996) Changes in the lumbosacral angle, sacral inclination and the curvature of the lumbar spine with aging. *Egypt. J. Anat.* 19: 35-47.
- Steffee A.D., Biscup R.S., Sitkowsky D.T. (1986) Segmental spine plates and screws with pedicle screw fixation. *Clin. Orthop. Rel. Res.* 203:45-53.
- Sugisaki K., Howard S., Espinozaorias A.A., Rim R., Andersson G.B.J, Inoue N. (2009) In- vivo three dimensional morphometric analysis of the lumbar pedicle isthmus. *Spine* 34: 2599-2604.
- Verbiest H. A. (1954) Radicular syndrome from developmental narrowing of the lumbar vertebral canal. *J. Bone Joint Surg.* 36: 230-237.
- Verbiest H. (1955) Further experiences on the pathological influence of a developmental narrowness of the bony lumbar vertebral canal. *J. Bone Joint Surg.* 37: 576-583.
- Weinstien J.N., Rydevik B.L., Rauschnig W. (1992) Anatomic and technical consideration of pedicle screw fixation. *Clin. Orthop. Rel. Res.* 284: 34-46.
- Whitesides T.E.J. (2003) The effect of interspinous implant on intervertebral disc pressure. *Spine* 28: 1906-1907.
- Zindrick M.R., Wiltse L.L., Widell E.H., Thomas J.C., Holland W.R., Field B.T. (1986) A biomechanical study of intrapedicular screw fixation in the lumbosacral spine. *Clin. Orthop. Rel. Res.* 203: 99-112.
- Zindrick M.R., Wiltse L.L., Doornick A., Widell E.H., Knight G.W., Patwardhan A.G. (1987) Analysis of the morphometric characteristics of the thoracic and lumbar pedicles. *Spine* 12: 160-166.
- Zucherman J.F., Hsu K.Y., Hartjen C.A. (2005) A multicenter, prospective, randomized trial evaluating the X-Stop interspinous process decompression system for the treatment of neurogenic intermittent claudication: 2 year follow-up results. *Spine* 30: 1351-1358.