

Research Article - Human Anatomy Case Report

## A case of total bilateral congenital ulnar artery absence detected with CT angiography

Emanuele Cabras<sup>1</sup>, Stefano Congia<sup>2,\*</sup>, Alessandro Palmas<sup>2</sup>, Giuseppe Dessi<sup>1</sup>, Antonio Capone<sup>2</sup><sup>1</sup> Orthopaedic and Traumatology Division, Brotzu Hospital, Cagliari, Italy<sup>2</sup> Department of Orthopaedics, University of Cagliari, Cagliari, Italy

### Abstract

Here we report a case of bilateral ulnar artery absence discovered during the treatment of a deep wound in the forearm. Variations and anomalies in the anatomy of the upper limb arteries are frequent, but the one that we found, to our knowledge, has never been described in other clinical cases.

### Key words

Ulnar artery absence, hand injury, congenital anomalies.

### Introduction

Anatomic anomalies and variations of arterial vessels of the upper limb are relatively frequent.

Mc Cormack et al. (1953) studied 750 upper limbs from 386 cadavers and found 139 deviations from normal anatomy: 107 anomalous radial arteries, 23 ulnar and 9 brachial; he also found that unilateral abnormalities are more frequent than bilateral ones (24.5% vs 6.3%).

Since the 19<sup>th</sup> century, when stages of embryological patterns of upper extremity arterial system were discovered, scientists have been trying to carry out a systematic description of abnormalities.

As a result of the growing types of anomalies discovered and the use of different terminologies, classifying the phenomena has become increasingly challenging (Rodriguez-Niedefuhr et al., 2003). Although between 9% and 18.5% of upper limbs in cadaveric studies presented with some kind of arterial abnormality (Ciervo et al., 2001), only few case reports in literature described, to our knowledge, upper limb arterial anomalies from a clinical and surgical point of view. Collecting a significant number of patients is difficult even in high-specialized centres.

Previous case reports mainly showed arterial abnormalities discovered during the preoperative planning of reconstructive surgery with radial flap carried out with observation, Allen test and imaging as Doppler ultrasonography or arteriography (Bhatt and Hall, 2010; Ro et al., 2016).

Some other cases showed complications after a brachiocephalic arterio-venous fistula (Ciervo et al., 2001). Accidental findings after traumatic injuries or wounds are less common (Muratore and Ozer, 2011; Zhao et al., 2016).

\* Corresponding author. E-mail: [stefano.congia@tiscali.it](mailto:stefano.congia@tiscali.it)

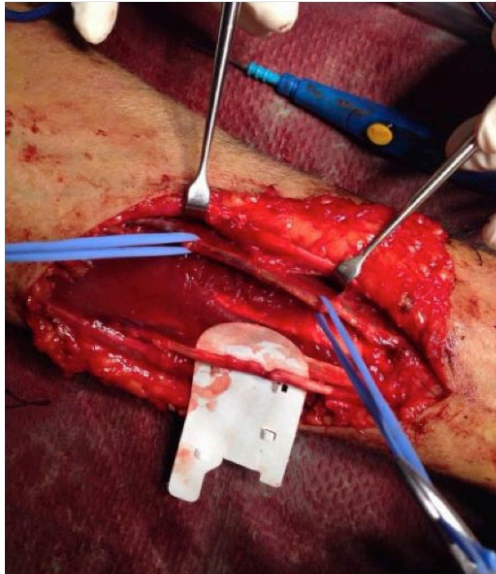
## Case report

A 64 years old man was admitted to our hospital due to a deep wound in the volo-ulnar aspect of the forearm in the middle-proximal third due to a chainsaw accident. The only relevant medical history was a prostate cancer operated 3 years before the admission. All procedures were performed in accordance with the ethical standards the 1964 Helsinki declaration and its later amendments.

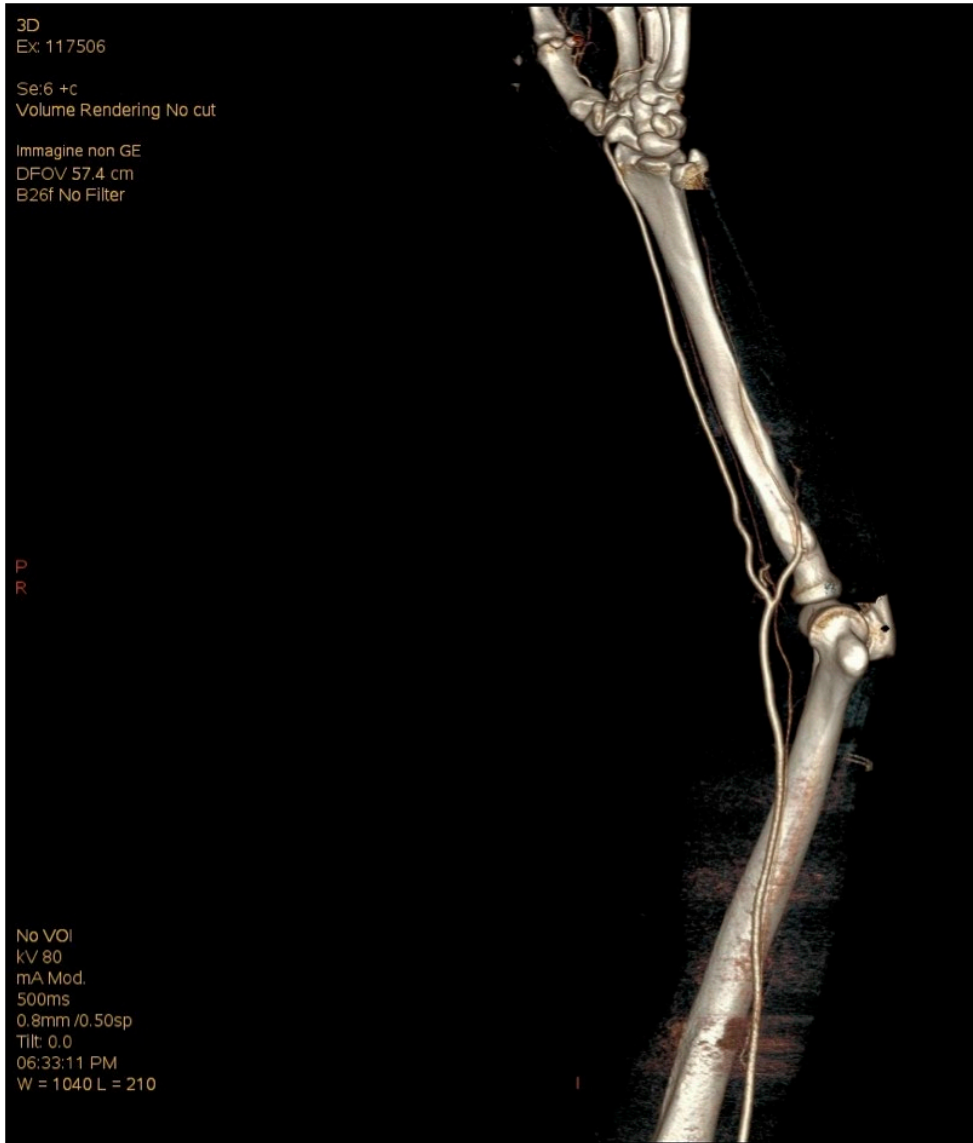
Local physical examination showed a deep wound (4 cm) on the volo-ulnar aspect of the middle-proximal forearm, sensory and motor ulnar nerve palsy, positive Allen Test and no signs of hypoperfusion or ischemia. We decided to treat immediately in order to explore the wound and repair soft tissue injuries.

No fractures of the forearm, elbow and wrist were shoed by the X-Ray. Intravenous Cefazolin (2 g) was administred prophylactically before surgery. The patient underwent surgery under tourniquet and general anaesthesia. After having prepared a sterile field we cleaned the wound and widened the incision proximally and distally to detect soft tissue lesions. We found a complete lesion of the flexor carpi ulnaris tendon and palmaris longus, a partial lesion of the flexor digitorum superficialis on the ulnar side, and also a partial lesion of ulnar nerve. Although we extended the wound we did not identify the ulnar artery (Figure 1). Positive Allen test and intraoperative findings were in keeping with a complete absence of ulnar artery. After concluding the exploration we sutured the partial ulnar nerve lesion and all the tendon lesions.

Postoperative progress has been regular and the patient was discharged two days after surgery. The skin wound healed within 2 weeks; motor ulnar palsy, hypoaesh-



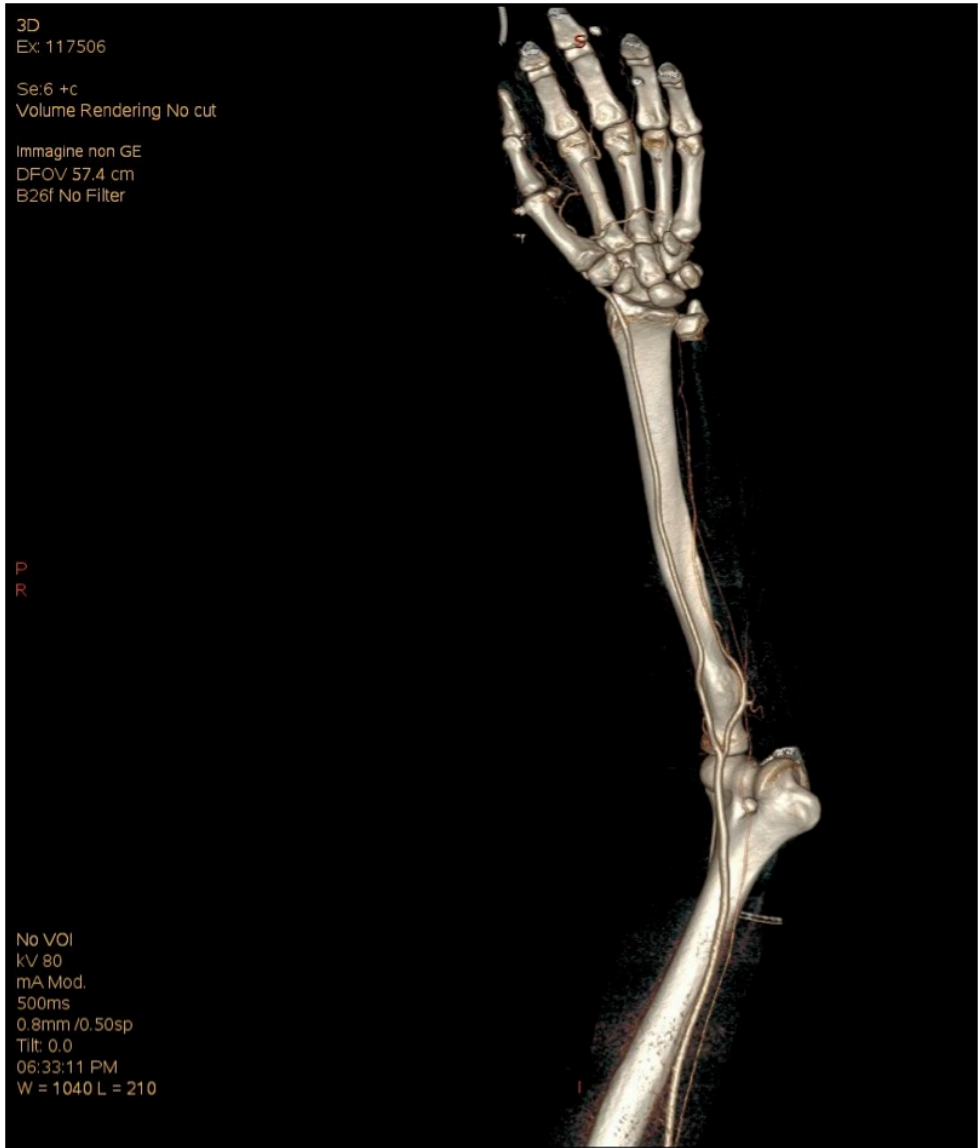
**Figure 1.** Intraoperative absence of ulnar artery, partial lesion of ulnar nerve.



**Figure 2.** Left arm CT angiography findings of ulnar artery absence.

thesia and dysaesthesia of ulnar innervation areas were completely recovered two months after surgery.

After the recovery the patient was scheduled for a CT of the chest as a follow up of the prostate cancer, therefore, with his consent, we decided to arrange in combination a CT angiography. This exam showed bilateral agenesis of ulnar artery with a



**Figure 3.** Right arm CT angiography findings of ulnar artery absence.

proximal intact stump, normal brachial artery and larger diameter radial artery (Figures 2, 3).

We also noticed decreased flow in common interosseus artery and palmar arterial arches.

## Discussion

The ulnar artery arises from the brachial artery and terminates in the superficial palmar arch, which creates anastomosis with the radial artery. The most frequently described anastomosis of the palmar arch is the “ulnar type” where almost all flow is supplied by ulnar artery (Lee et al., 2015).

The presence of an incomplete arch combined with the absence of continuation among the arteries explains ischemic conditions and this complication is well known to happen after harvesting radial artery from forearm or after traumatic or iatrogenic injuries.

In order to prevent irreversible vascular damage to the hand it is mandatory to perform the Allen test on the radial artery before surgery. Allen test has shown a high sensibility and specificity (Jarvis et al., 2000); in our opinion it should be performed preoperatively both in elective and trauma surgery.

In case of doubt, after observation and Allen test, a preoperative and non-invasive imaging is an appropriate procedure. In literature we found studies that showed the presence of median artery (Muratore and Ozer, 2011; Zhao et al., 2016), absence of brachial artery (Ciervo et al., 2001), high and asymmetric bifurcated brachial artery (Panagouli et al., 2014). There are several cadaveric studies and case reports about superficial ulnar arteries (Bhatt and Hall, 2010; Panagouli et al., 2014); this anomaly is present in approximately 3% of population and it is important to detect it in order to recognise an arterial lesion caused by a superficial wound or the usage of an intravenous catheter.

In our knowledge three studies showed the absence of ulnar artery (Lee et al., 2015; Zhao et al., 2016), but none of them proved a bilateral agenesis of ulnar artery. A large sample study assessed that the incidence of ulnar artery absence may be considered < 0.015% (Rodriguez-Niedefuhr et al., 2003) although several cadaveric studies did not find that abnormality (Lee et al., 2015).

Zhao et al. (2016) described a congenital unilateral absence of ulnar artery discovered during a surgical exploration of the forearm for a trauma and confirmed by Doppler sonography and angiography; in association with this abnormalities the author described a median artery lesion close to the median nerve, which was then ligated.

The study of Ro et al. (2016) showed a congenital bilateral and asymmetric hypoplasia of the ulnar artery detected preoperative before harvesting a free flap that they investigated using arteriography. Lee et al. (2015) accidentally found during a preoperative assessment for a radial forearm flap a complete distal bilateral ulnar artery absence without any others anomalies (presence of median artery, ulnar superficial artery, brachioulnar artery).

We report an intraoperative case of total absence of the ulnar artery without other anomalies, which after imaging investigation was revealed to be bilateral. To our knowledge no case report before showed this specific abnormalities nor it was ever assessed by CT angiography.

The absence of ulnar artery bilaterally is a rare and interesting case; reporting rare anomalies may have a clinical role during exploration of forearm wounds or during preoperative evaluations. Keeping in mind that from 9% to 18% of people could have a congenital upper limb arterial anomaly, tests as fast and easy as the Allen test are

quite useful to check upper extremity perfusion and eventually to help the operator to perform the surgery.

## Acknowledgments

All authors have no conflicts of interest to disclose. All authors have made substantial contributions to conception and design of the study, acquisition, analysis, interpretation of data, drafting the article and revising it.

## References

- Bhatt V., Hall T.J. (2010) Anatomical variations in forearm vascular anatomy. *J. Craniomaxillofac. Surg.* 38: 244.
- Ciervo A., Khan M., Pangilinan A.J., Dardik H. (2001) Absence of the brachial artery: Report of a rare human variation and review of upper extremity arterial anomalies. *J. Vasc. Surg.* 33: 191-194.
- Jarvis M.A., Jarvis C.L., Jones P.R., Spyt T.J. (2000) Reliability of Allen's test in selection of patients for radial artery harvest. *Ann. Thorac. Surg.* 70: 1362-1365.
- Lee J.H., Ju R.K., Jun Y.J., Kim Y.J. (2015) A rare case of bilateral absence of distal ulnar artery. *Plast. Aesthet. Res.* 2: 79-80.
- McCormack L.J., Cauldwell E.W., Anson B.J. (1953) Brachial and antebrachial arterial patterns; a study of 750 extremities. *Surg. Gynecol. Obstet.* 96: 43-54.
- Muratore T., Ozer K. (2011) Persistent median artery in pediatric trauma patient: case report. *J. Hand Surg. Am.* 36: 658-660.
- Panagouli E., Anagnostopoulou S., Venieratos D. (2014) Bilateral asymmetry of the highly bifurcated brachial artery variation. *Rom. J. Morphol. Embryol.* 55 : 469-472.
- Ro H.S., Roh S.G., Shin J.Y., Lee N.H., Yang K.M. (2016) Unusual anatomic variations associated with bilateral ulnar artery hypoplasia. *J. Craniofac. Surg.* 27: 749-750.
- Rodriguez-Niedefuhr M., Vazquez T, Parkin I.G., Sanudo J.R. (2003) Arterial patterns of the human upper limb: update of anatomical variations and embryological development. *Eur. J. Anat.* 7 (S1): 21-28.
- Zhao X., Ma X., Guo L. (2016) Congenital absence of the ulnar artery. *J. Hand Surg. Eur.* 41: 773-774.