

Research Article - Basic and Applied Anatomy

A cephalometric morphometric study of age- and gender-dependent shape patterns of the sella turcica

Ayman G. Mustafa^{1,2,*}, Jamal H. Abu Ghaida¹, Anas J. Mistareehi¹, Mohammed Z. Allouh¹, Saab M. Mistarihi³¹ Department of Anatomy, Faculty of Medicine, Jordan University of Science and Technology, Jordan² College of Medicine, Qatar University, Doha, Qatar³ Royal Medical Services, Jordanian Armed Forces. King Hussein Medical Center, Jordan

Abstract

The sella turcica is an important anatomic and radiologic entity. The shape of the sella turcica varies among normal individuals and can be influenced by local factors. The normal shape of sella turcica has been categorized as circular, oval, and flat, and several variants have been described. The sella turcica increases in size with age, but there is no agreement upon significance of gender-related differences. The main objective of this study is to build up a normative database of the shape of the sella turcica in the Jordanian population with reference to age and gender. For this purpose 509 computed cephalograms: 252 males and 257 females, aged 10 to 40 years old healthy Jordanians were collected and divided into adolescent and adult age groups in both genders. Viewbox 3 software was used to determine width and height, and shape of the sella turcica was accordingly assessed. Variants of shape were also documented. Our results showed that females exhibit higher percentage of overall normal shape but lower relative percentages of oval and flat shapes, as compared with males. In contrast to males, females also show decreasing trend of normal shape as age advances. Females and males change obviously in favor of oval shape. In terms of variants, as individuals advance in age, bridging and irregular dorsum clearly predominate. In terms of width and height, significant differences were evident between adult male group on one hand and adolescent female group and adult female group on the other hand. Between age categories and within male and female groups, sella linear dimensions were significantly different between adolescent and adult age groups. The significant increase of linear parameters of sella turcica across age groups indicates that there is significant degree of growth in sella turcica across the studied age groups. However, this growth does not affect the shape of sella turcica as the shape seems to be preserved across the studied age groups. The obtained data are discussed in terms of age- and gender-related growth and degenerative bone changes.

Key words

Morphometry, shape analysis, Jordan.

Introduction

The sella turcica, the Turkish saddle, is composed of the tuberculum sellae, the hypophysial fossa, and the dorsum sellae (Jones et al, 2005). In particular, the resemblance to the Turkish saddle stems from its high front and back support (Mutluer, 2006).

* Corresponding author. E-mail: agmustafa@just.edu.jo

The shape of the sella turcica is determined by anatomical structures in the sellar region i.e pituitary gland, the extent of the anterior and posterior intercavernous venous sinuses (Renn and Rhoton, 1975), and osseous bridges between the clinoid processes, and the internal carotid artery (Inoue et al, 1990). In addition, and based on studies on monozygotic twins and on correlation studies between sella shape in parents and in the offspring, the shape of the sella turcica is also genetically determined (Snijder and Blank, 1945, Brock-Jacobsen et al, 2009).

The general morphology of the normal sella turcica is categorized as circular, oval, and flat, with the oval type as the most frequent and the flat as the least frequent recognized shape. This so-called normal sella shape was repeatedly reported to account for approximately two thirds of cases in the absence of clinical pathology (Camp, 1923, Choi et al, 2001, Axelsson et al, 2004, Alkofide, 2007, Shah et al, 2011). Variants of shape represent the remaining third including oblique anterior wall, sella turcica bridge, double contour of the floor, irregular dorsum, and pyramidal dorsum (Camp, 1923, Lung and Tisch-rottensteiner, 1977, Kantor and Norton, 1987, Becktor et al, 2000, Alkofide, 2007). Interestingly in this regard, (Andredaki et al, 2007) reported uniform distribution of shape with no clear-cut grouping.

From an embryologic point of view, the sella turcica develops in the most anterior part of the germ sheet (Mueller and ORahilly, 2003). It should be noted that the anterior and posterior walls of the sella turcica have different origins (Miletich and Sharpe, 2004). The development of the pituitary gland is closely coordinated with that of the sella (Shing and Westphal, 1999). Postnatally, the contour of the anterior wall of the sella turcica remains stable, however, the floor and dorsal wall of the sella undergo resorption till early postpubertal age. The apposition of bone anteriorly stops at an early age, while resorption lasts longer up to 16-18 years of age posteriorly thus displacing the sella point backward and downward (Melsen, 1974).

Doubtlessly, clinicians need a baseline for normal radiographic anatomy and variability of the sella turcica to be able to better recognize and effectively investigate changes that may reflect pathological conditions, even prior to the onset of symptoms of pituitary or craniofacial syndromes (Andredaki et al, 2007). Indeed, changes of the sella are often the only indication of pathological cranial abnormality (Meschan, 1975).

In our previous study (Abu Ghaida et al, 2017), we confirmed the general trend of increase of linear sellar parameters and area with age, irrespective of gender in Jordanian population. We showed that the area showed the most obvious increase, which was differentially contributed for by the height of the sella in females and the length of the sella in males. This present study aims at building up a normative database describing the shape of the sella turcica in healthy Jordanians. Special attention is focused on age- and gender-related impact on this topic.

Materials and methods

Sample of study

The study sample consists of 509 computed lateral cephalograms of Jordanian subjects which were taken in a referral hospital in Amman-Jordan in the period from the beginning of 2013 to the end of 2014. The subjects were 252 males and 257

females, aged 10 to 40 years, who were seeking dental treatment only, but otherwise healthy with no diagnosed syndromes, surgical interventions, clefts or other malformations. As inclusion criteria all the computed lateral cephalograms exhibited the following features:

1. Clear reference ruler to correct the magnification of the images.
2. Good quality with clear radiographic landmarks and sella turcica outline needed for the measurement of the parameters of the sella turcica. Malocclusion and skeletal classes were not considered as criteria for the selection of the radiographs.

Determination of sella shape

Determination of normal shape of sella turcica was based on the numerical relation between the width and the height of the sella as proposed by Sniyder and Blank (1945) (see below). Circular shape corresponds to a ratio of sella width to height of approximately 1:1, oval shape corresponds to a ratio of approximately 1.5:1, flat shape corresponds to a ratio of approximately 2:1.

Determination of sella shape variants

Variants of shape, as described by Axelsson et al (2004) were morphologically diagnosed and grouped in categories including oblique anterior wall, sella turcica bridging, irregularity in posterior part of dorsum sellae (notching), pyramidal shape of the dorsum sellae, and double contour of the floor. The oblique anterior wall was determined according to the angle calculated by the computer software Viewbox 3 between a line of the sella anterior wall and a line passing through tuberculum sellae parallel to Frankfort horizontal line (see below). An angle equal or less than 45 degrees was considered as a criterion for the oblique anterior wall shape. Sella turcica bridging was only diagnosed when a complete and clear bridge presented joining the anterior and posterior clinoid processes.

Morphometry

Linear measurements of the sella turcica were performed on lateral cephalograms as previously described (Abu Ghaida et al, 2017). The cephalograms were scanned at 300 dpi, and software Viewbox 3 (dHAL Software, Kifissia, Greece) was used to study the sella turcica. To avoid bias during the measurements all the cephalograms were numbered at random, and the information related to the patients was concealed. All further work with the cephalograms was performed using these number codes, without revealing the data related the patient. Only after the measurements were completely done and archived, corresponding personal data for each number code was taken into consideration for data grouping and statistical analysis. The following points in the sella turcica were first determined and digitized (Silverman, 1957, Andredaki et al, 2007):

1. Orbitale: The most inferior point of the orbital floor below the center of the eye.
2. Porion: The most superior point of the external auditory meatus. Alternatively, the superior fossa of the temporomandibular joint, which lies at the same level, was used as a substitute.

3. Tuberculum sellae (TS): The anterior boundary of the sella turcica.
4. Posterior clinoid process (PClin).
5. Tip of the anterior clinoid process.
6. Tip of the posterior clinoid process.

The first two points were used to construct Frankfort horizontal line (FH). The contour of the sella turcica was traced from TS to PClin, and nine additional, equally spaced points along the internal contour of the sella turcica were defined. On the basis of these 11 points the computer software was used to define the following points (Diagram 1):

1. Sella most anterior: The most anterior point in the inner contour of the sella turcica.
2. Sella most posterior: The most posterior point in the inner contour of the sella turcica.
3. Sella floor: The lower most point in the inner contour of the sella turcica.
4. Midpoint between TS and PClin.

Using FH line as the reference (Diagram 1) and after adjusting the magnification of the radiographs the:

1. Sella width: The largest antero-posterior dimension from sella posterior to sella anterior, and
2. Sella height: The vertical distance from the sella floor to the midpoint between PClin and TS, were measured.

Statistical analysis

The cephalograms were categorized into two age groups for both genders. The groups were selected to represent adolescence group: 10-19 years old (total number 396: 207 males, 189 females), and adulthood group: 20-40 years old (total number 113: 45 males, 78 females), as advised by the World Health Organization (www.WHO.int/). For each age group and in both genders the basic statistics were performed for linear measurements of the sella turcica. Measurements were calculated to the nearest 0.01 mm. Statistical analysis of data was performed by transferring the data to a scientific statistical program (SPSS Inc., Chicago, Illinois, USA). Correlation tests were performed to describe statistically significant differences of normal shape, shape categories, and variants categories in addition to width and height of the sella with regard to gender and age using the Student's t-test for independent data with significance level of 5% ($P < 0.05$).

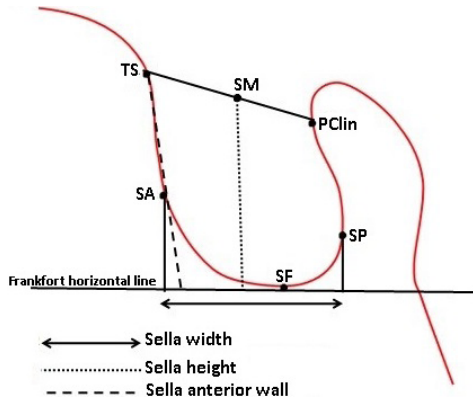


Diagram 1. Measurements of the sella turcica. TS = tuberculum sellae, SA = sella most anterior point, SF = sella floor, SP = sella most posterior point, PClin = posterior clinoid process, SM = sella median point. According to Andredaki et al., 2007, and Abu Ghaida et al., 2017, with modifications.

Error analysis

In accordance with Houston (1983), the accuracy and reproducibility of the measurements were confirmed by repeating the measurements for randomly selected 103 cephalograms by the same operator on three separate occasions with at least one week interval between the repeated measurements. Original and repeated sets of measurements were analyzed for significance of differences, coefficient of reliability, and variance.

Results

Width and height measurements

Table 1 shows the means of measured values for length and width of the sella for the overall test sample, the overall male and female groups, the overall adolescent and adult age groups, and for adolescent male and female groups and adolescent male and female groups. All values are expressed as mean \pm standard deviation, minimum and maximum values in mm.

Shape description and analysis

Figures 1-10 show representative cephalograms of normal shapes and variants of the sella turcica in different age groups and in both genders.

Table 1. Descriptive statistics of width and height of the sella turcica (expressed in mm; mean \pm standard deviation, minimum and maximum values).

Studied Groups	Width	Height
Total sample (No: 509)	8.69 \pm 1.34 (5.80 - 13.90)	6.32 \pm 1.03 (3.7 - 11.2)
Male (No: 252)	8.72 \pm 1.42 (6.2 - 13.9)	6.25 \pm 1.09 (3.7 - 11.2)
Female (No: 257)	8.67 \pm 1.26 (6.0 - 13.0)	6.38 \pm 0.96 (4.0 - 8.6)
Adolescent (No: 396)	8.51 \pm 1.29 (6.0 - 14.0)	6.16 \pm 0.96 (3.7 - 9.1)
Adulthood (No: 113)	9.32 \pm 1.32 (6.0 - 13.4)	6.87 \pm 1.06 (4.0 - 11.2)
Male adolescent (No: 207)	8.48 \pm 1.29 (6.2 - 13.8)	6.08 \pm 0.97 (3.7 - 9.1)
Female adolescent (No: 189)	8.55 \pm 1.30 (6.0 - 13.0)	6.24 \pm 0.95 (4.0 - 8.6)
Male adulthood (No: 45)	9.81 \pm 1.48 (7.4 - 13.4)	7.05 \pm 1.24 (4.7 - 11.2)
Female adulthood (No: 68)	9.00 \pm 1.10 (6.0 - 12.0)	6.75 \pm 0.90 (4.0 - 8.6)

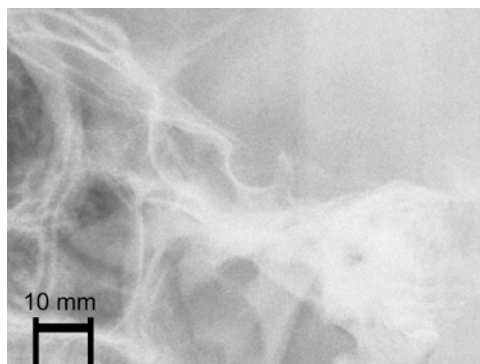


Figure 1. Sella turcica with normal shape (lateral cephalogram of adult female).

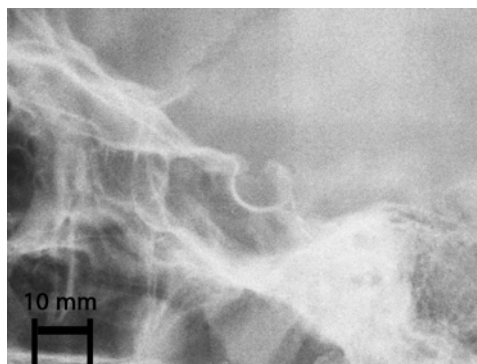


Figure 2. Sella turcica with circular shape (lateral cephalogram of adolescent male).

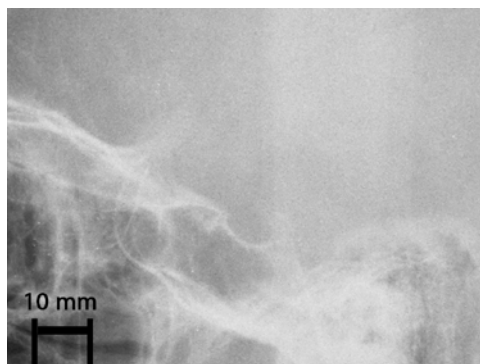


Figure 3. Sella turcica with oval shape (lateral cephalogram of adolescent male).

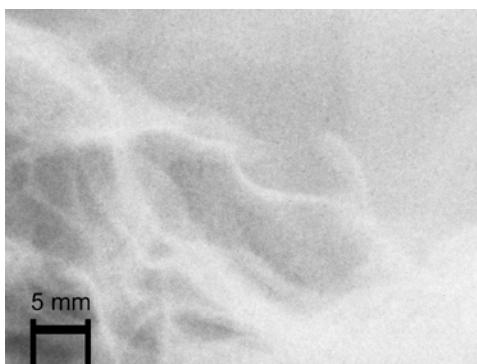


Figure 4. Sella turcica with flat shape (lateral cephalogram of adolescent female).

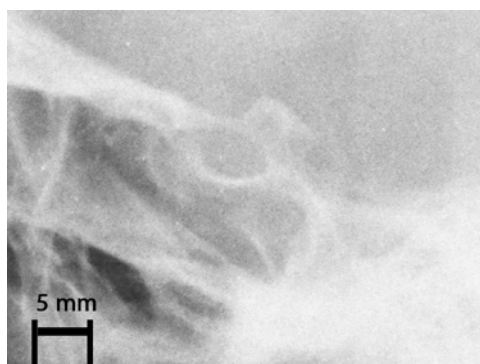


Figure 5. Sella turcica with complete bridge (lateral cephalogram of adult female).

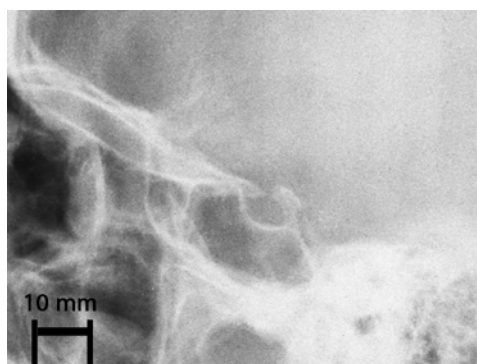


Figure 6. Sella turcica with incomplete bridge (lateral cephalogram of adult female).

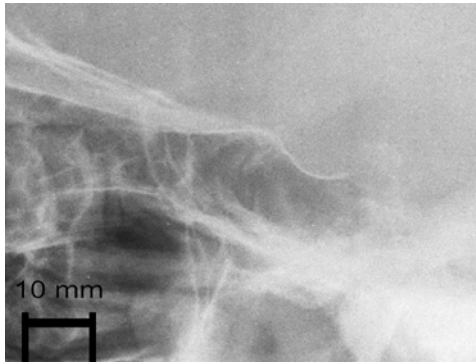


Figure 7. Sella turcica with oblique anterior wall (lateral cephalogram of adult male).




Figure 8. Sella turcica with double floor (lateral cephalogram of adult female).

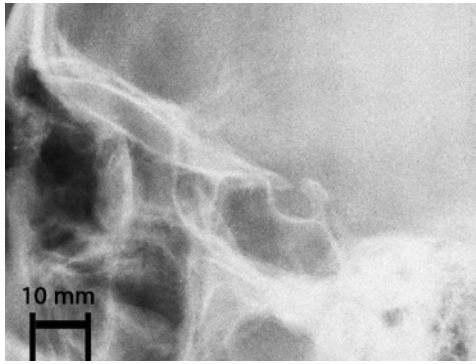


Figure 9. Sella turcica with notched dorsum (lateral cephalogram of adult female).




Figure 10. Sella turcica with pyramidal dorsum (lateral cephalogram of adolescent male).

Table 2 and Table 3 show number of cases for each shape category and variants in each age group and gender. Percentages of shape categories in reference to overall sample and corresponding reference group are also shown.

Correlations of shape categories and linear parameters

No significant correlation is evident between either age or gender with the sella shape (P -value >0.05). However, significant correlation between normal shape and presence of oblique anterior wall shape variant is present. Oblique anterior wall was more common with the oval shape followed with the circular shape and least with the flat shape.

Differences between mean width, but not mean height were significant between adult male and adult female age groups (P value <0.05). Within each gender group, differences between adolescent and adult male or female age groups were significant for width and height.

Table 2. Descriptive statistics of normal shape categories of the sella turcica.

Studied groups	Number of normal shape (% of the total cases)	Number of normal shape subcategories (% of total normal cases)		
		circular	oval	flat
Overall sample (No=509)	405 (79.6%)	124 (30.7%)	244 (60.2%)	37 (9.1%)
Total male group (No=252)	193 (76.6%)	51 (26.4%)	121 (62.7%)	21 (10.9%)
Total female group (No=257)	212 (82.5%)	73 (34.5%)	123 (58%)	16 (7.5%)
Total adolescence age group (No=396)	314 (79.3%)	95 (30.3%)	192 (61.1%)	27 (8.6%)
Total adulthood age group (No=113)	91 (80.5%)	29 (31.9%)	52 (57.1%)	10 (11%)
Male adolescence age group (No=207)	158 (76.3%)	41 (26.0%)	102 (64.5%)	15 (9.5%)
Male adulthood age group (No=45)	35 (77.8%)	10 (28.6%)	19 (54.3%)	6 (17.1%)
Female adolescence age group (No=189)	156 (82.5%)	54 (34.6%)	90 (57.7%)	12 (7.7%)
Female adulthood age group (No=68)	56 (82.4%)	19 (33.9%)	33 (58.9%)	4 (7.2%)

Table 3. Descriptive statistics of shape variants of the sella turcica.

Studied groups	Number of variants (% of total cases)	Number of variants subcategories (% of total variant cases)				
		Oblique anterior wall	Sellar bridge	Double floor	Notched dorsum	Pyramidal dorsum
Overall sample (No=509)	104 (20.4%)	22 (18.2%)	40 (33%)	18 (14.9%)	15 (12.4%)	26 (21.5%)
Total male group (No=252)	59 (23.4%)	15 (21.4%)	20 (28.6%)	10 (14.3%)	8 (11.4%)	17 (24.3%)
Total female group (No=257)	45 (17.5%)	7 (13.7%)	20 (39.2%)	8 (15.7%)	7 (13.7%)	9 (17.6%)
Total adolescence age group (No=396)	82 (20.7%)	20 (21.1%)	28 (29.5%)	14 (14.7%)	10 (10.5%)	23 (24.2%)
Total adulthood age group (No=113)	22 (19.5%)	2 (7.7%)	12 (46.2%)	4 (15.4%)	5 (19.2%)	3 (11.5%)
Male adolescence age group (No=207)	49 (23.7%)	13 (22.8%)	16 (28.1%)	7 (12.3%)	6 (10.5%)	15 (26.3%)
Male adulthood age group (No=45)	10 (22.2%)	2 (15.4%)	4 (30.8%)	3 (23.1%)	2 (15.4%)	2 (15.4%)
Female adolescence age group (No=189)	33 (17.5%)	7 (18.9%)	12 (32.4%)	7 (18.9%)	4 (10.8%)	8 (21.6%)
Female adulthood age group (No=68)	12 (17.6%)	0 (0.0%)	8 (61.5%)	1 (7.7%)	3 (23.1%)	1 (7.7%)

Table 4. Error analysis of the morphometric measurements.

Parameter	Original measurements (in mm)	Repeated measurements (No: 103, in mm)
Width	8.17 ± 0.13	8.53 ± 0.14
Height	6.07 ± 0.09	6.50 ± 0.10

Error calculation

The statistical analysis of the original and repeated measurement (Table 4) using paired t-test revealed no significant differences (P value>0.05) between the two sets of measurements. No systematic error was detected between the original and repeated measurements. Differences between original and repeated measurements ranged from 0.2-0.6 mm for the linear parameters of the sella. The coefficients of reliability were as following: Width = 91.8, Height = 92.1.

The random error (the square root of half of the variance of the difference between duplicate measurements) ranged from 0.052-0.093 mm.

Discussion

The importance of carrying out this work is based on both academic and applied clinical grounds. Radiographs of the normal sella turcica were reported to provide information that coincide well with data obtained from direct measurements on autopsy specimens (Camp, 1923), and provide a high sensitivity for detection of sellar changes (Du Boulay and Trickey, 1967). The relevance of radiological studies remains valid (Denk et al, 1999, Venieratos et al, 2005), in spite of studies showing that computer tomography and magnetic resonance imaging provide much greater sensitivity than cephalograms for detection of pituitary pathology (Kricheff, 1979).

Our results show that the normal shape i.e. absence of any variation, clearly predominates, accounting for approximately 80% of cases. Moreover, the oval category represents the most frequently seen shape mounting up to 60% of normal cases. The next common category is the circular shape (30%), while the flat shape is least evident (10%). Our data in this regard correlate well with already published data (Camp, 1923, Choi et al, 2001, Axelsson et al, 2004, Alkofide, 2007, Zagga et al, 2008, Najim and Al-Nakib, 2011, Shah et al, 2011). Regarding variants of shape (Axelsson et al, 2004), our results show that sellar bridge is the most common variant mounting up to approximately 33% of all variants. As next common variants are pyramidal dorsum and oblique anterior wall (Approximately 20% each). The least common variants are double floor and notched dorsum with approximately 13% for each.

Noteworthy, however, are the age-dependent, and gender-dependent differences regarding overall normal shape and percentages of categories on one hand, and overall variants and percentages of variant categories, on the other hand.

Females show higher percentage (Approximately 6%) of normal shape regardless of age. Furthermore, higher percentage of circular category (Approximately 9%)

and lower percentages of oval and flat categories are evident. Males, on the other hand, exhibit higher percentages of oval and flat categories (Approximately 8% and 3%, respectively). This trend is clearly age-dependent, as the oval and flat categories increase 11% and 7% between adolescent and adult groups, respectively. Dissected into gender, males show more change to circular and flat categories at the expense of lower oval category. Females, however, show an opposite trend.

As for percentages of variants, the overall incidence of approximately 20% can be further dissected into gender- and age-dependent patterns. Higher incidence of variants are evident in males (Approximately 5%). In overall terms, males show higher percentages of oblique anterior wall and pyramidal dorsum (Approximately 7% and 6%, respectively). Females, on the other hand, show an obvious higher percentage of sellar bridging (Approximately 10%).

In terms of age, as individuals pass to adulthood, a general trend of increase of the percentages of sellar bridging and notched dorsum (Approximately 16% and 8%, respectively). Oblique anterior wall and pyramidal dorsum, however, decrease (Approximately 13% and 12%, respectively). In this regard and as males and females advance into adulthood, males show an increase of percentages of sellar bridging, double floor, and notched dorsum (Approximately 3%, 11%, 4%, respectively), but decrease of percentages of oblique anterior wall and pyramidal dorsum (Approximately 8% and 11%, respectively). In females, on the other hand, the percentages of sellar bridging and notched dorsum increase (20% and 12%, respectively), while the percentages of double floor and pyramidal dorsum and oblique anterior wall decrease (Approximately 11%, 14%, and 0% respectively).

This observed pattern of change could be discussed in terms of normal age-related changes of bony elements of the sella. In fact, age-dependent changes in the shape of the sella turcica during growth have been shown to manifest in that the contour of the anterior wall of the sella turcica remains stable after early childhood, while the floor and dorsal wall of the sella undergo resorption till postpuberty, thus displacing the sella point backward and downward (Melsen, 1974). Variants of shape could be correlated with the appearance of age-related degenerative bone changes and calcification of the diaphragma sellae, which have been actually reported as a normal processes in the absence of any pathology (Kantor and Norton, 1987, Cederberg et al, 2003, Axelsson et al, 2004, Jones et al, 2005). Moreover, the double sellar floor may result from depression of the central part of the floor, asymmetry of floor of sphenoid sinus, or as effect of the carotid groove. The sphenoid sinus may also extend into the dorsum sellae.

In terms of sellar linear parameters: width and height, on which the determination of shape rests, significant differences regarding these dimensions between genders was found between adolescent and adult age groups, with sellar height being larger in females (Andredaki et al, 2007, Chauhan et al, 2014). This finding lies in accordance with our results (Abu Ghaida et al, 2017). Age-dependent changes of the height and width of the sella turcica in our study clearly confirm the classical notion of the trend of increase of parameters with age, irrespective of gender, although more in males (Haas, 1954, Fissure and DiChiro G, 1964, Israel, 1970, Tetradis and Kantor, 1999, Alkofide, 2007, Yasser et al, 2010, Filipovic et al, 2011, Najim and Al-Nakib, 2011), Shah et al, 2011, Chavan et al, 2012, Chauhan et al, 2014, Osunwoke et al, 2014). Expressed in percentages, our data show that the height undergoes significant over-

all increase of approximately 12% (8% in females). So while the sella expands in all directions in males most obviously (approximately 18%) in the length (Abu Ghaida et al, 2017), the height seems to be the major parameter of increase in females i.e. the sella becomes taller. This differential behavior has been already published regarding sellar length (Axelsson et al, 2004), and sellar height (Chauhan et al, 2014).

It must be noted that data related to measurements of the sella coincide well with studies performed on pituitary dimensions. In this regard, gradual increase in coronal and sagittal dimensions of the pituitary gland in both sexes up to 20 years of age has been shown (Denk et al, 1999). Moreover, it has been reported that changes in pituitary size as a function of age are mainly due to changes in gland height but not length or width (Doraiswamy et al, 1992, Hayakawa et al, 1989, Lurie et al, 1990). These changes may reflect normal neuro-endocrine differences between ages and sexes (Tsunoda et al, 1997). The discrepancy regarding significant correlations of height and width of the sella turcica in relation to age, irrespective of the gender, and significant gender-related differences of width of the sella turcica in adulthood, but the absence of significant correlation between either age or gender with the sella shape suggests that a significant increase of linear parameters of sella turcica across age groups runs parallel with significant age-related growth of the sella turcica. However, this growth does not affect the shape of sella turcica. Indeed, the shape seems to be preserved across the studied age groups as growth does not change the ratios of linear parameters to each other, which are used to determine the shape mathematically. The significant correlation between normal shape categories and presence of oblique anterior wall variant, on the other hand, seems to be a direct geometric association of shape, rather than an age-related change as oblique anterior wall was more common with the oval shape followed with the circular shape and least with the flat shape.

In the light of the results of our present study and the knowledge we were able to gather in our literature review and data compilation, we conclude that:

1. The shape categorization we present can be regarded as a normative database for this important anatomical and clinical entity in adolescent and adult Jordanians. To the best of our knowledge, this study represents the first comprehensive study conducted in Jordan so far.
2. The sella shape categories and incidence of shape variants in Jordanian population correlate well with corresponding data in the literature in other parts of the world, and speaks against a racial impact on this topic.
3. Age- and gender-related pattern of change of the shape of the sella turcica, and the change of incidence of shape variants appear to reflect anatomic changes related to somatic growth and hormonal activity of the pituitary gland which affect floor and posterior wall of the sella in first place, and go hand in hand with degenerative changes affecting local structures.
4. Significant change in height and width of the sella turcica is directly related to age, irrespective of gender, but this change does not lead to overall change of sella shape.
5. Future studies should focus on comparison between normal and pathologic cases to find out if one particular change of shape or appearance of specific shape variant could be adopted as a specific indicator of abnormality of the sella turcica.

Acknowledgments

The authors wish to express their deep gratitude to Mr. Saleem Rabadi, Art Director, Vast Technologies, Amman-Jordan and Mr. Noor Aldean Sleaman Sbaihhat, Radiology Technician, Royal medical services, for their professional help in collecting and processing the radiographs and diagrams.

This work is part of the MSc Thesis submitted by Mr. Anas Mistarehi in partial fulfillment of the requirements for obtaining the MSc Degree in Anatomy by the faculty of Higher Studies at the Jordan University of Science and Technology in August 2015.

This work has been supported by Grant No: 89/2015 by the Faculty of Research at Jordan University of Science and Technology

References

- Abu Ghaida J.H., Mistareehi A.J., Mustafa A.G., Mistarihi S.M., Ghozlan H.H. (2017) The normal dimensions of the sella turcica in Jordanians: a study on lateral cephalograms. *Folia Morphol. (Warsz)* 76: 1-9.
- Alkofide E.A. (2007) The shape and size of the sella turcica in skeletal class I, II, and III Saudi subjects. *Eur. J. Orthod.* 29: 457-463.
- Andredaki M., Koumantanou A., Dorotheou D., Halazonetis D.J. (2007) A cephalometric morphometric study of the sella turcica. *Eur. J. Orthod.* 29: 449-456.
- Axelsson S., Storhaug K., Kjaer I. (2004) Postnatal size and morphology of the sella turcica. Longitudinal cephalometric standards for Norwegians between 6 and 21 years of ages. *Eur. J. Orthod.* 26: 597-604.
- Becktor J., Einersen S., Kjaer I. (2000) A sella turcica bridge in subject with severe craniofacial deviations. *Eur. J. Orthod.* 22: 69-74.
- Brock-Jacobsen M.T., Pallisgaard C., Kjaer I. (2009) The morphology of sella turcica in monozygotic twins. *Twin Res. Hum. Genet.* 12: 598-604.
- Camp J.D. (1923) The normal and pathologic anatomy of the sella turcica as revealed at necropsy. *Radiology* 1: 65-73.
- Cederberg R.A., Benson B.W., Nunn M., English J.D. (2003) Calcification of the interclinoid and petroclinoid ligaments of sella turcica: a radiographic study of the prevalence. *Orthod. Craniofac. Res.* 4: 227-232.
- Chavan S.R., Kathole M.A., Katti A.S., Herekar N.G. (2012) Radiological analysis of sella turcica. *Int. J. Recent Trends in Science and Technology* 4: 36-40.
- Chauhan P., Kalra S., Mongia S.M., Ali S., Anureg A. (2014) Morphometric analysis of sella turcica in north Indian population: A radiological study. *Int. J. Res. Med. Sci.* 2: 521-526.
- Choi W.G., Hwang E.H., Lee S.R. (2001) The study of shape and size of normal sella turcica in cephalometric radiographs. *Korean J. Oral Maxillofac. Radiol.* 31: 43-49.
- Denk C.C., Onderoglu S., Ilgi S., Gurcan F. (1999) Height of normal pituitary gland on MRI: differences between age group and sexes. *Okajimas Folia Anat. Jpn.* 76: 81-88.
- Doraiswamy P.M., Potts J.M., Axelson D.A., Husain M.M., Lurie S.N., Na C., Escalona P.R., McDonald W.M., Figiel G.S., Ellinwood E.H. Jr (1992) MR assessment of pitu-

- itary gland morphology in healthy volunteer: age-and gender-related differences. *AJNR Am. J. Neuroradiol.* 13: 1295-1299.
- Du Boulay G.H., Trickey S. (1967) The choice of radiological investigations in the management of tumors around the sella. *Clin. Radiol.* 18: 349-365.
- Filipovic G., Puric M., Janosevic M., Stosic M. (2011) Radiological measuring of sella turcica's size in different malocclusions. *Acta Stomatologica Naissi* 27: 1035-1042
- Fissure R.L., DiChiro G. (1964) The small sella turcica. *Am. J. Roentgenol. Radium Ther. Nuc. Med.* 91: 996-1008.
- Haas L.L. (1954) The size of the sella turcica by age and sex. *Am. J. Roentgenol. Radium Ther. Nuc. Med.* 72: 754-761.
- Hayakawa K., Konishi Y., Matsuda T., Kuriyama M., Konishi K., Yamashita K., Okumura R., Hamanaka D. (1989) Development and aging of brain midline structure: assessment with MR imaging. *Radiology* 172: 171-177.
- Huoston W.J.B. (1983) The analysis of errors in orthodontic measurements. *Am. J. Orthod.* 83: 382-389.
- Inoue T., Rhoton A.L., Dan Theele D.V.M., Barry M.E. (1990) Surgical approaches to the cavernous sinus: A microsurgical study. *Neurosurgery* 26: 903-931.
- Israel H. (1970) Continuing growth of the sella turcica with age. *Am. J. Roentgenol.* 108: 516-527.
- Jones R.M., Faqir A., Millett D.T., Moos K.F., McHygh S. (2005) Bridging and dimensions of sella turcica in subjects treated by surgical-orthodontic means or orthodontics only. *Aggel Orthod.* 75: 714-718.
- Kantor M.L., Norton L.A. (1987) Normal radiographic anatomy and common anomalies seen in cephalometric film. *Am. J. Orthod. Dentofac. Orthop.* 91: 414-426.
- Kricheff I.I. (1979) The radiologic diagnosis of pituitary adenoma: an overview. *Radiology* 131: 263-265.
- Lung J., Tisch-Rottensteiner K.F. (1977) Ueber Form und Formvarianten der Sella turcica. *Verh. Anat. Ges.* 71: 1279-1282.
- Lurie S.N., Doraiswamy P.M., Husain M.M., Boyko O.B., Ellinwood E.H. Jr, Figiel G.S., Krishnan K.R. (1990) In vivo assessment of pituitary gland volume with magnetic resonance imaging: the effect of age. *J. Clin. Endocrinol. Metab.* 71: 505-508.
- Melsen B. (1974) The cranial base. The post natal development of the cranial base studied historically on human autopsy material. *Acta Odont. Scand.* 32: 57-71.
- Meschan I. (1975) An atlas of anatomy basic to radiology. W.B. Saunders, Philadelphia. Pp. 343-348.
- Miletich I., Sharpe P.T. (2004) Neural crest contribution to mammalian tooth formation. *Birth Defects Res.* 72: 200-212.
- Mueller F., O'Rahilly R. (2003) The prechordal plate, the rostral end of the notochord and nearby median features in staged human embryos. *Cells Tissues Organs* 173: 1-20.
- Mutluer S. (2006) Sella turcica, *Childs Nerv. Cyst.* 22: 333.
- Najim A.A., Al-Nakib L. (2011) A cephalometric study of sella turcica size and morphology among young Iraqi normal population in comparison to patients with maxillary malposed canine. *J. Bagh. Coll. Dentistry* 23: 53-58.
- Osunwoke E.A., Mokwe C.R., Amah-Tariah F.S. (2014) Radiologic measurements of the sella turcica in an adult Nigerian population. *Int. J. Pharmacol. Res.* 4: 115-117.

- Renn W.H., Rhoton A.L. (1975) Microsurgical anatomy of the sellar region. *J. Neurosurg.* 43: 288-289.
- Shah A.M., Bashir U., Ilyas T. (2011) The shape and size of the sella turcica in skeletal class I, II and III in patients presenting at Islamic international dental hospital, Islamabad. *Pakistan Oral Dental J.* 31: 104-110.
- Shing H.Z., Westphal H. (1999) Early steps in pituitary organogenesis. *Trends Genet.* 15: 236-240.
- Silverman F.N. (1957) Roentgen standards for size of the pituitary fossa from infancy through adolescence. *Am. J. Roentgenol.* 78: 451-460.
- Snyder L.H., Blank F. (1945) Studies in human inheritance. XXVII, the inheritance of the shape of the sella turcica. *Ohio J. Sci.* 45: 12-15.
- Tetradis S., Kantor M.L. (1999) Prevalence of skeletal and dental anomalies and normal variants seen in cephalometric and other radiographs of orthodontic patient. *Am. Orthod. Dentofac. Orthoped.* 116: 572-577.
- Tsunoda A., Okuda O., Sato K. (1997) MR height of the pituitary gland as a function of age and sex: special physiological hypertrophy in adolescence and in climacterium. *AJNR Am. J. Neuroradiol.* 18: 551-554.
- Venieratos D., Anagnostopoulou S., Garidou A. (2005) A new morphometric method for the sella turcica and the hypophyseal fossa and its clinical relevance. *Folia Morphol.* 64: 240-247.
- Yasser Y.A., Nahidh M., Yousif H.A. (2010) Size and morphology of sella turcica in Iraqi adults. *MDJ* 7: 23-30.
- Zagga A.D., Ahmed H., Tadros A.A., Saido S.A. (2008) Description of the normal variant of the anatomical shape of the sella turcica using plane radiographs: experience from Sokoto, northwestern Nigeria. *Ann. Afr. Med.* 7: 77-81.