



บทความทบทวนผู้ป่วย
(Case review)

Cases Report: Clavicular Fractures after Hook-Plate Fixation Surgery

Thitinut Dilokhuttakarn¹, Ronnachit Boonprasert¹, Chaturong Pornrattanamaneewong²

¹ Department of Orthopaedics, Faculty of Medicine, Srinakharinwirot University

² Department of Orthopaedics, Faculty of Medicine, Siriraj Hospital, Mahidol University

Abstract

The clavicular hooked plate had been used worldwide for fixation the unstable fracture of the distal clavicle and displaced acromioclavicular joint dislocation. Although it has been widely accepted as the new device used, some complications were still present. The reported complications include acromion fracture, clavicle fracture at the medial end of the hook plate, recurrent acromioclavicular joint subluxation, disengagement of plate as well as subacromial pain and impingement. There were few reports about complications after hook plate fixation surgery. The present study reported 2 cases of clavicle fracture at the medial end of the hook plate after the operation. The first case was diagnosed with displaced fracture at distal end of right clavicle (Neer type II) and the second case was diagnosed with displaced right acromioclavicular joint (Rockwood type IV). All fracture lines were initiated beneath the medial end of hook plate and adjacent to medial screw which indicated a weak point. Additionally, the stress at the medial end of the hook plate was increased. Both patients were received conservative treatment and were not performed re-fixation surgery. They achieved clavicle union with a good functional result.

Keywords: clavicular fractures, hook plate, complications

Corresponding author:

Thitinut Dilokhuttakarn

Department of Orthopaedics, Faculty of Medicine, Srinakharinwirot University

62 Moo 7 Rangsit-Nakhon Nayok Road,

Ongkharak, Nakhon Nayok 26120

E-mail: thitinutbank@gmail.com

■ Introduction

The clavicular hook plate has been used as a device for fixation the unstable fracture of the distal clavicle (Neer type II) and acromioclavicular joint dislocation. The great clinical results for patients treated with hook plates have been reported but some complications are still present¹. The reported complications with this device are acromion fracture, clavicle fracture at the medial end of the hook plate, recurrent acromioclavicular joint subluxation, disengagement of plate as well as subacromial pain and impingement². Therefore this device is advised to remove at the 8th to 12th week after operation, prior to perform full range of motion of shoulder joint^{2,3}.

We reported complications from using hook plate fixation in 2 cases who manifested with clavicular fracture at the medial end of hook plate in retained implant patients resulting in a secondary shoulder injury. The clavicular fractures were conservatively treated and none of the patients required surgery. All patients with complicated fracture presented bone union at the fracture site with a good functional result then the hook plates were removed after bone union of clavicular fractures.

■ Case report 1

In July 2012, a 40-year-old man had traffic accident and presented with pain at right shoulder due to a displaced fracture of distal end of right clavicle (Neer type II) with no associated neurovascular deficit (Figure 1).

He was operated by open reduction and internal fixation using 6-hole hook plate with 4 screws into the medial fragment and a single screw into the lateral fragment (Figure 2).

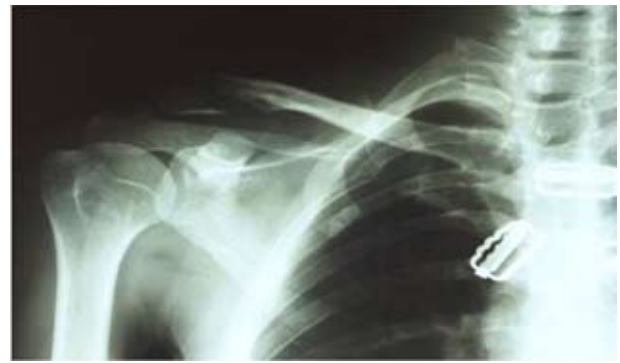

Figure 1. A radiograph showing a distal clavicular fracture (Neer type II).

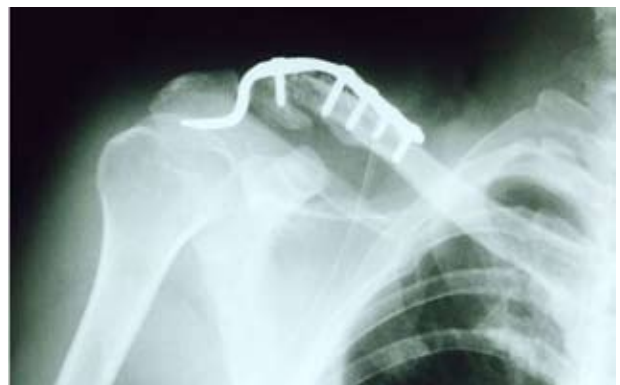

Figure 2. A postoperative radiograph presenting the distal clavicle which was fixed by using a 6-hole hook plate with 4 screws in the medial part and a single screw in the lateral part.

No intra-operative complications have been observed and the patient was instructed to perform pendulum exercises with limit shoulder movements. Four months after surgery, he had pain free during shoulder movements. Union of the distal end of clavicle fracture was revealed by radiographs. He then lost to follow up from orthopaedics department.

At 18 months after surgery, he had painful at right clavicle after traffic accident. He fell from motorcycle and landed on to his right shoulder directly. The radiograph showed a minimally displaced fracture at the medial end of plate and osteolysis over the acromial undersurface (Figure 3).

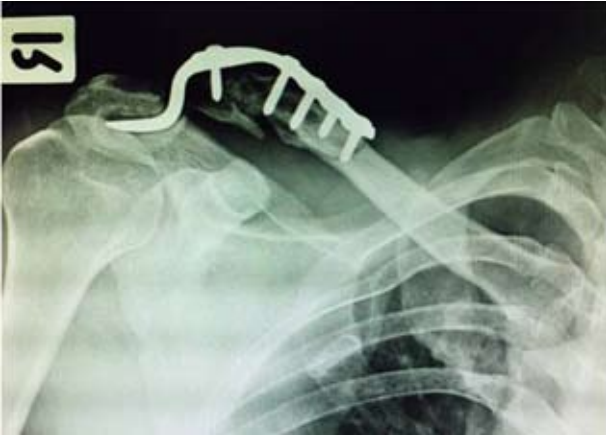

Figure 3. A radiograph showing the clavicle fracture at medial end of the hook plate after the motorcycle accident. Note osteolysis under the acromial surface.

The fracture reduction at distal clavicle was maintained. However, the fracture at medial end of plate was treated conservatively by immobilization in arm sling until no pain during shoulder motions. He, then, lost to follow up again.

A year after his second injury, he came to the orthopedic department due to medium velocity traffic accident. He presented with painful at right clavicle. The radiograph showed a fracture at the medial end of plate (Figure 4).

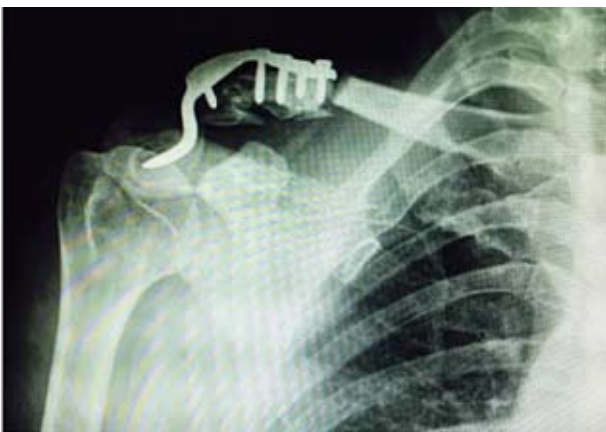

Figure 4. A radiograph demonstrating the clavicle fracture at medial end of the hook plate after the second injury.

This fracture was managed conservatively and healed eventually. The implant was removed and a broken of hook plate was observed in pre-operative radiograph (Figure 5).

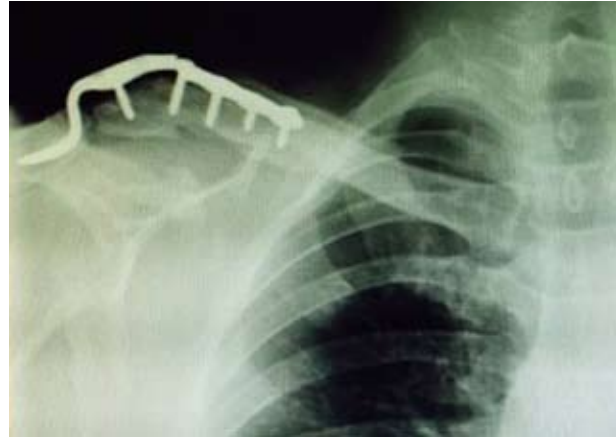


Figure 5. A radiograph after conservative treatment showing union of both distal clavicle fracture and clavicle fracture at medial end of the hook plate. The failure of implant hook plate was observed.

After the hook plate was removed (Figure 6), he had a full range of painless shoulder movements.

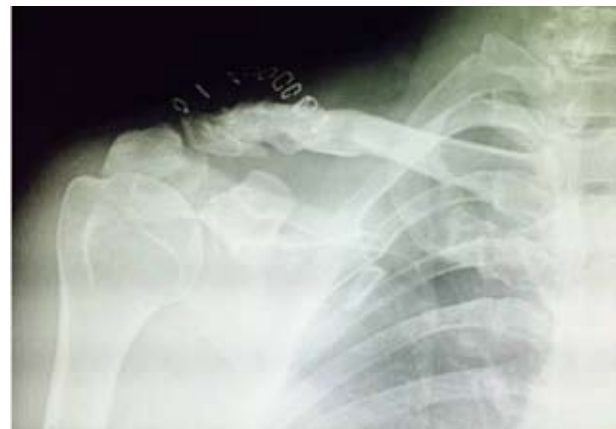

Figure 6. A radiograph after hook plate removal showing the union of both fracture sites (distal clavicle fracture and clavicle fracture at medial end of the hook plate).

■ Case report 2

In February 2015, a 47-year-old woman fell motorcycle and landed heavily on her right shoulder and arm. She had painful and could not move her right shoulder due to displaced right acromioclavicular joint (Rockwood type IV) (Figure 7) with no associated neurovascular deficit.

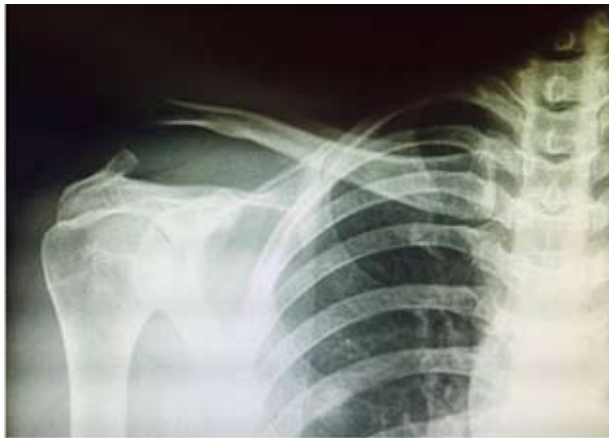

Figure 7. A radiograph showing acromioclavicular joint dislocation (Rockwood type IV).

She was operated by open reduction together with internal fixation using 5-hole hook plate with 4 screws into the clavicle (Figure 8).

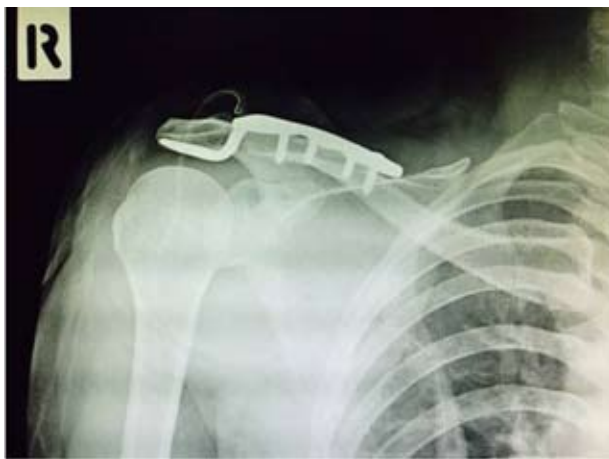

Figure 8. A postoperative radiograph demonstrating a reduction at acromioclavicular joint using a 5-hole hook plate.

In this case, no any treatment on soft tissue such as coracoclavicular ligament repair was performed. No intra-operative complications were observed. The patient was instructed to perform pendulum exercises with limit shoulder motions and heavy activities.

Two weeks after operation, she experienced pain at right clavicle after lying down on right shoulder. The radiograph showed a fracture at the medial end of plate (Figure 9).

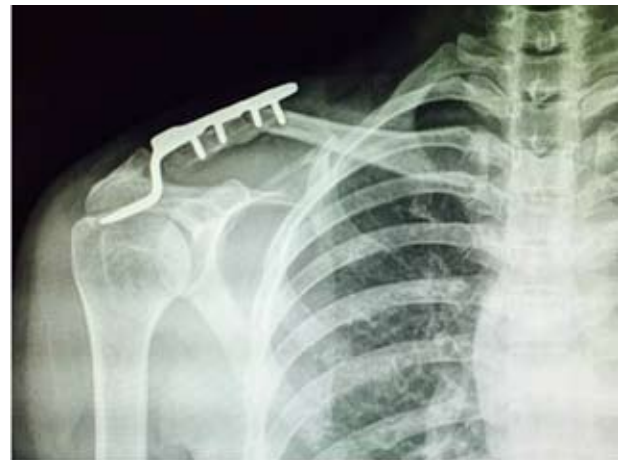

Figure 9. A radiograph revealing the clavicle fracture at medial end of the hook plate after injury.

Although the prominence of medial end of hook plate was observed, the acromioclavicular joint reduction was maintained. The right shoulder was immobilized by arm sling for 4 months. After that radiographs were performed and evidenced as union of the clavicle fracture. The hook plate was then removed. The patient had finally no complaint on pain during shoulder movements.

■ Discussion

There are many methods for fixation of displaced lateral clavicle fractures (Neer type II) and acromioclavicular joint dislocations. The clavicular hook plate is a popular device for internal fixation. Such plate is designed for placing on the superior surface of the clavicle with hook below the acromion locating posterior to the acromioclavicular joint. It provides a non-rigid fixation and maintains normal biomechanics of the acromioclavicular joint allowing some degree of early mobilization⁴. However, treatment using a hook plate is not a complication-free method. The main concern using the hook plate is subacromial impingement. Other described complications are diastasis of the acromioclavicular joint, recurrent dislocation of the acromioclavicular joint, failure fixation and disengagement of the plate⁴, osteolysis and fracture of the acromion⁵, as well as widening of the hook hole in the acromion¹.

Fracture of clavicle at the medial end of hook plate is a rare complication and few reports have been published⁶. It has been reported that there is a case of clavicular fracture at the medial end following a low energy fall as the complication of retaining the plate for more than 1 year². Moreover, clavicle fracture at the medial end of the implant 40 days after the operation without a second significant injury has also documented⁷. In most cases, the hook plates were removed and clavicular fractures were stabilized with plate system^{2,7}.

Our first case report, the clavicular hook plate had retained for 1 year before the secondary high energy injury. The second case, clavicle fracture occurred at the medial end of hook plate 2 week after the operation without a second significant injury. Both clavicular fractures were conservatively treated without surgery and the fracture healed eventually. The hook plates were then removed after bone union. The functional results were satisfactory. It could be possible that stress and motion at the acromioclavicular joint caused fracture at the medial end of the hook plate. The stress shielding effect of the implant on the underlying cortical bone exacerbated the osteoporosis. All fractures in this two case reports series here revealed that the fracture lines were initiated beneath the medial end of hook plate adjacent to medial screw. This location marked a weak point of the clavicle retained hook plate. Therefore, the clavicular hook plate should be removed at the 8th to 12th weeks after the operation before performing full shoulder activities⁸.

Some authors consider that once the fracture or ligament has healed, the removal of the hook plate is unnecessary⁹. From our experience the clavicular hook plate is recommended to remove routinely as early as possible before performing the full shoulder joint movements. All patients should be informed the risk of complications if this plate system is long-term retained.

■ Conclusion

The 2 case patients from this report demonstrates that a clavicle fracture at the medial end of the clavicular hook-plate is possible even without significant injury. Therefore, implant

removal is recommended as early as possible, and motion restriction should be emphasized until removal. All patients with this plate system should be informed the risk of this complication.

References

1. Kashii M, Inui H, Yamamoto K. Surgical treatment of distal clavicle fractures using the clavicular hook plate. *Clin Orthop Relat Res* 2006;447:158-64.
2. Nadarajah R, Mahaluxmivala J, Amin A, et al. Clavicular hook plate: complications of retaining the implant. *Injury* 2005;36:681-3.
3. Medical S-S. Manufacturer's guide: Clavicular hookplate. Synthes-Stratec Medical. Switzerland; 2003.
4. Charity RM, Haidar SG, Ghosh S, et al. Fixation failure of the clavicular hook plate: a report of three cases. *J Orthop Surg (Hong Kong)* 2006;14:333-5.
5. Chiang CL, Yang SW, Tsai MY, et al. Acromion osteolysis and fracture after hook plate fixation for acromioclavicular joint dislocation: A case report. *J Shoulder Elbow Surg* 2010;19:e13-5. doi:10.1016/j.jse.2009.12.005. Epub 2010 Mar 19.
6. Flinkkila T, Ristiniemi J, Hyvonen P, et al. Surgical treatment of unstable fractures of the distal clavicle: a comparative study of Kirschner wire and clavicular hook-plate fixation. *Acta Orthop Scand* 2002;73:50-3. doi:10.1080/000164702317281404.
7. Ding M, Ni J, Hu J, et al. Rare complication of clavicular hook plate: clavicle fracture at the medial end of the plate. *J Shoulder Elbow Surg* 2011;20:e18-20. doi:10.1016/j.jse.2011.06.005. Epub 2011 Aug 10.
8. Henkel T, Oetiker R, Hackenbruch W. Treatment of fresh Tossy III acromioclavicular joint dislocation by ligament suture and temporary fixation with the clavicular hooked plate. *Swiss Surg* 1997;3:160-6.
9. Faraj AA, Ketzer B. The use of a hook-plate in the management of acromioclavicular injuries. Report of ten cases. *Acta Orthop Belg* 2001;67:448-51.

รายงานผู้ป่วย ภาวะกระดูกไหปลาร้าหัก หลังการผ่าตัดใส่ Hook Plate

ฐิติณัฐ ดิลกหัตถการ¹ รณชิต บุญประเสริฐ¹ จตุรงค์ พรรตมณีนวงศ์²

¹ ภาควิชาออร์โธปิดิกส์ คณะแพทยศาสตร์ มหาวิทยาลัยศรีนครินทรวิโรฒ

² ภาควิชาออร์โธปิดิกส์ คณะแพทยศาสตร์ศิริราชพยาบาล มหาวิทยาลัยมหิดล

บทคัดย่อ

การผ่าตัดใส่ hook plate ที่กระดูกไหปลาร้าใช้ในการรักษาภาวะกระดูกไหปลาร้าส่วนปลายหักและเคลื่อนหรือข้อต่อโครมิโอคลาวิกิวลาร์เคลื่อน ปัจจุบันการใช้ hook plate ได้รับความนิยมมากขึ้นเนื่องจากวิธีการผ่าตัดไม่ซับซ้อนแต่เริ่มมีรายงานผู้ป่วยเกิดภาวะแทรกซ้อนหลังการผ่าตัดใส่ hook plate มากขึ้น เช่น ภาวะกระดูกไหปลาร้าหักบริเวณขอบ hook plate ด้านใน ขอบล่างของกระดูกโครเมียกร่อน ข้อต่อโครมิโอคลาวิกิวลาร์เคลื่อนซ้ำหลังการผ่าตัดใส่ hook plate เป็นต้น ซึ่งปัจจุบันภาวะแทรกซ้อนจากการผ่าตัดใส่ hook plate มีการรายงานในต่างประเทศเท่านั้น ยังไม่พบรายงานในประเทศไทยมาก่อน ผู้นิพนธ์จึงได้เสนอรายงานผู้ป่วย 2 รายที่ได้รับการผ่าตัดใส่ hook plate ที่บริเวณกระดูกไหปลาร้า ที่ศูนย์การแพทย์สมเด็จพระเทพรัตนราชสุดาฯ สยามบรมราชกุมารี คณะแพทยศาสตร์ มหาวิทยาลัยศรีนครินทรวิโรฒ จังหวัดนครนายก โดยผู้ป่วยรายแรกได้รับการผ่าตัดเนื่องจากมีภาวะกระดูกไหปลาร้าส่วนปลายหัก ส่วนผู้ป่วยรายที่สองมีภาวะข้อต่อโครมิโอคลาวิกิวลาร์เคลื่อน ผู้ป่วยทั้งสองรายเกิดจากอุบัติเหตุการจราจร หลังการผ่าตัดผู้ป่วยทั้งสองรายเกิดภาวะกระดูกไหปลาร้าหักบริเวณขอบ hook plate ด้านใน ซึ่งเป็นบริเวณรอยต่อระหว่างกระดูกส่วนที่ถูกยึดด้วย hook plate และสกรูกับส่วนเนื้อกระดูกปกติ ทำให้กระดูกไหปลาร้าบริเวณรอยต่อนี้มีความเครียดสูงขึ้นทำให้เกิดการหักได้ง่าย โดยผู้ป่วยรายแรกเกิดจากอุบัติเหตุการจราจรทำให้ไหล่ที่ได้รับการผ่าตัดกระดูกแตกพื้น ผู้ป่วยรายที่สองเกิดจากแรงกระทำที่ไม่รุนแรงจากการนอนตะแคงทับไหล่ที่ได้รับการผ่าตัด ผู้ป่วยทั้งสองรายได้รับการรักษาด้วยวิธีอนุรักษ์นิยมจนกระดูกไหปลาร้าติดดีแล้วจึงได้รับผ่าตัดนำ hook plate ออก หลังจากนั้นผู้ป่วยทั้งสองรายสามารถกลับไปใช้งานข้อไหล่ได้ดี และไม่มีอาการปวด

คำสำคัญ: ภาวะกระดูกไหปลาร้าหัก ภาวะแทรกซ้อน การผ่าตัดใส่ hook plate

ผู้นิพนธ์หลัก

ฐิติณัฐ ดิลกหัตถการ

ภาควิชาออร์โธปิดิกส์ คณะแพทยศาสตร์ มหาวิทยาลัยศรีนครินทรวิโรฒ

62 หมู่ 7 ถนนรังสิต-นครนายก ตำบลองครักษ์ จังหวัดนครนายก 26120

อีเมล: thitinutbank@gmail.com