

REVIEW ARTICLE



Bilateral supernumerary cusps on deciduous and permanent molars: A case report with a short review

K. B. Roopa, P. Poornima, Sidhant Pathak, I. E. Neena

Department of Pedodontics and Preventive Dentistry, College of Dental Sciences, Davangere, Karnataka, India

Correspondence:

Dr. K. B. Roopa, Department of Pedodontics and Preventive Dentistry, College of Dental Sciences, Davangere - 577 004, Karnataka, India. Phone: +91-9481688771. E-mail: roopakorishettar@gmail.com

Received 21 January 2015

Accepted 27 February 2015

doi: 10.15713/ins.ijcdmr. 50

How to cite the article:

K. B. Roopa, P. Poornima, Sidhant Pathak, I. E. Neena, "Bilateral supernumerary cusps on deciduous and permanent molars: A case report with a short review," Int J Contemp Dent Med Rev, vol. 2015, Article ID: 300115, 2015. doi: 10.15713/ins.ijcdmr. 50

Abstract

Extra cusps or the central cusps have been recognized as supernumerary cusps by many authors. Extra cusps are usually seen on premolars. Central cusps are of clinical importance as it could be associated with some anomalies that can lead to clinical complications. Extra or accessory cusps rarely pose any problem to the dentist. Even though, it may not cause an emergency in the clinic fracture of this cusp may lead to clinical problems. We present this rare case with bilateral central cusps both on permanent and deciduous molars. Review regarding central cusp, need for continuous follow-up are also been included.

Keywords: Deciduous molar, occlusal surface, permanent molar, supernumerary cusp

Introduction

Pathological conditions and developmental disturbances are the second most frequently affecting clinical problems. Expression of odontogenic genes is the important source of morphological change in individual teeth and dentition. Various signaling factors are produced by transcription factors that are encoded by these genes.^[1] Cell differentiation cell death and multiplications are the odontogenic tissue layer inductive interactions brought by these signaling factors.^[2] Mutation in developmentally regulated genes will cause the congenital malformation of teeth in humans.^[3] Gene mutation act at different levels of tooth formation, i.e., development of the embryonic bud stage bell stage, production of enamel and dentin formation or the root formation. Each tooth formation and cusp formation is under the control of specific genes. Same set will work for all cusps. Crown pattern is determined by the reaction diffusion mechanism that is controlled by genes.^[4] Extra cusps situated between lingual and buccal cusp tips on the occlusal surface of molars, pre molars and on the lingual surface of canine and incisors are called as central cusps. Variations in dentitions such as morphological changes in the structure can be seen in both primary and deciduous dentition. Changes in the structure could be appreciated in the form of cusp or increased number of roots or both.^[5] Extra cusps are rarely seen clinically which is one of the

common variations. Incidence of extra cusp depends on type and tooth affected. Carabelli cusps, talons cusp of incisors and Leong's tubercle of the premolar are the commonly reported variation seen both in primary and permanent dentition.^[6] Around 1-7% of talons cusp cases are been reported, 52% according to Curzon *et al.*, 1970; Chawla *et al.*, 1983; Shay, 1984. According to Kannapan and Swaminathan, 2001; Mavrodisz *et al.*, 2007 68% of carabelli cusps and according to Segura-Egea *et al.*, 2003 8% of Leong's tubercle are seen. Gene expression is the key for development and shape of the teeth. Future site of the cusps is determined by enamel knots.^[7] Enamel knot is responsible for the induction of the dental papilla. Primary knot is seen at late bud stage and increase in size till cap stage of tooth development.^[8] Primary enamel knot regulates cuspal morphogenesis with the release of various molecules such as fibroblast growth factors 4 and 9, transforming growth factor- β and bone morphogenic proteins 2, 4 and 7.^[9] These molecules causes the initiation of secondary enamel knots that mark the cusp formation at early bell stage.^[10] The accessory cusps on the occlusal surface of permanent molars are the variations of teeth that are rarely seen clinically. However, sporadically some abnormal shape projections may occur from time to time without any clear etiology. The purpose of this report is to highlight an incidental clinical finding of bilateral accessory central cusp of the first maxillary permanent molars and deciduous second molar.

Case Report

An 11-year-old male reported to the Department of Pedodontics and Preventive dentistry, College of Dental Sciences, Davangere, Karnataka, India with the chief complaint of forwardly placed anterior teeth. The medical and past dental histories were non-contributory. On intraoral examination, no abnormalities of soft tissues were found. The patient was in the mixed dentition period with good oral hygiene. A detailed dental evaluation was carried out, and it was noted that the patient had the maxillary anterior protruded. Maxillary right first primary molar had internal resorption. In addition to the above findings, a large central projection of a cusp was seen on the occlusal surface of the left and right maxillary first permanent molars [Figure 1]. The projection was 3 mm × 3 mm in size with a rhomboid base and was present at the center of the oblique ridge. The tip of the extra cusp lies one mm above the level of the other cusps of the teeth [Figure 2]. The presence of a similar cusp was observed on both right and left primary second molar, it was more of the

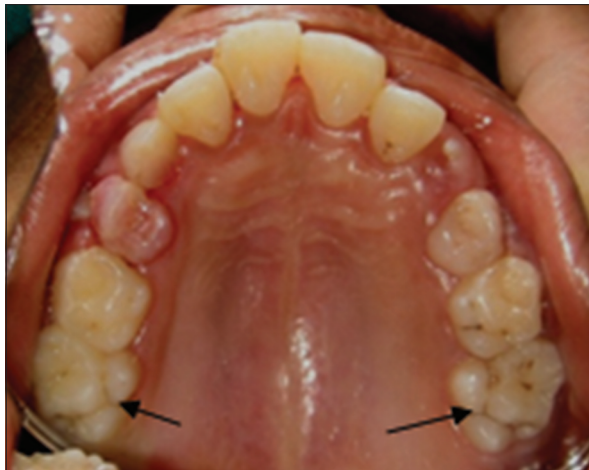


Figure 1: Bilateral supernumerary cusps on first maxillary molars

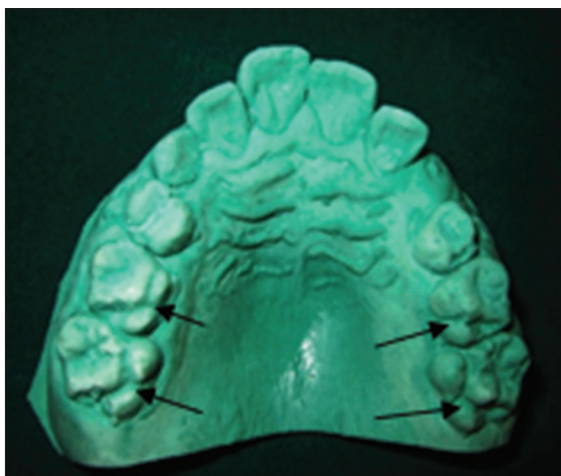


Figure 2: Central cusps above the occlusal level

bulge over the occlusal ridge and resembled a cusp [Figure 3]. The corresponding primary molar and permanent first molar of the mandibular arch did not exhibit any depression on the occlusal surface. Radiographic examination revealed no pulpal extension into the central cusp [Figure 4]. Grooves surrounding the accessory central cusps did not show any evidence of caries. The patient was advised for extraction of maxillary right primary first molar. Preventive measures such as oral hygiene and fluoride applications were instituted. Patient and parent were informed about the extra cusp and complications associated with it and advised for regular follow-up.

Discussion

Presence of multiple supernumerary cusps is a very rare entity. Anomalies are said to be the deviations from the normal structure, number, color, contour, size and degree of development of teeth. Developmental anomalies could be the results of systemic as well as local disturbances, thus influencing both deciduous and permanent dentition. Developmental disturbance regarding shape includes dens invaginatus, dens evaginatus, germination, fusion, and taons cusp.^[11] Extra cusp that appears like horn like projection on the affected surface of the crown is said to be dens evaginatus.^[12] Extra cusp is a rare entity mainly seen on premolars but can be associated with molars, canines and incisors. Extra cusp arises from cingulum area in incisors and canines where as in pre molars and molars it is observed on the

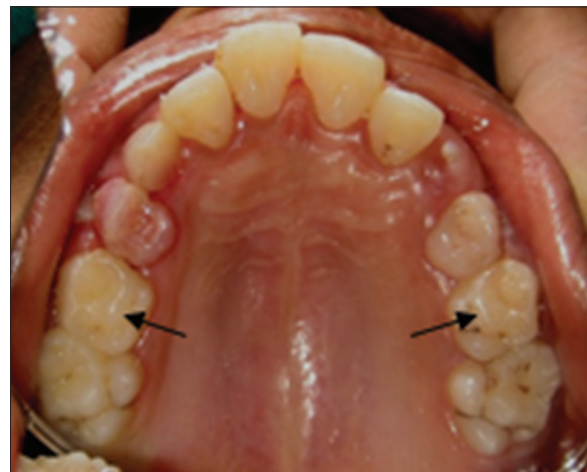

Figure 3: Supernumerary cusps on deciduous second molar

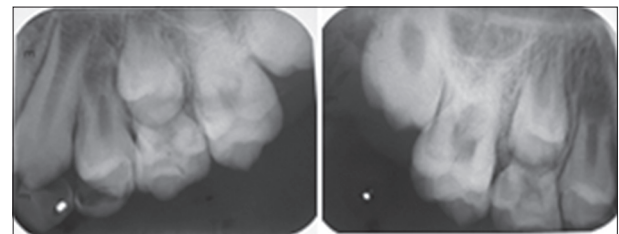


Figure 4: Radiographs of right and left molars

occlusal surface.^[11] Dens evaginatus composed of enamel and dentin enclosing pulp, appears clinically as occlusal tuberculated cusp. Common clinical consequence would be pulp exposure leading to pulpal inflammation necrosis and inflammation of periapical tissue due to wearing of the tubercle or fracture. If this happens in immature tooth diagnosis will be complicated. Treatment is also difficult due to immaturity.^[13] Both talons and central cusps are referred as dens evaginatus. Central cusp and talon cusp both are referred to as dens evaginatus.^[14]

According to Schulge dens evaginatus could be classified depending on location:^[15]

- A cone-like enlargement of the lingual cusp
- A tubercle on the inclined plane of the lingual cusp
- A cone-like enlargement of the buccal cusp
- A tubercle on the inclined plane of the buccal cusp
- A tubercle arising from the occlusal surface obliterating the central groove.^[16]

This anomaly, an enamel-covered tubercle on the occlusal surface between the buccal and lingual cusps of posterior teeth, can occur unilaterally or bilaterally. It occurs primarily in premolars, but also has been reported rarely on molars, canines, and incisors. The occurrence is five times more frequent in the mandible than in the maxilla.^[13] In our case, bilateral central cusps were seen both on primary and permanent maxillary molars. The occurrence of multiple central cusps is a rare entity and in our case, both deciduous and permanent molar had central cusp. Most common problem with this extra cusp in the occlusal interference when the tooth comes in contact with the opposing tooth. In our case, even though cusp was centrally placed, and there was no interference with opposing the tooth in occlusion or with lateral extrusion. The clinical importance of this condition is that this tubercle easily fracture or is worn away, exposing the fine pulpal extension, which may lead to infection. The patient and parents were informed about the potential problems with the extra cusp and need for regular monitoring was emphasized in our case. Preventive measures based on the depth of the fissures around the tubercle should be considered. When the fissures around the tubercle are deep, application of sealants could be done. In our case fissures were not deep so, fluoride application was done. Most of the literature is about talons cusp, and there are only few reports of central cusp. The occurrence of the multiple central cusp is a very rare entity, and literature is very sparse. Developmental anomalies of the teeth are clinically evident abnormalities. They may be the cause of various dental problems.^[11] The cusp-like anomalies itself does no harm to the patient. Recognizing this anomaly is not a problem when the affected tooth has just erupted while not in occlusion. Parents or guardians should be informed

about potential complications of this anomaly.^[13] Careful observation and appropriate investigations are required to diagnose the condition and institute appropriate treatment.^[11]

References

1. Thesleff I, Vaahtokari A, Partanen AM. Regulation of organogenesis. Common molecular mechanisms regulating the development of teeth and other organs. *Int J Dev Biol* 1995;39:35-50.
2. Matalova E, Tucker AS, Sharpe PT. Death in the life of a tooth. *J Dent Res* 2004;83:11-6.
3. Smith MM, Coates MI. Evolutionary origins of the vertebrate dentition: Phylogenetic patterns and developmental evolution. *Eur J Oral Sci* 1998;106 Suppl 1:482-500.
4. Koussoulakou DS, Margaritis LH, Koussoulakos SL. A curriculum vitae of teeth: Evolution, generation, regeneration. *Int J Biol Sci* 2009;5:226-43.
5. Kallay J. Extra cusp formation in the human dentition. *J Dent Res* 1966;45:1381-94.
6. Ooshima T, Ishida R, Mishima K, Sobue S. The prevalence of developmental anomalies of teeth and their association with tooth size in the primary and permanent dentitions of 1650 Japanese children. *Int J Paediatr Dent* 1996;6:87-94.
7. Hunter JP, Guatelli-Steinberg D, Weston TC, Durner R, Betsinger TK. Model of tooth morphogenesis predicts carabelli cusp expression, size, and symmetry in humans. *PLoS One* 2010;5:e11844.
8. Hargreaves K, Goodis H, editors. Seltzer and Bender's Dental Pulp. 1st ed. Chicago: Quintessence Publishing; 2002. p. 13-7.
9. Thesleff I, Keränen S, Jernvall J. Enamel knots as signaling centers linking tooth morphogenesis and odontoblast differentiation. *Adv Dent Res* 2001;15:14-8.
10. Thesleff I. Epithelial-mesenchymal signalling regulating tooth morphogenesis. *J Cell Sci* 2003;116:1647-8.
11. Guttal KS, Naikmasur VG, Bhargava P, Bathi RJ. Frequency of developmental dental anomalies in the Indian population. *Eur J Dent* 2010;4:263-9.
12. Vasudev SK, Goel BR. Endodontic management of dens evaginatus of maxillary central incisors: A rare case report. *J Endod* 2005;31:67-70.
13. Echeverri EA, Wang MM, Chavaria C, Taylor DL. Multiple dens evaginatus: Diagnosis, management, and complications: Case report. *Pediatr Dent* 1994;16:314-7.
14. Yip WK. The prevalence of dens evaginatus. *Oral Surg Oral Med Oral Pathol* 1974;38:80-7.
15. Scott GR, Turner CG II. The Anthropology of Modern Human Teeth: Dental Morphology and its Variation in Recent Human Populations. Cambridge: Cambridge University Press; 1997. p. 35-7.
16. Nirmala SV, Challa R, Velpula L, Nuvvula S. Unusual occurrence of accessory central cusp in the maxillary second primary molar. *Contemp Clin Dent* 2011;2:127-30.