



RESEARCH BRIEF



Diagnostic accuracy of cone-beam computed tomography using different voxel sizes versus digital intraoral radiography in detection of vertical root fractures of teeth with metallic post

Islam Shawky Mohamed Shaker¹, Nashwa S. Mohamed², Ahmed M. Abdelsamad²¹Department of Oral Radiology, Faculty of Dentistry, Misr International University, Cairo, Egypt, ²Department of Oral Radiology, Faculty of Dentistry, Cairo University, Egypt**Correspondence**Islam Shawky Mohamed Shaker, KM 28 Cairo – Ismailia Road Ahmed Orabi District, Cairo, Egypt. Tel.: +201001781106. E-mail: isl_shawky@hotmail.com

Received: 30 October 2016

Accepted: 17 December 2016

doi: 10.15713/ins.ijcdmr.124

How to cite this article:

Islam Shawky Mohamed Shaker, Nashwa S. Mohamed, Ahmed M. Abdelsamad, "Diagnostic accuracy of cone-beam computed tomography using different voxel sizes versus digital intraoral radiography in detection of vertical root fractures of teeth with metallic post," Int J Contemp Dent Med Rev, vol. 2017, Article ID: 031217, 2017. doi: 10.15713/ins.ijcdmr.124

Abstract

Background: Conventional radiographs are not an efficient diagnostic method to detect vertical root fracture (VRF). Cone-beam computed tomography (CBCT) overcomes the limitations of conventional radiography in the detection of VRF. In CBCT, metallic structures can cause artifacts in the images. **Aim:** This study aimed to determine the diagnostic accuracy of CBCT using different voxels in the detection of VRFs of teeth with metallic posts compared to digital intraoral radiography. **Materials and Methods:** A total of 120 single-rooted extracted human teeth were obtained and endodontically treated, then placed in an acrylic block and metallic posts were inserted. After post insertion, the teeth roots were divided into two groups one with induced VRFs and the other having intact roots with the posts inserted. Then, each tooth was coded and imaged 3 times using CBCT and digital periapical radiography (DPR). **Results:** DPR showed statistically significantly lower diagnostic accuracy than CBCT, and changing the voxel did not improve the diagnostic accuracy. **Conclusion:** In case of suspicious VRFs, CBCT is recommended to detect the presence of fractures. **Clinical Significance:** Since most teeth suspected to have VRFs are endodontically treated and have a metallic post in the root canal, fracture detection may pose a challenge CBCT resolves this issue.

Keywords: Cone-beam computed tomography in vertical root fractures, vertical root fractures cone-beam computed tomography, vertical root fractures detection, vertical root fractures periapical radiography

Introduction

The condition referred to as vertical root fracture (VRF) is a fracture that extends longitudinally from the root apex to the tooth's crown, according to the American Association of Endodontists.^[1]

The etiology of VRFs is mainly iatrogenic, usually owing to excessive canal shaping, excessive pressure during gutta-percha compaction, or excessive pressure during post-placement.^[2]

On radiographic images, the fracture can be seen as a radiolucent line between the fragments along with a discontinuity of the periodontal ligament shadow.^[3]

Cone-beam computed tomography (CBCT) has been used for proper diagnosis of root fractures to overcome the inherent disadvantages of anatomic superimposition. CBCT has allowed dental practitioners to visualize teeth three-dimensionally and with high spatial resolution.^[4]

While recent studies have demonstrated the superiority of CBCT in detecting root fractures, there are some limitations to proper imaging when high-density materials such as gutta-percha and intracanal metal posts are present. These materials may create artifacts that impair the quality of CBCT images. Beam hardening and streak artifacts can be superimposed on the root, creating difficulties for image assessment and may even mimic root fractures.^[5,6]

Materials and Methods**Study design**

This study was planned to assess the accuracy of CBCT versus intraoral digital periapical radiography (DPR) in the detection of root fractures of teeth with the metallic post.

Our study is a cross-sectional prospective (data collection was planned before the index test and reference standard test were performed) study with a blind comparison to a gold standard.

Teeth selection, preparation, and grouping

Teeth selection

A total of 120 single-rooted extracted human teeth were obtained from the Oral Surgery Department in the outpatient clinic in Misr International University.

Selection of the teeth was based on fulfilling the eligibility criteria which were:

1. Maxillary or mandibular single-rooted teeth.
2. Absence of root fracture on clinical examination.

Teeth preparation and grouping

All teeth included in our study were endodontically treated, then the gutta-percha in the cervical part of the root was removed



Figure 1: Endodontically treated teeth with the root covered by wax



Figure 2: A rectangular acrylic block with eight holes in each block to support the teeth

using Gates Glidden drills. The roots of teeth were covered by wax [Figure 1].

A rectangular acrylic block was prepared in a rectangular plastic box with sufficient height to hold teeth in a position simulating patient radiographic imaging. Then, eight holes were made in each block to support the teeth included in the study [Figure 2].

Each eight teeth were embedded in each acrylic block with their palatal surfaces directed outside toward the block borders.

The canals were prepared using standardized drills and the final standardized metallic posts were inserted [Figure 3].

After post insertion, the teeth roots were divided equally and randomly into 2 groups:

- In Group 1
Induced VRFs were created by applying excessive forces to the roots through excessive rotation of posts with larger sizes [Figure 4].
- In Group 2
The teeth having intact roots with the posts inserted.

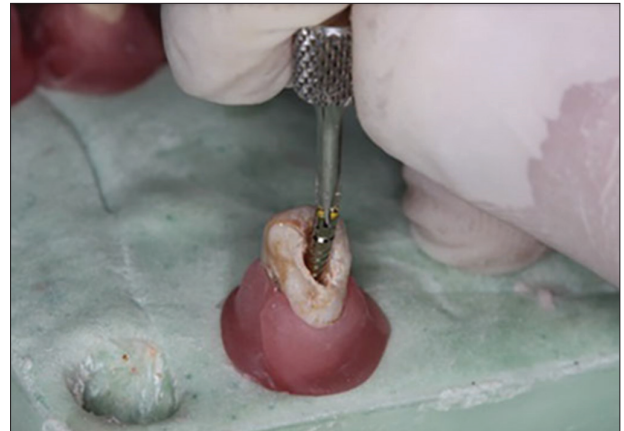

Figure 3: Final standardized metallic posts were inserted

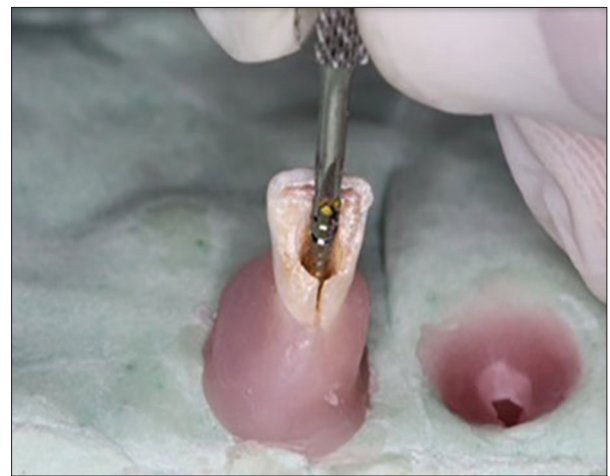


Figure 4: Induced vertical root fractures through excessive rotation of posts with larger sizes

Imaging of teeth

Each tooth was coded by special code (known only by the researcher) and placed randomly in acrylic blocks to be imaged 3 times as follows:

I-direct DPR

Using digital intraoral radiography, the exposure was made with an image for each two teeth using an intraoral X-ray machine (X-mind, Acteon, Satelec, France) with paralleling technique using a paralleling device and an intraoral imaging plate size 2 of the digital system (Vistascan Durr Dental, Germany).

The following exposure parameters, 70 kVp and 8 mA, were used. The images were evaluated using software (DBSWIN) to detect root fracture [Figure 5].

CBCT with standard resolution

Each block was sectioned into two halves each containing four teeth to be adjusted to the CBCT field of view.

The teeth were imaged using CBCT machine (Scanora3D, Soredex, Finland) after adjusting the control panel for image capturing with parameters adjusted at KVp = 90 mA = 10 voxel size = 133 μ m FOV = 5 cm \times 5 cm and exposure time = 6.1 s.

CBCT with high resolution

The exposure parameters used were the same as the first protocol but with different voxel size (voxel size of 85 μ m).

All CBCT images were analyzed using software (on demand 3D) viewer in axial, coronal, sagittal, and 3D views to detect the presence or absence of root fracture [Figure 6].

The outcome was binary for the presence or absence of fracture lines.

Blinding

The images were evaluated by two radiologists with an experience ranging from 10 to 25 years for the presence or absence of root fractures.

Two radiologists were blinded during periapical radiographs and CBCT image assessment as tooth preparation and coding

was done by a third researcher. Moreover, the statistician was blinded.

Statistical analysis

Data were presented as frequencies and percentages. Receiver operating characteristic (ROC) curve was constructed to evaluate diagnostic accuracy measures of the different modalities. Areas under the ROC curve (AUC) of the four modalities were compared using z-statistic. Sensitivity, specificity, positive, negative predictive values, and diagnostic accuracy measures were calculated.

The significance level was set at $P \leq 0.05$. ROC curve analysis was performed with MedCalc Version 11.3 for Windows (MedCalc Software bvba).

Results

Frequencies and percentages of fracture detection by different modalities are presented in Table 1.

The highest sensitivity was found with CBCT1 (CBCT with standard resolution) (66.7%) followed by CBCT2 (CBCT with high resolution) (65%). The lowest sensitivity was found with DPR (30%) [Table 2].

CBCT1, CBCT2, and DPR showed lower and equal specificity values (86.7%) [Table 2].

The highest positive predictive value was found with CBCT1 (83.3%) followed by CBCT2 (83%). The lowest positive predictive value was found with DPR (69.2%) [Table 2].

The highest negative predictive value was found with CBCT1 (72.2%) followed by CBCT2 (71.2%). The lowest negative predictive value was found with DPR (55.3%) [Table 2].

Pair-wise comparison between AUC the ROC for different modalities revealed that DPR showed statistically significantly lower diagnostic accuracy than CBCT1 and CBCT2 ($P \leq 0.05$) [Table 2].

ROC curve analysis revealed that the highest diagnostic accuracy was found with CBCT1 (76.7%) followed by CBCT2 (75.9%). The lowest diagnostic accuracy was found with DPR (58.4%) [Table 2].

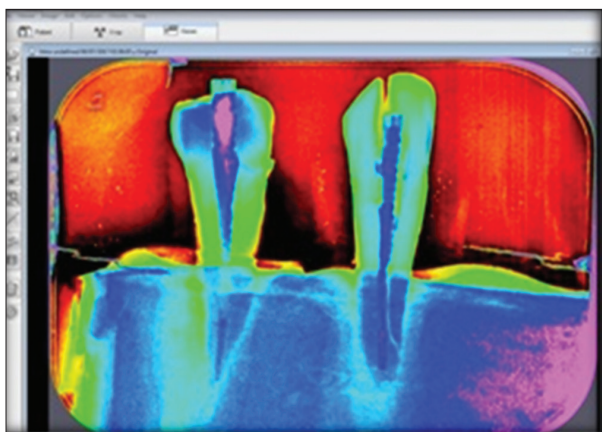


Figure 5: DBSWIN Software

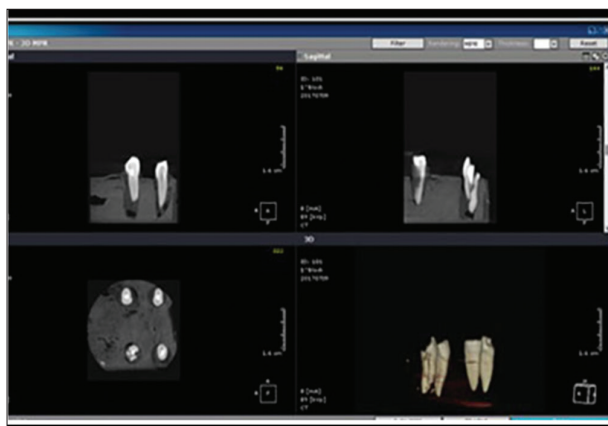


Figure 6: On demand 3D Software

Table 1: Frequencies (n) and percentages (%) for fracture detection by different modalities

Parameter	Standard n=120 (%)	Digital n=120 (%)	CBCT1 n=120 (%)	CBCT2 n=120 (%)
Fracture	60 (50.0)	26 (21.7)	48 (40.0)	47 (39.2)
Sound	60 (50.0)	94 (78.3)	72 (60.0)	73 (60.8)

Table 2: Sensitivity, specificity, predictive values, diagnostic accuracy, area under the ROC curve (AUC), and 95% confidence interval (95% CI) for the detection of fracture by different modalities

Modality	Sensitivity %	Specificity %	+PV %	-PV %	Diagnostic accuracy %	AUC	95% CI
DPR periapical radiography	30.0	86.7	69.2	55.3	58.4	0.583	0.490-0.673
CBCT1	66.7	86.7	83.3	72.2	76.7	0.767	0.681-0.839
CBCT2	65.0	86.7	83.0	71.2	75.9	0.758	0.672-0.832

+PV: Positive predictive value, -PV: Negative predictive value, AUC: Areas under the curve, ROC: Receiver operating characteristic

Table 3: Results of z-test for pair-wise comparisons between AUC of CBCT1 and CBCT2

Modalities	Z-statistic	P value
CBCT1 versus CBCT2	0.912	0.362

*Significant at $P \leq 0.05$, AUC: Areas under the curve

Changing the voxel size from 133 μm (CBCT1) to 85 μm (CBCT2) did not improve (lowered) the diagnostic accuracy from CBCT1 (76.7%) to CBCT2 (75.9%) but with no statistically significant difference [Table 3].

Discussion

Accurate diagnosis of VRF depends on a careful clinical examination, complete evaluation of the case, and on an imaging examination which assesses the integrity of the bone and of the dental structure.^[7,8]

Intraoral digital systems use lower radiation doses than conventional system, in addition to offering other advantages such as the opportunity for image enhancement and storage. Therefore, when performing radiographic examinations for the initial investigation of root fractures, it is appropriate to use this imaging method.^[9,10]

Da Silveira *et al.* 2013^[11] confirmed the superiority of CBCT over periapical radiography in detecting VRF and found that CBCT shows better results depending on the voxel used.

Detection of VRF is not only influenced by the type of imaging examination either conventional radiography or CBCT but also by the presence of material in the root canal, such as MPs, filling material, or remaining restorative material. Hence, in our study, we used CBCT with different voxel sizes compared to digitally enhanced periapical radiographs to detect VRF in the presence of metallic posts.

Teeth roots were covered by wax to simulate soft tissue.

Only single-rooted teeth included in the study to avoid the superimposition of other endodontically treated roots.

Paralleling technique was used in periapical radiography to adjust the beam direction perpendicular to the tooth surface using paralleling film holder and teeth were placed in the acrylic blocks with their buccal surface directed toward the beam to simulate clinical condition.

Induced VRFs were created by applying excessive forces to the roots through excessive rotation of posts to try to mimic the shape of fracture line in a clinical situation.

Our results showed that the highest diagnostic accuracy was found with CBCT1 (76.7%) followed by CBCT2 (75.9%). The lowest diagnostic accuracy was found with digital periapical radiograph (58.4%).

Digital periapical radiograph showed statistically significantly lower diagnostic accuracy than CBCT1 and CBCT2. This result is in agreement with the results of Varshosaz *et al.* 2010^[1] and Hassan *et al.* 2009.^[12]

In accordance with Varshosaz *et al.* 2010^[1] and Da Silveira *et al.* 2013,^[11] the results showed the reduced sensitivity of periapical radiography than CBCT in the presence of metallic post.

This can be attributed to that fracture line in mesiodistal direction is difficult to detect on periapical radiographs where the fracture line in radiographs is visible when the path of the x-ray is parallel to the plane of fracture, and otherwise, the fracture will not be visible on two-dimensional radiographs, especially in the primary stages when the fracture is a tender crack without detached fragments in addition to that superimposition of other structures is also a factor that limits the sensitivity of periapical radiography for diagnosis.

Regarding changing the voxel size from 133 μm (CBCT1) to 85 μm (CBCT2), this did not improve (lowered) the diagnostic accuracy from CBCT1 (76.7%) to CBCT2 (75.9%) but with no statistically significant difference.

These results are in line with Da Silveira *et al.* 2013^[12] who reported that different voxel sizes have no statistically significant difference in accuracy of detection of VRFs.

Conclusion

1. In case of clinical suspicious of VRF with negative findings on two-dimensional radiographic examination, CBCT is the imaging modality of choice to confirm the presence or absence of fractures.
2. Using voxel size of 133 μm is sufficient to accurately detect VRF.

References

1. Varshosaz M, Tavakoli MA, Mostafavi M, Baghban AA. Comparison of conventional radiography with cone beam computed tomography for detection of vertical root fractures: an *in vitro* study. *J Oral Sci* 2010;52:593-7.
2. Cohen S, Berman LH, Blanco L, Bakland L, Kim JS. Ademographic analysis of vertical root fractures. *J Endod* 2006;32:1160-3.
3. Wenzel A, Haiter-Neto F, Frydenberg M, Kirkevang LL. Variable-resolution cone-beam computerized tomography with enhancement filtration compared with intraoral photostimulable phosphor radiography in detection of transverse root fractures in an *in vitro* model. *Oral Surg Oral Med Oral Pathol Oral Radiol Endod* 2009;108:939-45.
4. Long H, Zhou Y, Ye N, Liao L, Jian F, Wang Y, *et al.* Diagnostic accuracy of CBCT tooth fractures: A meta-analysis. *J Dent* 2014;42:240-8.
5. Brady E, Mannocci F, Brown J, Wilson R, Patel S. A comparison of cone beam computed tomography and periapical radiography for the detection of vertical root fractures in nonendodontically treated teeth. *Int Endod J* 2014;47:735-46.
6. Moudi E, Haghanifar S, Madani Z, Alhavaz A, Bijani A, Bagheri M. Assessment of vertical root fracture using cone-beam computed tomography. *Imaging Sci Dent* 2014;44:37-41.
7. Bechara B, McMahan CA, Nasseh I, Geha H, Hayek E, Khawam G. Number of basis images effect on detection of root fractures in endodontically treated teeth using a cone beam computed tomography machine: An *in vitro* study. *Oral Surg Oral Med Oral Pathol Oral Radiol* 2013;115:676-81.
8. Tang L, Zhou XD, Wang Y, Zhang L, Zheng QH, Huang DM. Detection of vertical root fracture using cone beam computed tomography: Report of two cases. *Dent Traumatol* 2011;27:484-8.
9. Bechara B, Moore WS, McMahan CA, Noujeim M. Metal artefact reduction with cone beam CT: An *in vitro* study. *Dentomaxillofac Radiol* 2012;41:248-53.
10. Bezerra IS, Neves FS, Vasconcelos TV, Ambrosano GM, Freitas DQ. Influence of the artefact reduction algorithm of Picasso Trio CBCT system on the diagnosis of vertical root fractures in teeth with metal posts. *Dento Maxillofac Radiol* 2015;44:20140428.
11. da Silveira PF, Vizzotto MB, Liedke GS, da Silveira HL, Montagner F, da Silveira HE, *et al.* Detection of vertical root fractures by conventional radiographic examination and cone beam computed tomography - An *in vitro* analysis. *Dent Traumatol* 2013;29:41-6.
12. Hassan B, Metska ME, Ozok AR, Stelt PV, Wesselink PR. Detection of vertical root fractures in endodontically treated teeth by a cone beam computed tomography scan. *J Endod* 2009;35:719-22.

This work is licensed under a Creative Commons Attribution 4.0 International License. The images or other third party material in this article are included in the article's Creative Commons license, unless indicated otherwise in the credit line; if the material is not included under the Creative Commons license, users will need to obtain permission from the license holder to reproduce the material. To view a copy of this license, visit <http://creativecommons.org/licenses/by/4.0/> © Shaker ISM, Mohamed NS, Abdelsamad AM. 2017