

REVIEW ARTICLE



Botox and derma fillers: The twin-face of cosmetic dentistry

Aditya Sinha¹, Megha Hurakadli², Pramod Yadav³

¹Department of Periodontics, K.D Dental College and Hospital, Mathura, Uttar Pradesh, India, ²Department of Oral and Maxillofacial Surgery, Medlife Foundation, Ahmedabad, Gujarat, India, ³Department of Public Health Dentistry, K.D Dental College and Hospital, Mathura, Uttar Pradesh, India

Correspondence

Dr. Megha Hurakadli,
Department of Oral and Maxillofacial Surgery,
Medlife Foundation, Ahmedabad, Gujarat,
India.
Email: Megha.h12@gmail.com

Received 29 December 2014;

Accepted 30 January 2015

doi: 10.15713/ins.ijcdmr.27

How to cite the article:

Aditya Sinha, Megha Hurakadli, Pramod
Yadav, "Botox and derma fillers: The twin face
of cosmetic dentistry," Int J Contemp Dent
Med Rev, vol. 2015,
Article ID 131214, 2015.
doi: 10.15713/ins.ijcdmr.27

Abstract

In recent years, botulinum toxin and derma fillers have made their way into dentistry for both dental esthetic and therapeutic uses. They are here to stay and with more and more intra oral uses of these materials, they are fast becoming an integral part of everyday dental practice. They provide most significant, minimally invasive procedure at low cost with limited to no recovery time. Today botox and derma fillers both go hand in hand for rejuvenative and cosmetic procedures. This article focuses on the mechanism of action and various uses of botox and derma fillers in the maxillofacial areas along with its future implications in the dentistry.

Keywords: Botulinum toxin, dental esthetic, derma fillers

Introduction

People face variety of dental issues during their life few of which includes stained, separated carious teeth along with various degree of irregular gum problems. This could act as a major downside in one's look. An excellent smile can often be spoiled by irregular gum levels or excess gum. The cosmetic dentists will play a positive role in rectifying one's gum connected problem and enhance the charm of one's smile.

The gum is that part of the mouth which will have an effect on one's smile both health wise and cosmetically. If someone suffers from receding gums, his teeth seem longer and therefore the person appears older than he really is. Irregular gums can turn childlike smile into a criminal one. Use of botulinum toxin A (BTX) and dermal fillers are gaining popularity for the treatment of irregular gums.

The popularity of each, BTX and dermal fillers has matured quickly in recent years as a result of they provide the rejuvenative and enhancing aesthetic enhancements antecedently solely do able with surgery, however at lower value and with limited-to-no recovery time.

The use of neurotoxin and dermal fillers is one in all the quickest growing areas of medical specialty. Esthetic results delivered in terms of smoothing wrinkles and commutation lost

volume within the face, particularly the oral and peri-oral areas are very well known.

Botox in Dental Practice

BTX is a neurotoxin produced by the bacterium *Clostridium botulinum*. BTX that leads to botulism, a serious life-threatening illness in humans and animals that can even cause morbidity. Three forms of BTX type A (botox, dysport and xeomin) and one form of BTX type B (MyoBloc) are available commercially for various cosmetic and medical procedures.^[1] BTX are being frequently used for dental esthetics, therapeutics along with treatment of temporomandibular joint syndrome and facial pain in faciomaxillary areas.

Mechanism of Action of Botulinum

The release of acetyl choline at the neuromuscular junction is inhibited by the toxin hence there is reduced intensity of contraction or complete elimination of overall contraction of the muscle, depending on the amount of toxin used [Figure 1]. Essentially, the neurotoxin interrupts the contraction process of the muscles and causes temporary muscle paralysis. This

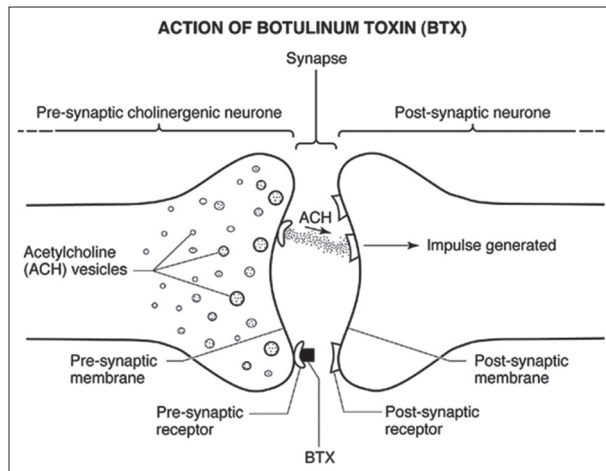


Figure 1: Botulinium toxin blocks pre synaptic receptor and prevents release of acetylcholine

can usually last up to 3 months as the muscle initiates new acetylcholine receptors and the growth of branches from the neurons to form new synaptic contacts. Slowly and steadily the muscle returns to its full function and with no side-effects.^[1]

Botox Dental Therapeutic Uses

1. Temporomandibular disorders (TMD) cases
2. Bruxism and clenching cases
3. Facial pain cases including treating trigger points
4. Treatment of angular cheilitis
5. Gummy smiles
6. Orthodontic relapse and depressed orthodontic appearance
7. Reducing muscle hyperactivity for retention of removable prosthodontics
8. Sialorrhea
9. Oromandibular dystonia
10. Trigeminal neuralgia.

TMD and facial pain

One or more trigger points in muscles are generally present in TMD cases. Palpating these points instantly causes transmission of pain along muscle or neuronal tracks emerging from these trigger points. Agents including sterile saline and local anesthetic have been used and injected directly into these trigger points. Disruption of the trigger point may bring relief, either short-term or long-term. As the effect of sterile saline or local anesthetic lasts from a few minutes to only a few days the treatment benefits are limited. The use of BTX for these trigger points has been extremely beneficial, the strength of the contraction of the muscle is reduced with the effect lasting for 3 months.

Neurotoxins can be generally applied to various muscles of the face and mastication, including the trapezius, depressor anguli oris, sternocleidomastoid, splenius capitus, frontalis, procerus, corrugator, orbicularis oris, orbicularis oculi, masseter,

temporalis mentalis, and pterygoid muscles for the TMD and facial pain cases.^[2] The masseter and temporalis muscles are always treated bilaterally even if only one side of the face is involved.

Bruxism and masseteric hypertrophy

Bruxism is the general term that refers to both clenching and grinding of the teeth. It leads to the destruction of healthy dentition along with exacerbation of the periodontal disease, causing TMD, headaches and facial pain. Bilateral injections of toxin are given into the masseter and temporalis muscles in bruxism and TMD patients. Injecting the right amount will decrease the power of contractions of the muscles of mastication in addition to, improve ability for mastication and talking. The neurotoxins can help reduce facial pain, TMD symptoms and remove bruxism element thus in a way helping in treatment of periodontal diseases. Masseteric hypertrophy refers to enlargement of the masseter muscles. This often leads to clenching and bruxism. Treatment for masseteric hypertrophy is toxin being injected into the belly of the masseter muscle.^[3] This will cause reduced intensity of contractions of the masseter muscles along with slenderization of face and like all other botulinium treatments, repeat injections are required every few months.

Orthodontic therapy

Relapse has been a continual problem for many general and orthodontic dental practitioners as teeth may continue to shift well after orthodontic therapy is complete. Many patients have a hyperactive mentalis muscle that often disrupts the alignment of teeth and may cause muscles to spasm. However, BTX can reduce muscle contraction intensity, allowing muscles to be retained to work properly over time. This could revolutionize how we deal with orthodontic relapse as more dental practitioners become familiar with botulinium uses.^[4]

Removable prosthodontics

Increasing numbers of patients are receiving implant treatment to help stabilize their dentures, there will always be patients who either cannot afford implant therapy or are not suitable candidates for the therapy. Many of these patients have hyperactive muscles, making it difficult to retain dentures in their mouths. Muscle training with the help of BTX may provide relief in these cases.

Sialorrhea

Excessive saliva production or the inability to hold saliva in the mouth can result in sialorrhea, more commonly known as drooling. Sialorrhea treatments include behavioral or occupational therapy and pharmaceutical treatments like scopolamine. However, also BTX can be used to treat sialorrhea via injection into the parotid and sub maxillary salivary glands, which inhibits the stimulation of the cholinergic receptor. This use of BTX to treat sialorrhea does not treat any muscles, but it does result in saliva reduction. However, this treatment must be

done carefully as too much neurotoxin can result in mastication difficulties, inability to swallow and dry mouth.

Oromandibular dystonia

It is a muscle dysfunction and pathology that involves the masticatory and lower facial muscles. It leads to unintended opening and closing of the mouth in vertical, lateral, and protrusive directions. This condition often results in involuntarily chewing of the soft tissue inside the mouth and also can interfere with regular chewing and speaking. Masseter injections of BTX have been reported to resolve some of these muscle dysfunctions.

Trigeminal neuralgia

Trigeminal neuralgia can be described as a sharp lancinating unilateral facial pain disorder that are generally limited to the distribution of one or more divisions of the trigeminal nerve. BTX is gaining popularity in its use regarding trigeminal neuralgia cases, it has been a very useful adjunct in treating these patients as primary or secondary treatment.^[5] Adding botulinum to the treatment plan may result in significant relief of trigeminal neuralgia symptoms.

Derma Fillers in Future Dental Practice

Derma fillers are materials that are injected beneath the skin to add volume, smoothing out perioral folds and area of reduced volume. The perfect dermal filler would be cheap, safe, painless to inject, hypoallergenic, and long lasting. In addition, it should have reliable and dependable results, feel natural beneath the skin, require very little time to inject, be ready-to use and have a low risk of complications. As the people become more aware about cosmetic treatments their demand to achieve a more younger look is increasing day by day, the cosmetic market has responded by providing the esthetic surgeons and dentists with an numerous options to meet the demands of the these type of patient.

Types of Derma Fillers

Dermal filler can be categorized as:

- A. Biodegradable (moderate and long duration)
- B. Non-biodegradable fillers.

Moderate duration biodegradable fillers

Example are collagen and the hyaluronic acid (HA) fillers, they are reabsorbed by the body quite quickly, so their cosmetic benefits are fairly short-lived.

HA

HA is the most prominent glycosaminoglycan in the skin. It potently binds to water and, when injected into the skin, softens, volumizes and hydrates the skin. It plays important role in cell growth, membrane receptor function, and adhesion.

HAs are linear polymeric dimers of N-acetyl glucosamine and glucuronic acid,^[6,7] their effect lasts up to 6-18 months depending on the source, extent of cross-linking, concentration and particle size of each product.^[8] To resist degradation by hyaluronidase, the crosslinking and the concentration of the HA is increased which in turn increase its viscosity and elasticity.

HA products are classified by the size of their microspheres.

1. Example of biphasic fillers are restylane, perlane, and macrolane contain different size of microsphere
2. Examples of monophasic HA products, such as juvederm, belotero, teosyal, prevelle silk, and varioderm, contain homogeneous microspheres and are more preferred fillers.

Collagen

Collagen is the major structural constituent of the skin. The first FDA-approved dermal filler was bovine collagen and was used until 2010, after which it was no longer produced. A bioengineered human collagen was FDA approved in the year 2003 for injection use. As this newer dermal filler had no bovine collagen, it did not require any pretreatment allergy testing.

Lidocaine containing dermafillers approved by FDA are both the bovine collagen (zyderm I, zyderm II, and zyplast) and bioengineered human collagen dermal fillers (cosmoderm I, cosmoderm II, and cosmoplast), they are least painful for the patient upon injection, and thus eliminate the use of topical anesthesia or nerve blocks.^[9]

Fillers with biodegradable particles

They stimulate the body to produce its own collagen and have longer duration of effect; example include calcium hydroxylapatite (CaHA; Radiesse; Merz Pharmaceuticals GmbH) and poly-L-lactic acid (PLLA; Sculptra; Valeant, West Laval, QC, Canada).

CaHA

They are synthetic CaHA microspheres suspended in a carrier gel, example is Radiesse, which was approved in 2006 by FDA for the treatment of facial wrinkles and folds and HIV-associated facial atrophy. In 2009 FDA approved it for cosmetic use in non-HIV patients also. It is composed of 30% CaHA and 70% carrier gel.^[10]

Injection provides immediate visual improvement with long-term deposition of new collagen surrounding the microspheres, contributing to an average duration of effect of about 15 months.^[11]

PLLA

PLLA is an artificial, biocompatible, biodegradable, immunologically inert peptide polymer that is believed to stimulate fibroblasts to produce more collagen, thus increasing facial volume. It provides soft tissue augmentation through stimulation of an inflammatory tissue response with subsequent collagen deposition.^[12]

PLLA produces a gradual treatment effect and some degree of correction with each session of treatment. Three injection sessions are required but once final correction is achieved results last up to 2 years.

Non-biodegradable fillers

They provoke a foreign body reaction that stimulates a fibroblastic deposition of collagen around the non-absorbable microspheres.^[13] Examples are polymethylmethacrylate (PMMA; Artecoll, the polyacrylamide hydrogel aquamid, and silikon 1000, a medical-grade pure form of silicone.

PMMA

It consists of 80% bovine dermal collagen plus 20% PMMA microspheres. The microspheres encapsulated by a fine fibrous capsule are left after the collagen vehicle is degraded within 1-3 months. Aquamid is a hydrophilic polyacrylamide gel made up of 97.5% sterile water bound to 2.5% cross-linked acrylamide polymer. The polymer gets integrated with soft tissue, fluid exchange occurs constantly between the hydrogel and surrounding tissue.^[14]

Silikon 1000 is injected in minute amounts using a microdroplet technique, the body deposits collagen around the silicone particles. As they are non-biodegradable, their complications are more and difficult to treat.

Cosmetic Indication Of Derma Fillers

1. Filling of rhytides (e.g., glabellar frown lines, forehead furrows, crow's feet, fine perioral rhytides, shallow scars) and folds
2. Acne scars and wrinkles
3. Correction of soft tissue loss due to disease or age
4. Used for volume replacement and enhancement procedures, including:-
 - A. Cheek and chin augmentation
 - B. Tear trough correction, nose reshaping
 - C. Midfacial volumization
 - D. Lip enhancement
 - E. Hand rejuvenation, and
 - F. Correction of facial asymmetry.

Dermal Filler Dental Therapeutic Uses

1. Used to establishing aesthetic dental lip lines and smile lines as an alternative to crown lengthening, gingivectomy, and veneers
2. Treatment of angular cheilitis
3. Elimination of "black triangles" that form between teeth after periodontal and implant surgical treatment
4. Re-establishing lip volume for proper phonetics
5. Establishing lip and peri-oral volume around the mouth for retention of removable prosthodontics
6. Treatment of a gummy smile.

Conclusion

In recent years, BTX and derma fillers have made their way into dentistry for both dental esthetic and dental therapeutic uses in the oral and maxillofacial areas. They are here to stay and with more and more intra oral uses of these materials, they are fast becoming an integral part of everyday dental practice including restorative, aesthetic, periodontal, orthodontic and prosthodontics implications. They provide patients with most significant, predictable, minimally invasive, aesthetic and therapeutic outcomes available for many everyday clinical situations.

References

1. Meunier FA, Schiavo G, Molgó J. Botulinum neurotoxins: From paralysis to recovery of functional neuromuscular transmission. *J Physiol Paris* 2002;96:105-13.
2. Kurtoglu C, Gur OH, Kurkcu M, Sertdemir Y, Guler-Uysal F, Uysal H. Effect of botulinum toxin-A in myofascial pain patients with or without functional disc displacement. *J Oral Maxillofac Surg* 2008;66:1644-51.
3. Kim HJ, Yum KW, Lee SS, Heo MS, Seo K. Effects of botulinum toxin type A on bilateral masseteric hypertrophy evaluated with computed tomographic measurement. *Dermatol Surg* 2003;29:484-9.
4. Bhogal PS, Hutton A, Monaghan A. A review of the current uses of Botox for dentally-related procedures. *Dent Update* 2006;33:165-8.
5. Allam N, Brasil-Neto JP, Brown G, Tomaz C. Injections of botulinum toxin type a produce pain alleviation in intractable trigeminal neuralgia. *Clin J Pain* 2005;21:182-4.
6. American Society for Aesthetic Plastic Surgery. Cosmetic Surgery National Data Bank Statistics 2012. Available from: <http://www.surgery.org/sites/default/files/ASAPS-2011-Stats.pdf>. [Last accessed on 2013 Sep 13].
7. Zielke H, Wölber L, Wiest L, Rzany B. Risk profiles of different injectable fillers: Results from the Injectable Filler Safety Study (IFS Study). *Dermatol Surg* 2008;34:326-35.
8. Narins RS, Brandt FS, Lorenc ZP, Maas CS, Monheit GD, Smith SR. Twelve-month persistency of a novel ribose-cross-linked collagen dermal filler. *Dermatol Surg* 2008;34 Suppl 1:S31-9.
9. Murray CA, Zloty D, Warshawski L. The evolution of soft tissue fillers in clinical practice. *Dermatol Clin* 2005;23:343-63.
10. Coleman KM, Voigts R, DeVore DP, Termin P, Coleman WP 3rd. Neocollagenesis after injection of calcium hydroxylapatite composition in a canine model. *Dermatol Surg* 2008;34 Suppl 1:S53-5.
11. Bass LS, Smith S, Busso M, McClaren M. Calcium hydroxylapatite (Radiess) for treatment of nasolabial folds: Long-term safety and efficacy results. *Aesthet Surg J* 2010;30:235-8.
12. Fitzgerald R, Vlegaar D. Facial volume restoration of the aging face with poly-L-lactic acid. *Dermatol Ther* 2011;24:2-27.
13. Hilinski JM, Cohen SR. Soft tissue augmentation with ArteFill. *Facial Plast Surg* 2009;25:114-9.
14. Pallua N, Wolter TP. A 5-year assessment of safety and aesthetic results after facial soft-tissue augmentation with polyacrylamide hydrogel (Aquamid): A prospective multicenter study of 251 patients. *Plast Reconstr Surg* 2010;125:1797-804.