

# Negative pressure wound therapy aids recovery following surgical debridement due to severe bacterial cellulitis with abdominal abscess post-cesarean

## A case report (CARE-Compliant)

Christopher N.J. Young, PhD<sup>a,\*</sup>, Ka Ying Bonnie Ng, MBChB<sup>b</sup>, Vanessa Webb, RM<sup>b</sup>, Sarah Vidow, TVN<sup>b</sup>, Rajeswari Parasuraman, MD<sup>b</sup>, Sameer Umranikar, MD<sup>b</sup>

### Abstract

**Introduction:** Bacterial cellulitis post-Cesarean section is rare. Negative pressure wound therapy (NPWT) is widely used in various medical specialities; its effectiveness in obstetrics however remains the topic of debate—used predominantly as an adjunct to secondary intention specific to high-risk patient groups. Its application in the treatment of actively infected wounds post-Cesarean is not well documented. Here, we document NPWT in the treatment of an unusually severe case of bacterial cellulitis with abdominal abscess postpartum. We provide a unique photographic timeline of wound progression following major surgical debridement, documenting the effectiveness of 2 different NPWT systems (RENASYS GO and PICO, Smith & Nephew). We report problems encountered using these NPWT systems and “ad-hoc” solutions to improve efficacy and patient experience.

A 34-year-old primiparous Caucasian female with no prior history or risk factors for infection and a normal body mass index (BMI) presented with severe abdominal pain, swelling, and extensive abdominal redness 7 days postemergency Cesarean section. Examination revealed extensive cellulitis with associated abdominal abscess. *Staphylococcus aureus* was identified in wound exudates and extensive surgical debridement undertaken day 11 postnatally due to continued febrile episodes and clinical deterioration, despite aggressive intravenous antibiotic therapy. Occlusive NPWT dressings were applied for a period of 3 weeks before discharge, as well as a further 5 weeks postdischarge into the community.

NPWT was well tolerated and efficacious in infection clearance and wound healing during bacterial cellulitis. Wound healing averaged 1 cm<sup>2</sup> per week before NPWT withdrawal; cessation of NPWT before full wound closure resulted in significantly reduced healing rate, increased purulent discharges, and skin irritation, highlighting the efficacy of NPWT. Five-month follow-up in the clinic found the wound to be fully healed with no additional scarring beyond the boundaries of the original Cesarean incision. The patient was pleased with treatment outcomes, reporting no lasting pain or discomfort from the scar.

**Conclusions:** This report represents the first documented use of NPWT to aid healing of an actively infected, open wound following extensive surgical debridement 10 days post-Cesarean section, confirming both the efficacy and tolerability of NPWT for the treatment of severe bacterial cellulitis in obstetric debridement.

**Abbreviations:** CRP = C-reactive protein, NPWT = negative pressure wound therapy, SSI = surgical site infection.

**Keywords:** Cesarean, cellulitis, negative pressure wound therapy (NPWT), obstetrics, PICO, RENASYS GO

Editor: Daryle Wane.

*As both a patient and a new mum, one of the key benefits of NPWT was the sense of security against further infection, particularly while caring for a new born and breast feeding. Due to the nature of the vacuum applied, any openings in the dressings that could have resulted in infection were quickly identified by the machine, which was reassuring. Second, NPWT reduced discomfort and pain (as immediately identified when conventional dressings were stepped down to (I felt prematurely), especially as the site was still swollen having just had a baby, leaving an “overhang.” I was able to reduce additional pain relief reasonably quickly. With due care, the dressing endured showering reasonably well—a small but important factor in my recovery from having a baby. Finally, I believe NPWT was a significant factor in reducing the time the wound took to heal. Overall, NPWT reduced my discomfort and increased my confidence in caring for my baby despite the severity and nature of the wound.*

Written informed consent was provided by the patient for publication of this case report and any accompanying images. A copy of the written consent is available for review by the Editor-in-Chief of the journal.

The authors declare they have no competing financial interests.

<sup>a</sup>Department of Molecular Medicine, School of Pharmacy and Biomedical Sciences, University of Portsmouth, Portsmouth, UK., <sup>b</sup>Department of Obstetrics and Gynaecology, Princess Anne Hospital, Southampton, UK.

\* Correspondence: Christopher N.J. Young, Molecular Medicine, School of Pharmacy and Biomedical Sciences, University of Portsmouth, St Michael's Building, Portsmouth PO1 2DT, UK (e-mail: christopher.young@port.ac.uk).

Copyright © 2016 the Author(s). Published by Wolters Kluwer Health, Inc. All rights reserved.

This is an open access article distributed under the Creative Commons Attribution-NoDerivatives License 4.0, which allows for redistribution, commercial and non-commercial, as long as it is passed along unchanged and in whole, with credit to the author.

Medicine (2016) 95:50(e5397)

Received: 15 June 2016 / Received in final form: 24 October 2016 / Accepted: 25 October 2016

<http://dx.doi.org/10.1097/MD.0000000000005397>

## 1. Introduction

Severe bacterial cellulitis postpartum is rare in obstetrics. The UK has an estimated 9.6% to 9.8% rate of Cesarean section infection,<sup>[1,2]</sup> with no information currently available pertaining to the extent or severity of infection for this data set. Principles of management generally comprise broad-spectrum antibiotics with the option of prompt surgical debridement and healing by secondary intention.

NPWT has been in clinical use for several decades. The pioneers of its modern application are widely regarded as Chariker et al<sup>[3]</sup> for their work on wound healing with exudate management and Morykwas et al<sup>[4]</sup> for the development of vacuum-assisted closure devices. The basic principle involves the application of foam or gauze packing to the wound, which is then sealed using an adhesive film and connected via tubing to a low pressure vacuum pump that provides either constant or intermittent vacuum to the wound bed. NPWT serves to reduce wound volume after significant tissue loss, preventing fluid build-up that could increase the risk of reinfection; blood-flow to the wound bed is increased via capillary dilation, thereby aiding regranulation due to increased growth factor delivery, while reducing the potential for hypoxia in the wound environment.<sup>[5]</sup> Growth of new tissue is observed to occur from the base and edges of the wound. NPWT therefore induces wound edge contraction during healing, promoting reductions in both wound size and scar size.<sup>[6]</sup>

The use of NPWT is expanding in several specialist areas including diabetic and pressure ulcers—particularly in geriatrics (for a review see Gupta et al).<sup>[6]</sup> NPWT in obstetrics is in contrast surprisingly rare. It has been trialed as an adjunct to Cesarean section in high-risk delivery groups such as the obese,<sup>[7]</sup> wherein data are predominantly limited to meta-studies aimed at trialing its wide-scale, short-term implementation postpartum as an adjunct therapy to routine secondary intention.<sup>[1,8,9]</sup> NPWT therapy specific to the treatment of actively infected wounds in obstetrics has not previously been documented.

Here, we report a particularly severe case of cellulitis with associated abdominal abscess caused by *S. aureus* infection after Cesarean section, which remained undiagnosed for 1 week postpartum. Aggressive antibiotic dosing proved unsatisfactory; febrile episodes continued for 3 days post-presentation to labor ward, leading to prompt and significant surgical debridement with the implementation of a 2-stage NPWT regime to aid wound healing.

## 2. Case report

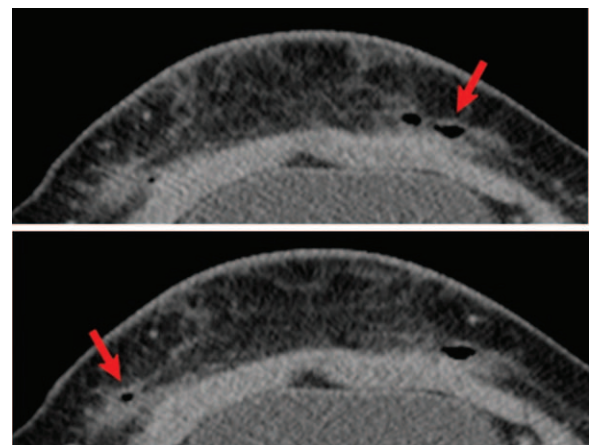
We describe a previously healthy primiparous 34-year-old Caucasian female who represented 8 days post-Cesarean section. This patient had no predisposing factors for infection and she had a normal body mass index (BMI) of 23.8 kg/m<sup>2</sup> at booking. She had spontaneous onset of labor with spontaneous rupture of membranes at term along with 13 days gestation. A category 2 Cesarean section was performed at the time due to suspected fetal compromise (pathological CTG showing atypical decelerations) at a cervical dilatation of 3 cm. The procedure was uncomplicated and the estimated blood loss was 650 mL. She recovered well postnatally, had midwifery led care on the ward, while receiving oral Flucloxacillin and was discharged day 2 post-Cesarean.

She presented to her general practitioner (GP) day 7 postnatally with fevers, pain, and redness around the Cesarean wound. The GP prescribed a 5-day course of oral Flucloxacillin and identified probable localised dermal tissue damage due to dressing removal

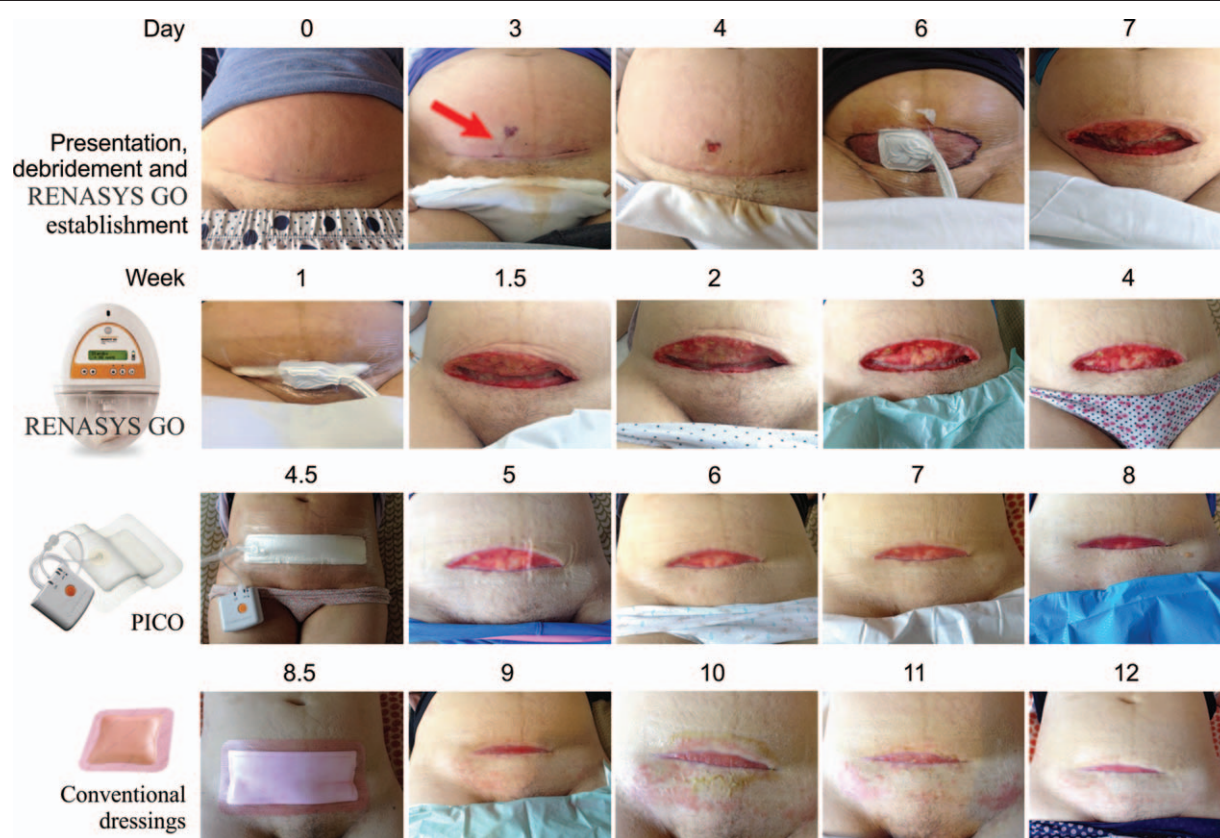
post-Cesarean. The patient then presented herself to labor ward following rupture of the misdiagnosed abdominal abscess the next day. The patient was febrile (38.8°C) and tachycardic (HR 110) at the time of presentation to the labor ward. She had worsening pain and abdominal redness, spreading approximately 20 cm superior to the wound, with swelling, purulent discharge. A ruptured abscess of approximately 2 cm<sup>2</sup> was identified; this had visibly tracked approximately 5 cm superior to the wound (Fig. 1, day 2, arrowed).

Physical examination by the bedside, performed by the obstetrician, revealed localized wound disruptions of <0.5 cm<sup>2</sup>, giving rise to extensive wound cavities beneath. A small amount of pus and blood was draining from the wound. Manual drainage of the wound was attempted with little to no effect. On admission, blood chemistry showed C-reactive protein (CRP) levels of 236 and white cell count of 13. She was initially managed conservatively with intravenous Flucloxacillin, and oral analgesia, with the later addition of intravenous clindamycin. Despite intravenous antibiotics, the patient continued to have febrile episodes. Tissue viability attended to dress the wound regularly. As there was no clinical improvement, a 1 off dose of gentamicin (5 mg/kg) was given on day 10 postnatally and a computed tomography (CT) scan was performed. This revealed extensive cellulitis within the subcutaneous fat, where several locules of gas were visible within the surgical wound (Fig. 1). An irregular 6.6 x 2.2 x 2.8 cm collection of fluid was observed anterior to the lower uterine body. No collections were observed within subcutaneous tissues and no ascites were observed. Inflammatory stranding was observed within the right-sided mesentery, but the appendix appeared normal in caliber. Due to continued swinging pyrexia, the patient underwent surgical debridement day 11 postnatally. The wound was opened and debrided; pockets of pus in the subcutaneous tissue were removed extensively from the right, just above the incision site. The abdominal sheath remained intact.

The wound was cleaned with Prontosan irrigation solution (B Braun Medical Ltd., Sheffield, UK) and packed with sterile Prontosan soaked gauze. RENASYS GO occlusive NPWT system, Smith & Nephew, Hertfordshire, UK, was procured from the hospital-based Tissue Viability Team and installed with constant operating pressure of 80 mm Hg. NPWT dressing was changed the next day, then every 4 days for a period of 8 weeks. Patient was afebrile postsurgery. Wound swabs identified *S. aureus* infection, prompting administration of Flucloxacillin



**Figure 1.** CT abdomen/pelvis with contrast. Cellulitis with associated gas pockets (arrowed) observed in the subcutaneous fat layer of the wound site.



**Figure 2.** Time course of wound treatment and healing. Wound was initially treated with oral antibiotics following presentation to GP (Day 0). Appearance and rupture of abdominal abscess prompted patient to present to labor ward (Day 4). Febrile temperature spiking following intravenous antibiotics prompted debridement and NPWT implementation (Day 6). RENASYS GO and PICO NPWT systems (Smith and Nephew) were applied for a period of 1 month each, followed by 1 month of conventional dressings. Conventional dressings leaked fluid incessantly resulting in significant skin irritation (see weeks 10–11).

(2 mg IV (intravenous), 4 times in 24 hours). Under the RENASYS GO system, wound closure progressed at a rate of approx. 1 cm<sup>2</sup> per week—wound size upon commencement of NPWT was approx. 18 x 8 x 4 cm.

NPWT regime consisted of 2 stages: Stage one—RENASYS GO system (Smith & Nephew, UK) was employed for 4 weeks with the patient discharged to the community after 3 weeks in hospital. Blood markers declined to CRP level of <50. The RENASYS GO system was changed twice weekly according to manufacturer's instructions and in consultation with the Tissue Viability Team who took over follow-up care postdischarge from labor ward. Twice-weekly changes proved successful—a longer interval could be tolerated, as wound exudate was well retained; however, dressing adhesion began to deteriorate after 4 days, which prompted this rationale. At 4 weeks, wound exudates were significantly reduced, bacterial slough was almost completely absorbed into the wound bed, and wound cavities had almost completely healed. Granulation tissue could be observed covering the surface of the wound edges with good levels of capillary regrowth (Fig. 2, weeks 1–4). In Stage 2, the RENASYS GO system was replaced with the PICO NPWT system (Smith & Nephew, UK), for a further 4 weeks, again with twice-weekly changes. This enabled the patient to benefit from increased mobility and flexibility while in the community. Antibiotic administration IV was continued for 3 weeks on postnatal ward, switching to oral upon discharge into the community; 7 days oral Clindamycin (300 mg; QDS, quater die sumendus or 4 times a day) and Flucloxacillin (1000 mg, QDS). In addition, 4 weeks of

Enoxaparin (40 mg, subcutaneous omni die or once daily) and anti-embolism stockings were prescribed.

Problems encountered using the NPWT systems employed included difficulties in transition from hospital-based care to community-based care and repeated incorrect attachment of RENASYS GO vacuum ports outside the supervisory environment of the hospital-based Tissue Viability Team, which led to insufficient or no vacuum at the wound site (Fig. 3, upper left panel, arrowed). Human error of community-based carers with insufficient experience or knowledge of NPWT systems being predominantly the cause, leading to continued patient discomfort, anxiety, and lack of confidence. A compounding factor of note here was the almost complete lack of discernment or understanding of NPWT rationales among those individuals used to providing nonspecialized wound care in the community setting. In this case, this resulted in the patient electing to carry out many of the dressing changes herself. It is clear that significant training and education would be required if NPWT usage is to become more widespread, a fact not often considered in NPWT literature when reviewing the potential benefits of this technique in obstetrics.

The PICO system also presented certain inherent impediments to smooth operation: First, it was discovered that a weak point in the dressing required repeated, specific modification using IV3000 adhesive film (Smith and Nephew) in order to achieve adequate occlusive vacuum (Fig. 3, right panel, arrowed). The patient had presented to the clinic with complaints of restless nights due to constant audible error signals from the pump unit,





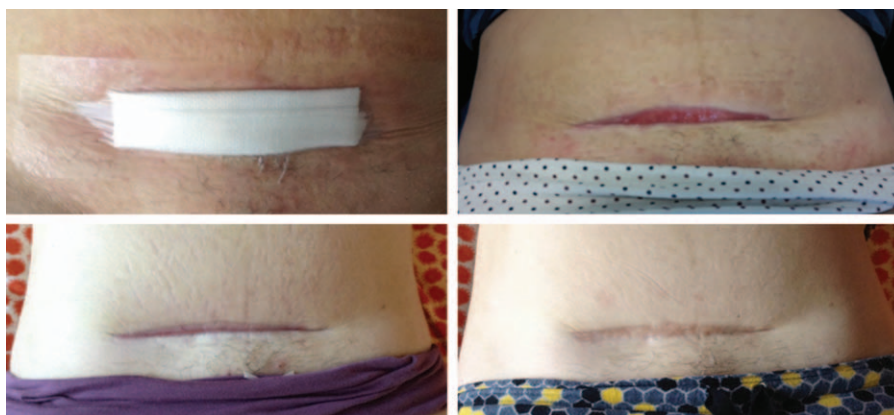
**Figure 3.** Problems encountered with NPWT systems. RENASYS GO vacuum connector applied incorrectly—port positioned too high for vacuum to be drawn—human error (Upper left panel). PICO system dressing sits proud of wound allowing fluid to escape along lower edge of dressing and irritate skin (Lower left panel). PICO vacuum connector often poorly adhered to dressing surface, resulting in no vacuum, solution—patient routinely applied adhesive film to indicated area of all PICO dressings (Right panel—red arrow).

and indeed had devised an “ad hoc” solution, consisting of a circular piece of film with a hole cut in the center, threaded over the vacuum tubing to seal the vacuum port. A final issue with the implementation of the PICO system in obstetrics is the inherent “v”-shaped nature of wounds that derive from hypogastric surgery where stomach distention after pregnancy results in a wound that is nonflat in nature. With a limited scope for attachment of an adhesive dressing in the hypogastric area, there was a tendency for fluid to accumulate along the lower edge of the PICO dressing. This resulted in significant losses in fluid retention within the dressing and subsequently, problems with skin irritation (Fig. 3, lower left panel, arrowed). This problem was solved through additional wound packing using sterile gauze, as the PICO dressing was observed to be sitting proud of the wound bed due to the shape of the wound.

Wound healing with the PICO system progressed rapidly to surface level, and decision was taken by the community team to cease NPWT. At this point, the wound measured approx. 11 x 1.5 cm. The change to conventional silver alginate dressings (Fig. 2, weeks 8.5–12) highlighted the superlative nature of the NPWT system; immediately upon removal of the PICO system, the patient experienced problems with skin irritation due to stagnant wound exudate accumulating between the skin and the

dressing. This would otherwise have been drawn into the dressing under vacuum. Tissue irritation surrounding the wound was significant enough to result in the patient being referred from the community back to the care of the Tissue Viability Team as an outpatient. Dressing changes were increased to every 48 hours and the patient requested reapplication of the PICO dressings. The wound closed under the close supervision of the Tissue Viability Team with dressing changes implemented when appropriate and tailored pragmatically to suit the changing appearance and shape of the wound (Fig. 4, upper left panel), which greatly improved wound health and the quality of the surrounding tissues (Fig. 4, upper right panel) compared with conventional dressings (Fig. 2, weeks 8.5–12).

At the 5-month follow-up in clinic, the wound had completely healed, the patient reported no pain or discomfort, with all sensations returning normally. Issues such as in-growing hairs had arisen due to continued shaving of the upper pubic region before occlusive dressing application. However, overall, the patient was completely satisfied with the outcome (Fig. 4, lower left panel) and reported an overall positive experience with NPWT. The patient also supplied a 12-month follow-up image; here, the wound is again reduced in size and appears robust and healthy (Fig. 4, lower right panel). The NPWT systems employed



**Figure 4.** Final stages of wound healing. Cessation of NPWT led to problems with fluid release using conventional dressings. This prompted the patient's own development of ad-hoc dressings comprising gauze folded into the wound and covered with film (Left panel); this method significantly improved skin health through increasing fluid retention in the wound (Upper right panel). Wound fully healed, 7 months after initial presentation (Lower right panel).

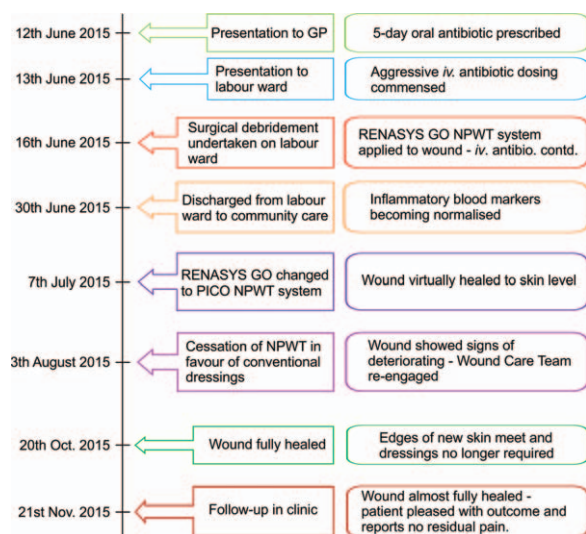


Figure 5. Timeline of interventions and outcomes.

in this case were ideally suited to use in obstetrics, being compact, quiet, portable, simple to apply, easy to change, and ultimately very effective in the treatment of a severe and actively infected Cesarean wound. Figure 5 depicts a timeline detailing the patient's diagnosis, interventions, and outcomes.

### 3. Discussion

Although cellulitis is among the most commonly observed maladies, factors governing a patient's pre-disposition remain almost entirely elusive, making prompt diagnosis essential. Fortunately, the majority of cases demonstrate uneventful recovery in response to antibiotic therapy, yet more chronic cases can necessitate surgical intervention. Aggressive surgical site infections (SSIs) are very unusual in obstetrics. Risk factors are thought to include prolonged labor, premature membrane rupture, inappropriate prophylactic antibiotic use, premature delivery, excessive vaginal intrusion, chronic anemia, and diabetes (reviewed in Gupta et al).<sup>[6]</sup> The patient discussed here displayed none of these risk factors and was fit and healthy before labor.

Cesarean delivery rates continue to rise in the UK, averaging 26.2% for 2013 to 2014,<sup>[10]</sup> with an estimated SSI rate of 9.6% to 9.8%.<sup>[1,2]</sup> No data exist regarding the severity or duration of infection for this group. NPWT in obstetrics remains under evaluation; its efficacy in reducing SSI rates post-cesarean has been demonstrated in high-risk patient groups such as the morbidly obese,<sup>[7]</sup> yet cost-benefit analyses currently limit its implementational usefulness in low-risk patients.<sup>[11]</sup> The cost and consequences of SSIs post-cesarean are, however, attracting increasing amounts of attention; risk factor analysis has indicated that BMI is a critical factor, with complication rates as high as 20% for those with BMI >35 kg/m<sup>2</sup><sup>[11]</sup> and closed laparotomy incisions in high-risk patient groups are currently the only area of obstetrics where NPWT application has been deemed cost-effective compared with conventional dressings.<sup>[11]</sup> Evidence exists for the benefits of NPWT in various medical specialties such as pressure ulcers, surgical wounds, and Fournier gangrene (a polymicrobial necrotizing fasciitis of the perineal, perianal, or genital areas).<sup>[12-14]</sup> Prophylactic application aside, to our

knowledge, no other case has detailed the use of NPWT in obstetrics following extensive surgical debridement under conditions of active infection. A previous case has reported favorable outcomes in post-cesarean SSIs where the patient has refused surgical intervention.<sup>[15]</sup> However, to our knowledge, this is the first detailed documentation of the successful implementation of NPWT to treat a severe SSI following significant surgical debridement in obstetrics. This study also serves as a detailed prognostic reference for both patients and clinicians, something that is entirely unique to the literature.

Interestingly, and rather unusually, upon presentation to labor ward, the infection had actively and visibly tracked subdermally perpendicular to the Cesarean incision in the superior direction (Fig. 2, day 2, arrowed). This artifact actually led to the patient's final decision to seek immediate medical attention; misdiagnosed as a dermal tear by her GP and community midwife, fortuitously this abscess ruptured overnight (Fig. 2, day 3) prompting the patient to present herself to the emergency labor ward; indeed, the infection actually remained undiagnosed for almost a week post-Cesarean and the patient reported having been initially discharged with abdominal pain, swelling and redness that she had assumed were "normal following a Caesarean procedure."

Final wound healing exceeded prognostic expectations; initial estimates of 6 months decreased to 2 to 3 months following the first 2 weeks of therapy where wound healing rate reached approx. 1 cm<sup>2</sup> per week. Generally, the patient reported a positive feeling of security and assurance of wound stability under NPWT, the vacuum providing solidity to the wound tissue that would otherwise have felt mobile and vulnerable. No issues were encountered while breast feeding or sleeping when the dressings were applied correctly and all dressings were well tolerated throughout with no observable side effects other than the problems with fluid retention, which were easily dealt with as described above. However, the patient reported incorrectly applied dressings to have resulted in slowed wound healing, lack of sleep due to loss of vacuum alarms sounding continuously, and general increased levels of anxiety. The patient did report moderate pain during dressing changes after leaving hospital, with adhesive remover sprays reportedly a rarity amongst community nurses. Previous studies reflecting on patient experience of NPWT have identified the management of pain during dressing removal as a priority for future development.<sup>[15]</sup> Indeed, the lack of training among community care providers was a particular point of contention for the patient in this case, which is borne out by recent reports highlighting the necessity for improvements in education and training among both patients and care providers around the correct implementation of NPWT before its more widespread use.<sup>[16,17]</sup> Upon cessation of NPWT, however, abdominal erythema re-emerged due to retention of wound exudates in contact with the skin beneath conventional dressings. Moreover, the wound bed became inflamed and swollen, taking on a blistered appearance (Fig. 2, week 10). This immediate deterioration of the wound following NPWT removal (Fig. 2, weeks 8.5-12) in favor of conventional dressings provides evidence for the success and suitability of NPWT in this case.

The timing of NPWT dressing removal is often a combination of therapeutic and cost-benefit assessment. In this case, the patient reported experiencing severe discomfort and protracted anxiety after NPWT removal, reporting a degree of annoyance that the decision had been taken to remove the dressing before full wound closure, a decision taken in this case by the community-based care team. Indeed, a significant factor affecting the implementation of NPWT in obstetrics in the UK may be

appropriate training and supervision of community-based care practitioners. The patient ended her treatment regime while implementing her own dressing changes, with dressings of her own design (Fig. 4, left panel), which proved successful in retaining excess fluid within the dressing and reducing skin irritation (Fig. 4, upper right panel). These latter stages of care, although less pertinent to the medical literature, actually constitute the most protracted period of patient recovery. Cesarean wounds are not uniform in surface shape owing to the protrusion of the upper abdominal wound face, forming a “v”-shaped groove in the skin surface, which requires additional wound packing. In this case, cessation of NPWT resulted in significant deteriorations in fluid retention capacity and resultant skin irritation, which contributed to reduced wound healing rates during the final stages of wound closure, resulting in unnecessarily protracted aftercare. The patient actually requested that NPWT be reinstated at this point to aid in fluid retention within the dressing. However, under the care of the community team, it was felt that this was not necessary. It is interesting to note the obvious decline in both healing rate and general wound health following cessation of NPWT, which would suggest that continued use of NPWT in this case led to better wound health and healing. Indeed, this case suggests that NPWT therapy should be considered until the point of full wound closure. Although this may not always remain cost-effective and may not be suitable for all patients, premature removal of NPWT may actually be a false economy; patients may have a prolonged recovery once NPWT is removed and wound healing rates may decrease as illustrated by this case. Cost-benefit analysis of the timing of NPWT removal would be useful to establish optimum therapeutic duration in the future.

A timeline of the patient’s interventions and outcomes is depicted in Fig. 5.

#### 4. Conclusion

Wounds that are acutely infected are challenging and require an intensive multimodal approach involving antibiotics, surgical intervention, and local specialists in wound care. NPWT offers the ability to promote the formation of granulation tissue in wounds and has the potential to expedite clearance of active infections and wound closure in the setting of obstetric wound healing. This case demonstrates NPWT to be safe, well tolerated, and efficacious in the treatment of severe obstetric SSIs where extensive surgical debridement is required. Furthermore, we illustrate a case of successful NPWT in a patient who is considered “low risk” and not deemed to have significant risk factors for wound infection. Although we show the potential

benefits of NPWT for the treatment of severe and active SSIs in open wounds in obstetrics, further randomized controlled trials to objectively assess outcomes and cost-effectiveness studies may be useful to guide appropriate use of NPWT.

#### References

- [1] Wloch C, Wilson J, Lamagni T, et al. Risk factors for surgical site infection following caesarean section in England: results from a multicentre cohort study. *BJOG* 2012;119:1324–33.
- [2] Wilson J, Wloch C, Saei A, et al. Inter-hospital comparison of rates of surgical site infection following caesarean section delivery: evaluation of a multicentre surveillance study. *J Hosp Infect* 2013;84:44–51.
- [3] Chariker M, Jeter K, Tintle T, et al. Effective management of incisional and cutaneous fistulae with closed suction wound drainage. *Contemp Surg* 1989;34:59–63.
- [4] Morykwas MJ, Argenta LC, Shelton-Brown EI, et al. Vacuum-assisted closure: a new method for wound control and treatment: animal studies and basic foundation. *Ann Plast Surg* 1997;38:553–62.
- [5] Huang C, Leavitt T, Bayer LR, et al. Effect of negative pressure wound therapy on wound healing. *Curr Probl Surg* 2014;51:301–31.
- [6] Gupta S, Gabriel A, Lantis J, et al. Clinical recommendations and practical guide for negative pressure wound therapy with instillation. *Int Wound J* 2016;13:159–74.
- [7] Mark KS, Alger L, Terplan M. Incisional negative pressure therapy to prevent wound complications following caesarean section in morbidly obese women: a pilot study. *Surg Innov* 2014;21:345–9.
- [8] Dohmen PM, Markou T, Ingemansson R, et al. Use of incisional negative pressure wound therapy on closed median sternal incisions after cardiothoracic surgery: clinical evidence and consensus recommendations. *Med Sci Monit* 2014;20:1814–25.
- [9] Hickson E, Harris J, Brett D. A journey to zero: reduction of post-operative caesarean surgical site infections over a five-year period. *Surg Infect (Larchmt)* 2015;16:174–7.
- [10] NHS. Maternity. Hospital Episode Statistics. 2013 (December):1–34. Available from: <http://content.digital.nhs.uk/catalogue/PUB16725/nhs-mate-eng-2013-14-summ-repo-rep.pdf>
- [11] Echebiri NC, McDoom MM, Aalto MM, et al. Prophylactic use of negative pressure wound therapy after caesarean delivery. *Obstet Gynecol* 2015;125:299–307.
- [12] Dumville JC, Webster J, Evans D, et al. Negative pressure wound therapy for treating pressure ulcers (Review). *Cochrane Database Syst Rev* 2015;5:CD011334.
- [13] Webster J, Scuffham P, Sherriff KL, et al. Negative pressure wound therapy for skin grafts and surgical wounds healing by primary intention. *Cochrane database Syst Rev* 2012;4:CD009261.
- [14] Ye J, Xie T, Wu M, et al. Negative pressure wound therapy applied before and after split-thickness skin graft helps healing of Fournier Gangrene. *Medicine (Baltimore)* 2015;94:e426.
- [15] Humburg J, Holzgreve W, Hoesli M-S. I Negative pressure wound therapy in post-caesarean superficial wound disruption: a report of 3 cases. *Wounds* 2006;18:166–9.
- [16] Upton PD, Andrews A. Negative pressure wound therapy: Improving the patient experience part 2 of 3. *J Wound Care* 2013;22:582–91.
- [17] Andrews A, Upton D. Negative pressure wound therapy: improving the patient experience part 3 of 3. *J Wound Care* 2013;22:671–2,674,676–678.