

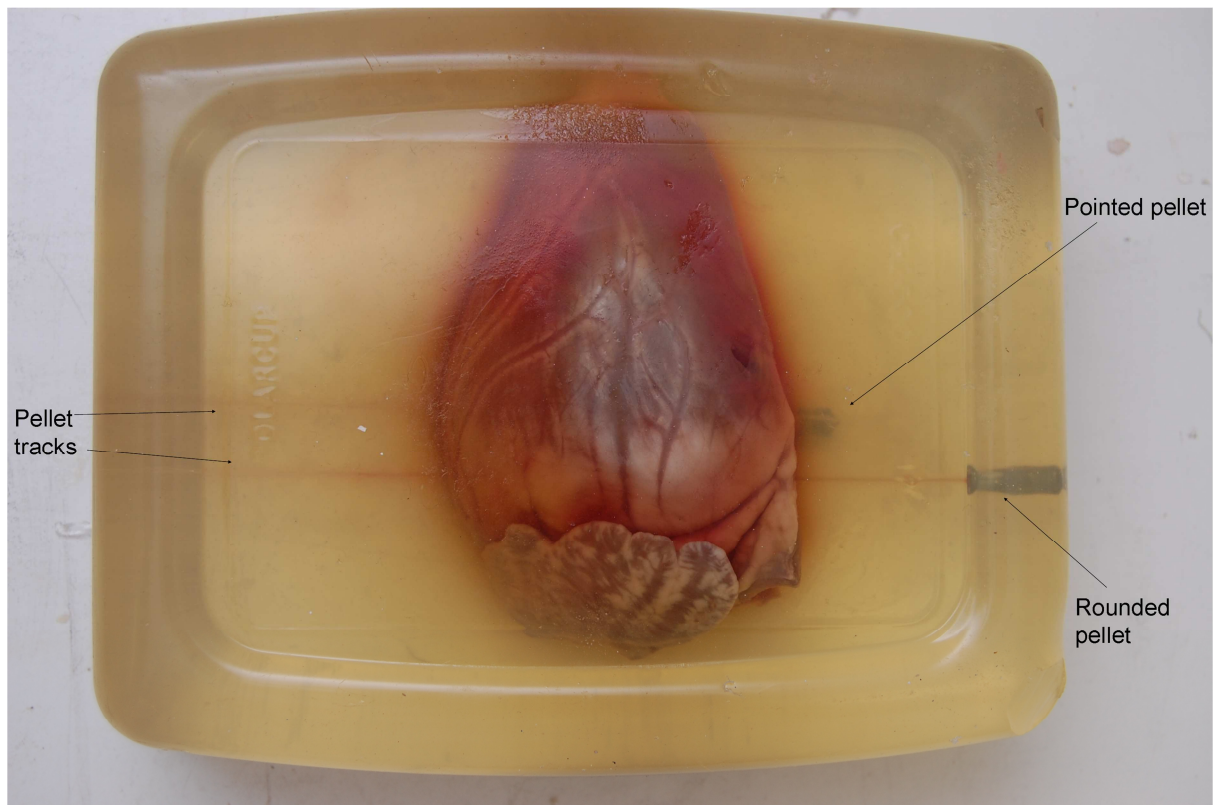Figure 1 Section of heart in ballistic gelatin, optical observation

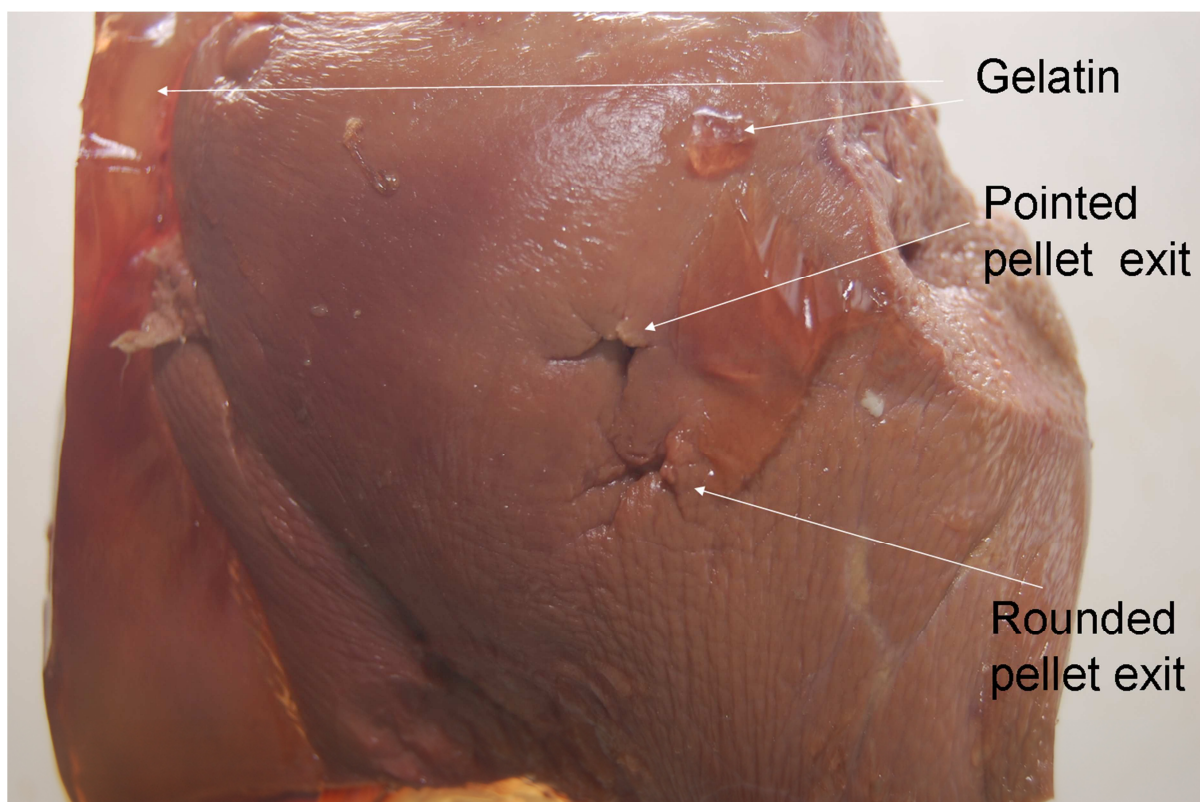


Figure 2 Section of liver, visual examination after gelatin has been removed

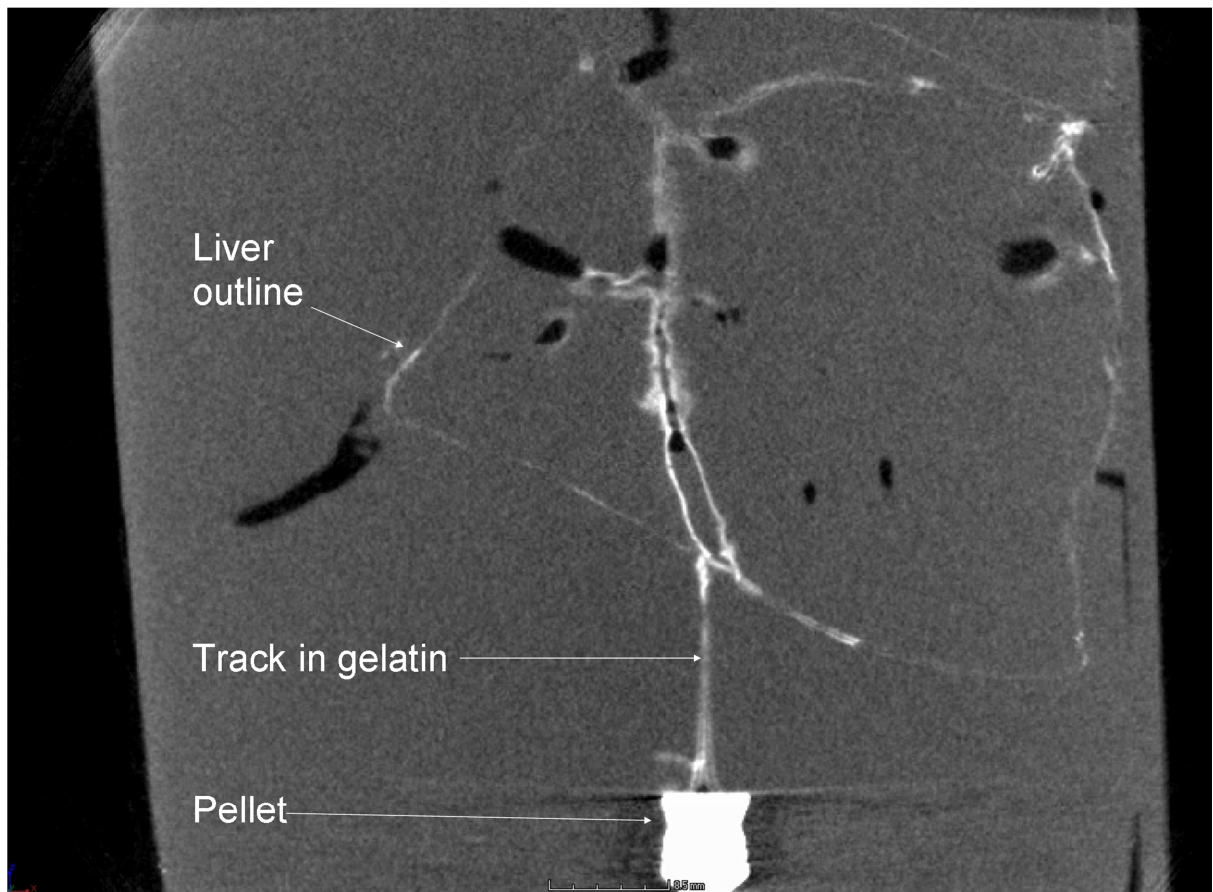


Figure 3 2-dimensional x-ray image through liver

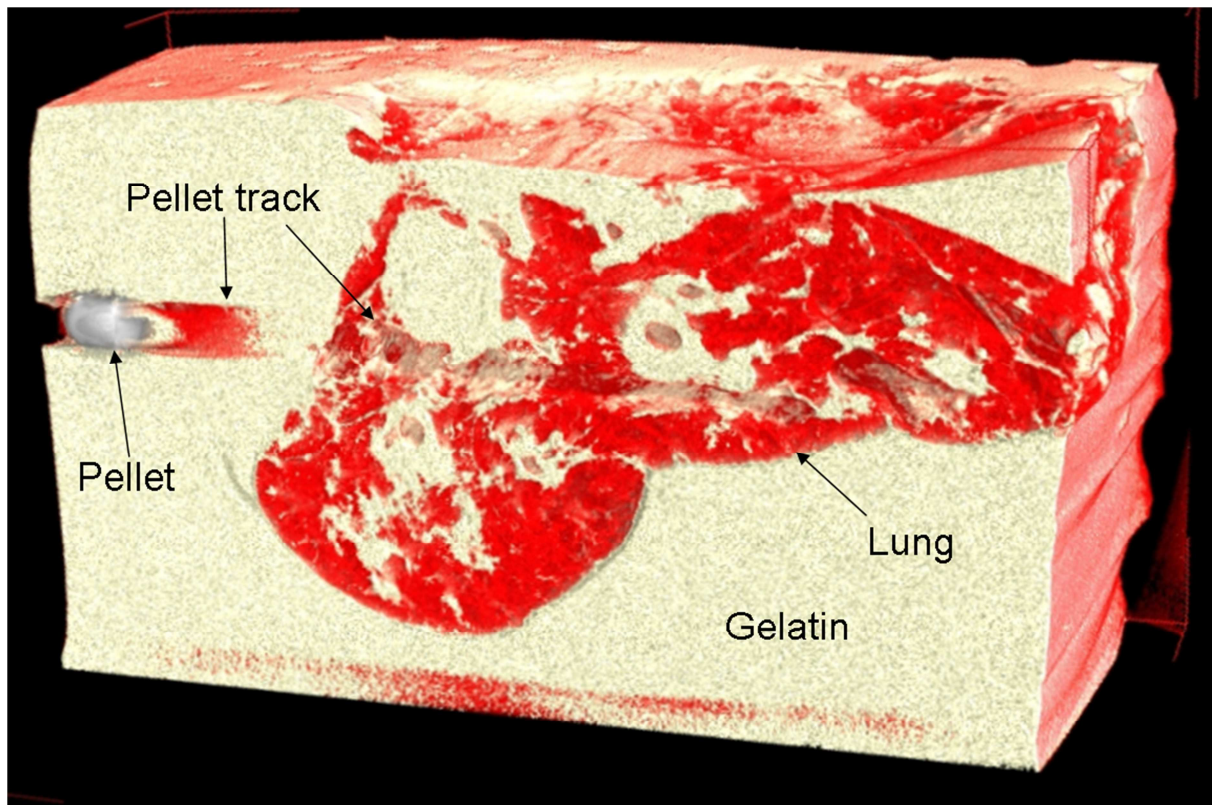


Figure 4 3-dimensional reconstruction from CT scanner of pellet track in lung




Figure 5 CT scan of pellet penetration through plasterboard