

RESEARCH ARTICLE

OPEN

Biomarkers of Targeted Therapy and Immuno-Oncology in Cancers Metastatic to the Breast

Semir Vranic, MD, PhD,* Wijendra Senarathne, MD,† Phillip Stafford, PhD,‡
Kelsey Poorman, PhD,† Barbara A. Pockaj, MD,‡ and Zoran Gatalica, MD, DSc‡

Abstract: The breast is a rare site for metastases, and their molecular characteristics have not been studied yet. Intrinsic molecular genetics, cancer characteristics, and breast tissue immune responses in diverse metastases to the breast have not been previously studied. We identified 64 patients with cancers metastatic to the breast: 51 carcinomas and 13 melanomas. Programmed death ligand 1 (PD-L1), steroid receptors, and HER2/neu expressions were evaluated using immunohistochemistry. Gene sequencing, copy number alterations, microsatellite instability, and tumor mutational burden were performed using next-generation sequencing platforms. The 3 most common primary sites for metastatic carcinomas were lung (37%), ovary (29%), and fallopian tubes/peritoneum (14%). *TP53* mutations were commonly (50%) observed among the carcinoma cases, while other mutations were characteristic for the primary cancers (*VHL* in renal, *BRCA1* in the fallopian tube, and *BRAF* in melanomas). High tumor mutational burden was detected in 5/14 carcinomas and 3/7 melanomas. Tumor cell PD-L1 expression was detected in 6 carcinomas, but not in any of the melanomas, whereas immune cells' expression of PD-L1 was seen in 17 carcinomas and 6 melanomas. Estrogen receptor status was positive in 13/49 carcinomas including 12 adenocarcinomas originating from the ovary and fallopian tube or peritoneum and 1 duodenal neuroendocrine carcinoma. No carcinoma was HER2/neu positive. Intrinsic genetic characteristics of the metastases to the breast followed the pattern commonly seen in primary tumors. Biomarkers of potential benefit to immune checkpoint inhibition therapy were limited to PD-L1-positive non-small cell lung

cancer. No common characteristics of the heterogeneous group of tumor metastases to this organ were identified.

Key Words: breast, secondary cancers, metastasis, carcinoma, molecular profiling, immuno-oncology

(*Appl Immunohistochem Mol Morphol* 2019;00:000–000)

Metastatic cancers to the breast are rare and constitute 1% to 2% of all breast malignancies.¹ When hematologic neoplasms are excluded, the frequency of secondary cancer deposits in the breast is ~1%.¹ Intramammary metastases are rarely isolated and are typically seen concurrently with metastases to other anatomic sites.^{1,2}

A comprehensive review by Koch et al³ revealed that melanomas are the most common secondary neoplasms in the breast (~30%) followed by lung, gynecologic, gastrointestinal, and hematologic malignancies.

Comprehensive molecular profiling has become the cornerstone of precision medicine. Apart from the cancers of unknown primary (CUP), most available molecular profiling information that pertains to the targeted cancer treatment originates from the primary tumors.⁴ A recently published study by Robinson et al⁴ revealed that the most commonly mutated genes in metastatic cancers were *TP53*, *CDKN2A*, *PTEN*, *PIK3CA*, and *RBI*. The study also revealed a significant burden of pathogenic germline variants (12.2% of all tested cases of which 75% were related to DNA repair defects).⁴ A study of Kim et al⁵ performed on 66 metastatic breast cancer samples using whole-exome, RNA-Seq, and targeted deep sequencing uncovered *TP53* and *PIK3CA* as the most frequent molecular events in breast metastases. A study by Ng et al⁶ focusing on synchronous primary breast cancers and their corresponding metastases confirmed a similar mutational portrait. However, metastatic breast cancers were enriched in several unique mutational alterations in genes involved in epithelial-to-mesenchymal transition [eg, *SMAD4*, *TCF7L2*, and *TCF4 (ITF2)*].

Given their rarity, the molecular characteristics of secondary (metastatic) cancers to the breast and their potential impact on therapy decisions are completely unknown. Our comprehensive literature search (all identified studies are summarized in Supplemental Table 1, Supplemental Digital Content 1, <http://links.lww.com/AIMM/A243>) revealed no study that specifically explored molecular features of

Received for publication July 26, 2019; accepted August 11, 2019.

From the *College of Medicine, QU Health, Qatar University, Doha, Qatar; †Caris Life Sciences; and ‡Department of Surgery, Mayo Clinic, Phoenix, AZ.

Z.G., W.S., P.S., and K.P. are employees of Caris Life Sciences. S.V. has received honoraria from Caris Life Sciences. B.A.P. declares no conflict of interest.

Reprints: Zoran Gatalica, MD, DSc, Caris Life Sciences, 4610 South 44th Place, Phoenix, AZ 85040 (e-mail: zgatalica@carisls.com).

Supplemental Digital Content is available for this article. Direct URL citations appear in the printed text and are provided in the HTML and PDF versions of this article on the journal's website, www.appliedimmunohist.com.

Copyright © 2019 The Author(s). Published by Wolters Kluwer Health, Inc. This is an open-access article distributed under the terms of the Creative Commons Attribution-Non Commercial-No Derivatives License 4.0 (CCBY-NC-ND), where it is permissible to download and share the work provided it is properly cited. The work cannot be changed in any way or used commercially without permission from the journal.

secondary cancers to the breast. In the present study, we reviewed the largest cohort of cancers metastatic to the breast profiled at a single reference center (Caris Life Sciences, Phoenix, AZ) for intrinsic cancer characteristics and biomarkers of immuno-oncologic (I-O) therapies.

MATERIALS AND METHODS

Samples

Cases of metastatic (secondary) cancers to the breast submitted for molecular profiling at Caris Life Sciences between July 2012 and August 2017 were analyzed. The histologic diagnoses including review of the diagnostic immunohistochemical workup performed at the referring pathology laboratories were confirmed in all cases by a board-certified pathologist at Caris Life Sciences. Hematologic malignancies and sarcomas, and melanomas and other cancers affecting the skin of the breast were excluded from the study.

Caris Life Sciences deidentified all the reports and remnant samples provided by the referring laboratories. Given that the remnant tissues from previous samplings with no associated identifiers were used, this research was compliant with 45 CFR 46.101(b). Therefore, the present study was deemed exempt from institutional review board approval, and consent requirements were waived.

Next-generation Sequencing (NGS)

Specimens were profiled using 2 massively parallel NGS (44-gene panel utilizes TruSeq Amplicon panel targeting mutation hotspots in 45 genes; 592-gene panel utilizes SureSelect XT biotinylated RNA probes to capture DNA fragments from the exons of 592 genes (Agilent, Santa Clara, CA), reflecting their availability at the time of testing (Table 1). Sequencing of the 44-gene panel used the MiSeq instrument, and, for the 592-gene panel, the

NextSeq instrument was used (Illumina, San Diego, CA).⁷⁻⁹

Copy number alterations (CNAs) were also explored on samples profiled with the 592-gene NGS panel. CNAs were calculated by comparing the depth of sequencing of genomic loci with a diploid control and the known performance of these genomic loci. Gains ≥ 6 copies were considered amplified.^{7,10}

The tumor mutational burden (TMB) was calculated by counting nonsynonymous missense mutations and excluding common germline variants using dbSNP 137 and 1000 genomes. TMB was considered high if ≥ 10 mutations/Mbp were detected, for any cancer type. TMB values were also used to compute a percentile per cancer type. For each of the metastatic cancers to the breast (non-small cell lung cancer [NSCLC], small cell lung cancer, melanoma, ovarian carcinoma, bladder carcinoma, breast carcinoma, and CUP), the total number of patients with a certain TMB score was divided by the total number of patients for that cancer cohort, resulting in a percentile score. Table 2 and Figure 1 list the percentiles for 10 representative TMB values, allowing for interconversion between TMB score and percentile. Table 3 lists metastatic cancers' TMB when determined to be "TMB High" with corresponding percentiles relative to TMB = 10 displayed.

Microsatellite instability (MSI) was calculated from the NGS data by direct analysis of short tandem repeat tracts in the target regions of sequenced genes. The count only included alterations that resulted in increases or decreases in the number of repeats; high MSI was defined as ≥ 46 altered microsatellite loci. This threshold was established by comparing NGS with the polymerase chain reaction-based microsatellite fragment analysis results from ~ 2100 samples.^{7,8,11}

Immunohistochemistry (IHC)

All IHC stains were performed using automated platforms (Benchmark; Ventana Medical Systems and DAKO Autostainer; Agilent, Santa Clara, CA) at a CLIA/CAP/ISO15189/NYSDOH certified clinical laboratory (Caris Life Sciences). Ki-67 (MIB1 antibody) was used to assess the proliferation rate of the neuroendocrine neoplasms (lung and duodenum).

Programmed death ligand 1 (PD-L1) expression was evaluated in the tumor cells (TCs) using SP142 (Ventana; n = 41), 28-8 (Agilent DAKO; for melanoma cases n = 13), and 22c3 clones (Agilent pharmDX DAKO, for NSCLC cases, n = 10) (Table 1). Specimens were considered positive using the SP142 PD-L1 clone if $\geq 5\%$ of TCs exhibited circumferential membranous positivity.¹²⁻¹⁴ The 22c3 positivity in NSCLC was based on established companion diagnostic criteria (Agilent). 28-8 PD-L1 positivity in melanomas was assessed using established complementary diagnostic criteria ($> 1\%$ viable positive cells) for nivolumab treatment in melanoma. We also assessed PD-L1 expression in immune cells (ICs) comprising lymphocytes, macrophages, and dendritic

TABLE 1. Overview of the Molecular Assays Used For Profiling of Metastatic Cancers to the Breast

Assay	No. Tested Cases
CNA	17
MSI	19
TMB	19
44-gene panel (TruSeq Amplicon panel)	41
592-gene panel (NGS)	19
Immunohistochemistry	
PD-L1	64
SP142 clone	41
28-8 clone (melanoma)	13
22c3 clone (NSCLC)	10
Steroid receptors (ER, PR, and AR)	49 (only carcinomas)
HER2/neu	45 (only carcinomas)
Ki-67	10 (only neuroendocrine neoplasms)

AR indicates androgen receptor; CNA, copy number alteration; ER, estrogen receptor; HER2, human epidermal growth factor receptor 2; MSI, microsatellite instability; NGS, next-generation sequencing; NSCLC, non-small cell lung cancer; PR, progesterone receptor; TMB, tumor mutational burden.

TABLE 2. TMB Conversion Table to Percentiles

TMB	Breast	NSCLC	SCLC	Melanoma	Ovarian	Bladder	CUP
3	0.02	0.01	0.01	0.01	0.02	0.01	0.02
5	0.17	0.07	0.05	0.07	0.2	0.05	0.15
7	0.47	0.23	0.17	0.21	0.55	0.23	0.42
9	0.65	0.36	0.29	0.29	0.74	0.37	0.57
11	0.83	0.54	0.5	0.41	0.91	0.55	0.72
13	0.91	0.68	0.69	0.48	0.96	0.69	0.8
15	0.95	0.78	0.82	0.56	0.98	0.76	0.84
17	0.96	0.85	0.91	0.62	0.98	0.83	0.86
20	0.97	0.9	0.96	0.68	0.99	0.89	0.89
22	0.98	0.93	0.97	0.71	0.99	0.91	0.91
24	0.98	0.94	0.98	0.74	0.99	0.93	0.92
26	0.99	0.95	0.98	0.76	0.99	0.95	0.93

CUP indicates cancer of unknown primary; NSCLC, non–small cell lung carcinoma; SCLC, small cell lung carcinoma; TMB, tumor mutational burden.

cells. Placental tissue served as a positive control for all PD-L1 antibodies.⁷

Androgen receptor (AR; Leica Biosystems), estrogen receptor (ER; Ventana), and progesterone receptor (PR; Ventana) were explored using a $\geq 1\%$ threshold for nuclear positivity for ER and PR¹⁵ and 10% for AR.¹⁰ Only for ovarian/fallopian tube and peritoneal carcinomas, we used the 3+/50% or 2+/75% threshold for ER positivity. Human epidermal growth factor receptor 2 (HER2; Ventana) was considered positive if $>10\%$ cancer cells showed complete, circumferential (3+) expression.¹⁶

RESULTS

Clinicopathologic Characteristics of the Cohort

We found 64 patients with cancers metastatic to the breast: 51 metastatic carcinomas and 13 melanomas

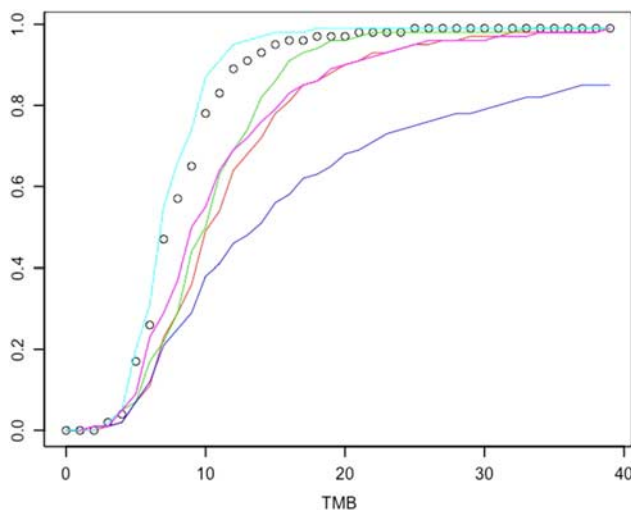


FIGURE 1. Plot of tumor mutational burden (TMB) (x-axis) versus percentile (y-axis) for cancer types in Table 2. Black dots represent breast carcinoma; red line represents non–small cell lung cancer; green line represents small cell lung cancer; blue line represents melanoma; cyan line represents ovarian cancer; magenta line is bladder cancer.

among 4500 breast biopsy specimens that were profiled in the period 2012 to 2017 (frequency $\sim 1.4\%$) (Table 3). There were 49 female and 2 male patients (both metastatic renal carcinomas) with a mean age of 57 years (range, 20 to 90 y). The known primary sites of metastatic carcinomas included the following (and they are): lung (n=19, 30%), ovary (n=15, 23%), peritoneum/fallopian tube (n=7, 11%), kidney (n=4, 6%), bladder (n=2, 3%), and duodenum and colon (n=1 each). CUPs were rare (n=2).

Histologically, 28 of the metastatic carcinomas were adenocarcinomas. Ten cases were neuroendocrine carcinomas (NEC) including 9 from the lung (7 small cell carcinomas (average Ki-67: 55%), 1 large NEC (Ki-67: 90%), 1 atypical carcinoid (Ki-67: 10%), and 1 duodenal NEC (Ki-67: 22%). Two cases were squamous cell carcinomas (both from the lung). Histopathologic evaluation of the 2 CUPs showed squamous carcinoma in 1 and serous-type adenocarcinoma in the other. The remaining 11 cases were of undifferentiated/other types of carcinoma.

Thirteen metastatic melanomas to the breast were encountered in 10 female and 3 male patients (mean age: 54 y, range, 22 to 90 y). Nine cases had no reported/known primary site (melanoma of unknown primary/MUP),¹⁷ while the remaining 4 metastatic melanomas originated from the skin of the head and neck, trunk, and buttock.

Steroid Receptor Profile and HER2 Status in Metastatic Carcinomas

ER was positive in 13/49 tested cases. A vast majority of the ER-positive cases originated from the ovary, fallopian tubes, and/or peritoneum (12 cases); the remaining ER-positive case was metastatic duodenal NEC. PR positivity was observed in 5 cases, originating from the ovary, fallopian tubes, and peritoneum. AR was positive in only 3 cases including 2 ovarian and 1 renal cell carcinoma. None of the tested cases (n=45) exhibited HER2 positivity. Both CUP cases were negative for all 3 steroid receptors and HER2. None of the cases harbored mutations in the estrogen receptor gene (*ESR1*) or the *ERBB2* (*HER2*) gene.

TABLE 3. A Summary of the Obtained Results For Predictive Immuno-oncologic Biomarkers in Metastatic Cancers to the Breast

Histologic Subtype	PD-L1 (TC)	PD-L1 (IC)	High TMB Status*	H-MSI Status†
Carcinomas, n/N (%)	6/51 (12)	17/51 (33)	5/14 (36)	0/14 (0)
Lung carcinoma	4/19	7/19	3/7	0/7
NSCLC	4/10	4/10	2/4 (50th percentile)	0/4
SCLC	0/9	3/9	1/3 (50th percentile)	0/3
Ovarian carcinoma	0/15	2/15	1/4 (87th percentile)	0/4
Fallopian tube/peritoneum	0/7	5/7	0/1	0/1
Kidney carcinoma	0/4	0/4	NA	NA
RCC	0/3	0/3	NA	NA
Medullary carcinoma	0/1	0/1	NA	NA
Bladder carcinoma	1/2	2/2	NA	NA
Duodenal NEC	0/1	0/1	0/1 (55th percentile)	0/1
Colorectal carcinoma	0/1	1/1	NA	NA
CUP	1/2	0/2	1/1	0/1
Melanomas, n/N (%)	0/13 (0)	6/12 (50)‡	3/7 (43)	0/5 (0)
MUP	0/9 (0)	5/9	2/4	0/2
Cutaneous melanoma	0/4	1/3	1/3 (38th percentile)	0/3

Far left: TMB as a numeric value is listed, followed by the resulting percentile per cancer type. For computing percentile, a cohort of patients was used. For NSCLC, 11,699 patients; for SCLC, 610 patients; for melanoma, 1751 patients; for ovarian cancer, 8234; for bladder cancer, 1016 nonurothelial patients, and for CUP, 1571 patients.

*TMB was considered high if ≥ 10 mutations/Mbp were detected.

†H-MSI status was defined as ≥ 46 altered microsatellite loci.

‡One case was difficult to assess for PD-L1 expression in inflammatory cells due to the heavy pigmentation.

CUP indicates cancer of unknown primary; H-MSI, high microsatellite instability; IC, immune cell; MUP, melanoma of unknown primary site; NA, not available; NEC, neuroendocrine carcinoma; NSCLC, non-small cell lung carcinoma; PD-L1, programmed death ligand 1; RCC, renal cell carcinoma; SCLC, small cell lung carcinoma; TC, tumor cell; TMB, tumor mutational burden.

Percentile is defined as the value below which the listed percentage of TMB values fall, for that tumor type.

I-O Biomarkers in Metastatic Carcinomas

PD-L1 Status

PD-L1 expression on TCs was present in $n=6/51$ cases (12%). PD-L1 TC-positive cases included 4 NSCLC (2 adenocarcinomas, 1 squamous cell carcinoma, and 1 NSCLC not otherwise specified, respectively), 1 bladder carcinoma, and 1 CUP case with squamous differentiation. Of note, 2 cases (lung adenocarcinoma and a CUP with squamous differentiation) exhibited high PD-L1 positivity (80% positivity).

The expression of PD-L1 in ICs was observed in $n=17/51$ cases. The positive cases included metastatic lung ($n=7$, 3 of which were NEC), peritoneal ($n=3$), bladder, ovarian and fallopian tube ($n=2$ each), and colorectal carcinoma ($n=1$). Only 3 cases demonstrated moderate to strong IC PD-L1 expression (30% to 50% positive ICs) (1 case each of bladder, ovarian, and fallopian tube carcinoma). Of note, 3 cases (2 NSCLC and 1 bladder carcinoma) had PD-L1 positivity in both cancer and ICs. None of the CUP cases had PD-L1 expression in ICs.

TMB and MSI Status in Metastatic Carcinomas and Primary Breast Cancers

TMB results were available for $n=14$ metastatic carcinomas; the average TMB was 9.6 mutations/Mbp. High TMB was observed in 5 cases: three lung carcinomas, 1 ovarian, and 1 CUP case (Table 3). The highest TMB was observed in the CUP case with squamous differentiation (29 mutations/Mbp). This case also exhibited a diffuse (80%) PD-L1 expression.

MSI status was available for $n=14$ metastatic carcinomas; all were microsatellite stable.

Mutational Profile and CNAs of Metastatic Carcinomas

The mutational profile of the cohort is summarized in Table 4. *TP53* mutation was the most common (50%) across all the histologies and lineages. Four cases with *KRAS* mutations were observed: Two mutations were seen in NSCLCs, 1 in peritoneal adenocarcinoma and in 1 CUP case (adenocarcinoma), respectively. Similarly, 4 lung-primary cases had *RBI* gene mutations (2 small cell lung cancer, 1 squamous, and 1 not otherwise specified, respectively). Three loss-of-function mutations in *PTEN* were detected (2 lung neuroendocrine and 1 lung adenocarcinoma). One case each of lung and ovarian adenocarcinoma carried pathogenic *BRAF* gene mutations. Similarly, 2 *NRAS* gene mutations were detected in 1 ovarian and colorectal adenocarcinoma, respectively. Two *PIK3CA* gene mutations were present in 1 renal and bladder carcinoma case. The first CUP presented with squamous differentiation harbored mutations in *TP53*, *KDM6A*, and *TSC2* genes along with the amplification of the *NFIB* gene. The second CUP case (adenocarcinoma histology) harbored mutations in both *KRAS* and *STK11* genes.

Some of the detected mutations were lineage-characteristic: 2 *VHL* mutations in renal clear cell carcinomas and 1 *SMARCB1* mutation in a renal medullary carcinoma case; one *BRCA1* mutation was detected in a fallopian tube carcinoma. The remaining ovarian and peritoneal carcinomas ($n=7$) did not have BRCA mutations. Neuroendocrine lung carcinomas ($n=8$) harbored *TP53* and *RBI* gene mutations ($n=2$ each). Other mutations (*AKT1*, *APC*, *ARID1A*, *ARID2*, *FANCC*, *FBXW7*,

TABLE 4. Overview of the Mutations Detected in Metastatic Cancers to the Breast

Histologic Subtype	Mutations (n)
Carcinomas	
Lung cancer	
Non-small cell lung carcinoma	<i>TP53</i> (9), <i>KRAS</i> (3), <i>PTEN</i> (3), <i>RBI</i> (2), <i>AKT</i> (1), <i>FANCC</i> (1), <i>HRAS</i> (1), <i>ARID1A</i> (1), <i>ARID2</i> (1), <i>EGFR</i> (1)
Small cell lung carcinoma	<i>TP53</i> (2), <i>RBI</i> (2), <i>FBXW7</i> (1)
Ovarian cancer	<i>TP53</i> (7), <i>BRAF</i> (2), <i>NRAS</i> (1)
Fallopian tube/peritoneum	<i>TP53</i> (3), <i>BRCA1</i> (1)
Kidney cancer	<i>VHL</i> (2), <i>SMARCB1</i> (1), <i>PIK3CA</i> (1)
Bladder cancer	<i>TP53</i> (2), <i>PIK3CA</i> (1)
Duodenum	None
Colon cancer	<i>TP53</i> (1), <i>NRAS</i> (1)
Cancer of unknown primary	<i>KRAS</i> (1), <i>TP53</i> (1), <i>KDM6A</i> (1), <i>TSC2</i> (1), <i>STK1</i> (1)
Melanomas	
Total	<i>BRAF</i> (8), <i>APC</i> (1), <i>CHEK1</i> (1), <i>CTTNB1</i> (1), <i>GNAI1</i> (1), <i>NRAS</i> (1), <i>PIK3CA</i> (1), <i>SF3B1</i> (1), <i>TP53</i> (1)
Melanoma of unknown primary	<i>BRAF</i> (6), <i>APC</i> (1), <i>NRAS</i> (1), <i>PIK3CA</i> (1), <i>TP53</i> (1)

and *TSC2*) were rare and affected single cases. Only 1, unusual *EGFR* gene mutation (p.R776C) was detected in a case of pulmonary adenocarcinoma.

CNAs were available for 13 carcinomas. Gains (≥ 6 copies) were observed in 12 genes including *ADGRA2* (n=2 cases), *AKT2* (n=2 cases), *CCNDA*, *CCNE*, *FGF*, *FGF3*, *FGF4*, *FGFR*, *MYB*, *NFIB*, *NSD3*, and *ZNF7* (n=1 case each). Only 2 carcinomas harbored >1 CNA: ovarian serous adenocarcinoma (6 genes: *ADGRA2*, *CCNDA*, *FGF*, *FGF3*, and *FGF4*) and lung squamous cell carcinoma (4 genes: *ADGRA2*, *AKT2*, *FGFR*, and *NSD3*).

The Predictive Biomarkers in Metastatic Melanomas

PD-L1 expression on melanoma TCs (>1%) was not observed in any of the tested cases (all TC negative). However, PD-L1-positive ICs were detected in half of the cases (n=6/12).

High TMB was detected in 3/5 metastatic melanomas, including 2 MUP cases, with the average TMB of 9.6 mutations/Mbp. All tested cases were microsatellite stable.

BRAF mutations were detected in 8/12 metastatic melanomas, including 6/8 MUP cases. *NRAS* mutation was present in only 1 case (MUP). None of the melanoma cases harbored *GNAS* gene mutations, although 1 case harbored concurrent mutations in *GNAI1* and *SF3B1*. No other detected molecular alterations were recurrent.

CNAs were available for 4 melanoma cases. Only 1 case (skin melanoma) harbored amplifications of the *CYP2D6* and *EP3* genes.

DISCUSSION

Secondary (metastatic) cancers to the breast are rare and contribute to ~1% of all breast malignancies.¹ Our results on the frequency and types of secondary mammary malignancies affecting the breast are in line with previously published data^{1,3} (Supplemental Table 1, Supplemental Digital Content 1, <http://links.lww.com/AIMM/A243>). CUPs were rare (only 2 were present in our series), whereas MUP site was more common.¹⁷⁻²¹ Our study explored the biomarkers of targeted and I-O therapy in this unique group of breast malignancies.

Among the metastatic carcinomas, a vast majority (80%) originated from lung and reproductive tract/peritoneum. Half of the metastatic lung cancers were NEC. These cancers may be clinically and histologically confused for the primary mammary carcinomas with neuroendocrine differentiation.¹ In contrast to the NEC of the breast,¹⁰ metastatic NEC from the lung were uniformly negative for steroid receptors ER, PR, and AR. In addition, these cancers lacked TC PD-L1 expression and exhibited low TMB, as previously reported.^{22,23} However, we confirm low (1% to 10%) IC PD-L1 in a proportion of the metastatic pulmonary NECs, as reported by several studies.^{23,24} Metastatic gynecologic/peritoneal carcinomas may also be confused for the primary mammary malignancies, not only morphologically but immunohistochemically, due to the frequent expression of steroid receptors, as confirmed in our study. None of these cases harbored mutations in the *ESR1* gene (encodes ER), which may be seen in ~20% of ER-positive breast cancers, particularly in a metastatic setting.²⁵⁻²⁷ In addition, *HER2* protein expression was consistently negative among the metastatic cancers to the breast, which is in contrast to the primary breast cancers (frequency 15% to 20%). *HER2* alterations (amplification and/or mutation) were also absent. *HER2* mutations have been increasingly recognized across the various cancers including breast (~2% to 3%), colorectal (~1.5%), gastric/gastroesophageal junction (~1.5%), genitourinary (~1%), gynecologic (~1%), lung (1%), and CUPs (~1%).²⁸⁻³² These mutations are associated with the acquired resistance to *HER2*-targeted therapies.³³

Our data on I-O profile of metastatic gynecologic/peritoneal carcinomas are in line with the previously published data on their metastases to nonbreast sites.^{34,35} Thus, metastatic ovarian and fallopian tube/peritoneal carcinomas were frequently enriched with PD-L1-positive tumor-infiltrating lymphocytes, and a subset of these harbored a high TMB. Such molecular alterations make these cancers potentially amenable for the trials with immune checkpoint inhibitors.

Three generations of *EGFR* tyrosine kinase inhibitors have been used for the treatment of NSCLC

harboring *EGFR* gene mutations.^{36,37} *EGFR* mutations have been described in 14% to 23% NSCLCs among the North American population.³⁸ Activating *EGFR* gene mutations are frequently detectable in metastatic NSCLCs.^{39–42} A recent report of Ota et al⁴³ confirmed the presence of an activating *EGFR* gene mutation in a case of metastatic pulmonary adenocarcinoma to the breast. In addition, the author's literature survey revealed *EGFR* mutations in 4/4 tested intramammary metastases of pulmonary adenocarcinomas.⁴³ In our study, a rare pathogenic *EGFR* mutation was detected in 1 case (pulmonary adenocarcinoma). The detected mutation (p. R776C) affects the protein kinase domain of the *EGFR*, resulting in its constitutive phosphorylation.^{44,45} The presence of such a mutation may also have therapeutic implications given that it may decrease the sensitivity to gefitinib and increase the sensitivity to erlotinib and AEE788.⁴⁶ The remaining metastatic NSCLCs in our study were devoid of *EGFR* gene alterations; hence, these cancers may not be suitable for treatment with *EGFR* tyrosine kinase inhibitors.

We had 2 CUP cases in our cohort, 1 with squamous and another with adenocarcinoma differentiation. The case presenting with squamous differentiation had a high TMB and high PD-L1 expression, making the patient potentially amenable to the treatment with immune checkpoint inhibitors.⁷ The other case of CUP harbored concurrent *KRAS* (p.G12V) and *STK11* (p. D194N) gene mutations. Germline *STK* mutations have been described in patients with Peutz-Jeghers syndrome (OMIM # 175200), whereas somatic *STK11* mutations have been reported in a wide spectrum of malignancies including lung, cervical, pancreatic, testicular, and other cancers.^{47,48} In the context of activating *KRAS* mutations, mutations leading to a loss of *STK11* function have been associated with decreased response to immune checkpoint inhibitors.⁴⁹

The molecular profile of metastatic melanomas to the breast (PD-L1 and TMB status) are concordant with the previous studies on cutaneous melanoma, including MUP cases.^{50–54}

It is well known that *BRAF*-mutant melanomas are prone to exhibit more aggressive biological behavior than *BRAF* wild-type melanomas.⁵⁵ We found pathogenic *BRAF* mutations in two thirds of metastatic melanomas, which is comparable to previous studies (~50%).^{55–57} One case harbored concurrent mutations in *GNAI1* (p. Q209L) and *SF3B1* (p. R625C). Although these mutations are mostly associated with uveal melanoma, they have also been reported in skin and mucosal melanomas.^{58,59} In an analysis of publically available genomic databases (TCGA), no *GNAI1*^{Q209} mutations were detected outside of melanoma. *SF3B1*^{R625} mutations were enriched in nonuveal melanomas compared with other “hotspot” mutations; however, *SF3B1* mutations in previously determined “hotspots” were also identified in primary breast carcinoma (1.1% of samples with the highest incidence of p.K700E). Melanomas of cutaneous origin that harbor these mutations have been associated with lower TMB

and a lack of response to immunotherapies.⁶⁰ This is, however, not fully consistent with our findings given that the specimen had a high TMB (13 mutations/Mbp), although no PD-L1 expression on either TC or IC components was observed.

In a small proportion of metastatic cancers to the breast, we detected a lineage-characteristic mutation that may improve the diagnosis (eg, *VHL* in renal clear cell carcinomas, *SMARCB1* in renal medullary carcinomas) and/or have therapeutic implications (*BRCA1* and *BRAF*). Thus, *BRCA1* mutations in fallopian tube carcinomas and *BRAF* mutations in melanomas may guide targeted treatments with poly (ADP-ribose) polymerase, and *BRAF* and *MEK* inhibitors.

In conclusion, we confirm the rarity of secondary cancers to the breast (1.4% of all breast biopsies with a malignancy). Their histotype distribution is in line with previous studies.^{1,3} Metastatic cancers to the breast shared similar molecular profile to their primary counterparts. The study also revealed a marked heterogeneity in terms of biomarkers of potential benefit to I-O and targeted therapies, necessitating individual patient profiling. The clinical impact of the targetable biomarkers in secondary cancers to the breast has to be determined.

REFERENCES

- Schnitt S, Collins LC. *Biopsy Interpretation of the Breast*, 3rd ed. Philadelphia, PA: Wolters Kluwer; 2018.
- Bombonati A, Lerwill MF. Metastases to and from the breast. *Surg Pathol Clin*. 2012;5:719–747.
- Koch A, Richter-Marot A, Wissler MP, et al. Mammary metastasis of extramammary cancers: current knowledge and diagnostic difficulties. *Gynecol Obstet Fertil*. 2013;41:653–659.
- Robinson DR, Wu YM, Lonigro RJ, et al. Integrative clinical genomics of metastatic cancer. *Nature*. 2017;548:297–303.
- Kim JY, Lee E, Park K, et al. Clinical implications of genomic profiles in metastatic breast cancer with a focus on TP53 and PIK3CA, the most frequently mutated genes. *Oncotarget*. 2017; 8:27997–28007.
- Ng CKY, Bidard FC, Piscuoglio S, et al. Genetic heterogeneity in therapy-naïve synchronous primary breast cancers and their metastases. *Clin Cancer Res*. 2017;23:4402–4415.
- Gatalica Z, Xiu J, Swensen J, et al. Comprehensive analysis of cancers of unknown primary for the biomarkers of response to immune checkpoint blockade therapy. *Eur J Cancer*. 2018;94: 179–186.
- Gatalica Z, Xiu J, Swensen J, et al. Molecular characterization of cancers with NTRK gene fusions. *Mod Pathol*. 2019;32:147–153.
- Joneja U, Vranic S, Swensen J, et al. Comprehensive profiling of metaplastic breast carcinomas reveals frequent overexpression of programmed death-ligand 1. *J Clin Pathol*. 2017;70:255–259.
- Vranic S, Palazzo J, Sanati S, et al. Potential novel therapy targets in neuroendocrine carcinomas of the breast. *Clin Breast Cancer*. 2019;19:131–136.
- Vanderwalde A, Spetzler D, Xiao N, et al. Microsatellite instability status determined by next-generation sequencing and compared with PD-L1 and tumor mutational burden in 11,348 patients. *Cancer Med*. 2018;7:746–756.
- Carbognin L, Pilotto S, Milella M, et al. Differential activity of nivolumab, pembrolizumab and MPDL3280A according to the tumor expression of programmed death-ligand-1 (PD-L1): sensitivity analysis of trials in melanoma, lung and genitourinary cancers. *PLoS One*. 2015;10:e0130142.
- Powles T, Eder JP, Fine GD, et al. MPDL3280A (anti-PD-L1) treatment leads to clinical activity in metastatic bladder cancer. *Nature*. 2014;515:558–562.

14. Taube JM, Klein A, Brahmer JR, et al. Association of PD-1, PD-1 ligands, and other features of the tumor immune microenvironment with response to anti-PD-1 therapy. *Clin Cancer Res.* 2014;20:5064–5074.
15. Hammond ME, Hayes DF, Dowsett M, et al. American Society of Clinical Oncology/College of American Pathologists guideline recommendations for immunohistochemical testing of estrogen and progesterone receptors in breast cancer. *J Clin Oncol.* 2010;28:2784–2795.
16. Wolff AC, Hammond ME, Hicks DG, et al. Recommendations for human epidermal growth factor receptor 2 testing in breast cancer: American Society of Clinical Oncology/College of American Pathologists clinical practice guideline update. *Arch Pathol Lab Med.* 2014;138:241–256.
17. Kamposioras K, Pentheroudakis G, Pectasides D, et al. Malignant melanoma of unknown primary site. To make the long story short. A systematic review of the literature. *Crit Rev Oncol Hematol.* 2011;78:112–126.
18. Savoia P, Fava P, Osella-Abate S, et al. Melanoma of unknown primary site: a 33-year experience at the Turin Melanoma Centre. *Melanoma Res.* 2010;20:227–232.
19. Ribero S, Pampena R, Bataille V, et al. Unknown primary melanoma: worldwide survey on clinical management. *Dermatology.* 2016;232:704–707.
20. Utter K, Goldman C, Weiss SA, et al. Treatment outcomes for metastatic melanoma of unknown primary in the new era: a single-institution study and review of the literature. *Oncology.* 2017;93:249–258.
21. Bae JM, Choi YY, Kim DS, et al. Metastatic melanomas of unknown primary show better prognosis than those of known primary: a systematic review and meta-analysis of observational studies. *J Am Acad Dermatol.* 2015;72:59–70.
22. Tsuruoka K, Horinouchi H, Goto Y, et al. PD-L1 expression in neuroendocrine tumors of the lung. *Lung Cancer.* 2017;108:115–120.
23. Schultheis AM, Scheel AH, Ozretic L, et al. PD-L1 expression in small cell neuroendocrine carcinomas. *Eur J Cancer.* 2015;51:421–426.
24. Kim HS, Lee JH, Nam SJ, et al. Association of PD-L1 expression with tumor-infiltrating immune cells and mutation burden in high-grade neuroendocrine carcinoma of the lung. *J Thorac Oncol.* 2018;13:636–648.
25. [No authors listed]. Metastatic ER+ breast cancer's genomic landscape. *Cancer Discov.* 2017;7:OF2.
26. Angus L, Beije N, Jager A, et al. ESR1 mutations: moving towards guiding treatment decision-making in metastatic breast cancer patients. *Cancer Treat Rev.* 2017;52:33–40.
27. Jeselsohn R, Buchwalter G, De Angelis C, et al. ESR1 mutations—a mechanism for acquired endocrine resistance in breast cancer. *Nat Rev Clin Oncol.* 2015;12:573–583.
28. Wen W, Chen WS, Xiao N, et al. Mutations in the kinase domain of the HER2/ERBB2 gene identified in a wide variety of human cancers. *J Mol Diagn.* 2015;17:487–495.
29. Bose R, Kavuri SM, Searleman AC, et al. Activating HER2 mutations in HER2 gene amplification negative breast cancer. *Cancer Discov.* 2013;3:224–237.
30. Kavuri SM, Jain N, Galimi F, et al. HER2 activating mutations are targets for colorectal cancer treatment. *Cancer Discov.* 2015;5:832–841.
31. Petrelli F, Tomasello G, Barni S, et al. Clinical and pathological characterization of HER2 mutations in human breast cancer: a systematic review of the literature. *Breast Cancer Res Treat.* 2017;166:339–349.
32. Priedigkeit N, Hartmaier RJ, Chen Y, et al. Intrinsic subtype switching and acquired ERBB2/HER2 amplifications and mutations in breast cancer brain metastases. *JAMA Oncol.* 2017;3:666–671.
33. Xu X, De Angelis C, Burke KA, et al. HER2 reactivation through acquisition of the HER2 L755S mutation as a mechanism of acquired resistance to HER2-targeted therapy in HER2(+) breast cancer. *Clin Cancer Res.* 2017;23:5123–5134.
34. Zhu X, Zhao L, Lang J. The BRCA1 methylation and PD-L1 expression in sporadic ovarian cancer. *Int J Gynecol Cancer.* 2018;28:1514–1519.
35. Gadducci A, Guerrieri ME. Immune checkpoint inhibitors in gynecological cancers: update of literature and perspectives of clinical research. *Anticancer Res.* 2017;37:5955–5965.
36. Takeda M, Nakagawa K. First- and second-generation EGFR-TKIs are all replaced to osimertinib in chemo-naive EGFR mutation-positive non-small cell lung cancer? *Int J Mol Sci.* 2019;20:1.
37. Russo A, Franchina T, Ricciardi GRR, et al. Third generation EGFR TKIs in EGFR-mutated NSCLC: where are we now and where are we going. *Crit Rev Oncol Hematol.* 2017;117:38–47.
38. Midha A, Dearden S, McCormack R. EGFR mutation incidence in non-small-cell lung cancer of adenocarcinoma histology: a systematic review and global map by ethnicity (mutMapII). *Am J Cancer Res.* 2015;5:2892–2911.
39. Matsuzaki T, Iwami E, Sasahara K, et al. A case report of metastatic lung adenocarcinoma with long-term survival for over 11 years. *Medicine (Baltimore).* 2019;98:e14100.
40. Ke SB, Qiu H, Chen JM, et al. Therapeutic effect of first-line epidermal growth factor receptor tyrosine kinase inhibitor (EGFR-TKI) combined with whole brain radiotherapy on patients with EGFR mutation-positive lung adenocarcinoma and brain metastases. *Curr Med Sci.* 2018;38:1062–1068.
41. Jiang T, Chu Q, Wang H, et al. EGFR-TKIs plus local therapy demonstrated survival benefit than EGFR-TKIs alone in EGFR-mutant NSCLC patients with oligometastatic or oligoprogressive liver metastases. *Int J Cancer.* 2019;144:2605–2612.
42. Liao L, Ji X, Ge M, et al. Characterization of genetic alterations in brain metastases from non-small cell lung cancer. *FEBS Open Bio.* 2018;8:1544–1552.
43. Ota T, Hasegawa Y, Okimura A, et al. Breast metastasis from EGFR-mutated lung adenocarcinoma: a case report and review of the literature. *Clin Case Rep.* 2018;6:1510–1516.
44. Kancha RK, von Bubnoff N, Peschel C, et al. Functional analysis of epidermal growth factor receptor (EGFR) mutations and potential implications for EGFR targeted therapy. *Clin Cancer Res.* 2009;15:460–467.
45. Ng PK, Li J, Jeong KJ, et al. Systematic functional annotation of somatic mutations in cancer. *Cancer Cell.* 2018;33:450–462;e410.
46. Sheu JJ, Hua CH, Wan L, et al. Functional genomic analysis identified epidermal growth factor receptor activation as the most common genetic event in oral squamous cell carcinoma. *Cancer Res.* 2009;69:2568–2576.
47. Sanchez-Cespedes M, Parrella P, Esteller M, et al. Inactivation of LKB1/STK11 is a common event in adenocarcinomas of the lung. *Cancer Res.* 2002;62:3659–3662.
48. Sanchez-Cespedes M. A role for LKB1 gene in human cancer beyond the Peutz-Jeghers syndrome. *Oncogene.* 2007;26:7825–7832.
49. Skoulidis F, Goldberg ME, Greenawald DM, et al. STK11/LKB1 mutations and PD-1 inhibitor resistance in KRAS-mutant lung adenocarcinoma. *Cancer Discov.* 2018;8:822–835.
50. Egberts F, Bergner I, Kruger S, et al. Metastatic melanoma of unknown primary resembles the genotype of cutaneous melanomas. *Ann Oncol.* 2014;25:246–250.
51. Kaunitz GJ, Cottrell TR, Lilo M, et al. Melanoma subtypes demonstrate distinct PD-L1 expression profiles. *Lab Invest.* 2017;97:1063–1071.
52. Javed A, Arguello D, Johnston C, et al. PD-L1 expression in tumor metastasis is different between uveal melanoma and cutaneous melanoma. *Immunotherapy.* 2017;9:1323–1330.
53. Panda A, Betigeri A, Subramanian K, et al. Identifying a clinically applicable mutational burden threshold as a potential biomarker of response to immune checkpoint therapy in solid tumors. *JCO Precis Oncol.* 2017. Doi: 10.1200/PO.17.00146.
54. Goodman AM, Kato S, Bazhenova L, et al. Tumor mutational burden as an independent predictor of response to immunotherapy in diverse cancers. *Mol Cancer Ther.* 2017;16:2598–2608.
55. Cheng L, Lopez-Beltran A, Massari F, et al. Molecular testing for BRAF mutations to inform melanoma treatment decisions: a move toward precision medicine. *Mod Pathol.* 2018;31:24–38.
56. Frinton E, Tong D, Tan J, et al. Metastatic melanoma: prognostic factors and survival in patients with brain metastases. *J Neurooncol.* 2017;135:507–512.

57. Rubinstein JC, Sznol M, Pavlick AC, et al. Incidence of the V600K mutation among melanoma patients with BRAF mutations, and potential therapeutic response to the specific BRAF inhibitor PLX4032. *J Transl Med.* 2010;8:67.
58. Sheng X, Kong Y, Li Y, et al. GNAQ and GNA11 mutations occur in 9.5% of mucosal melanoma and are associated with poor prognosis. *Eur J Cancer.* 2016;65:156–163.
59. Patel SP, Kim DW, Lacey CL, et al. GNA11 mutation in a patient with cutaneous origin melanoma: a case report. *Medicine (Baltimore).* 2016;95:e2336.
60. Johnson DB, Roszik J, Shoushtari AN, et al. Comparative analysis of the GNAQ, GNA11, SF3B1, and EIF1AX driver mutations in melanoma and across the cancer spectrum. *Pigment Cell Melanoma Res.* 2016;29:470–473.