



29th World Congress on Ultrasound in Obstetrics and Gynecology

12-16 October 2019, Berlin, Germany

Join us in Berlin at the leading event in
obstetric and gynecological ultrasound.

Register now

- 12 August** Early bird registration deadline
- 12 October** Pre-Congress courses
- 13 October** Congress opens

For full details visit isuog.org/worldcongress/2019

congress@isuog.org | +44 (0)20 7471 9955

* Discounts apply to ISUOG members, trainees and sonographers

Organised by the International Society of Ultrasound in Obstetrics and Gynecology.

#ISUOG2019    

 **isuog**.org

Imaging of gynecological disease: clinical and ultrasound characteristics of uterine sarcomas

M Ludovisi^{1*}, F Moro^{1*}, T Pasciuto¹, S Di Noi¹, S Giunchi², L Savelli³, MA Pascual⁴, P Sladkevicius⁵, JL Alcazar⁶, D Franchi⁷, R Mancari⁷, MC Moruzzi¹, D Jurkovic⁸, V Chiappa⁹, S Guerriero¹⁰, C Exacoustos¹¹, E Epstein¹², F Frühauf¹³, D Fischerova¹³, R Fruscio¹⁴, F Ciccarone¹, GF Zannoni¹⁵, G Scambia¹, L Valentin^{5,16†}, AC Testa^{17†}

¹Dipartimento Scienze della Salute della Donna e del Bambino, Fondazione Policlinico Universitario A. Gemelli, IRCCS, Rome, Italy;

²Gynecologic Oncology Unit, Sant'Orsola-Malpighi Hospital, University of Bologna, Bologna, Italy;

³Department of Obstetrics and Gynecology, University of Bologna, Bologna, Italy;

⁴Department of obstetrics, Gynecology and Reproduction, Hospital Universitario Dexeus, Barcelona, Spain;

⁵Department of Obstetrics and Gynecology, Skåne University Hospital, Malmö, Sweden;

⁶Department of Obstetrics and Gynecology, Clinica Universidad de Navarra, Pamplona, Spain;

⁷Gynecologic Oncology Unit, Division of Gynecology, IEO, European Institute of Oncology IRCCS, Milan, Italy;

⁸Institute for Women's Health University, College Hospital, London, UK;

⁹Department of Gynecologic Oncology, IRCCS National Cancer Institute, Milan, Italy;

¹⁰Department of Obstetrics and Gynecology, Policlinico Universitario Duilio Casula, University of Cagliari, Monserrato, Cagliari, Italy;

¹¹Department of Biomedicine and Prevention, Obstetrics and Gynecological clinic, University of Rome Tor Vergata;

¹²Department of Clinical Science and Education, Karolinska Institutet, and Department of Obstetrics and Gynecology, Södersjukhuset, Stockholm, Sweden;

¹³Gynecological Oncology Center, Department of Obstetrics and Gynecology, First Faculty of medicine, Charles University in Prague and General University Hospital in Prague, Czech Republic;

¹⁴Clinic of Obstetrics and Gynecology, University of Milano - Bicocca, Department of Medicine and Surgery, San Gerardo Hospital, Monza Italy;

¹⁵Institute of Histopathology, Fondazione Policlinico Universitario A. Gemelli, IRCCS, Università Cattolica del Sacro Cuore, Rome, Italy

¹⁶Institution of Clinical Sciences Malmö, Lund University, Sweden

¹⁷Istituto di Ginecologia e Ostetricia, Università Cattolica del Sacro Cuore, Rome, Italy

*ML and FM contributed equally

†LV and AT contributed equally

Running title

Uterine sarcomas

Key words: leiomyosarcoma; sarcoma, endometrial stromal; ultrasonography, pattern recognition.

Corresponding author:

This article has been accepted for publication and undergone full peer review but has not been through the copyediting, typesetting, pagination and proofreading process which may lead to differences between this version and the Version of Record. Please cite this article as doi: 10.1002/uog.20270

Manuela Ludovisi
Dipartimento Scienze della Salute della Donna e del Bambino, Fondazione Policlinico
Universitario A. Gemelli, IRCCS, Rome, Italy
L.go A. Gemelli 8, 00168 Rome, Italy
Email: mludovisi@gmail.com

Abstract

Objective To describe the clinical and ultrasound characteristics of uterine sarcomas.

Methods This is a retrospective multicenter study. From the databases of 13 ultrasound centers, we identified patients with a histological diagnosis of uterine sarcoma with available ultrasound reports and ultrasound images who had undergone preoperative ultrasound examination between 1996 and 2016. As a first step, each author collected information from the original ultrasound reports on predefined ultrasound features of the tumors from his/her own center and by checking the ultrasound images to find information on variables not described in the original report. As a second step, 16 ultrasound examiners reviewed electronic ultrasound images in a consensus meeting and described them using a predetermined terminology.

Results We identified 116 patients with a leiomyosarcoma, 48 with endometrial stromal sarcoma, and 31 with undifferentiated endometrial sarcoma. Median age of the patients was 56 (range, 26-86) years. Most patients were symptomatic at diagnosis (164/183, 89.6%), the most frequent presenting symptom being abnormal vaginal bleeding (91/183, 49.7%). Patients with endometrial stromal sarcoma were younger than patients with leiomyosarcoma or undifferentiated endometrial sarcoma (median age 46 years vs 57 vs 60). The results of the first and second step of

analysis were similar. According to the assessment by the original ultrasound examiners, the median largest tumor diameter was 91 (range 7-321) mm. Visible normal myometrium was reported in 149/195 (76.4%) cases, and 80% (156/195) of lesions were solitary. Most sarcomas were solid masses (>80% solid tissue) (155/195, 79.5%) and most manifested inhomogeneous echogenicity of the solid tissue (151/195, 77.4%), one sarcoma was multicystic without solid components. Cystic areas were described in 87/195 (44.6%) tumors and most cyst cavities had irregular walls (67/87, 77.0%). Internal shadowing was observed in 42/192 (21.9%) sarcomas and fan shaped shadowing in 4/192 (2.1%). Moderate or rich vascularization was found on color Doppler in 127/187 (67.9%) cases. In 153/195 (78.5%) sarcomas the original ultrasound examiner suspected malignancy.

Conclusions Uterine sarcomas typically appear as solid masses with inhomogeneous echogenicity, sometimes with irregular cystic areas but rarely with fan shaped shadowing. Most are moderately or very well vascularized.

Introduction

Aim

The aim of this retrospective study is to describe the clinical and ultrasound characteristics of uterine sarcomas.

Background

Epidemiology

Uterine sarcomas are rare malignant tumors arising from the mesenchymal tissues of the uterus, i.e. the endometrial stroma, uterine muscle and connective tissue. They represent 1% of female genital tract malignancies and 3-7% of all uterine malignancies^{1,2}.

Population-based estimates of uterine sarcoma incidence range from 1.55 to 1.95 per 100,000 women per year³. It is estimated that 0.1-0.3% of patients operated on for presumed uterine leiomyoma have a uterine sarcoma.⁴⁻⁶

According to the 2011 WHO classification, uterine sarcomas are classified as leiomyosarcomas, endometrial stromal sarcoma or undifferentiated endometrial sarcoma.⁷ This terminology will be used in this report. Leiomyosarcoma has been reported to be the most common type of sarcoma (41-60%) followed by carcinosarcoma (35%) and endometrial stromal sarcoma (16-20%).^{8,9}

In published reports, the median age of women with leiomyosarcoma was 50-56 years at diagnosis,^{3,7} endometrial stromal sarcoma 40-55 years^{3,10} and undifferentiated stromal sarcoma 55-60 years,⁷ and age adjusted incidence of leiomyosarcoma was twice as high in black women as in white women.^{3,11} Other risk factors for all histological types of sarcoma were advanced age and postmenopausal status.¹¹ Associations between endometrial stroma sarcoma and exposure to tamoxifen,^{12,13} unopposed estrogen³ and polycystic ovary syndrome have been reported.¹⁴ Endometrial stromal sarcoma is more common in women with past history of pelvic radiation.⁷

Microscopy

Histopathological diagnosis of uterine sarcomas has always been a challenge, because many benign variants of smooth muscle tumors (e.g. mitotically active leiomyomas, apoplectic leiomyomas and leiomyomas with bizarre nuclei) can simulate leiomyosarcomas. Diagnosis of endometrial stromal sarcomas is also difficult, which is reflected by frequent changes in their classification.¹⁵

The histopathologic diagnosis of uterine leiomyosarcoma is based on mitotic count exceeding 10 mitotic figures per 10 high-power-fields (MF/10 HPF), cellular atypia, and the presence of coagulative necrosis.^{16,17} Leiomyosarcomas are composed of fascicles of spindle cells with abundant eosinophilic cytoplasm.⁷ Cellular pleomorphism can be marked in poorly differentiated neoplasms. The mitotic index is usually high.^{18,19} Tumor cell necrosis occurs in one third and is characterized by an abrupt transition from viable to not viable tissue. Both cytological atypia and mitotic activity should usually be present to diagnose leiomyosarcomas, because of the difficulty in reliably distinguishing between necrosis due to infarction and tumor cell necrosis.¹⁹⁻²¹ Vascular invasion is found in 10-22% of leiomyosarcomas, and many leiomyosarcomas invade the

surrounding myometrium.⁷ Several immune-histochemical and molecular genetic studies on uterine leiomyosarcomas have been published.^{19, 22- 27} In 30 - 40% of leiomyosarcomas estrogen receptors, progesterone receptors, and androgen receptors are found.^{19,24}

The term endometrial stromal sarcoma is applied to neoplasms composed of cells that resemble endometrial stromal cells of the proliferative endometrium.¹⁹ Endometrial stromal sarcomas are low grade tumors with cells of relatively uniform size and shape. They typically show < 3 MF/10 HPF, but there can also be greater mitotic activity.⁷ Proliferation of small vessels and arterioles resembling endometrial spiral arterioles is a characteristic finding. Cluster of differentiation 10 (CD10) - a metalloproteinase - is the most specific biomarker of endometrial stromal sarcoma.²⁷

In undifferentiated endometrial sarcomas, tumor cell necrosis is generally present and can be extensive. Mitotic activity is variable but there are usually > 10 MF/10 HPF.¹ These tumors should be diagnosed only after extensive sampling has excluded smooth muscle or skeletal muscle differentiation or small foci of carcinoma, because findings of these would result in a diagnosis of carcinosarcoma. Undifferentiated endometrial sarcomas lack immunoreaction for estrogen and progesterone receptors, but many are Endothelial Growth Factor Receptor immunoreactive.²⁸ CD10 expression is not helpful in the differential diagnosis with other uterine sarcomas, because undifferentiated endometrial sarcomas as well as leiomyosarcomas and carcinosarcomas may express this marker.

Macroscopy

Leiomyosarcomas average 6-9 cm in diameter and the cut surface is typically soft, bulging, fleshy, necrotic and hemorrhagic with irregular margins.¹⁹ Infiltrative growth into the myometrium

is often noted grossly (or under the microscope), but some leiomyosarcomas may be relatively well circumscribed. About two-thirds are intramural, one-fifth submucosal and one tenth subserosal.¹⁹ They are often single masses (50-75% of cases).⁷ If a leiomyosarcoma is associated with leiomyomas, the sarcoma is usually the largest mass.¹⁹ Leiomyosarcomas tend to be larger and softer than leiomyomas.^{7,29}

Endometrial stromal sarcomas have an irregular nodular growth involving the endometrium, myometrium, or both. Size is variable but most range from 5 to 10 cm. They typically have a yellow to tan fleshy cut surface with hemorrhage and necrosis occasionally seen.¹⁹

Undifferentiated endometrial sarcomas grow as soft polypoid tumors that bulge into the endometrial cavity and invade the underlying myometrium. Hemorrhage and necrosis are frequently present.¹⁹

Clinical features and prognosis

Women with leiomyosarcomas often present with symptoms of abnormal uterine bleeding (56%) either in the pre- or post-menopausal period, a palpable pelvic mass (54%), or abdominal pain (22%).¹ Signs and symptoms resemble those of benign leiomyomas, and preoperative distinction between the two on the basis of clinical information may be difficult. Malignancy should be suspected in case of tumor growth in post-menopausal women who are not on hormonal replacement therapy.³⁰ Occasionally, the presenting symptoms are explained by tumor rupture (hemoperitoneum), extrauterine growth (one-third to one-half of cases), or metastases.¹⁹ Leiomyosarcomas are very aggressive tumors with poor prognosis.¹⁹ Treatment includes total

abdominal hysterectomy and debulking of tumor outside the uterus. Oophorectomy is generally recommended, but it might not be necessary in patients of reproductive age with early stage disease. However, even in such patients, oophorectomy must be considered if the tumor is estrogen/progesteron receptor positive. Lymph node dissection is controversial, but if there are no signs of metastatic lymph nodes, lymph node dissection can be spared.³¹⁻³³ The role of adjuvant radiation therapy for patients with Stage I/II leiomyosarcoma is highly controversial, because it does not seem to affect either progression or survival.^{34,35} The benefits of chemotherapy for patients who have undergone complete resection of disease limited to the uterus are also controversial.³⁶ Occasionally, estrogen-receptor positive tumors will respond to hormonal treatment, for example progestin, aromatase inhibitor, Gonadotrophin Releasing Hormone (GnRH) analogues or GnRH analogues plus megestrol acetate.³⁷

Patients with endometrial stromal sarcoma often present with abnormal uterine bleeding and/or pelvic pain, but as many as 25% may be asymptomatic.³⁸ Endometrial stromal sarcomas are indolent tumors with a favorable prognosis. Stage is the most important prognostic factor. The 5-year disease specific survival for stage I and II tumors is 90% compared to 50% for stage III and IV tumors.^{39,40} Surgical treatment of endometrial stromal sarcomas is hysterectomy and bilateral salpingo-oophorectomy.⁴¹ However, in young patients affected by early stage endometrial stromal sarcoma who wish to preserve reproductive function, fertility sparing surgery (hysteroscopic removal of the lesion and sparing of uterus and ovaries) is an option.^{42,43} Endometrial stromal sarcomas are usually hormone receptor-positive, and progestins and aromatase inhibitors are used as adjuvant treatment for this disease.²⁷

Undifferentiated endometrial sarcomas have very poor prognosis, and most patients die of the disease within 2 years from diagnosis.¹⁹ Treatment is primarily surgical with or without adjuvant radiotherapy or chemotherapy.^{44,45}

Accepted Article

Methods

This is a retrospective study of women diagnosed with uterine sarcoma between 1996 and 2016. From the databases of 13 ultrasound centers, we identified patients with a histological diagnosis of uterine sarcoma. We only included women who had undergone preoperative ultrasound examination by an experienced ultrasound examiner with ultrasound reports and images available for analysis. All women underwent transvaginal or transrectal ultrasound examination supplemented with a transabdominal scan if necessary to allow comprehensive examination of the uterus and adnexa. For most ultrasound examinations, high-end ultrasound equipment attached to 5.0 - 9.0 MHz vaginal probes and 3.5 - 5.0 MHz abdominal probes were used.

Information on the patients' age, presenting symptoms, menopausal status, parity, previous exposure to pelvic radiation, and FIGO stage of the sarcoma was retrieved retrospectively from patient records, and was entered into a dedicated Excel file (Microsoft Office Excel 2011, Redmond, WA, USA). Postmenopause was defined as absence of vaginal bleeding for at least 1 year after the age of 40 years provided that the amenorrhea could not be explained by medication or disease.

As a first step, information on the gray scale and color Doppler ultrasound features of the sarcomas was obtained as follows: each author collected information from the original ultrasound reports on predefined ultrasound features of the tumors from his/her own center and by checking saved ultrasound images and video clips to find information on features not described in the original report. The following ultrasound information was recorded in the Excel file: the largest diameter of the largest uterine lesion suspected to be a sarcoma, visible normal myometrium (yes, no), echogenicity of the solid tissue of the tumor as assessed subjectively (homogeneous vs

Accepted Article

inhomogeneous), presence of cystic areas within the tumor, regularity of the outline of cyst cavities (defining it as irregular if at least one cyst cavity had irregular contour), echogenicity of cyst content (anechoic, low level, hemorrhagic, ground glass, or other echogenicity),⁴⁶ type of tumor (unilocular, unilocular-solid, multilocular, multilocular-solid or solid),⁴⁶ presence of shadows described either as “fan shaped shadowing” as seen in adenomyosis or “internal shadows” (as often seen in leiomyomas),⁴⁷ calcifications (hyperechoic foci with shadowing behind), regularity of the tumor border (regular or irregular), endometrial cavity visible (yes, no, or no reliable information), free fluid in the pouch of Douglas, and ascites (ascites defined as fluid outside the pouch of Douglas). The presence of additional lesions typical of benign leiomyomas was also noted.⁴⁷ To reflect the vascularization of the tumor, the color content of the tumor scan on color Doppler ultrasound examination was estimated and classified using a color score. A color score of 1 means that no color or power Doppler signals were detected in the tumor, a score of 2 that a minimal amount of color Doppler signals was detected, a color score of 3 that a moderate amount was detected and a score of 4 that abundant color was detected.⁴⁶ The diagnosis suggested by the original ultrasound examiner in the original ultrasound report was also recorded as well as information on whether the lesion was judged to manifest ultrasound features typical of a benign myoma. The answer “no reliable information” was used when an ultrasound variable was neither described in the original report nor deducible from digital images or video clips.

As a second step, a consensus meeting was held with 16 ultrasound examiners from gynecological referral ultrasound units from four countries. They all had more than 10 years’ experience in gynecological ultrasonography. The aim was to try to identify typical ultrasound patterns of sarcomas. The consensus meeting started with the organizers of the meeting (ML and

Accepted Article

ACT) proposing which ultrasound variables (for example “shadowing” or “echogenicity of solid tissue”) should be used to describe uterine sarcomas and showing representative images of the different categories of each variable. After discussion among the participants, eleven variables (with definitions of each variable category) were selected for use in the second analysis of the images (Figure 1). Most of the variables and variable categories were the same as those used in the first step of analysis: visible normal myometrium; echogenicity of the solid tissue of the mass; presence of cystic areas; regularity of internal cyst walls; shadowing; calcifications; regularity of tumor border; appearance compatible with typical benign myoma.⁴⁷ The color score was assessed separately for circumferential and intra-lesional vascularization.⁴⁷ The classification of the echogenicity of the cyst contents differed from that in the first step of analysis: anechoic, low level, hemorrhagic, ground glass, and mixed (more than one type of cyst content in the same cyst cavity; for example fluid levels). In case of multiple cyst locules with different cyst contents, the predominant type of cyst contents was reported, while the echogenicity was classified as “variable” when no type of cyst contents dominated over the other. A new variable describing the echogenicity of the solid tissue of the tumor was introduced: the “cooked appearance”. It indicates lack of structure of the solid tissue of the tumor (Figure 2). After having agreed on the variables and terminology, the 16 ultrasound examiners looked at representative electronic ultrasound images of each tumor and described them using the predefined variables (Figure 1). Each observer noted his/her evaluation in a dedicated research form. The answer “impossible to say” means that the examiner was unable to make a decision, the answer “not assessable” means that the available ultrasound images did not contain the information necessary to provide an answer. All data were entered into a dedicated Excel file (Microsoft Office Excel 2011, Redmond, WA, USA).

Statistical calculations were performed using the Statistical Package for the Social Sciences software (SPSS Statistic, IBM corp., New York, NY, USA, PASW version 20.0). Results are presented for all sarcomas as well as separately for leiomyosarcoma, endometrial stromal sarcoma and undifferentiated endometrial sarcoma. Results based on the original ultrasound reports and retrospective evaluation of ultrasound images by the principal investigators at each center (here denoted “results obtained by original examiner”) are presented as median (range) or absolute frequency (percentage). The results of the consensus meeting are presented as the prevalence of a variable category calculated as the percentage of times that the category was noted relative to the total number of ratings for that variable.

Results

We identified 195 patients with uterine sarcomas from the database of the contributing ultrasound centers: 116 leiomyosarcomas, 48 endometrial stromal sarcomas and 31 undifferentiated endometrial sarcomas. The number of cases contributed per center is shown after the main text.

Demographic background data and FIGO stage of the tumors are shown in Table 1. Median age of the patients was 56 (range, 26-86) years and most patients were postmenopausal (111/195, 56.9%).

The majority of patients were symptomatic at diagnosis (164/183, 89.6%), and the most frequent presenting symptom was abnormal vaginal bleeding (91/183, 49.7%). Most tumors were FIGO Stage I (120/188, 63.8%). Patients with endometrial stromal sarcoma were younger than those with leiomyosarcoma or undifferentiated endometrial sarcoma (median age 46 years vs 57 vs 60) and they were more often premenopausal (32/48 vs 47/116 vs 5/31; 66.7% vs 40.5% vs 16.1%).

Abnormal bleeding was more common in patients with endometrial stromal sarcoma and undifferentiated endometrial sarcoma than in those with leiomyosarcoma (28/46, 21/30 vs 42/107; 60.9%, 70.0% vs 39.3%). Endometrial stromal sarcomas were more often FIGO stage I than the other sarcomas (39/48 vs 65/110 vs 16/30; 81.2% vs 59.0% vs 53.3%), while undifferentiated endometrial sarcomas were more often FIGO stage IV (9/30 vs 21/110 vs 4/48; 30.0% vs 19.1% vs 8.3%).

The sonographic characteristics of the uterine sarcomas are shown in Table 2 and in Figures 3-6. Median largest tumor diameter was 91 (range 7-321) mm. According to the assessment by the original examiners (first step of analysis), all but one sarcoma with reliable information on sonographic tumor type (n = 172) contained solid components and the vast majority were solid tumors (155/172, 90%). Most sarcomas manifested inhomogeneous echogenicity of the solid tissue

(151/195, 77.4%), cystic areas were described in 87/195 (44.6%), and most of the cystic areas had irregular walls (67/87, 77.0%). Internal shadows were found in 42/192 (21.5%) of cases, while fan shaped shadowing was rare (4/192, 2.1%). Tumor borders were found to be irregular in 103/195 (52.8%) cases. Moderate or rich vascularization was observed in 127/187 (67.9%) tumors with reliable color Doppler information.

There were some differences in ultrasound features between leiomyosarcomas (Figure 4), endometrial stromal sarcomas (Figure 5), and undifferentiated endometrial sarcomas (Figure 6). Leiomyosarcomas were larger than endometrial stromal sarcomas and undifferentiated endometrial sarcomas (median largest diameter 106 mm vs 68 vs 70). Endometrial stromal sarcomas manifested the highest percentage of visible normal endometrium (44/48, 91.7%) and regular tumor borders (29/48, 60.4%) and were less vascularized than the other sarcomas (score 1-2 in 20 of 47 tumors with reliable color Doppler information, 42.5%). Undifferentiated endometrial sarcomas manifested the highest percentage of absent shadowing (27/31, 87.1%), irregular tumor borders (23/31, 74.2%), and hemorrhagic or ground glass echogenicity of cyst fluid (6/15, 40%). Endometrial stromal sarcoma was the type of sarcoma that was most often misclassified as benign (13/48, 27.1%), undifferentiated sarcoma was the type of sarcoma that was least often misclassified as benign (1/31, 3.2%). Ultrasound features of uterine sarcomas that were misclassified as benign versus those correctly classified as malignant by the original ultrasound examiner are shown in Table 3. Tumors judged to be benign more often had visible normal myometrium (36/40 vs 111/153, 90.0% vs 72.5%), visible endometrium (28/40 vs 65/153, 70.0% vs 42.5%), homogenous echogenicity of the solid tissue (22/40 vs 21/153, 55% vs 13.7%), absence of cystic areas (32/40 vs 74/153, 80% vs

48.4%), regular tumor border (30/40 vs 61/153, 75.0% vs 39.9%), and color score 1 or 2 (22/40 vs 38/153, 55% vs 24.8%) than the tumors judged to be malignant.

Most sarcomas (> 80%) were described as not being typical of a benign myoma both by the original ultrasound examiners and by the examiners in the consensus meeting. Other results differed slightly between the original examiners and those in the consensus meeting. In the consensus meeting, visible normal myometrium was reported less often (53.5% vs 76.4%), while inhomogeneous echogenicity of the solid tissue of the lesion, cystic areas, irregular tumor border and fan shaped shadowing were reported more often (91.2% vs 77.9%; 54.7% vs 44.6%; 62.1% vs 52.8%; 11.7% vs 2.1%). At the consensus meeting, the prevalence of cooked appearance of solid tissue was 21.7%.

Discussion

We have described the clinical and ultrasound characteristics of uterine sarcomas. Only 10% of the patients with a sarcoma were asymptomatic, the most common presenting symptom being abnormal vaginal bleeding. On ultrasound, sarcomas typically appeared as isolated large solid masses with inhomogeneous echogenicity of the solid tissue, sometimes containing cystic (usually irregular) areas but not manifesting shadowing or calcifications. Although most sarcomas were moderately or well vascularized, a third of them manifested minimal or absent vascularization. Fourteen percent of the sarcomas were described as manifesting ultrasound signs typical of a benign myoma, and 20% were classified as benign by the ultrasound examiner. Endometrial stromal sarcoma was the type of sarcoma most often misclassified as benign on ultrasound, undifferentiated sarcoma was the one least often misclassified as benign.

Our study provides information to an area that is poorly elucidated in the literature. To our knowledge it is the largest study describing ultrasound findings in uterine sarcomas. The analysis performed during the consensus meeting is another strength. In the consensus meeting predefined variables and definitions of variable categories were first agreed upon and then used by 16 ultrasound examiners to describe the ultrasound images of the sarcomas. This makes our results likely to be generalizable. A limitation of our study is that it is retrospective: some information could not be retrieved, and when reviewing saved images, the ultrasound examiners knew the diagnosis, and this may have introduced bias.

Our results agree with information in publications describing the clinical characteristics of uterine sarcomas in that most patients were symptomatic^{1,34} and in that leiomyosarcomas were mainly diagnosed in postmenopausal women, while more than 50% of patients with endometrial

stromal sarcomas were premenopausal.³⁴ Several studies have described the sonographic appearance of uterine sarcomas⁴⁸⁻⁶² (Table 4). All studies are small, few ultrasound variables were used to describe the ultrasound images, and leiomyosarcomas, endometrial stromal sarcomas and undifferentiated stromal sarcomas were usually not described separately. Exacoustos et al, in the largest published series of leiomyosarcomas (n = 8), found that leiomyosarcomas are usually large (largest diameter >8 cm in seven of eight cases), manifest inhomogeneous echogenicity of solid tissue and often (50%) contain cystic areas. They found rich central vascularization in seven of the eight leiomyosarcomas.⁴⁸ We found that about one fourth of the leiomyosarcomas manifested minimal or absent vascularization, and the prevalence of minimal or absent central vascularization in the consensus meeting was 35.5%. It is difficult to explain this discrepancy. To our knowledge, the largest published series describing ultrasound features of endometrial stromal sarcoma includes ten cases: Park and coworkers described endometrial stromal sarcomas as solid masses with a mean size of 6.2 cm and with internal cystic degeneration in many cases.⁵⁷

Internal shadows and fan shaped shadowing are characteristics of benign myometrial lesions, such as myomas and adenomyosis^{63,64} but seem to be rare in sarcomas. Bonneau et al analyzed ultrasound findings in 85 benign myomas and 23 uterine malignant myometrial tumors of different types.⁶² Uterine malignancies more frequently appeared as a single mass with no acoustic shadowing than benign myomas. In our series, internal shadows could be detected in about 20% of the sarcomas, while fan shaped shadowing was described more rarely. Calcifications were found in about 10% of the sarcomas in our series. Bonneau et al described ultrasound signs of calcifications in 4/20 (20%) benign leiomyomas and in 1/6 (16%) sarcomas,⁶² and Pekindil et al described one case of endometrial stroma sarcoma with ultrasound signs of calcifications verified

histologically.⁵⁸ Results regarding calcifications in uterine leiomyosarcomas visible on magnetic resonance imaging (MRI) are contradictory^{65, 66}.

Two ultrasound examiners (DJ and ACT) proposed an ultrasound feature which they called “cooked appearance” to describe the appearance of solid tissue in uterine sarcomas (Figure 2). They suggest that this echogenicity corresponds to tissue necrosis, which is an important characteristic of sarcomas on histological examination.¹⁵ Our finding of no or minimal vascularization in about one third of the sarcomas may also be explained by tumor necrosis. Ultrasound signs of necrosis in pelvic metastases from non-gynecological tumors has been described as heterogeneous, avascular areas of mixed echogenicity with blurred borders radiating to the adjacent vascularized tissue.⁶⁷ Some of the participants in the consensus meeting had difficulties with understanding the definition of the cooked appearance pattern (which is entirely subjective), and so almost 20% of the ratings for the variable cooked appearance was “impossible to say”. Still, about 20% of the ratings for the variable cooked appearance was “present”.

Misclassifying a sarcoma as a benign myoma may result in delayed treatment or inappropriate surgical treatment, for example morcellation of the sarcoma with tumor spillage and/or tumor-positive resection margins. This is highly likely to worsen the prognosis.⁶⁸ About 85% of the uterine sarcomas in our series did not manifest ultrasound signs typical of a benign myoma, and 79% were judged to be clearly malignant or suspicious for malignancy. This is reassuring. It is possible that some rare benign types of uterine leiomyoma could be confused with uterine sarcomas on ultrasound, e.g. cellular leiomyomas or mitotically active leiomyomas. To our knowledge, only Exacoustos’ et al (2007) compared the ultrasound features of cellular uterine leiomyomas with those of uterine sarcoma.⁴⁸ They found “ordinary” benign leiomyomas and cellular benign

leiomyomas to manifest similar ultrasound features, while both “ordinary” leiomyomas and cellular leiomyomas manifested ultrasound characteristics different from those of uterine sarcomas.

Ultrasound findings of a large uterine myometrial tumor with inhomogenous echogenicity, internal irregular cystic areas, absence of shadows and absence of calcifications in a woman with gynecological symptoms (in particular abnormal vaginal bleeding) suggest malignancy. The ability of subjective assessment of ultrasound images using the ultrasound features outlined above to correctly discriminate between benign and malignant myometrial tumors can only be properly evaluated in a prospective study. Because sarcomas are rare tumors, it is a true challenge to conduct such a study. However, it should be feasible by involving several large oncological referral centers staffed with highly experienced ultrasound examiners.

CONTRIBUTING CENTERS

- University of Bologna (35 cases)
- Catholic University, Rome (27 cases)
- Autonomous University of Barcelona (25 cases)
- University of Pamplona (18 cases)
- Skane University Hospital Malmoe (18 cases)
- European Institute of Oncology, Milan (17 cases)
- University College Hospital of London (14 cases)
- National Cancer Institute, Milan (11 cases)
- University of Cagliari (9 cases)
- Tor Vergata, Rome (7 cases)

- Charles University of Prague (6 cases)
- Karolinska Hospital, Stockholm (5 cases)
- San Gerardo University of Monza (3 cases)

References

- 1) D'Angelo E, Prat J. Uterine sarcomas: a review. *Gynecol Oncol*. 2010; **116**: 131–139.
- 2) Major FJ, Blessing JA, Silverberg SG, Morrow CP, Creasman WT, Currie JL, Yordan E, Brady MF. Prognostic factors in early-stage uterine sarcoma. A Gynecologic Oncology Group study. *Cancer* 1993; **71**: 1702–1709.
- 3) Tropé CG, Abeler VM, Kristensen GB. Diagnosis and treatment of sarcoma of the uterus. A review. *Acta Oncol* 2012; **51**: 694–705.
- 4) Von Bargen EC, Grimes CL, Mishra K, Wang R, Haviland MJ, Hacker MR, Carnevale JA, Estes AJ, Elkadry EA. Prevalence of occult pre-malignant or malignant pathology at the time of uterine morcellation for benign disease. *Int J Gynaecol Obstet* 2017; **137**: 123-128.
- 5) Pados G, Tsolakidis D, Theodoulidis V, Makedos A, Zaramboukas T, Tarlatzis B. Prevalence of occult leiomyosarcomas and atypical leiomyomas after laparoscopic morcellation of leiomyomas in reproductive-age women. *Hum Reprod*. 2017; **32**: 2036-2041.
- 6) Perkins RB, Handal-Orefice R, Hanchate AD, Lin M, Paasche-Orlow MK. Risk of Undetected Cancer at the Time of Laparoscopic Supracervical Hysterectomy and Laparoscopic Myomectomy: Implications for the Use of Power Morcellation. *Womens Health Issues* 2016; **26** :21-6.
- 7) Zaloudek CJ, Hendrickson MR, Soslow RA. Mesenchymal Tumors of the Uterus. In *Blaustein's Pathology of the Female Genital Tract*, Kurman RJ, Hedrick Ellenson L, Ronnet BM (eds). Springer Science Business Media LLC: New York, 2011; 453–527.
- 8) Nordal RR, Thoresen SO. Uterine sarcomas in Norway 1956–1992: incidence, survival and mortality. *Eur J Cancer* 1997; **33**: 907–911.

- 9) Nagai T, Takai Y, Akahori T, Ishida H, Hanaoka T, Uotani T, Sato S, Matsunaga S, Baba K, Seki H. Novel uterine sarcoma preoperative diagnosis score predicts the need for surgery in patients presenting with a uterine mass. *Springerplus* 2014; **3**: 678.
- 10) Shah SH, Jagannathan JP, Krajewski K, O'Regan KN, George S, Ramaiya NH. Uterine sarcomas: then and now. *AJR Am J Roentgenol* 2012; **199**: 213–223.
- 11) Hosh M, Antar S, Nazzal A, Warda M, Gibreel A, Refky B. Uterine Sarcoma: Analysis of 13,089 Cases Based on Surveillance, Epidemiology, and End Results Database. *Int J Gynecol Cancer* 2016; **26**: 1098–1104.
- 12) Wickerham DL, Fisher B, Wolmark N, Bryant J, Costantino J, Bernstein L, Runowicz CD. Association of tamoxifen and uterine sarcoma. *J Clin Oncol* 2002; **20**: 2758–2760.
- 13) Wysowski DK, Honig SF, Beitz J. Uterine sarcoma associated with tamoxifen use. *N Engl J Med* 2002; **346**: 1832–1833.
- 14) Gadducci A, Gargini A, Palla E, Fanucchi A, Genazzani AR. Polycystic ovary syndrome and gynecological cancers: is there a link? *Gynecol Endocrinol.* 2005; **20**: 200-208.
- 15) Oliva E. Practical issues in uterine pathology from banal to bewildering: the remarkable spectrum of smooth muscle neoplasia. *Modern Pathology* 2016; **29**(Suppl): 104-120.
- 16) Zaloudek CJ, Norris HJ. Mesenchymal tumors of the uterus. In *Progress in Surgical Pathology Vol III*, Fenoglio CM, Wolff M (eds). Masson: New York 1981; 1–35.
- 17) Evans HL, Chawla SP, Simpson C, Finn KP. Smooth muscle neoplasms of the uterus other than ordinary leiomyoma. A study of 46 cases with emphasis on diagnostic criteria and prognostic factors. *Cancer* 1988; **62**: 2239–2247.
- 18) Pelmus M, Penault-Llorca F, Guillou L, Collin F, Bertrand G, Trassard M, Leroux A, Floquet A, Stoeckle E, Thomas L, MacGrogan G. Prognostic factors in early-stage leiomyosarcoma of the uterus. *Int J Gynecol Cancer* 2009; **19**: 385–390.

- 19) Oliva E, Carcangiu ML, Carinelli S, Young RH. Mesenchymal tumours. In *WHO Classification of Tumours of Female Reproductive Organs*, Kurman RJ, Carcangiu ML, Herrington CS, Young RH (eds). IARC Press: Lyons, 2014; 135–147.
- 20) Bell SW, Kempson RL, Hendrickson MR. Problematic uterine smooth muscle neoplasm. A clinicopathologic study of 213 cases. *Am J Surg Pathol* 1994; **18**: 535–558.
- 21) Lim D, Alvarez T, Nucci MR, Gilks B, Longacre T, Soslow RA, Oliva E. Interobserver variability in the interpretation of tumor cell necrosis in uterine leiomyosarcoma. *Am J Surg Pathol* 2013; **37**: 650–658.
- 22) Chen L, Yang B. Immunohistochemical analysis of p16, p53, and Ki-67 expression in uterine smooth muscle tumors. *Int J Gynecol Pathol* 2008; **27**: 326–332.
- 23) O'Neill CJ, McBride HA, Connolly LE, McCluggage WG. Uterine leiomyosarcomas are characterized by high p16, p53 and MIB1 expression in comparison with usual leiomyomas, leiomyoma variants and smooth muscle tumours of uncertain malignant potential. *Histopathology*. 2007; **50**: 851–858.
- 24) Akhan SE, Yavuz E, Tecer A, Iyibozkurt CA, Topuz S, Tuzlali S, Bengisu E, Berkman S. The expression of Ki-67, p53, estrogen and progesterone receptors affecting survival in uterine leiomyosarcomas. A clinicopathologic study. *Gynecol Oncol* 2005; **99**: 36–42.
- 25) Oliva E, Young RH, Amin MB, Clement PB. An immunohistochemical analysis of endometrial stromal and smooth muscle tumors of the uterus: a study of 54 cases emphasizing the importance of using a panel because of overlap in immunoreactivity for individual antibodies. *Am J Surg Pathol* 2002; **26**: 403–412.
- 26) Raspollini MR, Pinzani P, Simi L, Amunni G, Villanucci A, Paglierani M, Taddei GL. Uterine leiomyosarcomas express KIT protein but lack mutation(s) in exon 9 of c-KIT. *Gynecol Oncol* 2005; **98**: 334–335.
- 27) Kobayashi H, Uekuri C, Akasaka J, Ito F, Shigemitsu A, Koike N, Shigetomi H. The biology of uterine sarcomas: A review and update. *Mol Clin Oncol* 2013; **1**: 599–609.

- 28) Lee CH, Ali RH, Rouzbahman M, Marino-Enriquez A, Zhu M, Guo X, Brunner AL, Chiang S, Leung S, Nelnyk N, Huntsman DG, Blake Gilks C, Nielsen TO, Dal Cin P, van de Rijn M, Oliva E, Fletcher JA, Nucci MR. Cyclin D1 as a diagnostic immunomarker for endometrial stromal sarcoma with YWHAE-FAM22 rearrangement. *Am J Surg Pathol* 2012; **36**: 1562–1570.
- 29) Abeler VM, Royne O, Thoresen S, Danielsen HE, Nesland JM, Kristensen GB. Uterine sarcomas in Norway. A histopathological and prognostic survey of a total population from 1970 to 2000 including 419 patients. *Histopathology* 2009; **54**: 355–364.
- 30) Perri T, Korach J, Sadetzki S, Oberman B, Fridman E, Ben-Baruch G. Uterine leiomyosarcoma: does the primary surgical procedure matter? *Int J Gynecol Cancer* 2009; **19**: 257–260.
- 31) Giuntoli II RL, Metzinger DS, DiMarco CS, Cha SS, Sloan JA, Keeney GL, Gostout BS. Retrospective review of 208 patients with leiomyosarcoma of the uterus: prognostic indicators, surgical management, and adjuvant therapy. *Gynecol Oncol* 2003; **89**: 460–469.
- 32) Hoellen F, Waldmann A, Benthin S, Hanker L, Rody A, Fischer D. The role of lymphadenectomy in uterine sarcoma: a clinical practical approach based on retrospective analysis. *Anticancer Res* 2014; **34**: 985–993.
- 33) Kapp DS, Shin JY, Chan JK. Prognostic factors and survival in 1396 patients with uterine leiomyosarcomas: emphasis on impact of lymphadenectomy and oophorectomy. *Cancer* 2008; **112**: 820–830.
- 34) Wen KC, Horng CC, Wang PH, Chen YJ, Yen MS, Ng HT; Taiwan Association of Gynecology Systematic Review Group. Uterine sarcoma Part I-Uterine leiomyosarcoma: The Topic Advisory Group systematic review. *Taiwan J Obstet Gynecol* 2016; **55**: 463–471.
- 35) Reed NS, Mangioni C, Malmstrom H, Scarfone G, Poveda A, Pecorelli S, Tateo S, Franchi M, Jobsen JJ, Coens C, Teodorovic I, Vergote I, Vermorken JB; European Organisation for Research and Treatment of Cancer Gynaecological Cancer Group. Phase III randomised study to evaluate the role of adjuvant pelvic radiotherapy in the treatment of uterine sarcomas stages I and II: an

European Organisation for Research and Treatment of Cancer Gynaecological Cancer Group study (protocol 55874). *Eur J Cancer* 2008; **44**: 808–818.

36) Hensley ML, Barrette BA, Baumann K, Gaffney D, Hamilton AL, Kim JW, Maenpaa JU, Pautier P, Siddiqui NA, Westermann AM, Ray-Coquard I. Gynecologic Cancer InterGroup (GCIG) consensus review: uterine and ovarian leiomyosarcomas. *Int J Gynecol Cancer* 2014; **24**(Suppl): 61–66.

37) Thanopoulou E, Judson I. Hormonal therapy in gynecological sarcomas. *Expert Rev Anticancer Ther* 2012; **12**: 885–894.

38) Chang KL, Crabtree GS, Lim-Tan SK, Kempson RL, Hendrickson MR. Primary uterine endometrial stromal neoplasms. A clinicopathologic study of 117 cases. *Am J Surg Pathol* 1990; **14**: 415–438.

39) Prat J, Mbatani N. Uterine sarcomas. *Int J Gynecol Obstet* 2015; **131**: 105–110.

40) Chan JK, Kavar NM, Shin JY, Osann K, Chen LM, Powell CB, Kapp DS. Endometrial stromal sarcoma: a population-based analysis. *Br J Cancer* 2008; **99**: 1210–1215.

41) Uterine Sarcoma in NCCN Clinical Practice Guidelines in Oncology (NCCN Guidelines) Uterine Neoplasms, Version 2.2018-May 25, 2018; pg 31.

42) Laurelli G, Falcone F, Scaffa C, Messalli EM, Del Giudice M, Losito S, Greggi S. Fertility-sparing management of low-grade endometrial stromal sarcoma: analysis of an institutional series and review of the literature. *Eur J Obstet Gynecol Reprod Biol* 2015; **195**: 61–66.

43) Xie W, Cao D, Yang J, Jiang X, Shen K, Pan L, Huang H, Lang J, You Y, Chen J. Fertility-sparing surgery for patients with low-grade endometrial stromal sarcoma. *Oncotarget* 2017; **8**: 10602–10608.

44) Mansi JL, Ramachandra S, Wiltshaw E, Fisher C. Endometrial stromal sarcomas. *Gynecol Oncol* 1990; **36**: 113–118.

- 45) Sutton G, Blessing JA, Park R, Di Saia PJ, Rosenshein N. Ifosfamide treatment of recurrent or metastatic endometrial stromal sarcomas previously unexposed to chemotherapy: a study of the Gynecologic Oncology Group. *Obstet Gynecol* 1996; **87**: 747–750.
- 46) Timmerman D, Valentin L, Bourne TH, Collins WP, Verrelst H, Vergote I; International Ovarian Tumor Analysis (IOTA) Group. Terms, definitions and measurements to describe the sonographic features of adnexal tumors: a consensus opinion from the International Ovarian Tumor Analysis (IOTA) Group. *Ultrasound Obstet Gynecol*. 2000; **16**: 500-505.
- 47) Van den Bosch T, Dueholm M, Leone FP, Valentin L, Rasmussen CK, Votino A, Van Schoubroeck D, Landolfo C, Installé AJ, Guerriero S, Exacoustos C, Gordts S, Benacerraf B, D'Hooghe T, De Moor B, Brölmann H, Goldstein S, Epstein E, Bourne T, Timmerman D. Terms, definitions and measurements to describe sonographic features of myometrium and uterine masses: a consensus opinion from the Morphological Uterus Sonographic Assessment (MUSA) group. *Ultrasound Obstet Gynecol* 2015; **46**: 284–298.
- 48) Exacoustos C, Romanini ME, Amadio A, Amoroso C, Szabolcs B, Zupi E, Arduini D. Can gray-scale and color Doppler sonography differentiate between uterine leiomyosarcoma and leiomyoma? *J Clin Ultrasound* 2007; **35**: 449–457.
- 49) Hata K, Hata T, Maruyama R, Hirai M. Uterine sarcoma: can it be differentiated from uterine leiomyoma with Doppler ultrasonography? A preliminary report. *Ultrasound Obstet Gynecol*. 1997; **9**: 101-104.
- 50) Aviram R, Ochshorn Y, Markovitch O, Fishman A, Cohen I, Altaras MM, Tepper R. Uterine sarcomas versus leiomyomas: gray-scale and Doppler sonographic findings. *J Clin Ultrasound*. 2005; **33**: 10-13.
- 51) Szabó I, Szánthó A, Papp Z. Uterine sarcoma: diagnosis with multiparameter sonographic analysis. *Ultrasound Obstet Gynecol*. 1997; **10**: 220-221.

- 52) Adesiyun AG, Samaila MO. Leiomyosarcoma uteri in a white woman. *Ann Afr Med.* 2010; **9**: 35-38.
- 53) Cho FN, Liu CB, Yu KJ. Low-grade endometrial stromal sarcoma initially manifesting as a large complex pedunculated mass arising from the uterine surface. *Ultrasound Obstet Gynecol.* 201; **38**: 233-234.
- 54) Gandolfo N, Gandolfo NG, Serafini G, Martinoli C. Endometrial stromal sarcoma of the uterus: MR and US findings. *Eur Radiol* 2000; **10**: 776–779
- 55) Jayakrishnan K, Koshy AK, Manjula P, Nair AM, Ramachandran A, Kattoor J. Endometrial stromal sarcoma mimicking a myoma. *Fertil Steril* 2009; **92**: 1744-1746
- 56) Kim JA, Lee MS, Choi JS. Sonographic Findings of Uterine Endometrial Stromal Sarcoma. *Korean J Radiol* 2006; **7**: 281-286
- 57) Park GU, Rha SE, Oh SN, Lee A, Lee KH, Kim MR. Ultrasonographic findings of low-grade endometrial stromal sarcoma of the uterus with a focus on cystic degeneration. *Ultrasonography* 2016; **35**: 124–130.
- 58) Pekindil G, Tuncyurek O, Orguc S, Inceboz U, Kandiloglu AR, Caglar H. A case of endometrial stromal sarcoma with curvilinear calcification. *Gynecologic Oncology* 2005; **98**: 318-321.
- 59) Perez-Montiel D, Salmeron AA, Dominquez Malagon H. Multicystic Endometrial Stromal Sarcoma. *Ann Diagn Pathol* 2004; **8**: 213-218.
- 60) Somma A, Falletti J, Di Simone D, Marra A, Nazzaro G, Miranda M, Insabato L. Cystic Variant of Endometrial Stromal Sarcoma: Report of Two Cases. *Int J Surgl Pathol* 2012; **21**: 278-281.
- 61) Toprak U, Pasaoglu E, Karademir A, Gülbay M. Sonographic, CT, and MRI Findings of Endometrial Stromal Sarcoma Located in the Myometrium and Associated with Peritoneal Inclusion Cyst. *AJR* 2004; **182**: 1531-1533.

- 62) Bonneau C, Thomassin-Naggara I, Dechoux S, Cortez A, Darai E, Rouzier R. Value of ultrasonography and magnetic resonance imaging for the characterization of uterine mesenchymal tumors. *Acta Obstet Gynecol Scand* 2014; **93**: 261–268.
- 63) Kliwer MA, Hertzberg BS, George PY, McDonald JW, Bowie JD, Carroll BA. Acoustic shadowing from uterine leiomyomas: sonographic-pathologic correlation. *Radiology* 1995; **196**: 99 – 102.
- 64) Dueholm M. Transvaginal ultrasound for diagnosis of adenomyosis: a review. *Best Pract Res Clin Obstet Gynaecol* 2006; **20**: 569 – 582.
- 65) Amant F, Coosemans A, Debiec-Rychter M, Timmerman D, Vergote I. Clinical management of uterine sarcomas. *Lancet Oncol* 2009; **10**: 1188-1198.
- 66) Santos P, Cunha TM. Uterine sarcomas: clinical presentation and MRI features. *Diagn Interv Radiol* 2015; **21**: 4-9.
- 67) Zikan M, Fischerova D, Pinkavova I, Dundr P, Cibula D. Ultrasonographic appearance of metastatic non-gynecological pelvic tumors. *Ultrasound Obstet Gynecol* 2012; **39**: 215–225.
- 68) Food and Drug Administration. Laparoscopic Uterine Power Morcellation in Hysterectomy and Myomectomy: FDA Safety Communication (US); 2014 April.

Figure legends

Figure 1. Ultrasound variables with their categories illustrated by schematic drawings (a) and ultrasound images (b) used during the consensus meeting.

Low level cyst fluid is illustrated by showing an image of an ovarian cyst circumferential color score 3 is illustrated by drawing on top of the ultrasound image.

Figure 2. Images of a leiomyosarcoma (a), and an undifferentiated endometrial sarcoma (b) showing “cooked appearance of the solid tissue”, i.e. lack of structure of the solid tissue of the tumor and absence of shadowing.

Figure 3. Images showing ultrasound features of uterine sarcomas. According to the assessment by the original examiner, there was normal visible myometrium in 149/195 (76.4%) cases (a,c) (yellow arrows), 152/195 (77.9%) of the sarcomas manifested inhomogenous echogenicity of the solid tissue (a,b,d), 87/195 (44.6%) contained cystic areas (c), 103/195 (52.8%) had irregular tumor borders (b), and 127/187 (67.9%) manifested moderate or rich vascularization (d).

Figure 4 Gray-scale ultrasound images of three leiomyosarcomas (a,b,c) with the corresponding color or power Doppler images: rich (d), moderate (e) and minimal vascularization (f).

Figure 5 Gray-scale ultrasound images of three endometrial stromal sarcomas (a,b,c) with the corresponding color or power Doppler images: moderate (d,e) and minimal vascularization (f).

Figure 6 Gray-scale ultrasound images of three undifferentiated endometrial sarcomas (a,b,c) with the corresponding color or power Doppler images: rich (d,e), and minimal vascularization (f).

Table 1 Clinical characteristics of 195 patients with uterine sarcomas

Characteristics	All n=195	Leiomyosarcomas n= 116	Endometrial stromal sarcomas n= 48	Undifferentiated endometrial sarcomas n= 31
Age at diagnosis, years	56 (26-86)	57 (30-86)	46 (26-79)	60 (28-84)
Nulliparous	50 (25.6)	27 (23.3)	15 (31.3)	8 (25.8)
Premenopausal	84 (43.1)	47 (40.5)	32 (66.7)	5 (16.1)
Current hormonal therapy ^a	26/185 (14.1)	16/109 (14.6)	5/47 (10.6)	5/29 (17.2)
Previous pelvic radiation ^b	1/186 (0.5)	1/109 (0.9)	0/48 (0)	0/29 (0)
Symptoms ^c				
Asymptomatic	19/183 (10.4)	12/107 (11.2)	5/46 (10.9)	2/30 (6.7)
Abnormal bleeding	91/183 (49.7)	42/107 (39.3)	28/46 (60.9)	21/30 (70.0)
Abdominal pain	30/183 (16.4)	19/107 (17.8)	8/46 (17.4)	3/30 (10.0)
Abdominal distension	15/183 (8.2)	13/107 (12.1)	0/46 (0)	2/30 (6.7)
Mass detected at other imaging	7/183 (3.8)	3/107 (2.8)	2/46 (4.3)	2/30 (6.7)
Self palpated mass	3/183 (1.6)	3/107 (2.8)	0/46 (0)	0/30 (0)
More than one of the above symptoms	14/183 (7.7)	11/107 (10.3)	3/46 (6.5)	0/30 (0)
Other	4/183 (2.2)	4/107 (3.7)	0/46 (0)	0/30 (0)
FIGO Stage ^d				
I	120/188 (63.8)	65/110 (59.0)	39/48 (81.2)	16/30 (53.3)
II	12/188 (6.4)	7/110 (6.4)	3/48 (6.3)	2/30 (6.7)
III	22/188 (11.7)	17/110 (15.5)	2/48 (4.2)	3/30 (10.0)
IV	34/188 (18.1)	21/110 (19.1)	4/48 (8.3)	9/30 (30.0)

Results are presented as n (%) or median (range).

^a Information available for 185 patients: 109 patients with leiomyosarcoma, 47 patients with endometrial sarcoma and 29 patients with undifferentiated endometrial sarcoma.

^b Information available for 186 patients: 109 patients with leiomyosarcoma, 48 patients with endometrial sarcoma and 29 patients with undifferentiated endometrial sarcoma.

^c Information available for 183 patients: 107 patients with leiomyosarcoma, 46 patients with endometrial sarcoma and 30 patients with undifferentiated endometrial sarcoma.

^d Information available for 188 patients: 110 patients with leiomyosarcoma, 48 patients with endometrial sarcoma and 30 patients with undifferentiated endometrial sarcoma.

Table 2 Ultrasound characteristics of uterine sarcomas according the original ultrasound examiner's report, and prevalence of ultrasound characteristics when ultrasound images were judged retrospectively by 16 experienced ultrasound examiners in a consensus meeting

Characteristics	All		Leiomyosarcomas		Endometrial stromal sarcomas		Undifferentiated endometrial sarcomas	
	Original examiner	Consensus meeting, prevalence*	Original examiner	Consensus meeting, prevalence*	Original examiner	Consensus meeting, prevalence*	Original examiner	Consensus meeting, prevalence*
	n= 195	n= 152 Total ratings= 2110	n= 116	n= 92 Total ratings= 1284	n= 48	n= 33 Total ratings= 454	n= 31	n= 27 Total ratings= 372
Modality of scan								
Vaginal	93 (47.7)	-	46 (39.7)	-	33 (68.8)	-	14 (45.2)	-
Vaginal and abdominal	100 (51.3)	-	69 (59.5)	-	15 (31.3)	-	16 (51.6)	-
Rectal and abdominal	2 (1.0)	-	1 (0.9)	-	0 (0)	-	1 (3.2)	-
Largest diameter of lesion, mm	91 (7-321)	-	106 (30-321)	-	68 (12-210)	-	70 (7-250)	-
Visible normal myometrium								
Yes	149 (76.4)	1128 (53.5)	81 (69.8)	599 (46.7)	44 (91.7)	299 (65.9)	24 (77.4)	230 (61.8)
No	46 (23.6)	809 (38.3)	35 (30.2)	577 (44.9)	4 (8.3)	128 (28.2)	7 (22.6)	104 (28)
Impossible to say	-	136 (6.4)	-	83 (6.5)	-	22 (4.8)	-	31 (8.3)
Not assessable	-	37 (1.8)	-	25 (1.9)	-	5 (1.1)	-	7 (1.9)
Type of tumor								
Multilocular	1 (0.5)	-	0 (0)	-	0 (0)	-	1 (3.2)	-
Multilocular-solid	16 (8.2)	-	12 (10.3)	-	3 (6.3)	-	1 (3.2)	-
Solid	155 (79.5)	-	85 (73.3)	-	43 (89.5)	-	27 (87.1)	-
No (reliable) information	23 (11.8)	-	19 (16.4)	-	2 (4.2)	-	2 (6.5)	-
Echogenicity of solid tissue								
Homogeneous	43 (22.1)	158/2110 (7.5)	22 (19)	68/1284 (5.3)	14 (29.2)	42/454 (9.3)	7 (22.6)	48/372 (12.9)
Inhomogeneous	151 (77.4)	1925/2110 (91.2)	94 (81)	1211/1284 (94.3)	34 (70.8)	406/454 (89.4)	23 (74.2)	308/372 (82.8)
Impossible to say	-	16/2110 (0.8)	-	2/1284 (0.2)	-	2/454 (0.4)	-	12/372 (3.2)
Not assessable (no solid tissue)	1 (0.5)	11/2110 (0.5)	0 (0)	3/1284 (0.2)	0 (0)	4/454 (0.9)	1 (3.2)	4/372 (1.1)

Table 2 Ultrasound characteristics of uterine sarcomas according the original ultrasound examiner's report, and prevalence of ultrasound characteristics when ultrasound images were judged retrospectively by 16 experienced ultrasound examiners in a consensus meeting

Characteristics	All		Leiomyosarcomas		Endometrial stromal sarcomas		Undifferentiated endometrial sarcomas	
	Original examiner	Consensus meeting, prevalence*	Original examiner	Consensus meeting, prevalence*	Original examiner	Consensus meeting, prevalence*	Original examiner	Consensus meeting, prevalence*
	n= 195	n= 152 Total ratings= 2110	n= 116	n= 92 Total ratings= 1284	n= 48	n= 33 Total ratings= 454	n= 31	n= 27 Total ratings= 372
<i>Cystic areas</i>								
Yes	87 (44.6)	1155 (54.7)	54 (46.6)	746 (58.1)	18 (37.5)	239 (52.6)	15 (48.4)	170 (45.7)
No	108 (55.4)	902 (42.7)	62 (53.4)	512 (39.9)	30 (62.5)	208 (45.8)	16 (51.6)	182 (48.9)
Impossible to say	-	37 (1.8)	-	18 (1.4)	-	4 (0.9)	-	15 (4.0)
Not assessable	-	16 (0.8)	-	8 (0.6)	-	3 (0.7)	-	5 (1.3) (cont.)
<i>Cystic area walls if cystic areas were present</i>								
Regular	20 (23.0)	202 (17.5)	10 (18.5)	133 (17.8)	7 (38.9)	40 (16.7)	3 (20.0)	29 (17.1)
Irregular	67 (77.0)	935 (81.0)	44 (81.5)	602 (80.7)	11 (61.1)	194 (81.2)	12 (80.0)	139 (81.8)
Impossible to say	-	16 (1.4)	-	11 (1.5)	-	3 (1.3)	-	2 (1.2)
Not assessable	-	2 (0.2)	-	0 (0)	-	2 (0.8)	-	0 (0)
<i>Echogenicity of cystic content</i>								
Anechoic	43 (49.4)	484 (41.9)	26 (48.1)	305 (40.9)	9 (50.0)	117 (49.0)	8 (53.3)	62 (36.5)
Low level	23 (26.4)	255 (22.1)	18 (33.3)	150 (20.1)	4 (22.2)	52 (21.8)	1 (6.7)	53 (31.2)
Haemorrhagic	9 (10.3)	27 (2.3)	4 (7.4)	20 (2.7)	2 (11.1)	6 (2.5)	3 (20.0)	1 (0.6)
Ground glass	11 (12.6)	95 (8.2)	6 (11.1)	67 (9)	2 (11.1)	11 (4.6)	3 (20.0)	17 (10.0)
Other	1 (1.2)	-	0 (0)	-	1 (5.6)	-	0 (0)	-
Mixed	-	122 (10.6)	-	83 (11.1)	-	19 (7.9)	-	20 (11.8)
Variable	-	163 (14.1)	-	115 (15.4)	-	32 (13.4)	-	16 (9.4)
Impossible to say	-	7 (0.6)	-	5 (0.7)	-	1 (0.4)	-	1 (0.6)
Not assessable	-	2 (0.2)	-	1 (0.1)	-	1 (0.4)	-	0 (0)

Table 2 Ultrasound characteristics of uterine sarcomas according the original ultrasound examiner's report, and prevalence of ultrasound characteristics when ultrasound images were judged retrospectively by 16 experienced ultrasound examiners in a consensus meeting

Characteristics	All		Leiomyosarcomas		Endometrial stromal sarcomas		Undifferentiated endometrial sarcomas	
	Original examiner	Consensus meeting, prevalence*	Original examiner	Consensus meeting, prevalence*	Original examiner	Consensus meeting, prevalence*	Original examiner	Consensus meeting, prevalence*
	n= 195	n= 152 Total ratings= 2110	n= 116	n= 92 Total ratings= 1284	n= 48	n= 33 Total ratings= 454	n= 31	n= 27 Total ratings= 372
Shadowing								
No shadowing	146 (74.9)	1306 (61.9)	82 (70.7)	746 (58.1)	37 (77.1)	276 (60.8)	27 (87.1)	284 (76.3)
Internal shadows	42 (21.5)	517 (24.5)	32 (27.6)	371 (28.9)	8 (16.7)	100 (22.0)	2 (6.5)	46 (12.4)
Fan shaped shadowing	4 (2.1)	247 (11.7)	1 (0.9)	152 (11.8)	2 (4.2)	69 (15.2)	1 (3.2)	26 (7.0)
No (reliable) information	3 (1.5)	-	1 (0.9)	-	1 (2.1)	-	1 (3.2)	-
Impossible to say	-	24 (1.1)	-	11 (0.9)	-	2 (0.4)	-	11 (3.0)
Not assessable	-	16 (0.8)	-	4 (0.3)	-	7 (1.5)	-	5 (1.3)
Calcification								
Yes	18 (9.2)	172 (8.2)	12 (10.3)	116 (9)	4 (8.3)	30 (6.6)	2 (6.5)	26 (7.0) (cont.)
No	163 (83.6)	1907 (90.4)	97 (83.6)	1157 (90.1)	40 (83.3)	418 (92.1)	26 (83.9)	332 (89.2)
No (reliable) information	14 (7.2)	-	7 (6.0)	-	4 (8.3)	-	3 (9.7)	-
Impossible to say	-	18 (0.9)	-	7 (0.5)	-	2 (0.4)	-	9 (2.4)
Not assessable	-	13 (0.6)	-	4 (0.3)	-	4 (0.9)	-	5 (1.3)
Tumor border								
Regular	91 (46.7)	685 (32.5)	55 (47.4)	411 (32)	29 (60.4)	173 (38.1)	7/31 (22.6)	101 (27.2)
Irregular	103 (52.8)	1310 (62.1)	61 (52.6)	807 (62.9)	19 (39.6)	265 (58.4)	23/31 (74.2)	238 (64)
Impossible to say	1 (0.5)	95 (4.5)	0 (0)	57 (4.4)	0 (0)	8 (1.8)	1/31 (3.2)	30 (8.1)
Not assessable	-	20 (0.9)	-	9 (0.7)	-	8 (1.8)	-	3 (0.8)
Cooked appearance								
Yes	-	457 (21.7)	-	317 (24.7)	-	62 (13.7)	-	78 (21.0)

Table 2 Ultrasound characteristics of uterine sarcomas according the original ultrasound examiner's report, and prevalence of ultrasound characteristics when ultrasound images were judged retrospectively by 16 experienced ultrasound examiners in a consensus meeting

Characteristics	All		Leiomyosarcomas		Endometrial stromal sarcomas		Undifferentiated endometrial sarcomas	
	Original examiner	Consensus meeting, prevalence*	Original examiner	Consensus meeting, prevalence*	Original examiner	Consensus meeting, prevalence*	Original examiner	Consensus meeting, prevalence*
	n= 195	n= 152 Total ratings= 2110	n= 116	n= 92 Total ratings= 1284	n= 48	n= 33 Total ratings= 454	n= 31	n= 27 Total ratings= 372
No	-	1221 (57.9)	-	709 (55.2)	-	316 (69.6)	-	196 (52.7)
Impossible to say	-	373 (17.7)	-	226 (17.6)	-	57 (12.6)	-	90 (24.2)
Not assessable	-	59 (2.8)	-	32 (2.5)	-	19 (4.2)	-	8 (2.2)
Color score								
1	6 (3.1)	-	5 (4.3)	-	1 (2.1)	-	0 (0)	-
2	54 (27.7)	-	27 (23.3)	-	19 (39.6)	-	8 (25.8)	-
3	73 (37.4)	-	45 (38.8)	-	16 (33.3)	-	12 (38.7)	-
4	54 (27.7)	-	34 (29.3)	-	11 (22.9)	-	9 (29.0)	-
No (reliable) information	8 (4.1)	-	5 (4.3)	-	1 (2.1)	-	2 (6.5)	-
Circumferential color score								
1/2 (Absent or minimal)	-	820 (38.9)	-	498 (38.8)	-	181 (39.9)	-	141 (37.9)
3/4 (Moderate or abundant)	-	834 (39.5)	-	524 (40.8)	-	209 (46.0)	-	101 (27.2)
Impossible to say	-	97 (4.6)	-	53 (4.1)	-	12 (2.6)	-	32 (8.6)
Not assessable	-	359 (17.0)	-	209 (16.3)	-	52 (11.5)	-	98 (26.3) (cont.)
Internal color score								
1/2 (Absent or minimal)	-	728 (34.5)	-	456 (35.5)	-	169 (37.2)	-	103 (27.7)
3/4 (Moderate or abundant)	-	1117 (52.9)	-	707 (55.1)	-	239 (52.6)	-	171 (46.0)
Impossible to say	-	26 (1.2)	-	11 (0.9)	-	0 (0)	-	15 (4.0)
Not assessable	-	239 (11.3)	-	110 (8.6)	-	46 (10.1)	-	83 (22.3)

Table 2 Ultrasound characteristics of uterine sarcomas according the original ultrasound examiner's report, and prevalence of ultrasound characteristics when ultrasound images were judged retrospectively by 16 experienced ultrasound examiners in a consensus meeting

Characteristics	All		Leiomyosarcomas		Endometrial stromal sarcomas		Undifferentiated endometrial sarcomas	
	Original examiner	Consensus meeting, prevalence*	Original examiner	Consensus meeting, prevalence*	Original examiner	Consensus meeting, prevalence*	Original examiner	Consensus meeting, prevalence*
	n= 195	n= 152 Total ratings= 2110	n= 116	n= 92 Total ratings= 1284	n= 48	n= 33 Total ratings= 454	n= 31	n= 27 Total ratings= 372
<i>Is the lesion typical of a benign myoma?</i>								
Yes	28 (14.4)	178 (8.4)	18 (15.5)	106 (8.3)	9 (18.8)	50 (11.0)	1 (3.2)	22 (5.9)
No	167 (85.6)	1833 (86.9)	98 (84.5)	1117 (87)	39 (81.3)	385 (84.8)	30 (96.8)	331 (89.0)
Impossible to say	-	89 (4.2)	-	58 (4.5)	-	16 (3.5)	-	15 (4.0)
Not assessable	-	10 (0.5)	-	3 (0.2)	-	3 (0.7)	-	4 (1.1)
<i>Endometrial cavity</i>								
Clearly visualized	93 (47.7)	-	54 (46.6)	-	27 (56.3)	-	12 (38.7)	-
Not clearly visualized	99 (50.8)	-	59 (50.9)	-	21 (43.8)	-	19 (61.3)	-
No reliable information	3 (1.5)	-	3 (2.6)	-	0 (0)	-	0 (0)	-
<i>Ultrasound signs of other lesions typical of benign myoma</i>								
Yes	39 (20.0)	-	22 (19.0)	-	13 (27.1)	-	4 (12.9)	-
No	156 (80.0)	-	94 (81.0)	-	35 (72.9)	-	27 (87.1)	-
<i>Free fluid in Douglas pouch</i>								
Yes	13 (6.7)	-	8 (6.9)	-	2 (4.2)	-	3 (9.7)	-
No	182 (93.3)	-	108 (93.1)	-	46 (95.8)	-	28 (90.3)	-
<i>Ascites</i>								
Yes	4 (2.1)	-	3 (2.6)	-	1 (2.1)	-	0 (0)	-
No	191 (97.9)	-	113 (97.4)	-	47 (97.9)	-	31 (100)	- (cont.)

Table 2 Ultrasound characteristics of uterine sarcomas according the original ultrasound examiner's report, and prevalence of ultrasound characteristics when ultrasound images were judged retrospectively by 16 experienced ultrasound examiners in a consensus meeting

Characteristics	All		Leiomyosarcomas		Endometrial stromal sarcomas		Undifferentiated endometrial sarcomas	
	Original examiner	Consensus meeting, prevalence*	Original examiner	Consensus meeting, prevalence*	Original examiner	Consensus meeting, prevalence*	Original examiner	Consensus meeting, prevalence*
	n= 195	n= 152 Total ratings= 2110	n= 116	n= 92 Total ratings= 1284	n= 48	n= 33 Total ratings= 454	n= 31	n= 27 Total ratings= 372
<i>Diagnosis on the basis of subjective assessment</i>								
Clearly malignant	92 (47.2)	-	60 (51.7)	-	11 (22.9)	-	21 (67.7)	-
Malignancy can not be excluded	61 (31.3)	-	30 (25.9)	-	23 (47.9)	-	8 (25.8)	-
Benign	40 (20.5)	-	26 (22.4)	-	13 (27.1)	-	1 (3.2)	-
No reliable information	2 (1.0)	-	0 (0)	-	1 (2.1)	-	1 (3.2)	-

Results are presented as n (%) or median (range).

* The overall prevalence of a category was calculated as the percentage of times that the category was noted by all examiners relative to the total number of ratings:

10 patients * 16 raters= 160; 114 patients * 14 raters= 1596; 23 patients *13 raters= 299; 5 patients *11 raters= 55. Total= 2110 for all cases.

10 patients * 16 raters= 160; 64 patients * 14 raters= 896; 15 patients *13 raters= 195; 3 patients *11 raters= 33. Total=1284 for leiomyosarcoma cases.

29 patients * 14 raters= 406; 2 patients *13 raters= 26; 2 patients *11 raters= 22. Total= 454 for endometrial stromal sarcoma cases.

21 patients * 14 raters= 294; 6 patients *13 raters= 78; Total= 372 for undifferentiated endometrial sarcoma cases.

Table 2 Ultrasound characteristics of uterine sarcomas according the original ultrasound examiner's report, and prevalence of ultrasound characteristics when ultrasound images were judged retrospectively by 16 experienced ultrasound examiners in a consensus meeting

Characteristics	All		Leiomyosarcomas		Endometrial stromal sarcomas		Undifferentiated endometrial sarcomas	
	Original examiner	Consensus meeting, prevalence*	Original examiner	Consensus meeting, prevalence*	Original examiner	Consensus meeting, prevalence*	Original examiner	Consensus meeting, prevalence*
	n= 195	n= 152 Total ratings= 2110	n= 116	n= 92 Total ratings= 1284	n= 48	n= 33 Total ratings= 454	n= 31	n= 27 Total ratings= 372

Table 3 Ultrasound characteristics of uterine sarcomas classified as benign or malignant according to the subjective assessment of the original examiner

Characteristics	Cases with benign subjective assessment at ultrasound examination n=40	Cases with malignant subjective assessment at ultrasound examination n=153
Modality of scan		
Vaginal	27 (67.5)	65 (42.5)
Vaginal and abdominal	13 (32.5)	86 (56.2)
Rectal and abdominal	0 (0)	2 (1.3)
Largest diameter of lesion, mm	71 (12-250)	96 (7-321)
Visible normal myometrium		
Yes	36 (90.0)	111 (72.5)
No	4 (10.0)	42 (27.5)
Type of tumor		
Multilocular	0 (0)	1 (0.7)
Multilocular-solid	2 (5.0)	14 (9.2)
Solid	31 (77.5)	122 (79.7)
No (reliable) information	7 (17.5)	16 (10.5)
Echogenicity of solid tissue		
Homogeneous	22 (55.0)	21 (13.7)
Inhomogeneous	18 (45.0)	131 (85.6)
Not assessable (no solid tissue)	0 (0)	1 (0.7)
Cystic areas		
Yes	8 (20.0)	79 (51.6)
No	32 (80.0)	74 (48.4)
Cystic area walls if cystic areas were present		
Regular	3/8 (37.5)	17/79 (21.5)
Irregular	5/8 (62.5)	62/79 (78.5)
Echogenicity of cystic content		
Anechoic	5/8 (62.5)	38/79 (48.1)
Low level	3/8 (37.5)	20/79 (25.3)
Haemorrhagic	0/8 (0)	9/79 (11.4)
Ground glass	0/8 (0)	11/79 (13.9)
Other	0/8 (0)	1/79 (1.3)
Shadowing		
No shadowing	30 (75.0)	115 (75.2)
Internal shadows	10 (25.0)	31 (20.3)
“Rain in the forest” sign/ Shadowing fan shaped	0 (0)	4 (2.6)
No (reliable) information	0 (0)	3 (2.0)
Calcification		
Yes	5 (12.5)	13 (8.5)
No	35 (87.5)	126 (82.4)
No (reliable) information	0 (0)	14 (9.2)
Tumor border		
Regular	30 (75.0)	61 (39.9)
Irregular	10 (25.0)	91 (59.5)
Impossible to say	0 (0)	1 (0.7)
Color score		
1	4 (10.0)	2 (1.3)

Table 3 Ultrasound characteristics of uterine sarcomas classified as benign or malignant according to the subjective assessment of the original examiner

Characteristics	Cases with benign subjective assessment at ultrasound examination n=40	Cases with malignant subjective assessment at ultrasound examination n=153
2	18 (45.0)	36 (23.5)
3	8 (20.0)	63 (41.2)
4	5 (12.5)	49 (32.0)
No (reliable) information	5 (12.5)	3 (2.0)
<i>Is the lesion typical of a benign myoma?</i>		(cont.)
Yes	24 (60.0)	4 (2.6)
No	16 (40.0)	149 (97.4)
<i>Endometrial cavity</i>		
Clearly visualized	28 (70.0)	65 (42.5)
Not clearly visualized	11 (27.5)	86 (56.2)
No reliable information	1 (2.5)	2 (1.3)
<i>Ultrasound signs of other lesions typical of benign myoma</i>		
Yes	11 (27.5)	28 (18.3)
No	29 (72.5)	125 (81.7)
<i>Free fluid in Douglas pouch</i>		
Yes	0 (0)	13 (8.5)
No	40 (100)	140 (91.5)
<i>Ascites</i>		
Yes	0 (0)	4 (2.6)
No	40 (100)	149 (97.4)

Results are presented as n (%) or median (range).

Table 4 Summary of published studies describing ultrasound features of uterine sarcomas




























Author (year)	Number of cases	Ultrasound mode used	Ultrasound findings
Hata 1997 ⁴⁹	4 leiomyosarcomas 1 mixed mesodermal tumor	Spectral Doppler	Peak Systolic Velocity (PSV) in sarcomas was significantly higher than in leiomyomas, Resistance Index (RI) was similar in sarcomas and leiomyomas.
Szabò 1997 ⁵¹	3 leiomyosarcomas 5 endometrial stromal sarcomas 4 mixed mesodermal tumors	Spectral Doppler	Both RI and PSV were significantly higher in leiomyomas than in uterine sarcomas.
Aviram 2005 ⁵⁰	6 leiomyosarcomas 7 mixed mesodermal tumors	Gray-scale and spectral Doppler	Ultrasound features of leiomyosarcomas were similar to those of leiomyomas. RI was significantly higher in leiomyomas than in sarcomas.
Exacoustos 2007 ⁴⁸	8 leiomyosarcomas	Gray-scale and color Doppler	Leiomyosarcomas were significantly larger (7/8 larger than 8 cm) than both leiomyomas and STUMPs. Cystic changes in 4/8 leiomyosarcomas. 7/8 leiomyosarcomas had a marked increase of central and peripheral vascularity, leiomyomas had mild to marked peripheral blood flow with little or absent central flow.
Adesiyun 2010 ⁵²	1 leiomyosarcoma	Gray-scale	Myometrium with multiple circumscribed heterogeneous masses, the largest mass 7.1 cm.
Bonneau 2014 ⁶²	3 leiomyosarcomas 1 rhabdomyosarcoma 2 endometrial stromal sarcomas 7 undifferentiated endometrial sarcomas 6 carcinosarcomas	Gray-scale and color Doppler	Single tumor, no acoustic shadowing, and thickened endometrium were typical ultrasound features of uterine sarcomas. On color Doppler examination, 4/10 tumors were highly vascularized.
Gandolfo 2000 ⁵⁴	2 endometrial stromal sarcomas	Gray-scale and color Doppler	Case 1 was a heterogeneous solid mass containing an isolated cystic component and a few venous flow signals on spectral Doppler Case 2 was a solid mass with mixed structure and detectable color Doppler signals
Pérez-Montiel 2004 ⁵⁹	1 endometrial stromal sarcoma	Gray-scale and color Doppler	Cystic lesion, 8 cm, smooth and well-defined borders, septae, anechoic echogenicity of cyst fluid, and peripheral vascularity.
Toprak 2004 ⁶¹	1 endometrial stromal sarcoma	Gray-scale	Myometrial complex cystic mass with smooth borders, nodular solid areas and cystic spaces with thick septations

Author (year)	Number of cases	Ultrasound mode used	Ultrasound findings
Pekindil 2005 ⁵⁸	1 endometrial stromal sarcoma	Gray-scale and color Doppler	Huge heterogeneous solid mass with cystic components and a curvilinear calcification. A few venous Doppler signals were detected centrally. The endometrium could not be visualized.
Kim 2006 ⁵⁶	10 endometrial stromal sarcomas	Gray-scale and color Doppler	Four ultrasound patterns were identified. <ol style="list-style-type: none"> 1. Polypoid mass protruding into the endometrial cavity (cont.) from the myometrium, with partially nodular margins and hypoechoic echotexture (3 cases). 2. Intramural mass with ill-defined margins and heterogeneous echotexture (1 case). 3. Intramural mass with smooth margins and heterogeneous echotexture (5 cases). 4. Central mass with ill-defined margins and septated cyst echotexture (1 case). Mean mass length 83.5 mm (range 38-160). Single lesion in 8/10 cases, multiple in 5/10 cases. Focal irregular vascularity in 5/10 cases
Gayakrishnan 2009 ⁵⁵	1 endometrial stromal sarcoma	Gray-scale and color Doppler	A well-defined hyperechoic lesion with cystic spaces, 6 cm, distorting the endometrial cavity but distinct from it. Increased vascularity on color Doppler.
Cho 2011 ⁵³	1 endometrial stromal sarcoma	Gray-scale and color Doppler	A 15-cm well-circumscribed multilocular-solid pelvic mass with a large cystic component. No vascularity on color Doppler
Somma 2012 ⁶⁰	1 endometrial stromal sarcoma	Gray-scale	A complex multicystic mass originating from the myometrium with solid and cystic areas separated by thick septae, 87 mm.
Park 2016 ⁵⁷	10 endometrial stromal sarcomas	Gray-scale	Four ultrasound patterns were identified: <ol style="list-style-type: none"> 1. Solid mass containing cystic areas (6 cases) 2. Unilocular cystic mass (1 case) 3. An ill-defined infiltrative solid mass mimicking adenomyosis (2 cases) 4. A well-defined solid mass (1 case) Largest diameters 4 to 9.1 cm (mean 6.2 cm). Well-defined, smooth margins in 6/10 cases, ill-defined margins in 4/10 cases. 7/10 tumors

Author (year)	Number of cases	Ultrasound mode used	Ultrasound findings
			had small or large internal cystic areas.

TUMP, Uterine smooth muscle tumor of uncertain malignant potential

ULTRASOUND FEATURES OF UTERINE SARCOMAS (fig 1a)

VISIBLE NORMAL MYOMETRIUM		yes (1) no (2)
ECHOGENICITY	 	homogeneous (1) inhomogeneous (2)
CYSTIC AREAS		yes (1) no (2)
CYSTIC AREA WALLS	 	regular (1) irregular (2)
CYST CONTENT	     	anechoic (1) low level (2) haemorrhagic (3) ground-glass(4) mixed (5) variable (6)
SHADOWING	  	no shadows (1) internal shadows (2) fan shaped shadowing (3)
CALCIFICATIONS		yes (1) no (2)
TUMOR BORDER	 	regular (1) irregular (2)
COOKED ASPECT		yes (1) no (2)
INTERNAL COLOR SCORE	   	1 2 3 4
CIRCUMFERENTIAL COLOR SCORE	   	1 2 3 4
DOES THE LESION LOOK LIKE A TYPICAL BENIGN MYOMA?	yes (1) no (2)	

ULTRASOUND FEATURES OF UTERINE SARCOMAS (fig 1b)






























VISIBLE NORMAL MYOMETRIUM			yes <input type="checkbox"/> no <input type="checkbox"/>				
ECHOGENICITY			homogeneous <input type="checkbox"/> inhomogeneous <input type="checkbox"/>				
CYSTIC AREAS			yes <input type="checkbox"/> no <input type="checkbox"/>				
CYSTIC AREA WALLS			regular <input type="checkbox"/> irregular <input type="checkbox"/>				
CYST CONTENT							anechoic <input type="checkbox"/> low level <input type="checkbox"/> haemorrhagic <input type="checkbox"/> ground-glass <input type="checkbox"/> mixed <input type="checkbox"/> variable <input type="checkbox"/>
SHADOWING				no shadows <input type="checkbox"/> internal shadowing <input type="checkbox"/> fan shaped shadowing <input type="checkbox"/>			
CALCIFICATIONS			yes <input type="checkbox"/> no <input type="checkbox"/>				
TUMOR BORDER			regular <input type="checkbox"/> irregular <input type="checkbox"/>				
COOKED ASPECT			yes <input type="checkbox"/> no <input type="checkbox"/>				
INTERNAL COLOR SCORE					1 <input type="checkbox"/> 2 <input type="checkbox"/> 3 <input type="checkbox"/> 4 <input type="checkbox"/>		
CIRCUMFERENTIAL COLOR SCORE					1 <input type="checkbox"/> 2 <input type="checkbox"/> 3 <input type="checkbox"/> 4 <input type="checkbox"/>		
DOES THE LESION LOOK LIKE A TYPICAL BENIGN MYOMA?			yes <input type="checkbox"/> no <input type="checkbox"/>				

Figure1

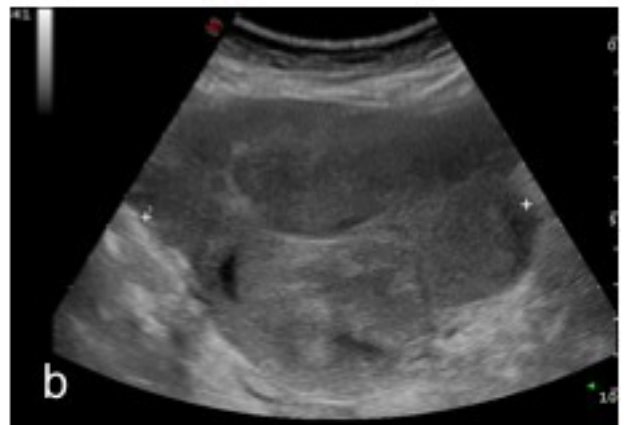
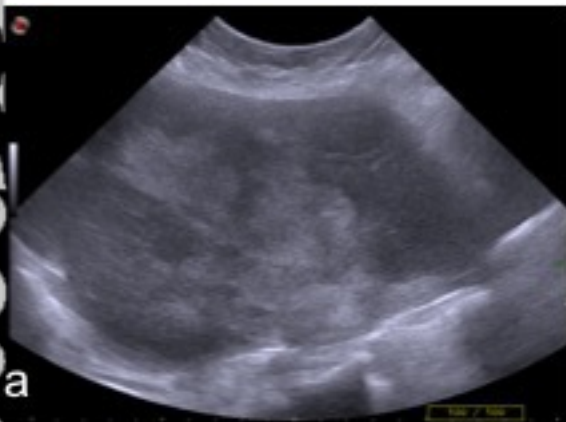


Figure2

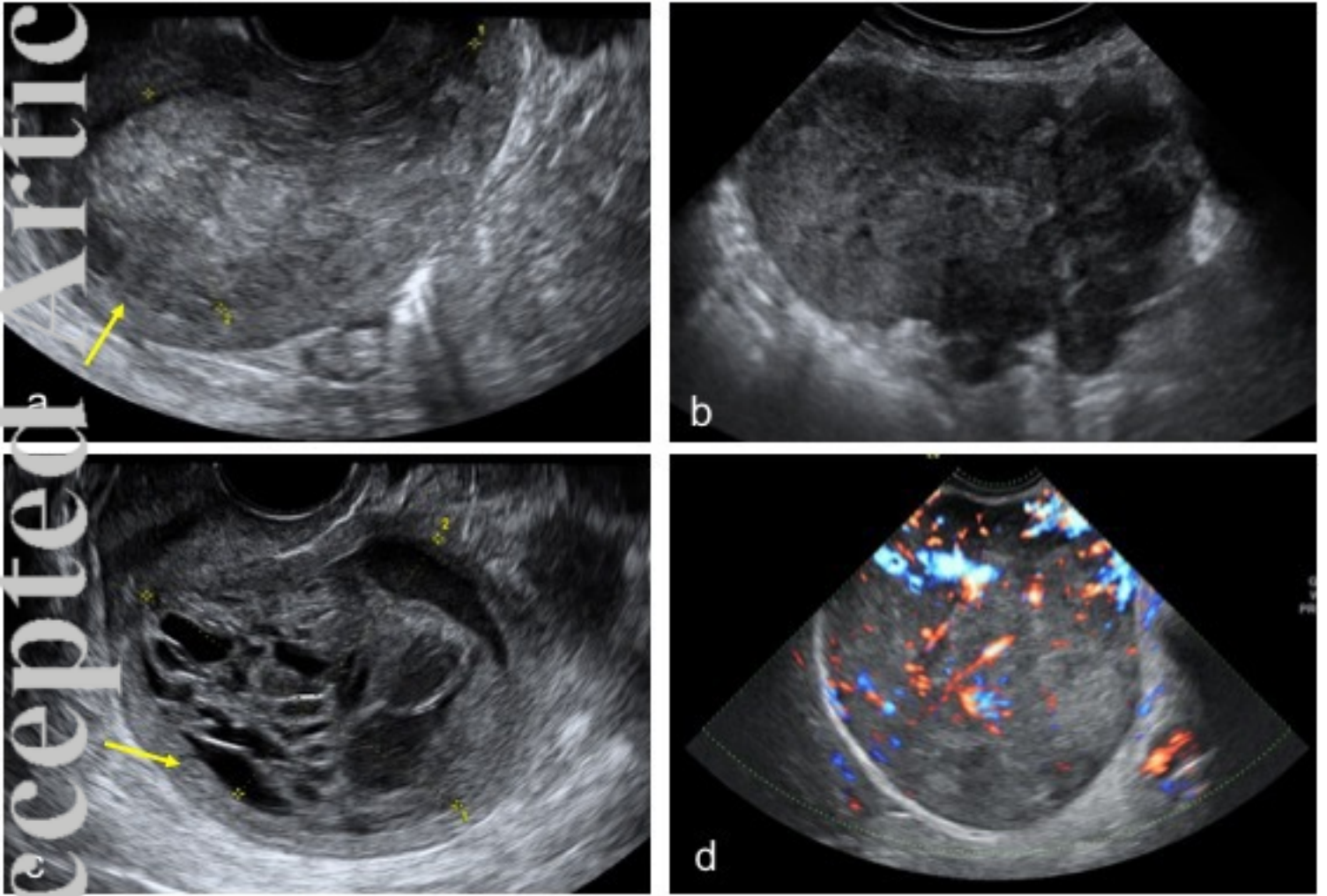


Figure3

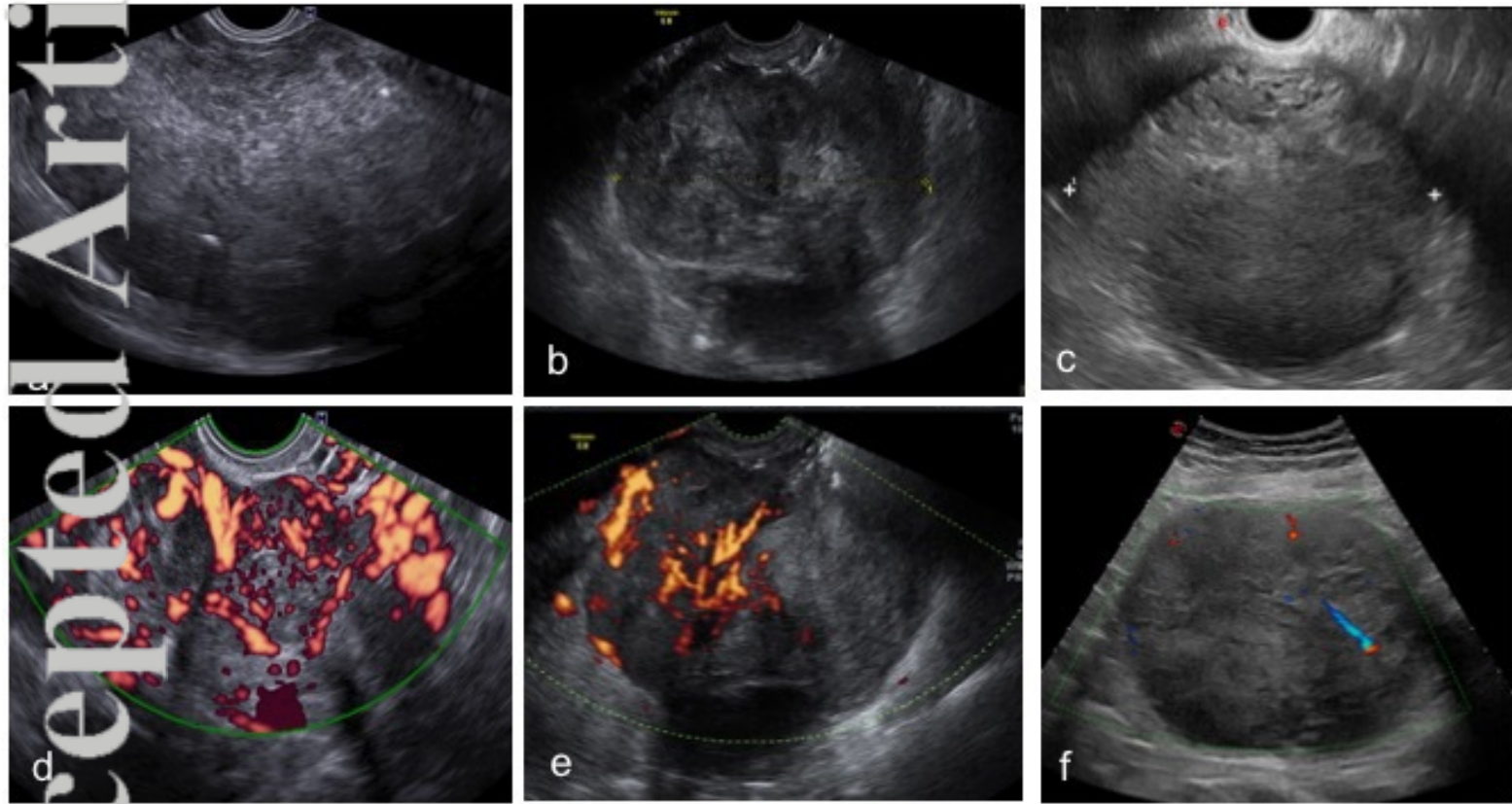


Figure4

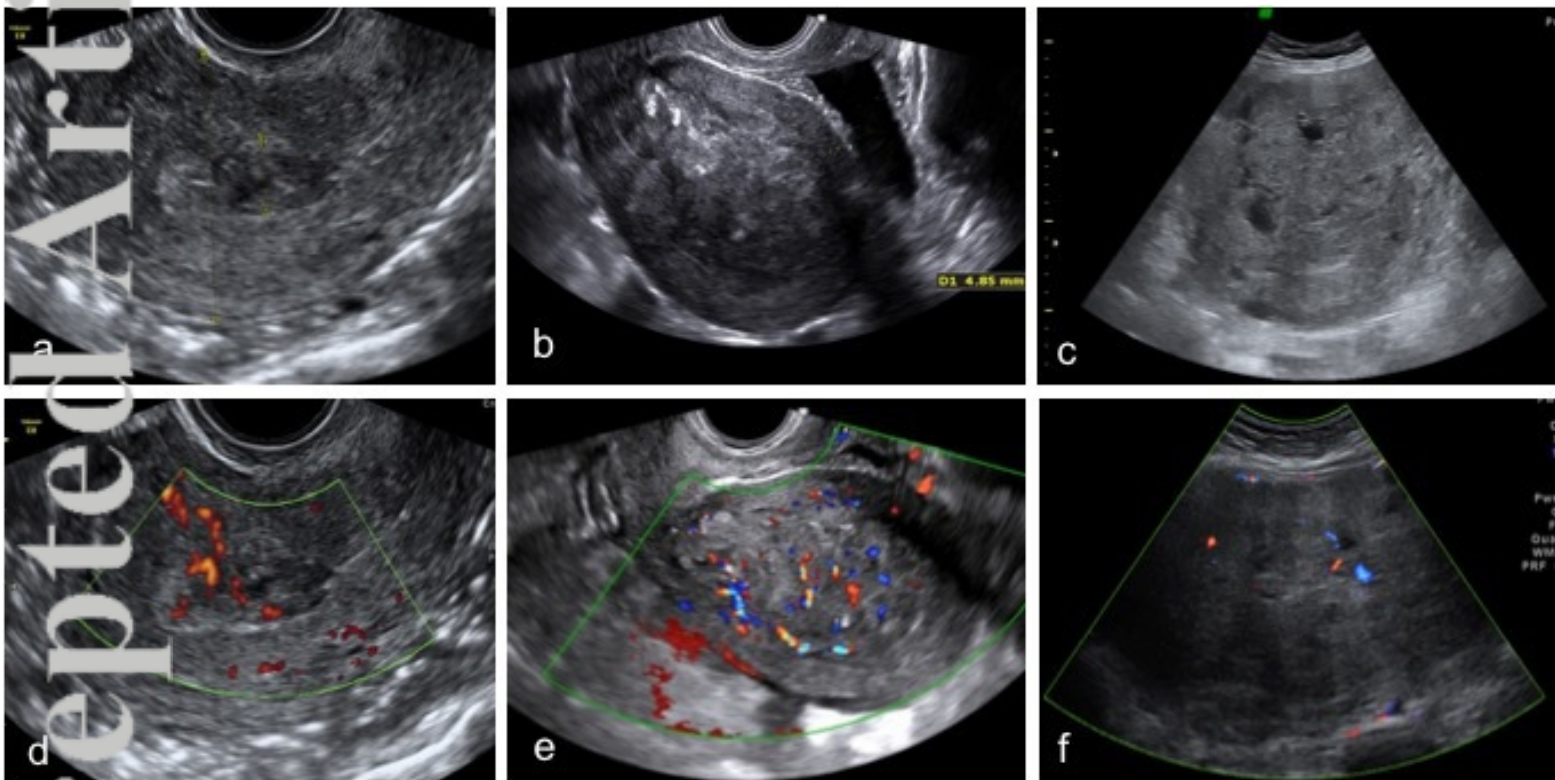


Figure5

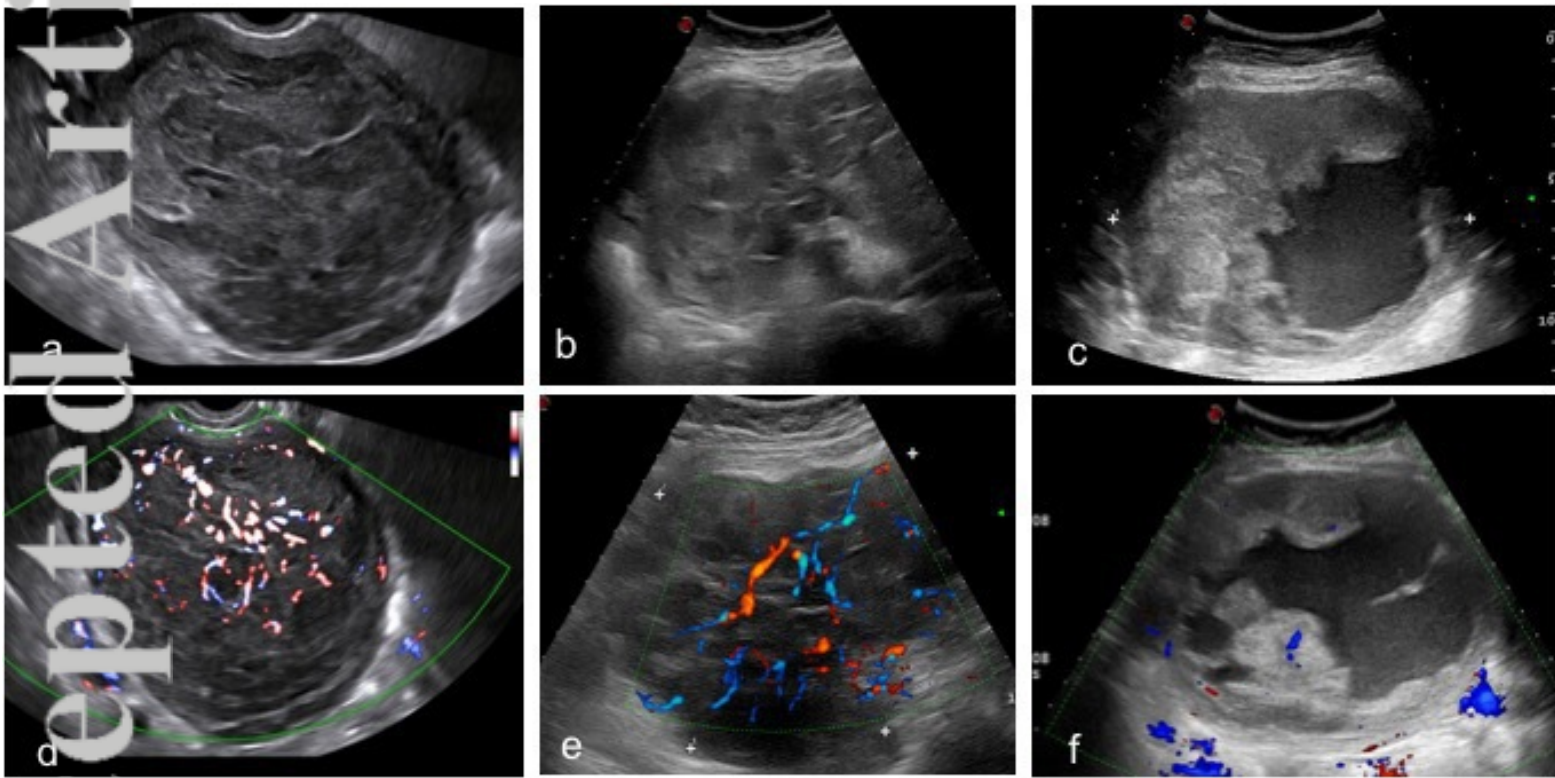


Figure6