

# Pure

Scotland's Rural College

## Fatal mycotic encephalitis in a Northern bottlenose whale (*Hyperoodon ampullatus*) caused by *Aspergillus fumigatus*

Foster, G; Dagleish, Mark P; Reid, RJ; Barley, JP; Howie, F

*Published in:*  
Veterinary Record

Print publication: 30/11/2008

[Link to publication](#)

### *Citation for published version (APA):*

Foster, G., Dagleish, M. P., Reid, R.J., Barley, J.P., & Howie, F. (2008). Fatal mycotic encephalitis in a Northern bottlenose whale (*Hyperoodon ampullatus*) caused by *Aspergillus fumigatus*. *Veterinary Record*, 163(20), 602-604.

### General rights

Copyright and moral rights for the publications made accessible in the public portal are retained by the authors and/or other copyright owners and it is a condition of accessing publications that users recognise and abide by the legal requirements associated with these rights.

- Users may download and print one copy of any publication from the public portal for the purpose of private study or research.
- You may not further distribute the material or use it for any profit-making activity or commercial gain
- You may freely distribute the URL identifying the publication in the public portal ?

### Take down policy

If you believe that this document breaches copyright please contact us providing details, and we will remove access to the work immediately and investigate your claim.

## Fatal mycotic encephalitis caused by *Aspergillus fumigatus* in a northern bottlenose whale (*Hyperoodon ampullatus*)

M. P. DAGLEISH, G. FOSTER, F. E. HOWIE, R. J. REID, J. BARLEY

THE northern bottlenose whale (*Hyperoodon ampullatus*) is a deep-diving species found in the North Atlantic Ocean and some of its adjacent seas, occurring in mainly cold temperate to subarctic waters. It is purported to be the most extensively studied of the beaked whales owing to its long history of commercial exploitation and a singularly intensive long-term study of live animals that commenced after whaling for this species was prohibited in 1977 (Santos and others 2001, Reeves and others 2002). Despite several reports of strandings, often with detailed descriptions of the stomach contents, no causes of death other than possible whaling injuries in one animal have been recorded (Mitchell and Kozicki 1975, Clarke and Kristensen 1980, Lick and Piatkowski 1998, Lucas and Hooker 2000, Santos and others 2001).

Mycoses in marine mammals, although considered rare, are being diagnosed and reported (Dagleish and others 2006, Barley and others 2007) with increasing frequency, and are critically important among the fatal infectious diseases as they may be indicative of underlying immunosuppression (Gedek and others 1993). Marine mammals are considered to be dead-end hosts for mycotic disease, such that transmission between conspecifics is thought to be extremely rare, despite two zoonotic infections from cetaceans having been reported (Geraci and Ridgway 1991). Pulmonary mycotic infections are the most commonly diagnosed, although other organs are also affected (Reidarson and others 1999). Although morbillivirus infection is a known cause of immunosuppression in many species (Heaney and others 2002), other putative aetiologies for immunosuppression in marine mammals include anthropogenic toxins (Ross 2002), heavy metals (Bennett and others 2001), concurrent disease, including parasitism, and malnutrition (Beineke and others 2005). This short communication describes an incident of fatal mycotic encephalitis caused by *Aspergillus fumigatus* in a northern bottlenose whale in Scotland.

A juvenile male northern bottlenose whale was seen circling and moribund in shallow water. It subsequently stranded and died shortly afterwards in right lateral recumbency at Craigton, North Kessock, on the east coast of Scotland, in October 2006. It was investigated as part of a UK strandings project.

The carcass was transported to Scottish Agricultural College Veterinary Services, Inverness, where postmortem examination was performed by a modification of a recognised protocol for cetaceans (Kuiken and Hartmann 1991). Samples of lung, liver, spleen, kidney, forebrain and mesenteric lymph node, and blood and swabs from the small and large intestine, rectum, and bronchial pus were stored at 4°C overnight before routine microbiological examination, as described previously by Dagleish and others (2006). Samples for histological examination (lung, liver, spleen, adrenal glands, kidney, urinary bladder, mesenteric lymph node, and skin from the flank and tail fluke) were fixed in

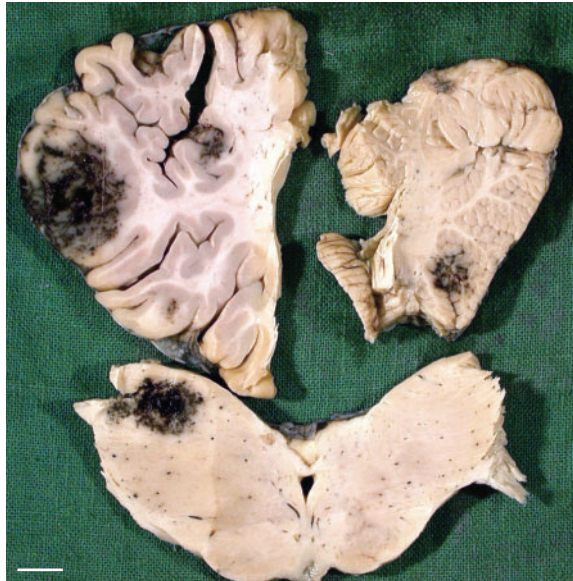

FIG 1: Coronal sections of the cerebrum (top left) and midbrain (bottom), both anterior views, and a sagittal section of the cerebellar vermis (top right) of a northern bottlenose whale (*Hyperoodon ampullatus*). There are roughly circular, poorly circumscribed areas of haemorrhage (black) in all three sections. Bar=1 cm

10 per cent formal saline, and the brain was fixed in 20 per cent formal saline. Coronal slices of fixed brain were made through the anterior pole of the cerebrum, corpus striatum, thalamus, occipital lobes, midbrain, cerebellar peduncles and three levels of the medulla, along with a sagittal section through the cerebellar vermis. Formal saline-fixed samples were routinely processed, embedded in paraffin wax, sectioned at 5 µm, mounted on glass microscope slides and stained with haematoxylin and eosin for histological examination. Selected brain sections were also subjected to the Grocott-Gomori methenamine silver (GGM) stain technique for fungi (Grocott 1955).

Gross postmortem examination revealed that the animal had died recently. There was no evidence of bloating or postmortem predator damage. The carcass was 483 cm long from the tip of the upper jaw to the tail notch, with a girth measurement immediately anterior to the dorsal fin of 244.0 cm. The weight of the carcass was unavailable, but it was in poor body condition, with dorsal, lateral and ventral midline blubber thicknesses immediately in front of the dorsal fin of 42 mm, 37 mm and 37 mm, respectively. Further examination revealed foul-smelling, yellow-green, tenacious, purulent material in the trachea and the airways of the left lung, the parenchyma of which was hyperaemic and oedematous, and sank when placed in fixative. The right lung was congested. The meninges of the brain were congested and a single focal, roughly circular area of haemorrhage approximately 2 cm in diameter was present immediately beneath the leptomeninges of the left cerebral hemisphere. The perirenal fat was depleted and gelatinous, and the coronary blood vessels were congested, as were the longissimus dorsi muscles, which were also atrophied. There was no evidence of sustainable feeding, with only vegetable matter and a few squid beaks present in the cardiac section of the stomach, and bile-stained fluid in the pyloric section of the stomach, duodenum and small intestine. On the skin of the tail fluke, multiple roughly circular lesions were present on the epidermis extending to various depths through the skin, all typical in appearance of poxvirus lesions in various stages of healing (Van Bresse and others 1999). The cortices of the adrenal glands appeared to be mildly enlarged. Sectioning of the brain revealed multiple roughly circular focal haemorrhagic lesions up to 3 cm in diameter with poorly defined margins throughout both the grey and white matter. Most were in the cerebrum but lesions were also present in the midbrain and the base of the cerebellum (Fig 1).

*Veterinary Record* (2008) 163, 602-604

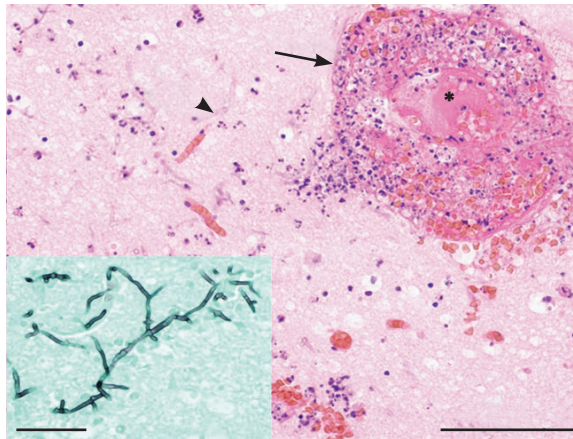
M. P. Dagleish, BVM&S, PhD, MRCVS, Moredun Research Institute, Pentlands Science Park, Bush Loan, Penicuik, Midlothian EH26 0PZ

G. Foster, CSci, FIBMS, R. J. Reid,

J. Barley, BVetMed, PhD, MRQA, MRCVS, Wildlife Unit, SAC Veterinary Services, Drummondhill, Stratherrick Road, Inverness IV2 4JZ

F. E. Howie, BVMS, MVM, FRCPath, MRCVS, SAC Veterinary Services, Bush Estate, Penicuik, Midlothian EH26 0QE

**FIG 2: Histological preparation of the cerebral cortex of a northern bottlenose whale (*Hyperoodon ampullatus*). Thrombosed blood vessel (\*) and surrounding thick cuff composed of polymorphonuclear neutrophils, haemorrhage and fibrin (arrow) and fungal hyphae in the neuropil (arrowhead) are visible. Haematoxylin and eosin. Bar=100 µm. Inset: Histological preparation of cerebral cortex showing the presence of septate dichotomously branching fungal hyphae, typical of *Aspergillus fumigatus*, in the neuropil. Grocott-Gomori methenamine silver. Bar=50 µm**



A profuse growth of *A. fumigatus*, two types of *Fusobacterium* species and mixed coliforms and pseudomonads was recovered from the purulent bronchial material. A scant growth of *A. fumigatus* was also recovered from the forebrain, but from no other tissues. Scant growths of mixed coliforms were recovered from the liver, spleen, blood, and small and large intestines. Profuse growths of *Morganella morganii*, *Photobacterium damsela* and *Eubacterium* species were recovered from the rectal swab. Cultures of the kidney and mesenteric lymph node showed no growth after 14 days. Histological examination of haematoxylin and eosin-stained sections confirmed the haemorrhagic nature of the lesions in the brain and also showed them to be predominantly suppurative. The polymorphonuclear neutrophils (PMNs) infiltrating the brain were highly heterogeneous in nature, with karyorrhexis, pyknotic and apoptotic nuclear morphologies all present. A severe vasculitis was present, with PMNs and fungal hyphae infiltrating the blood vessel walls (Fig 2), and many of the vessels were thrombosed. Most affected blood vessels were contained within well-delineated foci of malacia of varying size and severity. Serum leakage was prominent in the meninges and around some blood vessels in the thalamus, many of which were within large foci of malacic tissue. Examination of sections of brain stained with GGM enabled classification of the fungal hyphae as septate and dichotomously branching, consistent with *A. fumigatus* (Fig 2), and showed fungal hyphae to be present within the neuropil and not just adjacent to blood vessel walls. The lung was congested and partially collapsed. The liver was congested, and hepatocellular disorganisation and patchy portal fibrosis were present. Congestion and terminal degeneration were present in the kidney, and the mesenteric lymph node was fully populated and not reactive. No significant lesions were present in the heart, spleen or urinary bladder. The flank skin contained a focus of vesicle formation within the epidermis with associated epidermal collapse. Proteinaceous fluid and PMNs were present in the vesicles, and PMNs had also infiltrated the underlying dermis. In the tail fluke lesion, there was marked intercellular and intracellular oedema of the nuclear keratin layer, which was of uniform thickness on one side, with an area of full thickness epidermal necrosis and suppurative inflammation, but florid and irregular on the other, with oedema in the deeper layers of the dermis. These lesions are consistent with those reported for poxvirus infection in other cetaceans (Van Bressem and others 1999).

This description of severe mycotic encephalitis is the first report of a disease-related cause of death in a stranded northern bottlenose whale, despite the numerous accounts of previous strandings. Additionally, this is the first report of lesions typical of poxvirus in this species. Considering the number and extent of the lesions in the brain, the failure to detect fungal hyphae in any other tissue is remarkable, although the

profuse growth of *A. fumigatus* from the purulent material found in the airways of the left lung suggests that the pulmonary route may well have been the portal of entry to the body, followed by bloodborne dissemination to the brain. A similar pathogenesis has been postulated previously in a harbour porpoise with an intracranial granuloma caused by *A. fumigatus*, although this was associated with severe lung pathology including a heavy nematode parasite burden (Dagleish and others 2006), neither of which was found in the case described here. It is not clear whether the lack of observed lung pathology was due to a relatively small focus of fungal disease or the sampling of a relatively small part of the lungs. It is tempting to speculate that immunocompromise was likely on the basis of knowledge of aspergillosis in mammals (Gedek and others 1993). Although no pathology suggestive of an underlying immunosuppressive disease-related cause was found in this case, evaluation of virological aetiologies was not done due to a lack of availability to the authors of these specific diagnostic tests. However, the absence of sustained feeding, especially the presence of only a few squid beaks, and the poor body condition suggest that malnutrition may have played a role.

This report underlines the need for the application of careful selection criteria to live-stranded cetaceans with respect to re-floatation attempts, especially for those species that typically inhabit deep water (Dagleish and others 2007), as failure to do so may further compromise the welfare of animals already in distress. It also highlights the requirement for continued surveillance and thorough pathological examination of marine mammal fatalities, including detailed examination of the central nervous system, to determine whether immunocompromise-related disease incidence is truly increasing in marine mammals, especially since these animals are considered to be disease sentinels of both the marine and coastal environments.

## ACKNOWLEDGEMENTS

The authors would like to thank Clare Underwood (Moredun Research Institute) for preparation of histological sections and Dr David Buxton for constructive criticism of the manuscript. The Scottish Strandings Scheme, as part of the UK Cetacean Strandings Investigation Programme, is operated under contract to DEFRA, with financial support from the Scottish Executive's Environment and Rural Affairs Department, as a contribution to its coordinated programme of research on the North Sea. The project was funded by DEFRA (Ref M216/06).

## References

- BARLEY, J., FOSTER, G., REID, B., DAGLEISH, M. & HOWIE, F. (2007) Encephalitis in a northern bottlenose whale. *Veterinary Record* **160**, 452
- BEINEKE, A., SIEBERT, U., MCLACHLAN, M., BRUHN, R., THRON, K., FAILING, K., MÜLLER, G. & BAUMGÄRTNER, W. (2005) Investigations of the potential influence of environmental contaminants on the thymus and spleen of harbor porpoises (*Phocoena phocoena*). *Environmental Science and Technology* **39**, 3933-3938
- BENNETT, P. M., JEPSON, P. D., LAW, R. J., JONES, B. R., KUIKEN, T., BAKER, J. R., ROGAN, E. & KIRKWOOD, J. K. (2001) Exposure to heavy metals and infectious disease mortality in harbour porpoises from England and Wales. *Environmental Pollution* **112**, 33-40
- CLARKE, M. R. & KRISTENSEN, T. K. (1980) Cephalopod beaks from the stomachs of two northern bottlenosed whales (*Hyperoodon ampullatus*). *Journal of the Marine Biological Association of the United Kingdom* **60**, 151-156
- DAGLEISH, M. P., BARLEY, J., HOWIE, F. E., REID, R. J., HERMAN, J. & FOSTER, G. (2007) Isolation of *Brucella* species from a diseased atlanto-occipital joint of an Atlantic white-sided dolphin (*Lagenorhynchus acutus*). *Veterinary Record* **160**, 876-878
- DAGLEISH, M. P., PATTERSON, I. A. P., FOSTER, G., REID, R. J., LINTON,

- C. & BUXTON, D. (2006) Intracranial granuloma caused by asporogenic *Aspergillus fumigatus* in a harbour porpoise (*Phocoena phocoena*). *Veterinary Record* **159**, 458-460
- GEDEK, B., KAADEN, O. R., MAHNEL, H. & MAYR, A. (1993) Niedere Pilze. In *Medizinische Mikrobiologie, Infektions- und Seuchenlehre*. 6th edn. Ed A. Mayr. Stuttgart, Enke Verlag. pp 811-814
- GERACI, J. R. & RIDGWAY, S. H. (1991) On disease transmission between cetaceans and humans. *Marine Mammal Science* **7**, 191-194
- GROCOTT, R. G. (1955) A stain for fungi in tissue sections and smears using Gomori's methenamine-silver nitrate technic. *American Journal of Clinical Pathology* **25**, 975-979
- HEANEY, J., BARRETT, T. & COSBY, S. L. (2002) Inhibition of in vitro leukocyte proliferation by morbilliviruses. *Journal of Virology* **76**, 3579-3584
- KUIKEN, T. & HARTMANN, M. G. (1991) Dissection techniques and tissue sampling. Proceedings of the first ECS workshop on cetacean pathology. Leiden, The Netherlands, September 13 to 14, 1991. pp 1-39
- LICK, R. & PIATKOWSKI, U. (1998) Stomach contents of a northern bottlenose whale (*Hyperoodon ampullatus*) stranded at Hiddensee, Baltic sea. *Journal of the Marine Biological Association of the United Kingdom* **78**, 643-650
- LUCAS, Z. N. & HOOKER, S. K. (2000) Cetacean strandings on Sable Island, Nova Scotia, 1970-1998. *Canadian Field Naturalist* **114**, 45-61
- MITCHELL, E. D. & KOZICKI, V. M. (1975) Autumn stranding of a northern bottlenose whale (*Hyperoodon ampullatus*) in the Bay of Fundy, Nova Scotia. *Journal of the Fisheries Research Board of Canada* **32**, 1019-1040
- REEVES, R. R., STEWART, B. S., CLAPHAM, P. J. & POWELL, J. A. (2002) Northern bottlenose whale. In *Sea Mammals of the World: A Complete Guide to Whales, Dolphins, Seals, Sea Lions and Sea Cows*. 1st edn. London, A & C Black. pp 268-269
- REIDARSON, T. H., MCBAIN, J. F., DALTON, L. M. & RINALDI, M. G. (1999) Diagnosis and treatment of fungal infections in marine mammals. In *Zoo and Wild Animal Medicine Current Therapy*. 4th edn. Eds M. E. Fowler, R. E. Miller. London, W. B. Saunders. pp 478-485
- ROSS, P. S. (2002) The role of immunotoxic environmental contaminants in facilitating the emergence of infectious diseases in marine mammals. *Human and Ecological Risk Assessment* **8**, 277-292
- SANTOS, M. B., PIERCE, G. J., SMEENK, C., ADDINK, M. J., KINZE, C. C., TOUGAARD, S. & HERMAN, J. (2001) Stomach contents of northern bottlenose whales *Hyperoodon ampullatus* stranded in the North Sea. *Journal of the Marine Biological Association of the United Kingdom* **81**, 143-150
- VAN BRESSEM, M. F., VAN WAEREBEEK, K. & RAGA, J. A. (1999) A review of virus infections of cetaceans and the potential impact of morbilliviruses, poxviruses and papillomaviruses on host population dynamics. *Diseases of Aquatic Organisms* **38**, 53-65