

AN INCIDENTAL FINDING OF NODAL NECK RECURRENCE OF CUTANEOUS MALIGNANT MELANOMA AFTER A 34-YEAR DISEASE-FREE PERIOD

ZLATKO KLJAJIĆ¹, PETRA SMOJE¹, PETAR IVANIŠEVIĆ¹, SAŠA ERCEGOVIĆ², NENAD KUNAC³, KRISTIЈAN BEČIĆ⁴ and NEIRA PUIZINA-IVIĆ⁵

University of Split, Split University Hospital Center, ¹Department of Otorhinolaryngology, ²Department of Maxillofacial Surgery, ³Department of Pathology, ⁴University of Split, School of Medicine and ⁵Split University Hospital Center, Department of Dermatology, Split, Croatia

The authors report a case of a 64-year-old man who had nodal recurrence of melanoma 34 years after the primary diagnosis of a cutaneous melanoma on his back. Neck ultrasound confirmed an oval anechogenic/hypoechoic lobular lesion (1.6x1.7 cm) in the right supraclavicular fossa. Fine-needle aspiration revealed sparse population of the poorly preserved malignant cells and bare malignant nuclei with prominent nucleoli. Extirpation of the lymph node was done and the histopathologic diagnosis confirmed metastatic melanoma. The man was referred to positron emission tomography/computed tomography, dermatologist, ophthalmologist and gastroenterologist for further management to exclude other potential sites of new primary melanoma. It is one of the longest disease-free latency periods between the primary melanoma diagnosis and recurrence reported to date. This article suggests melanoma to be a disease with a potentially lifelong risk of recurrence, however, late recurrences are very rare. The clinicians and patients must be vigilant and aware of the risk of late recurrences.

Key words: melanoma, ultra-late recurrence, supraclavicular region, neck dissection

Address for correspondence: Petar Ivanišević, MD
University of Split
Split University Hospital Center
Department of Otorhinolaryngology
Spinčićeva 1
21 000 Split, Croatia
Tel: +385 21 556410
e-mail: pivanisevic@kbsplit.hr

INTRODUCTION

Cutaneous melanoma is the most common type of melanoma and is responsible for the majority of deaths caused by skin malignancies. The incidence of this tumor is increasing worldwide, especially in the fair-skinned populations (1). Early detection of melanoma is the best way to reduce mortality. Primary cutaneous melanoma may develop in precursor melanocytic nevi, arise *de novo* (stages I and II), or present with metastatic spread (stages III and IV). Surgery is the primary mode of therapy for localized cutaneous melanoma (2). After the surgery, many patients remain disease free for the rest of life, whereas others can have disease recurrence. Recurrence or progression can be in the form of locoregional and/or distant metastasis,

which can be fatal. The recurrence rates are influenced by the stage at which the primary disease first presents and by the treatment received.

Important factors in the melanoma staging system are the presence of ulcerations and mitotic rates. They are used to complement depth of invasion to assign the stage. The increasing mitotic rate among patients with clinically node-negative (cN0) primary melanoma was significantly associated with decreasing melanoma-specific survival (MSS) on univariate analysis (3).

Most of the initial recurrences occur in the first 2 years after the primary disease diagnosis. Initial recurrences 10 years after the initial treatment are termed late recurrences and those occurring after 15 years of disease-free interval are termed ultra-late recurrences (4).

CASE REPORT

A 64 year-old man presented to a local hospital with a painless lymph node (2 cm) in the right supraclavicular area. The node was slightly moveable under the skin. He reported a history of cutaneous malignant melanoma on his back excised 34 years before (Figure 1). His discharge summary documented radical excision of the skin, fat, deep fascia and split thickness skin graft reconstruction, which confirmed malignancy with no evidence for further spread. He recalled no adjuvant therapy or disease recurrence in the 34-year period. Breslow and Clark thickness was not available for our case as the primary diagnosis was set 34 years prior to the disease recurrence.

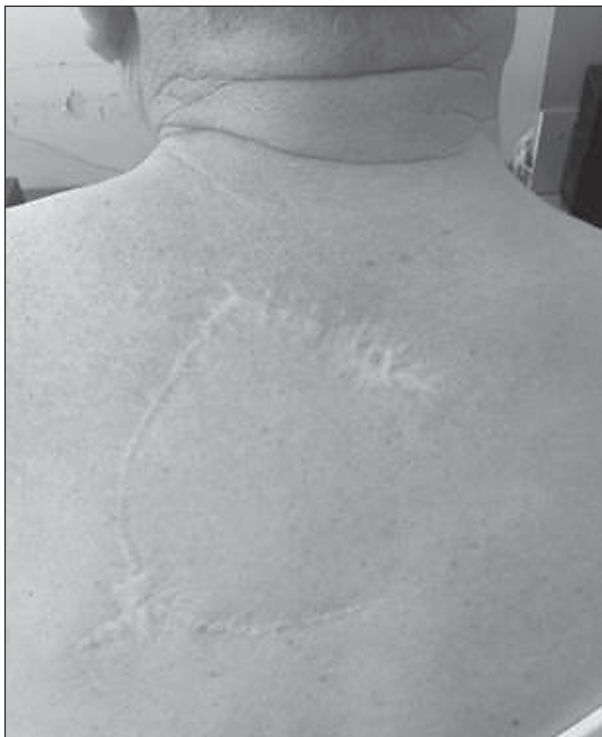

Fig. 1. The site of primary melanoma occurrence on the patient's back after excision and reconstruction by rotation flap.

Neck ultrasound confirmed an oval anechogenic/hypoechoic lobular lesion (1.6x1.7 cm) in the right supraclavicular fossa. Fine-needle aspiration (FNA) sample of the solitary neck mass revealed sparse population of the poorly preserved malignant cells and bare malignant nuclei with prominent nucleoli. Because of that, extirpation of that lymph node was recommended. Extirpation of the lymph node was done under endotracheal anesthesia (ETA) and the histopathologic diagnosis confirmed metastatic melanoma (Figures 2 and 3). The man was referred to dermatologist, ophthalmologist and gastroenterologist for further management to exclude other potential sites of new primary melanoma.

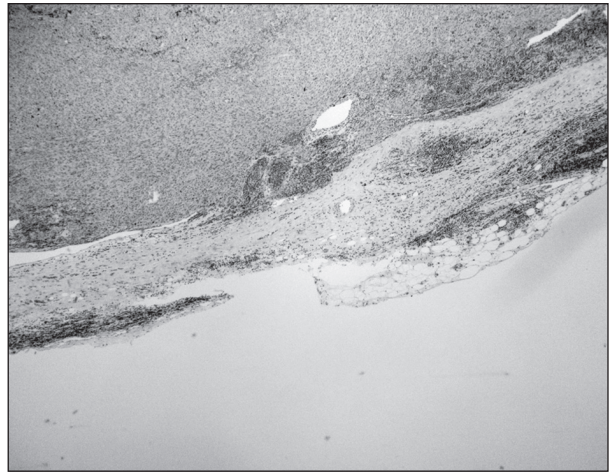


Fig. 2. Lymph node is infiltrated with abundant tumor tissue composed of aggregates of spindle-shaped, atypical polygonal melanocytes.

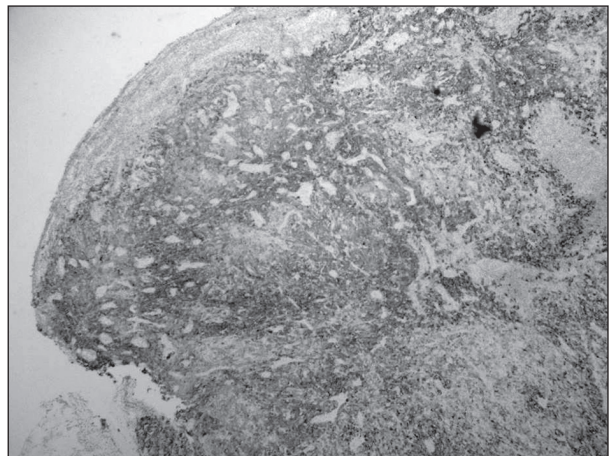


Fig. 3. Tumor tissue is melan A and S100 positive.

In the following, rather short, period of 3 weeks, while the patient was preparing for the procedure of 'radical right neck dissection', clinical examination revealed three oval palpable masses under the postoperative incision. Neck computed tomography (CT) and ultrasound showed the presence of one clinically suspicious lymph node on the right, between the lateral side of the operative incision and the clavicle (6.6 mm) and two clinically suspicious lymph nodes above the middle part of the postoperative incision (4.8 mm and 4.4 mm). Positron emission tomography/computed tomography (PET/CT) confirmed two foci of pathological metabolism (Figure 4).

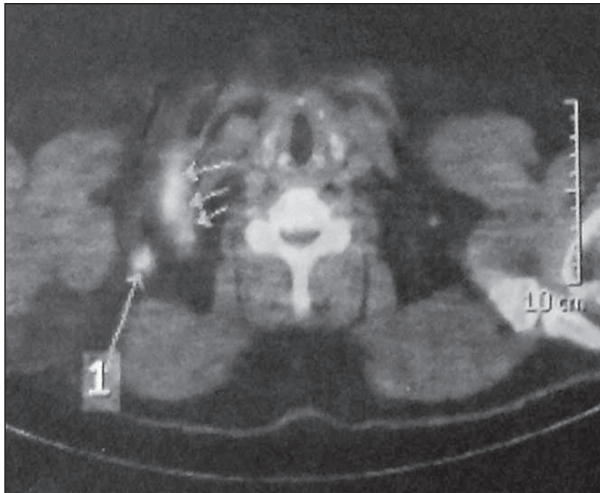


Fig. 4. Preoperative PET/CT of the right supraclavicular region.

Radical right neck dissection was immediately performed. Histology confirmed three lymph nodes almost completely replaced by metastatic melanoma with no extracapsular spread (Figure 5). The oncologic team decided to administer radiotherapy to the right side of the neck and supraclavicular region in a dose of 42 Gy in 7 fractions.




Fig. 5. Histologically, the three nodes of the fifth level are infiltrated with tumor tissue composed of spindle atypical lymphocytes showing moderate pleomorphism. The capsule of the lymph node is intact.

No clinical signs of recurrence were noted on his post-operative and post-radiotherapy outpatient visits. Follow up neck and abdomen ultrasound and PET/CT at 6 months were tumor-free (Figure 6). The patient is still alive and healthy, and has been regularly examined by the oncologist, dermatologist and otorhinolaryngologist, with no evidence for almost 5-years follow-up period.

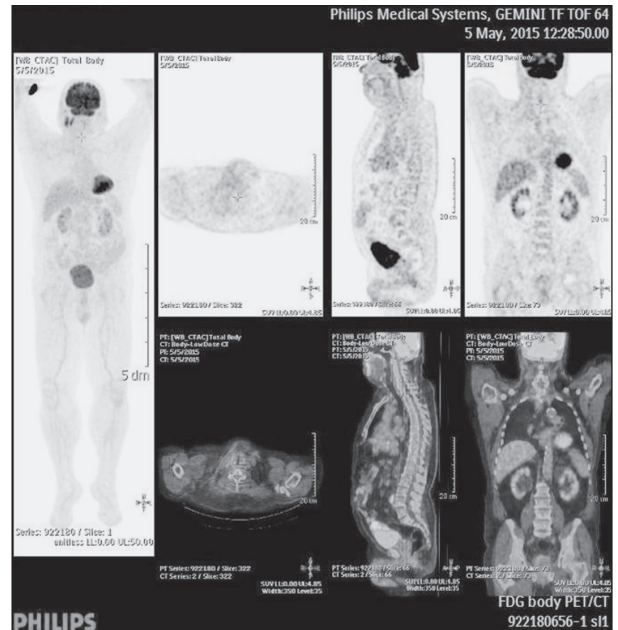


Fig. 6. Follow up PET/CT 6 months after the operation.

DISCUSSION

The patient described had no evidence for second cutaneous primary melanoma. Clinical examination, ultrasound and PET/CT examination showed no evidence for non-cutaneous melanoma. The nodal metastasis observed was in the draining basin appropriate for the original primary tumor to be the cause, which supports the theory that this case was a recurrence. It is therefore assumed that the metastasis was an ultra-late recurrence, 34 years following the original melanoma.

The ultra-late recurrence of cutaneous melanoma with several decades of quiescence is extremely rare. We found the currently longest latency period of disease-free survival from diagnosis to recurrence to be 45 years (5).

In our case, the patient was symptomatic, so the accurate diagnosis was easily established and the right therapy was applied in a rather short period from the first doctor appointment. It is speculated that a number of patients may present with or die from widespread metastasis, never being brought to the attention of the doctors that originally treated them.

Malignant melanoma is a possible life threatening disease with development of regional or distant metastases. In most patients, metastases occur within the first 2 to 5 years after excision of the primary tumor. The majority of recurrences and deaths resulting from malignant melanoma can be seen within 5 years after the

treatment of the primary tumor. Late recurrences, defined as those occurring 10 or more years after the diagnosis, are relatively uncommon events (6). There are well-recognized prognostic factors influencing overall and disease-free survival following treatment with curative intent for primary melanoma. The strongest indicator of prognosis is Breslow thickness, which unfortunately was not available in our case as the primary diagnosis had been set 34 years prior to the disease recurrence (1).

Number of tumor-involved regional nodes, one *versus* two or three *versus* four or more metastatic nodes, presence of in-transit/satellite/microsatellite disease, and sentinel node tumor burden are also negative prognostic factors. Other factors adversely affecting prognosis are ulceration status, mitotic rate, age older than 65 years and male gender (7). These negative prognostic features appear to be largely confined to patients having recurrences within 10 years of their primary diagnosis. Late progression of disease is rare; it is of high clinical interest to identify the risk of late metastases and possible risk factors to establish efficient long-term follow-up programs for patients with malignant melanoma. Schmid-Wendtner *et al.* found higher rates of late recurrence in men with primary tumors located on the trunk. In their study, survival after late recurrence did not correlate with disease-free survival (6). Faries *et al.* found late recurrence to be associated with both tumor (thin, non-ulcerated, non-head/neck, node negative) and patient (younger age, less male predominant) characteristics. Multivariate analysis confirmed younger age, thinner and node negative tumors in the late recurrence group. Late recurrences were more likely to be distant, but were associated with better post-recurrence survival on univariate and multivariate analyses (8). However, Tsao *et al.* concluded that ultra-late recurrences could occur in any patient without identifiable risk factors (9). Sella-Abate *et al.* analyzed 1372 melanoma patients disease free for more than 10 years. Seventy-seven of them progressed after this time point. The first recurrence was regional in 52 and distant in 25 patients. Lymph node recurrence was most common among regional recurrences. Distant recurrence was characterized by visceral involvement. The two most common single sites were brain and lung (10).

Melanoma is often considered to be a radio resistant tumor. However, some studies showed that adjuvant radiation therapy provided good regional control. Bibault *et al.* recommend using adjuvant radiation therapy for patients with lymph node metastases from cutaneous melanoma, especially if they present one or more lymph nodes with extracapsular extension (11). The total dose should be between 30 and 70 Gy, considering the region of radiation, with a standard

fractionation regimen in order to maximize the efficacy and minimize toxicity (11). Our oncology team, considering the regions of radiation and complications which can occur, decided to administer radiation therapy in a total dose of 42 Gy.

There are four types of cutaneous melanoma: superficial spreading, lentigo maligna, acral lentiginous and nodular.

Feichtenschlager *et al.* found that superficial spreading melanoma (39.5%) was the most frequent histological subtype (12).

Survival analysis of a sub-cohort of 577 patients showed better 5-year overall survival for women compared to men (75.8% *vs.* 63.6%; $p=0.025$) irrespective of the type and stage of cutaneous melanoma (12).

Melanoma is an aggressive and highly metastatic disease. Over several decades, the incidence of melanoma has steadily risen, and the incidence rates have increased and continue to rise nowadays. The initial sites of distant metastases are most commonly the skin, subcutaneous tissue and lymph nodes. The most common sites of visceral metastases are the lung, brain, liver and bone. In patients with melanoma, metastatic disease is felt to be very unlikely if there has been no recurrence of disease for 10 years after initial treatment. However, such late recurrences are known to occur. Because of lifelong risk of melanoma recurrence, lifetime follow-up of melanoma patients is highly recommended. Education of patients, especially those with cutaneous melanoma, about qualified self-examination for early detection of other primary melanomas is necessary. They need to be followed up under the care of a hospital specialist, as advised by the UK guidelines for the management of cutaneous melanoma (13). In the end, we can only say that melanoma is a never-ending story.

R E F E R E N C E S

1. Vecchiato A, Zonta E, Campana L *et al.* Long-term survival of patients with invasive ultra-thin cutaneous melanoma. *Medicine*. 2016; 95: 2452. doi: 10.1097/MD.0000000000002452.
2. Mihajlovic M, Vlajkovic S, Jovanovic P, Stefanovic V. Primary mucosal melanomas: a comprehensive review. *Int J Clin Exp Pathol*. 2012; 5: 739-53.
3. Gershenwald JE, Scolyer RA, Hess KR *et al.* Melanoma staging: evidence-based changes. American Joint Committee on Cancer 8th Edition Cancer Staging Manual. *CA Cancer J Clin* 2017; 67: 472-92. doi: 10.3322/caac.21409.

4. Carlson JA, Slominski A, Linette GP, Mihm MC Jr, Ross JS. Biomarkers in melanoma: staging, prognosis and detection of early metastases. *Expert Rev Mol Diagn* 2003; 3: 303-30. doi: 10.1586/14737159.3.3.303
5. Goodenough J, Cozon CL, Liew SH. An incidental finding of a nodal recurrence of cutaneous malignant melanoma after a 45-year disease-free period. *BMJ Case Rep.* 2014; 2014: 2014-204289. doi: 10.1136/bcr-2014-204289.
6. Schmid-Wendtner MH, Baumert J, Schmidt M *et al.* Late metastases of cutaneous melanoma: an analysis of 31 patients. *J Am Acad Dermatol* 2000; 43: 605-9. doi: 10.1067/mjd.2000.107234
7. Gershenwald JE, Scolyer RA, Hess KR *et al.* Melanoma of the skin. *Cancer Staging Manual, 8th Edition: AJCC.* 2016: 1-5.
8. Faries MB, Steen S, Ye X, Morton DL. Late recurrence in melanoma: clinical implications of lost dormancy. *J Am Coll Surg* 2013; 217: 27-34. doi: 10.1016/j.jamcollsurg.2013.03.007.
9. Tsao H, Cosimi AB, Sober AJ. Ultra-rate recurrence (15 years or longer) of cutaneous melanoma. *Cancer* 1997; 79: 2361-70.
10. Sella-Abate S, Ribero S, Sanlorenzo M *et al.* Risk factors related to late metastases in 1,372 melanoma patients disease free more than 10 years. *Int J Cancer* 2015; 136: 2453-7. doi: 10.1002/ijc.29281.
11. Bibault JE, Dewas S, Mirabel X *et al.* Adjuvant radiation therapy in metastatic lymph nodes from melanoma. *Radiat Oncol.* 2011; 6: 12. doi: 10.1186/1748-717X-6-12.
12. Feichtenschlager V, Weihsengruber F, Richter L, Vujic I, Rappersberger K, Posch C. Clinical melanoma characteristics and survival – a single-center retrospective study between 2000 and 2010. *Wien Med Wochenschr* 2019. doi: 10.1007/s10354-018-0678-3. (ahead of print)
13. Marsden JR, Newton-Bishop JA, Burrows L *et al.* Revised U.K. guidelines for the management of cutaneous melanoma 2010. *Br J Dermatol.* 2010; 163: 238-56. doi: 10.1016/j.bjps.2010.07.006.

SAŽETAK

INCIDENTALNI NALAZ ČVORA NA VRATU KOŽNOG MALIGNOG MELANOMA NAKON 34 GODINE LATENCIJE

Z. KLJAJIĆ¹, P. SMOJE¹, P. IVANIŠEVIĆ¹, S. ERCEGOVIĆ², N. KUNAC³, K. BEČIĆ⁴ i N. PUIZINA-IVIĆ⁵

Klinički bolnički centar Split, ¹Klinika za bolesti uha, nosa i grla s kirurgijom glave i vrata, ²Odjel za maksilofacijalnu kirurgiju, ³Klinički zavod za patologiju, sudsku medicinu i citologiju, ⁴Sveučilište u Splitu, Medicinski fakultet i ⁵Klinika za kožne i spolne bolesti, Split, Hrvatska

Prikazujemo slučaj 64-godišnjeg muškarca koji je imao metastazu melanoma u limfnom čvoru 34 godine nakon postavljene dijagnoze kožnog melanoma na leđima. Na ultrazvuku je ponadena ovalna anehogena/hipoehogena lobularna lezija (1,6x1,7 cm) u desnoj supraklavikularnoj regiji. Citološka punkcija je ukazivala na slabo diferencirane maligne stanice. Učinjena je ekstirpacija limfnog čvora i patohistološki nalaz je potvrdio metastatski melanom. Daljnjom obradom (pozitronska emisijska tomografija, pregled dermatologa, oftalmologa i gastroenterologa) nije pronađeno novo sjelo primarnog melanoma. To je jedno od najdužih razdoblja između primarnog melanoma i povratka bolesti opisano do danas. Ovaj prikaz pokazuje da se metastaze melanoma mogu javiti tijekom cijelog života. Liječnici i bolesnici moraju biti svjesni rizika kasnih metastaza.

Ključne riječi: melanom, kasna metastaza, supraklavikularna regija, disekcija vrata