

Ann Indian Acad Neurol. 2019 Jul-Sep; 22(3): 327–331.

PMCID: PMC6613414

doi: 10.4103/aian.AIAN_191_18; 10.4103/aian.AIAN_191_18

PMID: [31359949](#)

An Unusual Combination of Neurological Manifestations and Sudden Vision Loss in a Child with Familial Hyperphosphatemic Tumoral Calcinosis

[Lokesh Lingappa](#), [Shoji Ichikawa](#),¹ [Amie K. Gray](#),¹ [Dena Acton](#),¹ [Michael J. Evans](#),¹ [Rajsekara Chakravarthi Madarasu](#),² [Ramesh Kekunnaya](#),³ and [Sirisharani Siddaiahagari](#)

Department of Neurology and Hemato-Oncology, Rainbow Children's Hospital and Birthright, Hyderabad, Telangana, India

¹Department of Medicine, Indiana University School of Medicine, Indianapolis, Indiana, USA

²Department of Nephrology, Star Hospital, Hyderabad, Telangana, India

³Jasti V Ramanamma Children's Eye Care Centre, LV Prasad Eye Institute, Hyderabad, Telangana, India

Address for correspondence: Dr. Lokesh Lingappa, Rainbow Children's Hospital and Birthright, Banjara Hills, Hyderabad - 500 034, Telangana, India. E-mail: siriloki@gmail.com

Copyright : © 2006 - 2019 Annals of Indian Academy of Neurology

This is an open access journal, and articles are distributed under the terms of the Creative Commons Attribution-NonCommercial-ShareAlike 4.0 License, which allows others to remix, tweak, and build upon the work non-commercially, as long as appropriate credit is given and the new creations are licensed under the identical terms.

Abstract

Hyperphosphatemia in the absence of renal failure is an unusual occurrence, particularly in children, but is a common primary feature of familial hyperphosphatemic tumor calcinosis. We report a child with hyperphosphatemia who presented with multiple episodes of neurologic dysfunction involving lower motor neuron facial nerve palsy along with sequential visual loss. He also had an episode of stroke. There was an extensive metastatic calcification of soft tissue and vasculature. Hyperphosphatemia with normal serum alkaline phosphatase, calcium, parathyroid hormone, and renal function was noted. He was managed with hemodialysis and sevelamer (3 months) without much success in reducing serum phosphate level, requiring continuous ambulatory peritoneal dialysis (3 years). Intact fibroblast growth factor 23 (*FGF23*) was undetectable, with C-terminal *FGF23* fragments significantly elevated (2575 RU/ml, normal <180 RU/ml). Sequencing demonstrated homozygous c.486C >A (p.N162K) mutation in *FGF23 exon 3*, confirming the diagnoses of primary *FGF23* deficiency, the first case to be reported from India.

Keywords: Continuous ambulatory peritoneal dialysis, familial hyperphosphatemic tumor calcinosis, primary *FGF23* deficiency, sevelamer, sudden vision loss

INTRODUCTION

Hyperphosphatemia in children is an unusual finding, especially in the absence of renal failure, and when reported, it is generally due to vitamin D intoxication, tumor lysis syndrome which is transient and situation specific; isolated hypoparathyroidism and pseudohypoparathyroidism are two other conditions to be evaluated in such cases.

Familial hyperphosphatemic tumoral calcinosis (FHTC OMIM211900) is a rare autosomal recessive disease,[1] although the exact prevalence rate is unknown.[2] Most reported pediatric cases (78%) have been 2–13 years of age.[3] It is associated with disturbed mineral metabolism and hyperphosphatemia as a prominent manifestation.[4] If untreated, this may lead to metastatic calcification around the major joints, in soft tissues and arterial walls, which is a common sequale. There have been around 200 cases of FHTC since its first report by Duret in 1899.

We report a case of FHTC with normal renal function in a 8-year-old boy who presented with acute, permanent loss of vision, multiple neurological manifestations which accumulated over a period.

CASE REPORT

The first presentation was at 4 years of age with right lower motor neuron (LMN) facial paralysis. Later at 6 years, he had left facial palsy. There was no involvement of other cranial nerves. On both occasions, facial palsy resolved spontaneously over 4–5 months.

At 7 years of age, he had an episode of the transient decrease in vision in both eyes lasting for 15 min, associated with holocranial headache and bone pain in both lower limbs. He was evaluated for cerebral ischemic event; however, no abnormality was detected on brain magnetic resonance imaging (MRI) with diffusion-weighted imaging. After 2 months, he had a fracture of right elbow following a trivial fall. He also developed mild, left-sided hemiplegia at 7 years 8 months of age, which resolved spontaneously.

By his 8th year, he experienced a sudden, painless loss of vision in the right eye, 25 days before the ophthalmic consultation. This was the first consultation at our institute; we noted frontal bossing, dolichocephaly, abnormal crowding of teeth, and a submental hard painless swelling.

There was only perception of light in the right eye during this visit. Vision in the left eye was normal; whitish calcium-like deposits were present on the posterior border of the lid margins, the conjunctiva in the interpalpebral zone of both eyes [Figure 1]. He had full ocular movements and right esotropia of 30 prism diopters. There was a relative afferent pupillary defect of Grade 4 with optic atrophy in the right eye. Visual evoked potential (VEP) showed extinguished flash response (EFR) on the right side. Flash VEP was normal in the left eye. Optic nerve head appearance was normal on the left side [Figure 1].

Complete blood picture, serum sodium, potassium, chloride, renal function tests, and urinary pH were within normal limits. Serum inorganic phosphorus was high (9.4 mg/dL) with normal alkaline phosphatase (193 U/L) [Table 1]. Renal parameters were normal [Table 2]. Normal functioning of parathyroid glands was denoted by normal PTH level and negative scintigraphy for adenoma. Persistent hyperphosphatemia was documented on repeat evaluation [Table 2].

Brainstem auditory evoked response showed bilateral moderate hearing loss. X-rays of the long bone and computed tomography (CT) brain with bone window demonstrated soft-tissue and vascular calcification.

X-ray of the knee, wrist, and spine showed sclerotic changes. Extensive sclerosis of skull vault, metastatic calcification of the subcortical frontal lobe and basal ganglia, tentorium cerebelli, falx cerebri, submental

region, and wall of the ophthalmic artery and carotid artery on both sides [Figure 2] were noted on noncontrast CT of the brain and orbits.

We started him on the oral phosphate-binding agent (Sevelamer 800 mg three times a day [t.i.d]) at 8 years of age the time he consulted us, which lowered the phosphate levels marginally but failed to bring it to the normal range.

Five months after the loss of vision in the right eye, there was an acute painless visual loss in the left eye. The left pupil showed a minimal reaction to the direct light. The fundus showed right-sided optic atrophy and normal optic nerve on the left side. EFR was seen with VEP on the left side; however, flash VEP showed a good response indicating retrobulbar pathology, possibly due to ischemia. Figure 3 depicts the chronology of symptoms.

On both occasions of visual loss, he received intravenous methylprednisolone (500 mg/day in divided doses for 3 days). Failing to control phosphate levels by oral therapy (sevelamer, 800 mg t.i.d) alone, he was started on hemodialysis for 3 months and kept on maintenance therapy with a target to achieve serum inorganic phosphorus <5.5 mg/dl and calcium phosphate <60 mg/dL. Other than dialysis to reduce phosphate and sevelamer, we initially tried on aluminum hydroxide and low phosphate diet for 2 months, but without any effect. Despite regular continuous ambulatory peritoneal dialysis (CAPD) for 3 years using solutions with low phosphate, his serum phosphorus levels never normalized. Throughout his illness, urine output was adequate with normal renal function.

He died of acute respiratory failure with features of septicemia at the age of 12 years. The child presented acutely with fever, swelling of lower limbs, and breathing difficulty. His blood tests demonstrated elevated white blood cell count with 82% polymorphs and elevated C-reactive protein (96 mg/dl). After starting antibiotics, he deteriorated rapidly and succumbed. He did not have evidence of peritonitis, during this period, calcium and phosphorus were similar to earlier observations. Although his immune status might have been affected by his poor oral intake, and dietary restrictions, we could not find an immediate causal relation to his death and FHTC. Persistent hyperphosphatemia with normal renal function and metastatic calcification in this child suggested the diagnosis of familial tumoral calcinosis and he was further evaluated biochemically and by DNA sequencing.

Intact FGF23 was undetectable (below 3 pg/ml), while the C-terminal FGF23 fragments were significantly elevated (2575 RU/ml [normal <180 RU/ml]). Sequencing demonstrated no mutation in the GALNT3 gene, but a homozygous c.486C>A mutation on FGF23 exon 3. This novel mutation results in the substitution of asparagine to lysine (p.N162K). His parents were both heterozygous for this mutation.

DISCUSSION

Recent advances in genetics have identified FHTC as a monogenic disorder resulting in hyperphosphatemia due to fibroblast growth factor 23 (FGF 23) deficiency,[5,6,7] while FHTC and hyperostosis-hyperphosphatemia syndrome have been described as separate entities, and few reports indicate that these entities are part of a continuous spectrum of the same disease.[8,9]

As a consequence of this derangement in phosphate metabolism, soft-tissue calcifications are frequent which may appear like a mass (tumoral); hence, the name and clinical presentation vary depending on the affected site. There are reports of skin and long bone involvement, corneal calcification, and angioid streaks associated with FHTC. However, the combination of persistent hyperphosphatemia unresponsive to

treatment, varied neurological presentations, and vision loss has not been reported.

The optic nerve sheath and the ophthalmic artery are the two possible sites of calcification around the optic nerves. Concurrent carotid artery calcification makes ophthalmic artery involvement more likely.

Ophthalmic artery calcification with pipestem pattern without ischemic episodes has been reported in one patient of diabetes mellitus with renal failure.[\[10\]](#)

Our patient consulted us at the age of 8 years for the sequential loss of vision in both eyes, initially in the right eye, and later in the left eye. The presence of deposits on the lid margins, the conjunctiva of both eyes indicated an abnormality in mineral metabolism. A history of bone pain in the past strengthened our suspicion and LMN facial palsy was suggesting possible facial canal narrowing/ischemic pathology with spontaneous improvement.

During the initial episode, a relative afferent pupillary defect of Grade 4 with optic atrophy, EFR on VEP in the affected eye (right eye) indicated anterior visual pathway pathology. In general, it takes around 2–4 weeks to develop subtle optic disc pallor (partial optic atrophy).

In the second episode, where the left eye was involved, EFR on VEP was seen in the affected eye; flash VEP showed a good response indicating a retrobulbar anterior visual pathway defect, possibly due to ischemia.

He had intermittent headache during his course of illness, and never papilledema was noted during his detailed ophthalmological evaluations done on a regular basis. Neither CT scan nor MRI brain revealed any features of chronic raised intracranial pressure; there was no evidence of consecutive optic atrophy.

We noted persistent hyperphosphatemia, sclerosis of bone and soft-tissue metastatic calcification, which further strengthened our diagnosis of TC. We noted patchy calcification surrounding the optic nerve in our patient, which could have led to posterior ischemic optic neuropathy.

Undetectable intact FGF23 levels and a homozygous FGF23 mutation confirmed our diagnosis. FGF23 plays an important role in maintaining phosphate homeostasis, and inadequate intact FGF23 concentrations result in hyperphosphatemia.

FGF23 is a potent regulator of serum phosphate concentrations by decreasing phosphate reabsorption in the renal proximal tubule, leading to increased renal phosphate excretion. It also is an important regulator of calcitriol by decreasing 1 α -hydroxylase (CYP27B1) and increasing 24 hydroxylases (CYP24A1) in the proximal tubule. Thus, inactivating mutations of FGF23, as well as GALNT3 (which O-glycosylates FGF23) or Klotho (a co-receptor for FGF23), gives rise to hyperphosphatemia and increased, or inappropriately normal calcitriol concentrations.[\[11\]](#)

Our patient had a homozygous FGF23 mutation that resulted in failure to secrete full-length, biologically active FGF23, leading to hyperphosphatemia, soft-tissue calcifications, and sclerotic bone. In addition, he had unusual neurologic and ophthalmic manifestations. Although the longitudinal measurement of FGF23 is unavailable, this unusually severe phenotype may suggest severe FGF23 deficiency.

Ophthalmic involvement, which is often associated with FHTC, manifests as calcifications of the eyelid, cornea, and/or angioid streaks. Interestingly, calcium salts commonly deposit in the conjunctiva and cornea, and rarely in the walls of the globe.[\[12,13\]](#)

Conjunctival calcification as seen in our case is the result of hyperphosphatemia and can be seen in patients

with chronic renal failure. Increased pH of exposed palpebral aperture leads to precipitation of calcium phosphate salts. It is almost always associated with corneal calcium deposition in varying degree, which resembles Vogt's limbal girdle.[12] Our patient was asymptomatic for the ocular calcification and had normal renal function. Calcification of eyelid margin noted in our patient is a rarer phenomenon and reported only in a few cases of familial tumoral calcinosis.[14,15]

The cause of visual loss in this child is not clear. Narrowing of the optic canal though present, does not seem to be the likely cause. Abrupt onset of visual loss on both occasions is not favoring compressive optic neuropathy in which gradual decrease in visual acuity is the characteristic feature. Visual morbidity in sclerotic bone diseases is attributable to compromised optic canals,[12] although retinal degeneration has also been reported in some cases. With electroretinography being normal in our patient, sudden total loss of optic nerve function is consistent with an ischemic event. The history of transient loss of vision and spontaneously resolving seventh nerve palsy strongly support the possibility of an ischemic pathology. Sudden vision loss has not been reported in the literature.

Primary FGF23 deficiency is associated with features of soft-tissue calcification as seen in the index case. Persistent hyperphosphatemia, in this case, was recalcitrant to sevelamer, hemodialysis and CAPD. Pharmacological therapy did not reduce the serum phosphate levels to the optimum level requiring hemodialysis and CAPD to achieve the goal in the absence of renal failure. Although we could not achieve reduction of the phosphate levels to the target (serum inorganic phosphorus <5.5 mg/dl and calcium phosphate <60 mg/dL) with CAPD, he survived for 3 years. He died prematurely at the age of 12 years due to severe septicemia.

This is one of the most severe forms of FGF 23 mutation detected; no other reported cases in the literature had visual loss and serial neurologic involvement with premature death.

Declaration of patient consent

The authors certify that they have obtained all appropriate patient consent forms. In the form the patient(s) has/have given his/her/their consent for his/her/their images and other clinical information to be reported in the journal. The patients understand that their names and initials will not be published and due efforts will be made to conceal their identity, but anonymity cannot be guaranteed.

Financial support and sponsorship

Nil.

Conflicts of interest

There are no conflicts of interest.

Acknowledgment

The authors thank Ravi Varma, Interventional Radiologist, Citi Neuro Centre, Hyderabad, India and Mehul Shah, consultant Pediatric Nephrologist, Apollo Hospitals, Hyderabad, India, for their guidance and support in the management of the case.

REFERENCES

1. Pakasa NM, Kalengayi RM. Tumoral calcinosis: A clinicopathological study of 111 cases with emphasis on the earliest changes. *Histopathology*. 1997;31:18–24. [PubMed: 9253620]
2. NIH. Hyperphosphatemic Familial Tumoral Calcinosis. Genetics Home Reference. Bethesda, MD: NIH; 2017. [last accessed on 2018 May 15]. US National Library of Medicine 2016. Available from: <https://www.ghr.nlm.nih.gov/condition/hyperphosphatemic-familial-tumoral-calcinosis> .
3. Rafaelsen S, Johansson S, Ræder H, Bjerknes R. Long-term clinical outcome and phenotypic variability in hyperphosphatemic familial tumoral calcinosis and hyperphosphatemic hyperostosis syndrome caused by a novel GALNT3 mutation; case report and review of the literature. *BMC Genet*. 2014;15:98. [PMCID: PMC4181413] [PubMed: 25249269]
4. Mahadevan S, Adhisivam B, Kumar CN. Tumoral calcinosis with hyperphosphatemia. *Indian J Pediatr*. 2005;72:889–90. [PubMed: 16272668]
5. Chefetz I, Sprecher E. Familial tumoral calcinosis and the role of O-glycosylation in the maintenance of phosphate homeostasis. *Biochim Biophys Acta*. 2009;1792:847–52. [PMCID: PMC3169301] [PubMed: 19013236]
6. Benet-Pagès A, Orlik P, Strom TM, Lorenz-Depiereux B. An FGF23 missense mutation causes familial tumoral calcinosis with hyperphosphatemia. *Hum Mol Genet*. 2005;14:385–90. [PubMed: 15590700]
7. Larsson T, Yu X, Davis SI, Draman MS, Mooney SD, Cullen MJ, et al. A novel recessive mutation in fibroblast growth factor-23 causes familial tumoral calcinosis. *J Clin Endocrinol Metab*. 2005;90:2424–7. [PubMed: 15687325]
8. Ichikawa S, Baujat G, Seyahi A, Garoufali AG, Imel EA, Padgett LR, et al. Clinical variability of familial tumoral calcinosis caused by novel GALNT3 mutations. *Am J Med Genet A*. 2010;152A:896–903. [PMCID: PMC3392654] [PubMed: 20358599]
9. Frishberg Y, Topaz O, Bergman R, Behar D, Fisher D, Gordon D, et al. Identification of a recurrent mutation in GALNT3 demonstrates that hyperostosis-hyperphosphatemia syndrome and familial tumoral calcinosis are allelic disorders. *J Mol Med (Berl)* 2005;83:33–8. [PubMed: 15599692]
10. Nakayama M, Ura Y, Nagata M, Okada Y, Sumida Y, Nishida K, et al. Carotid artery calcification at the initiation of hemodialysis is a risk factor for cardiovascular events in patients with end-stage renal disease: A cohort study. *BMC Nephrol*. 2011;12:56. [PMCID: PMC3206830] [PubMed: 21999942]
11. Hu MC, Kuro M, Moe OW. Secreted Klotho and chronic kidney disease. *Adv Exp Med Biol*. 2012;728:126–57. [PMCID: PMC3780390] [PubMed: 22396167]
12. Porter R, Crombie AL. Corneal and conjunctival calcification in chronic renal failure. *Br J Ophthalmol*. 1973;57:339–43. [PMCID: PMC1214897] [PubMed: 4576906]
13. Caldemeyer KS, Smith RR, Edwards-Brown MK. Familial hypophosphatemic rickets causing ocular calcification and optic canal narrowing. *AJNR Am J Neuroradiol*. 1995;16:1252–4. [PubMed: 7677018]
14. Ichikawa S, Imel EA, Sorenson AH, Severe R, Knudson P, Harris GJ, et al. Tumoral calcinosis presenting with eyelid calcifications due to novel missense mutations in the glycosyl transferase domain of the GALNT3 gene. *J Clin Endocrinol Metab*. 2006;91:4472–5. [PubMed: 16940445]
15. Barry G, Khachikian S, Beck A, Belden C, Pearce J, Simon JW, et al. Optic canal diameter in infantile

osteopetrosis. J Pediatr Ophthalmol Strabismus. 2009;46:112–4. [PubMed: 19343974]

Figures and Tables

Figure 1

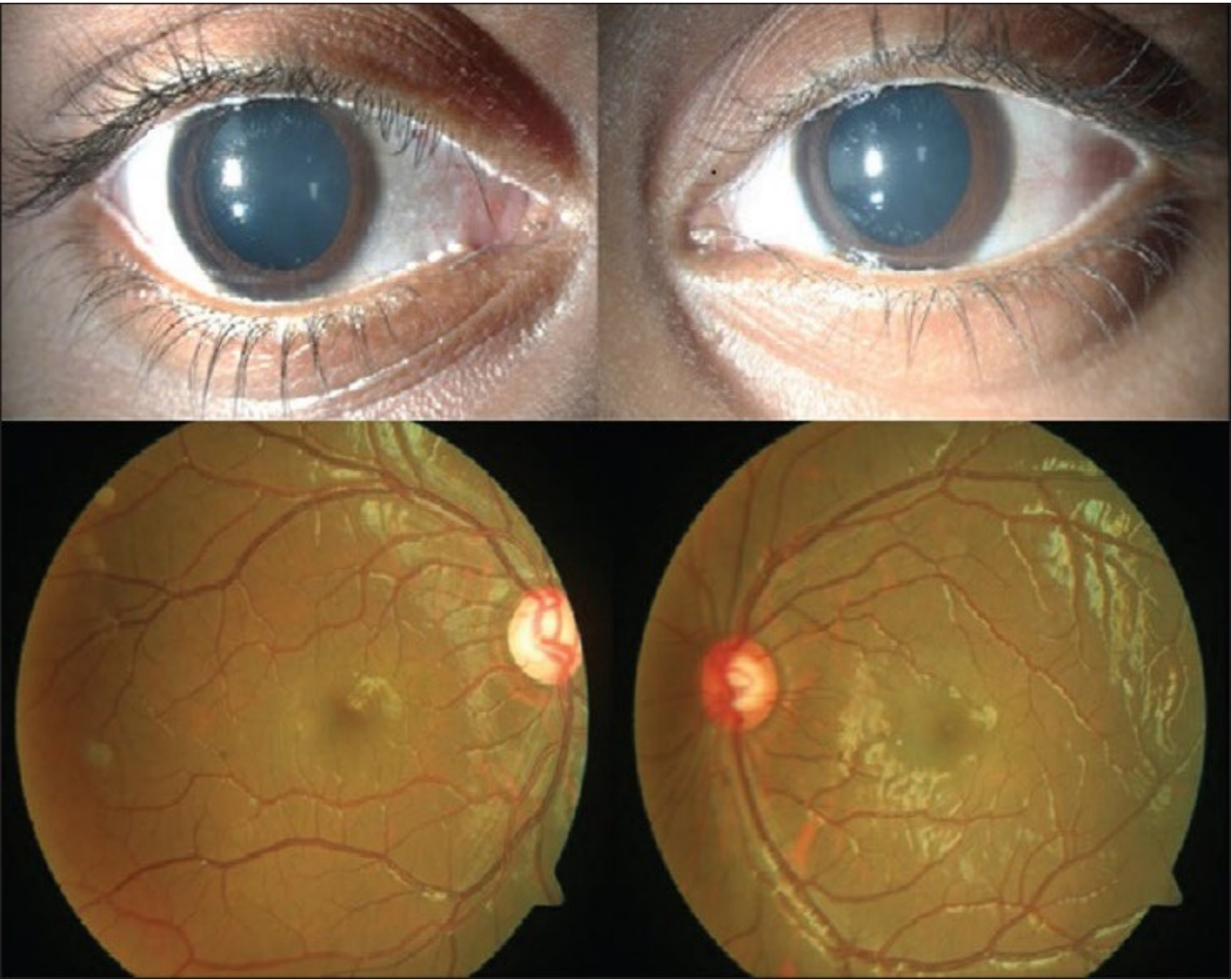


Image demonstrating chalky deposits on the posterior margin of the eyelid and fundus demonstrating optic atrophy in the right eye

Table 1

Laboratory parameters

Laboratory Parameters	Observation	Normal range	Remark
Venous blood pH	7.278	7.31-7.41	Low, but not significant
Serum inorganic phosphorous	9.4 mg/dL	3.1-5.9 mg/dL	High

Serum calcium	9.9 mg/dL	9-10.1mg/dL			Within range	
Parathormone	16pg/mL	12-95pg/mL			Within range	
S. Alkaline phosphatase	193U/L	218-499 U/L			Low	
Urinary Phosphate	53mg/dL	3.7-5.4 mg/dL			High	
Parameters	Normal values	Observations				
		First	Second	Third	Fourth	Fifth
Serum Calcium (mg/dL)	8.5-10.5	9.5			10.4	7.2
Serum Phosphorous (mg/dL)	3.8-6.5	8.1	9.4	7.8	9.2	9.6
Alkaline Phosphatase (IU/L)	208-450	145			106	
Calcium (Spot urine)		9.9				
		53				
Phosphorous (Spot urine)			12		32	
Creatinine (Spot urine)		96		30		140
Parathormone (pg/mL)	12-95pg/mL	16				

High serum phosphorous along with increased urinary phosphate in the presence of normal serum calcium & parathormone levels. There was persistent hyperphosphatemia with normal renal parameters

Table 2

Constitution of dialysate

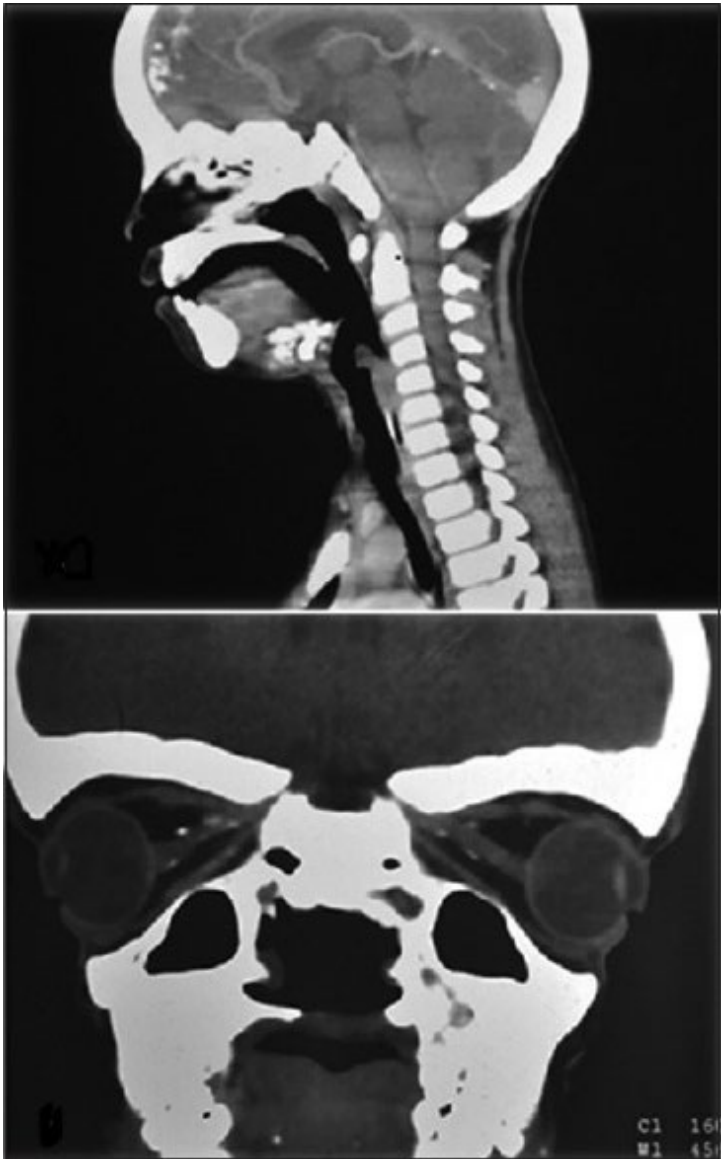Parameter	Concentration
Anhydrous Glucose*	1.36%w/v
Glucose monohydrate*	1.50%w/v
Sodium chloride*	0.538%w/v
Sodium lactate [†]	0.448%w/v
Calcium chloride*	0.0184%w/v
Magnesium chloride*	0.0051%w/v

Parameter	mmol/L
Sodium (Na ⁺)	132.00
Calcium (Ca ²⁺)	1.25
Magnesium (Mg ²⁺)	0.25
Chloride (Cl ⁻)	95.00

Lactate (C ₃ H ₅ O ₃)	40.00
Osmolarity (mOsm/L)	344
p ^H at 25°C	5.5

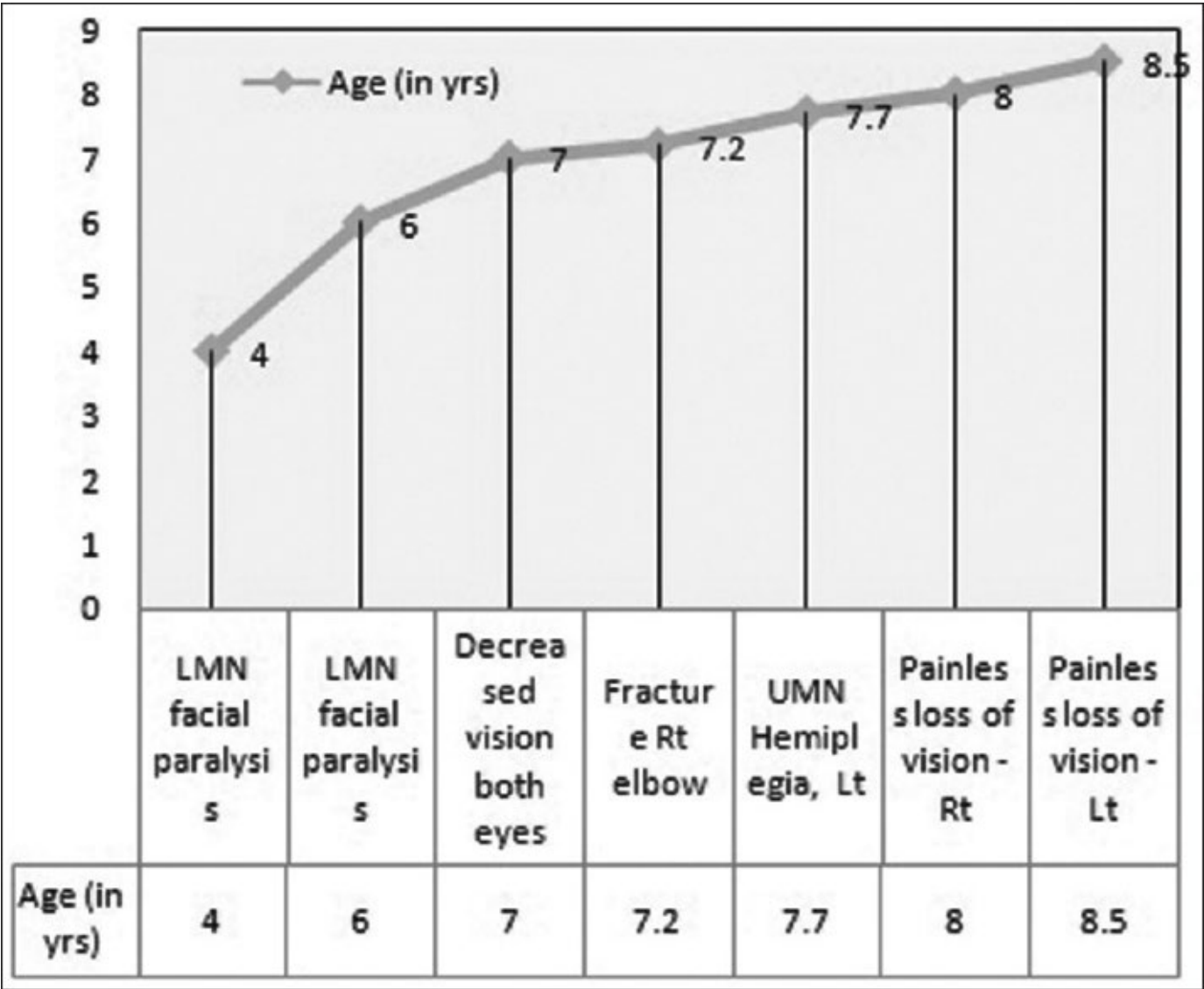
*European Pharmacopea, †French Pharmacopea

Figure 2



Computed tomography sagittal section of the brain (bone window) depicting calcified lymph nodes in the submental region with calcification of falx and hyperdense cortex of the flat bones of the skull, and coronal section bone window demonstrating patchy calcification of optic nerve, more prominent on the right side than left, along with areas of gyral calcification on the left more than the right hemisphere

Figure 3



Chronology of symptoms (supplementary)

Articles from Annals of Indian Academy of Neurology are provided here courtesy of **Wolters Kluwer -- Medknow Publications**