



ELSEVIER

Contents lists available at [ScienceDirect](http://ScienceDirect.com)

Oral and Maxillofacial Surgery Cases

journal homepage: www.oralandmaxillofacialsurgerycases.com

Trans-nasal endoscopic marsupialization of a voluminous radicular cyst involving maxillary sinus and nasal cavity: A case report and a literature review on this surgical approach

Ugo Consolo ^a, Pierantonio Bellini ^b, Giuseppe Lizio ^{c,*}^a Professor of Maxillofacial Surgery, Department of Surgery, Medicine, Dentistry and Morphological Sciences with Transplant Surgery, Oncology and Regenerative Medicine Relevance, School of Dentistry, University of Modena and Reggio Emilia, Modena, Italy^b Researcher, Department of Surgery, Medicine, Dentistry and Morphological Sciences with Transplant Surgery, Oncology and Regenerative Medicine Relevance, School of Dentistry, University of Modena and Reggio Emilia, Modena, Italy^c Resident, Unit of Dentistry and Maxillofacial Surgery, "Policlinico di Modena" Hospital, Modena, Italy / Research Assistant, Department of Biomedical & Neuromotor Sciences, University of Bologna, Bologna, Italy

ARTICLE INFO

Article history:

Available online 13 April 2018

Keywords:

Endoscopy
Marsupialization
Odontogenic cysts
Maxillary sinus
Nasal cavity

ABSTRACT

The treatment of a huge cystic lesion in the upper jaw involving the respiratory cavities may result challenging. A traditional oral approach entails patient discomfort and may have negative aesthetic implications. This treatment, particularly in case of enucleation not preceded by marsupialization for volumetric reduction of the lesion, may cause irreversible damage to important anatomical structures and the collapse of the bone architecture. The purpose of this case report is to show the benefits of an endoscopic trans-nasal approach for the definitive treatment of such a clinical situation. The surgical technique aimed to remove part of the cystic wall and to open the inner compartment of the lesion to the nasal cavity after the resection of the anterior edge of the inferior turbinate and the lateral wall of the inferior nasal meatus. After a follow-up period of 18 months, without any problem or discomfort for the patient, the cyst appeared radiologically healed without the loss of any lesion-associated tooth. The bone nasal cavity, the maxillary sinus and the anterior alveolar process architecture, noticeably modified by the expansive enlargement of the cyst, resulted completely restored with a complete recover of the respiratory and oral functions.

© 2018 The Authors. Published by Elsevier Inc. This is an open access article under the CC BY-NC-ND license (<http://creativecommons.org/licenses/by-nc-nd/4.0/>).

1. Introduction

Odontogenic sinus diseases that involve the nasal and paranasal cavities often causes an alteration of their peculiar structural characteristics with impairment of the respiratory function [1,2]. The traditional trans-oral surgical access, that aims to a wide approach for a complete removing of the lesion, is time consuming and causes post-operative discomfort and, sometimes, irreversibly damage the bone structures and the ciliar mucosa, with the loss of the sinus clearance [1,3]. Potential morbidity of this technique includes oro-antral fistulas formation, the loss of dental elements, the necessity of reconstructive

* Corresponding author. Department of Surgery, Medicine, Dentistry and Morphological Sciences with Transplant Surgery, Oncology and Regenerative Medicine Relevance, School of Dentistry, University of Modena and Reggio Emilia, Modena, Italy Via del Pozzo, 71 - 41124 Modena, Italy.

E-mail addresses: giuseppelizio@libero.it, giuseppe.lizio2@unibo.it (G. Lizio).

surgery and chronic sinusitis [4]. The mini-invasive trans-oral marsupialization, aiming to reduce the dimension of the lesion before the definitive enucleation, implies patient collaboration for the entire long-term period of treatment [5,6]. The introduction of endoscopic surgical intervention, improving the knowledge of the sinus function, underlined the importance of a mini-invasive approach to respect the sinus walls and mucosa [7,8]. Thus, the frequency of external or intra-oral interventions for sinus diseases was greatly reduced and the entire mucosal stripping in the sinusitis Caldwell-Luc approach was largely abandoned, with lower discomfort and shorter recovery times. The endoscopic nasal exam gives more diagnostic particulars about the macroscopic characteristics of a lesion and its relations with the anatomical environment, completing the radiographic information [9] and allowing to choose the better surgical treatment. Under the endoscopic visual system angled instrument can reach a lesion, according to its characteristics and location, passing through the medium nasal meatus, widening the osteo meatal complex (OMC) with the so-called functional endoscopic sinus surgery (FESS) or through the inferior nasal meatus, perforating the lateral wall of the nasal cavity. Generally the first approach is preferred in case of a sinusitis or a huge cyst or neoplasm [9], while the second one is chosen in case of anterior location of a lesion with involvement of the bottom of the nasal cavity [10–13]. Impacted canines close to the nasal pavement have been removed with a trans-nasal endoscopic surgery [14].

This paper reports about a case of a voluminous radicular cyst involving the upper airways successfully treated with its marsupialization in the nasal cavity with an endoscopic assisted surgery. The case has been included in the literature background about this technical approach.

2. Case presentation

A 23-year old woman was referred to our operative division by her dentist for a supposed inflammatory process involving the left infra-orbital region and left nasal alar region beginning about 15 days before with assumption of oral antibiotics (amoxicillin 1gr twice a day for 7 days for a week) without any substantial variation of the clinical scenario. During the first visit in office, the patient did not complain of any symptoms apart from the progressive swelling in correspondence of the left nostril and anterior cheek with a tension feeling, a little sore after digital pressure, and the gingival swelling in the anterior vestibule. Clinically it was recorded a swollen appearance of the left infra-orbital and left nasal alar region, with protrusion of the left upper lip, raising up of the left nostril with reduction of its aperture, with no redness or sensitive alteration of the skin. Intra-oral examination revealed a circumscribed swelling of the vestibule in the left incisors and canine zones, slightly tender to bimanual extra and intra-oral palpation, no fluctuant. A little expansion in the anterior-left palatal vault was noted, tough to palpation. All the teeth of the upper left arch resulted vital to the pulp thermic and electric test, except the upper later incisor, that had been treated and reconstructed with composite material several years before for caries. The panoramic radiograph showed an indefinite radiolucent area periapical to the upper left incisors and the canine superimposing distally to the image of the left maxillary sinus. The computed tomographic scan, requested thereafter, showed a voluminous radio-opaque area occupying almost entirely the left maxillary sinus cavity; some coronal scans in correspondence of the canine and premolar location showed expansion and thinning of the external sinus bone walls and of the palatal versant of alveolar process, while the medial wall appeared bowed toward the nasal septum with involvement and disappearance of the inferior meatus and nasal floor (Fig. 1); axial scans revealed a forward expansion of the anterior wall of the sinus cavity with alteration of its normal profile resulting in a rounded protrusion towards the soft tissue with, in some scans, the disappearance of lateral wall and the inferior meatus (Fig. 2). A presumed diagnosis of an odontogenic cyst (radicular cyst, keratocyst) or neoplasm was formulated and a mini-invasive endoscopic nasal approach in general anaesthesia was chosen principally to take an incisional biopsy and put in communication the inner compartment of the cyst to the nasal cavity and to plan the better approach for a subsequent radical removal of the disease.

Nasal cavity was decongested, and local anaesthetic (lidocaine 2% and 1:100,000 adrenaline) was injected through the nasal floor and the cyst walls. By retracting the nostril with a Killian speculum, an incision of approximately 15 mm along the floor of the nasal vestibule with a lateral relief incision was performed, the nasal mucosa and the periosteum were raised off from the anterior portion of pavement and lateral wall of the nasal cavity and of inferior turbinate. With the aid of a 0°–45° degree 4-mm rigid optical endoscope, the anterior edge of the inferior turbinate was cut off with a through-cutting

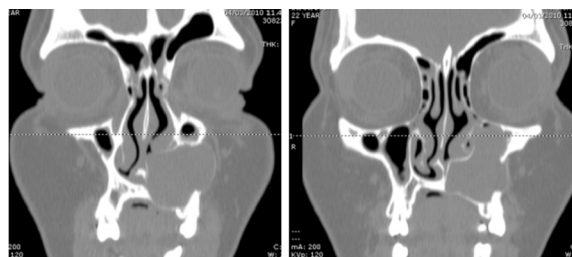


Fig. 1. The coronal computed tomography images show a voluminous radio-opaque area involving almost entirely the left maxillary sinus and the inferior meatus of the nasal cavity.

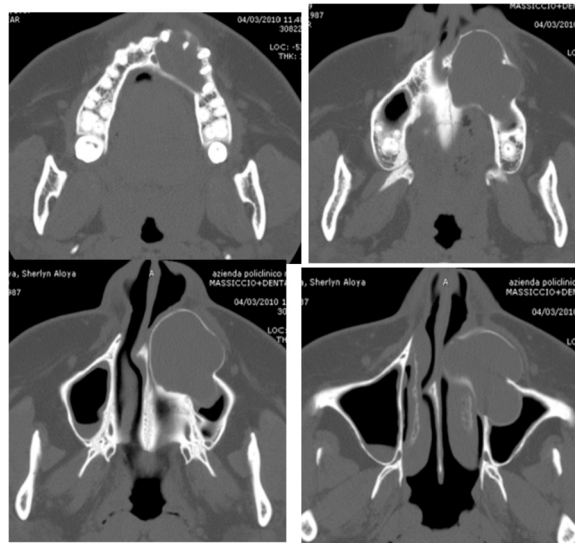


Fig. 2. The axial computed tomography images show a radiopaque area involving the left upper maxilla alveolar process, the left maxillary sinus with the forward expansion of its anterior wall and the inferior meatus.

instrument and the lateral wall of the inferior nasal meatus was drilled using a thin-stalk burr to create a bone window between the sinus and the nose; once reached, the cystic wall was partially removed with an angled micro-debrider and the obtained fragment was kept for the histological examination (Fig. 3). The cut edges of the nasal mucous membrane and the cyst lining were closely matched during the operation without edge-to-edge suturing. A slight fatty gauze dressing was rolled up in the nasal vestibule and kept for approximately 5 h to avoid bleeding. The overall duration of the intervention was about 15 min.

The patient was discharged the day after surgery, and the clinical course was completely uneventful, without any facial swelling or hematoma. Histopathologic findings showed stratified squamous epithelium lining cystic fibro-hyaline tissue. Postoperative endoscopic examination revealed complete epithelialization over the edge of the newly created opening at 4 weeks after marsupialization. Six and 18 months after surgery CT showed the radicular cyst to be substituted by an air-containing cavity with a well-epithelialized ostium at the anterior or anterolateral nasal floor, without evidence of mucus accumulation in the maxillary sinus or recurrence of the cyst (Figs. 4 and 5). The treatment of marsupialization was considered definitive.

3. Discussion

Maxillary sinus, anatomically and functionally related to the nasal cavity and close to the alveolar dental process, can be affected by odontogenic or rhinogenic pathologies. Inflammatory or malformative processes deriving from the dental structures involve the sinus through a continuity solution of the sinus mucosal and osseous floor, apart from the iatrogenic creation of oro-antral communications [1,2]. Most of the rhinogenic sinus pathologies, like sinusitis or mucocèles, depending primarily on bacteria or viruses, are correlated an inadequate drainage and aeration for an obstructed osteo-meatal complex (OMC) [15]. Sometimes an odontogenic pathology, that requires in any case the treatment of the affected teeth or the closure of an oro-antral communication, becomes independent from its own origin and requires a combined approach of a dentist and an otho-rhino-laryngologist [1].

Before the improvement of the endoscopic techniques, the surgical access to the sinus pathology was always from the oral cavity in attempt to reach and drastically remove polyps, foreign bodies or cystic lesions or completely eliminate the affected sinus mucosa and the inflammatory products, as in the Caldwell-Luc procedure. This technique, in particular, aimed to create a better communication between the sinus cavity and the nasal one opening the inferior meatus to improve the post-operative drainage and prevent from recurrence. The conventional intra-oral approach for removal of huge lesions is quite invasive, with the design of wide mucosal flaps, the loss of bone and the possible damage to nerve and vascular bundles, teeth roots and sinus mucosa. This surgery causes relevant post-operative discomforts, such as swelling and hematomas, and complications as wound infection, with dehiscence, oro-antral fistulas, scars formation, and numbness of gingiva [7,11,16]. The Caldwell-Luc procedure, moreover, implies the re-epithelialising of the sinus cavity walls by the oral mucosa with the lack of the normal muco-ciliary physiology and the sinus clearance impairment [1] with the risk of delayed mucocèles and, in some cases, of chronic osteitis [7,17]. As an alternative, trans-oral marsupialization or decompression, represents a minimally invasive approach with the aim to diminish the volume of a cyst and its closeness to delicate anatomical structures and to allow a second definitive removal of the residual lesion with the restoration of the original anatomic architecture [5,6].

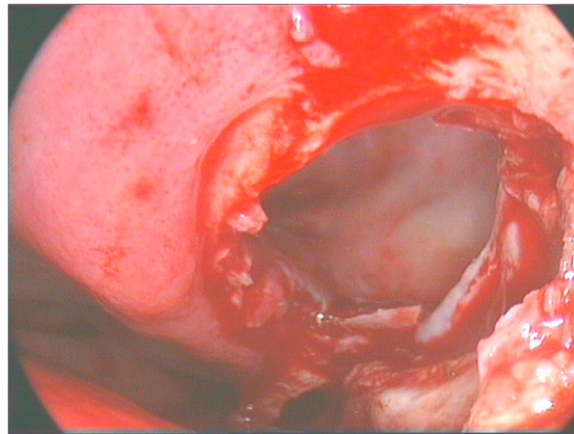


Fig. 3. Endoscopic view after trans-nasal marsupialization of the cystic lesion.

Nevertheless even this approach is prone to drawbacks and complications, just like the intraoral use of a stent or obturator for the communication patency maintaining, with the entrapment of food remnants in the new accessory cavity, the consequent risk of super-infection, and unaesthetic implications in the frontal zones.

The diagnosis of a lesion with a great involvement of a maxillary sinus is no simple. The clinical scenario may be confused by a super-imposition of a sinusitis to a primary odontogenic problem. Radicular or dentigerous cysts involving the maxillary sinus are clinically silent except in case of an acute super-infection with pain and fistulas, and panoramic x-rays can show only a diffuse radio-opacity in the maxillary sinus. These lesions can be diagnosed on CT scans where they appear as radio-opacity with well-circumscribed margins related to the moving up of the sinus floor and a thin rim of bone around the profile of the cyst [4,18]. Dentigerous cysts are always associated with an impacted dislocated tooth. In magnetic resonance imaging a cyst appears as a medium-intensity homogenous lesion on T1-weighted images and hyper-intense homogenous lesion on T2-weighted series. Nevertheless, the diagnostic distinction of an odontogenic lesion involving the maxillary sinus and nasal cavity from dental abscesses, nasal furuncles, non odontogenic cysts, and benign or malignant soft tissue tumors may be debatable [11]. Hence an endoscopic approach, even if for an incisional biopsy, can be useful to choose the adequate therapeutic approach to the disease.

The progress of nasal endoscopy allowed to discover the role of the ciliate sinus mucosa and the patency of the osteomeatal complex in preventing from sinus pathologies [7] and pointed out the importance of a mini-invasive surgical approach for sparing as much as possible the structure and the function of the maxillary sinus. The improvement of endoscopic instrumentation allows today to respect the sinus mucosa considering that areas of exposed bone are subsequently recovered by a mucosa with decreased ciliary density and function with resultant chronic inflammation, scarring, and mucocele formation [7]. Hence, previously used grasping forceps, harmful for sinus mucosa, have been replaced by 60–45° angled instruments with more precise through-cutting capability, associated to micro-debriders, angled blades and suction-irrigation drills.

In the reported case the pre-operative diagnosis was not so evident. The anterior expansion of the cyst with the involvement of the nasal cavity and the swelling of the para-nasal region with the lifting of the left nostril in absence of

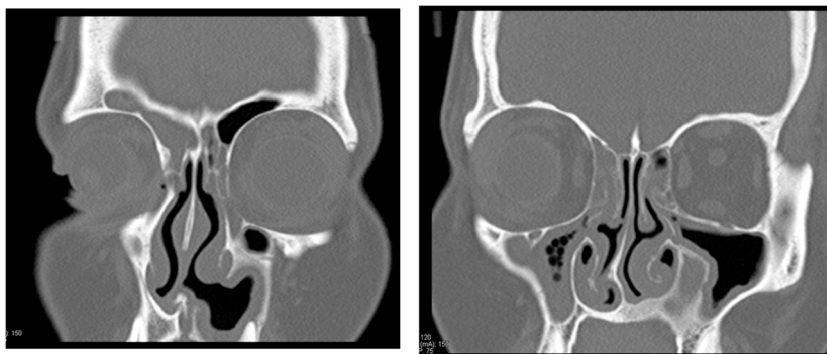


Fig. 4. The coronal computed tomography images six months after the marsupialization.

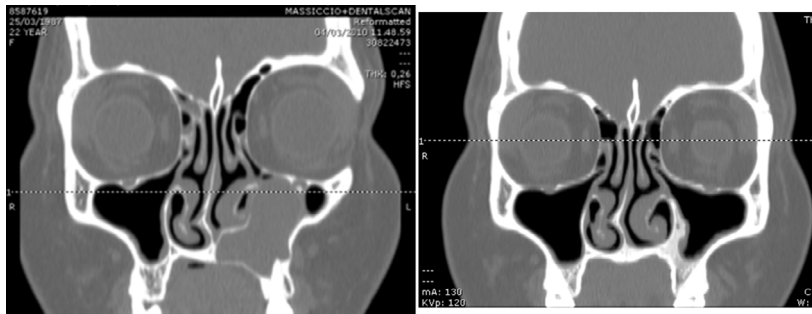


Fig. 5. The coronal computed tomography images before the treatment (left) and 18 months after marsupialization(right). The comparison of the two images underlines the recovering of the anatomical architecture of maxillary sinus and nasal fossa with the disappearance of the lesion.

symptoms could be predictive for a naso-labial cyst; nevertheless the periapical involvement of the lateral incisor, necrotic, pushed us to a pre-operative diagnosis of a radicular cyst. Actually nobody could have excluded a keratocyst or, a mixed fibrous-epithelial neoplasm.

A sinus involving lesion can be reached through the medium nasal meatus, widening the osteo-meatal complex (OMC) with (FESS) technique, whose previous aim was improving the drainage of mucous secretions in rhino-sinusitis, facilitating a quicker recovery of the sinus clearance. Generally this approach is preferred in case of complete involvement of the sinus cavity by a sinusitis or a large dentigerous cyst often associated to a traditional oral approach from the canine fossa [17]. The typical situation where the two specialists, nasal endoscopist and oral surgeon, are involved is the chronic sinusitis after an oro-antral communication, that can be a complication of a previous intra-oral approach for removal huge lesion, dental extraction, alveolar reconstructive surgery and implantology. It is very important to perform any surgical closure of the oro-antral communication in a disease-free sinus situation [1,19].

If a lesion is distant from the OMC, in more anterior location, and involving the anterior and lower portion of the nasal cavity the approach through the inferior meatus is preferred after a mucosal and bone opening of the lateral nasal wall. This endoscopically assisted nasal approach resulted useful in treating nasolabial [11] or naso-palatine duct cysts [10,13], but even odontogenic cysts as radicular and dentigerous ones [12,20], and it was preferred to the oral access to remove canines in a paranasal inclusion [14,21,22].

The endoscopic nasal approach, both from the medium or inferior meatus was adopted even for marsupialization [4,10,20]. This technique can be chosen even intra-operatively when results particularly difficult to remove the entire cyst's wall with the possibility to live remnants of cystic lining reducing the risk of recurrence [4,23]. Transnasal endoscopic marsupialization has been reported in treating postoperative maxillary mucocoeles, even known as “postoperative maxillary cysts”: these are complications of Caldwell-Luc operations [16,17] and had been traditionally treated with trans-oral excision and sub-labial vestibular antrostomy, with a lot of complications [24].

After marsupialization of a cyst, epithelialization will occur between the cut edges of the nasal mucosa and the lining of the cyst that results progressively completely substituted by the respiratory ciliated epithelium, mimicking a new accessory paranasal sinus. Differently from a marsupialization by a trans-oral approach, the respiratory mucosa and the patency of the surgically created ostium with the upper airways provided the new-created cavity with a particular ventilation and drainage function preventing from mucous accumulation and infective complications, as a new paranasal sinus [20]. Even with endoscopic assistance, marsupialization is more rapid and simple than enucleation with a low intra surgically problems and complications.

In treating the reported case it was chosen the minimal invasive approach according to the literature background, confident that any other option could have entailed longer treatment time, a longer and more painful recovery, damage to the sinus mucosa, the loss of the normal bone architecture and, considering the anterior expansion of the lesion, un-aesthetic post-operative implications. A complete healing of the lesion has been obtained without any recurrence. Obviously, this treatment required a complex and expensive instrumentation and particular skills.

This surgical approach has been rarely adopted so, considering its benefits, it was judged worth-wile to propose it to the scientific audience.

4. Conclusion

Marsupialization of an odontogenic radicular cyst involving the nasal and the sinus cavities with an endoscopic nasal-assisted surgical approach is a valid diagnostic and therapeutic alternative to a trans-oral surgical access, considering that it entails minimal operative timing, no post-operative discomfort and it can be considered definitive without risk of recurrence.

References

- [1] Hajjioannou J, Koudounarakis E, Alexopoulos K, Kotsani A, Kyrmizakis DE. Maxillary sinusitis of dental origin due to oroantral fistula, treated by endoscopic sinus surgery and primary fistula closure. *J Laryngol Otol* 2010;124:986–9.
- [2] Zirk M, Dreiseidler T, Pohl M, Rothamel D, Buller J, Peters F, Zoller JE, Kreppel M. Odontogenic sinusitis maxillaris: a retrospective study of 121 cases with surgical intervention. *J Cranio-Maxillo-Fac Surg* 2017;45:520–5.
- [3] Costa F, Emanuelli E, Robiony M, Zerman N, Polini F, Politi M. Endoscopic surgical treatment of chronic maxillary sinusitis of dental origin. *J Oral Maxillofac Surg* 2007;65:223–8.
- [4] Jain K, Goyal P. Endoscopic surgical treatment of maxillary odontogenic cysts. *Int For. Allergy Rhinol*. 2015;5:602–4.
- [5] Lizio G, Sterrantino AF, Ragazzini S, Marchetti C. Volume reduction of cystic lesions after surgical decompression: a computerised three-dimensional computed tomographic evaluation. *Clin Oral Invest* 2013;17:1701–8.
- [6] Lizio G, Tomaselli L, Landini L, Marchetti C. Dentigerous cysts associated with impacted third molars in adults after decompression: a prospective survey of reduction in volume using computerised analysis of cone-beam computed tomographic images. *Br J Oral Maxillofac Surg* 2017;55:691–6.
- [7] Govindaraj S, Adappa ND, Kennedy DW. Endoscopic sinus surgery: evolution and technical innovations. *J Laryngol Otol* 2010;124:242–50.
- [8] Sindwani R, Manz R. Technological innovations in tissue removal during rhinologic surgery. *Am J Rhinol Allergy* 2012;26:65–9.
- [9] Xu GZ, Jiang Q, Yang C, Yu CQ, Zhang ZY. Clinicopathologic features of dentigerous cysts in the maxillary sinus. *J Craniofac Surg* 2012;23:e226–31.
- [10] Honkura Y, Nomura K, Oshima H, Takata Y, Hidaka H, Katori Y. Bilateral endoscopic endonasal marsupialization of nasopalatine duct cyst. *Clin Pract* 2015;5:748.
- [11] Ozer S, Cabbazade C, Ogretmenoglu O. A new transnasal approach to nasolabial cyst: endoscopic excision of nasolabial cyst. *J Craniofac Surg* 2013;24:1748–9.
- [12] Seno S, Ogawal T, Shibayama M, Ogawa F, Fukui J, Owaki S, Suzuki M, Shimizu T. Endoscopic sinus surgery for the odontogenic maxillary cysts. *Rhinology* 2009;47:305–9.
- [13] Wu PW, Lee TJ, Huang CC, Huang CC. Transnasal endoscopic marsupialization for a huge nasopalatine duct cyst with nasal involvement. *J Oral Maxillofac Surg* 2013;71:891–3.
- [14] Marianetti TM, Torroni A, Gasparini G, Moro AS, Pelo S. Transnasal endoscopic approach to the impacted maxillary canine. *J Craniofac Surg* 2014;25:1859–61.
- [15] Kamel RH. Endoscopic transnasal surgery in chronic maxillary sinusitis. *J Laryngol Otol* 1989;103:492–501.
- [16] Huang CC, Chen CW, Lee TJ, Chang PH, Chen YW, Chen YL, Fu CH, Wu CC, Huang CC. Transnasal endoscopic marsupialization of postoperative maxillary mucoceles: middle meatal antrostomy versus inferior meatal antrostomy. *Eur Arch Oto-Rhino-Laryngol* 2011;268:1583–7.
- [17] Sawatsubashi M, Murakami D, Oda M, Komune S. Transnasal endoscopic surgery of post-operative maxillary cysts. *J Laryngol Otol* 2015;129(Suppl 2):S46–51.
- [18] Penarrocha M, Carrillo C, Penarrocha M, Penarrocha D, von Arx T, Vera F. Symptoms before periapical surgery related to histologic diagnosis and postoperative healing at 12 months for 178 periapical lesions. *J Oral Maxillofac Surg* 2011;69:e31–7.
- [19] Mehra P, Murad H. Maxillary sinus disease of odontogenic origin. *Otolaryngol Clin North Am* 2004;37:347–64.
- [20] Su CY, Chien CY, Hwang CF. A new transnasal approach to endoscopic marsupialization of the nasolabial cyst. *Laryngoscope* 1999;109:1116–8.
- [21] Iwai T, Aoki N, Yamashita Y, Omura S, Matsui Y, Maegawa J, Tohna I. Endoscopic removal of bilateral supernumerary intranasal teeth. *J Oral Maxillofac Surg* 2012;70:1030–4.
- [22] Sanei-Moghaddam A, Hyde N, Williamson P. Endoscopic removal of a supernumerary tooth from the nasal cavity in an adult. *Br J Oral Maxillofac Surg* 2009;47:484–5.
- [23] Cho DY, Hwang PH. Results of endoscopic maxillary mega-antrostomy in recalcitrant maxillary sinusitis. *Am J Rhinol* 2008;22:658–62.
- [24] Murray JP. Complications after treatment of chronic maxillary sinus disease with Caldwell-Luc procedure. *Laryngoscope* 1983;93:282–4.